
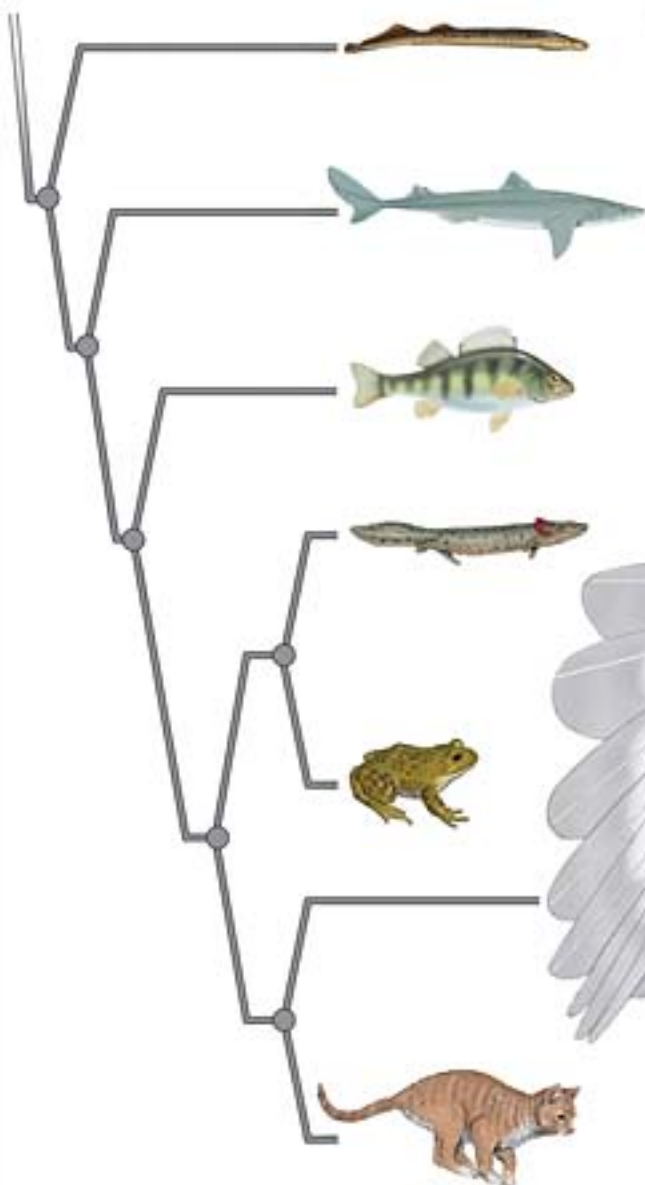


# The Dissection of Vertebrates

A LABORATORY MANUAL

Gerardo De Iuliis  
Dino Pulerà



# **The Dissection of Vertebrates**

**A Laboratory Manual**





# **The Dissection of Vertebrates**

## **A Laboratory Manual**

Gerardo De Iuliis, PhD

University of Toronto

and George Brown College of Applied Arts and Technology

Dino Pulerà, MScBMC, CMI




AMSTERDAM • BOSTON • HEIDELBERG • LONDON • NEW YORK • OXFORD  
PARIS • SAN DIEGO • SAN FRANCISCO • SINGAPORE • SYDNEY • TOKYO

Academic Press is an imprint of Elsevier



Acquisitions Editor: Tamsin Kent  
Marketing Manager: Trevor Daul  
Project Manager: Jeff Freeland  
Cover Design Direction: Cate Rickard Barr  
Text Design: Julio Esperas  
Composition: SNP Best-set Typesetter Ltd., Hong Kong  
Printer: Hing Yip Printing Co., Ltd.

Academic Press is an imprint of Elsevier  
30 Corporate Drive, Suite 400, Burlington, MA 01803, USA  
525 B Street, Suite 1900, San Diego, California 92101-4495, USA  
84 Theobald's Road, London WC1X 8RR, UK

This book is printed on acid-free paper. 

Copyright © 2007, Elsevier Inc. All rights reserved.

Exceptions:

- (a) Except as otherwise provided in Paragraph 2(b) below, the Author hereby grants and transfers to the Publisher the Work (including any prior unpublished versions of the Work) and all rights in the Work, including the entire copyright (and any renewals and extensions of the copyright) throughout the world, and all rights under copyright, including the exclusive right to publish, perform, reproduce, distribute, and sell the Work and to create derivative works, in all forms or media now known or later developed, in all languages, throughout the world, and the right to license or authorize others to do all of the foregoing.
- (b) With respect to original illustrations created by the Author for the Work (herein the "Illustrations"), copyright for which is retained by the Author, the Author grants to the Publisher the non-exclusive right to publish the Illustrations in all editions and versions of the Work, including derivative works based on the Work, for sales throughout the world in all forms or media now known or hereafter developed, and in all languages. The Author further agrees that the Publisher may grant to third parties permission to include the Illustrations in other works, and any copies of display of the Illustrations, will include proper credit to the Work as the sources of first publication of the Illustrations. However, the Author further agrees that the Author will not permit publication of the Illustrations in any competing works.

No part of this publication may be reproduced or transmitted in any form or by any means, electronic or mechanical, including photocopy, recording, or any information storage and retrieval system, without permission in writing from the publisher.

Permissions may be sought directly from Elsevier's Science & Technology Rights Department in Oxford, UK: phone: (+44) 1865 843830, fax: (+44) 1865 853333, E-mail: [permissions@elsevier.com](mailto:permissions@elsevier.com). You may also complete your request on-line via the Elsevier homepage (<http://elsevier.com>), by selecting "Support & Contact" then "Copyright and Permission" and then "Obtaining Permissions."

#### Library of Congress Cataloging-in-Publication Data

Application submitted

#### British Library Cataloguing-in-Publication Data

A catalogue record for this book is available from the British Library.

ISBN 13: 978-0-12-088776-7

ISBN 10: 0-12-088776-2

For information on all Academic Press Publications  
visit our Web site at [www.books.elsevier.com](http://www.books.elsevier.com)

Printed in the United States of America

06 07 08 09 10 8 7 6 5 4 3 2 1

Working together to grow  
libraries in developing countries

[www.elsevier.com](http://www.elsevier.com) | [www.bookaid.org](http://www.bookaid.org) | [www.sabre.org](http://www.sabre.org)

ELSEVIER

BOOK AID  
International

Sabre Foundation

This book is for our spouses,  
Virginia and Cinzia,  
and children,  
Daniel, Theodore, and Jacob,  
who are our loves and our lives

With deep respect, admiration, and gratitude, we dedicate this book to three teachers at the University of Toronto that early on in our academic careers instilled in us a passion for anatomy, paleontology, and art, as well as the intellectual discipline required to make them our careers. Their contributions are to be seen throughout the following pages.

Charles S. (Rufus) Churcher  
Stephen G. Gilbert  
Thomas S. Parsons

To our readers:

Despite our best efforts, there are bound to be errors that escaped our notice, and we would appreciate being informed of these. We encourage you to contact us directly with your comments, suggestions, and possible ideas of text and illustrations for future editions of this book. We look forward to hearing from you.

Sincerely,

Dr. Gerry De Iuliis  
gerry.deiuliis@utoronto.ca

Dino Pulerà  
dino.pulera@utoronto.ca

# CONTENTS

<i>Contents Guide</i>	<i>xi</i>
<i>Preface</i>	<i>xiii</i>
<i>Acknowledgments</i>	<i>xvii</i>
<i>Introduction</i>	<i>xix</i>

## CHAPTER 1 THE CRANIATA AND VERTEBRATA

Phylogeny and Classification	1
Vertebrate Relatives	4
Craniates and Vertebrates	7
Early Stages in the Evolution of Vertebrates	8
Vertebrata	8

## CHAPTER 2 THE LAMPREY

Introduction	19
Section I—Skeleton	19
Section II—External Anatomy	20
Section III—Pleuroperitoneal Cavity and Viscera	21
Section IV—Sagittal Section	22
Key Terms: Lamprey	26

## CHAPTER 3 THE SHARK

Introduction	27
Section I—Skeleton	27
Chondrocranium	28
Splanchnocranium	28

Vertebrae and Fins	31
Key Terms: Skeleton	33
<b>Section II—External Anatomy</b>	<b>35</b>
Key Terms: External Anatomy	37
<b>Section III—Muscular System</b>	<b>39</b>
Trunk and Appendicular Muscles	39
Muscles of the Head and Branchial Region	40
Branchiomic Musculature	40
Hypobranchial Musculature	43
Key Terms: Muscular System	45
<b>Section IV—Digestive and Respiratory Systems</b>	<b>45</b>
Key Terms: Digestive and Respiratory Systems	50
<b>Section V—Cardiovascular System</b>	<b>51</b>
Heart and Arterial Circulation	51
Heart	51
Arteries of the Branchial Region	51
Branches of the Dorsal Aorta	52
Venous Circulation	55
Hepatic Portal System	55
Renal Portal System	58
Systemic Veins	58
Key Terms: Cardiovascular System	59
<b>Section VI—Urogenital System</b>	<b>59</b>
Male Urogenital System	62
Key Terms: Male Urogenital System	62
Female Reproductive System	62
Key Terms: Female Reproductive System	63
<b>Section VII—Sensory Organs</b>	<b>63</b>
Ampullae of Lorenzini	63
Lateral Line System	63
Nose	63
Eye	63



Ear	67
Key Terms: Sensory Organs	68
<b>Section VIII—Brain and Cranial Nerves</b>	<b>70</b>
Brain	71
Cranial Nerves (CNN 0, I–X, and Lateral Line Nerves)	73
Ventral View of the Brain	75
Sagittal Section of the Brain	76
Key Terms: Brain and Cranial Nerves	76

## CHAPTER 4 THE PERCH

<b>Introduction</b>	<b>77</b>
<b>Section I—Skeleton</b>	<b>77</b>
Skull	77
Key Terms: Skull	79
Postcranial Skeleton	80
Key Terms: Postcranial Skeleton	80
<b>Section II—External Anatomy</b>	<b>81</b>
Key Terms: External Anatomy	82
<b>Section III—Mouth, Oral Cavity, and Pharynx</b>	<b>82</b>
Key Terms: Mouth, Oral Cavity, and Pharynx	83
<b>Section IV—Pleuroperitoneal Cavity and Viscera</b>	<b>83</b>
Key Terms: Pleuroperitoneal Cavity and Viscera	87

## CHAPTER 5 THE MUDPUPPY

<b>Introduction</b>	<b>89</b>
<b>Section I—Skeleton</b>	<b>89</b>
Cranial Skeleton	89
<i>Skull</i>	89
<i>Mandible</i>	90
<i>Hyoid Apparatus</i>	91
Key Terms: Cranial Skeleton	91
Postcranial Skeleton	92
<i>Axial Skeleton</i>	92
<i>Appendicular Skeleton</i>	92
Key Terms: Postcranial Skeleton	92

<b>Section II—External Anatomy</b>	<b>94</b>
Key Terms: External Anatomy	95
<b>Section III—Mouth, Oral Cavity, and Pharynx</b>	<b>95</b>
Key Terms: Mouth, Oral Cavity, and Pharynx	96
<b>Section IV—Pleuroperitoneal Cavity and Viscera</b>	<b>96</b>
Key Terms: Pleuroperitoneal Cavity and Viscera	98
<b>Section V—Urogenital System</b>	<b>98</b>
Male Urogenital System	102
Female Urogenital System	102
Key Terms: Urogenital System	102
<b>Section VI—Cardiovascular System</b>	<b>102</b>
Heart	102
Venous System	102
Arterial System	105
Key Terms: Cardiovascular System	107

## CHAPTER 6 THE FROG

<b>Introduction</b>	<b>113</b>
<b>Section I—Skeleton</b>	<b>113</b>
Skull, Mandible, and Hyoid Apparatus	113
Key Terms: Skull, Mandible, and Hyoid Apparatus	116
Postcranial Skeleton	117
Key Terms: Postcranial Skeleton	118
<b>Section II—External Anatomy</b>	<b>118</b>
Key Terms: External Anatomy	120
<b>Section III—Mouth, Oral Cavity, and Pharynx</b>	<b>120</b>
Key Terms: Mouth, Oral Cavity, and Pharynx	120
<b>Section IV—Pleuroperitoneal Cavity, Viscera, and Urogenital System</b>	<b>120</b>
Key Terms: Pleuroperitoneal Cavity, Viscera, and Urogenital System	125
<b>Section V—Cardiovascular System</b>	<b>125</b>
Key Terms: Cardiovascular System	130

## CHAPTER 7 THE CAT

<b>Introduction</b>	<b>131</b>		
<b>Section I—Skeleton</b>	<b>132</b>		
Cranial Skeleton	132		
<i>Skull</i>	132		
<i>Mandible</i>	138		
<i>Hyoid Apparatus</i>	139		
Key Terms: Cranial Skeleton	139		
Postcranial Skeleton	140		
<i>Vertebral Column</i>	140		
Cervical Vertebrae	140		
Thoracic Vertebrae	141		
Lumbar Vertebrae	142		
Sacral Vertebrae	142		
Caudal Vertebrae	143		
<i>Ribs</i>	144		
<i>Sternum</i>	144		
<i>Forelimb</i>	144		
Scapula	144		
Clavicle	145		
Humerus	145		
Ulna	146		
Radius	146		
Manus	147		
<i>Hind Limb</i>	147		
Pelvis	147		
Femur	147		
Patella	148		
Tibia	148		
Fibula	149		
Pes	149		
Key Terms: Postcranial Skeleton	150		
<b>Section II—External Anatomy</b>	<b>151</b>		
Key Terms: External Anatomy	152		
<b>Section III—Muscular System</b>	<b>153</b>		
Muscle Terminology	153		
Connective Tissue and Fiber Direction	153		
Key Terms: Muscular System	153		
Subdivision of the Musculature	153		
Skinning the Cat	153		
Appendicular Musculature	158		
<i>Muscles of the Forelimb</i>	158		
Superficial Forelimb Muscles: Lateral View	158		
Superficial Forelimb Muscles: Ventral View	160		
Deep Forelimb Muscles: Lateral View	160		
Deep Forelimb Muscles: Lateral View with Forelimb Abducted	163		
Key Terms: Muscles of the Forelimb	165		
		<i>Muscles of the Hind Limb</i>	165
		Superficial Hind Limb Muscles: Lateral View	165
		Superficial Hind Limb Muscles: Medial View	166
		Deep Hind Limb Muscles: Lateral View	168
		Deep Hind Limb Muscles: Medial View	171
		Key Terms: Muscles of the Hind Limb	173
		<i>Muscles of the Head and Trunk</i>	174
		Muscles of the Trunk	174
		Muscles of the Back and Neck	174
		Muscles of the Throat and Jaw	178
		Key Terms: Muscles of the Head and Trunk	180
		<b>Section IV—Digestive and Respiratory Systems</b>	<b>180</b>
		Salivary Glands	180
		Oral Cavity and Pharynx	180
		Pericardial Cavity	186
		Abdominopelvic Cavity	186
		Key Terms: Digestive and Respiratory Systems	194
		<b>Section V—Cardiovascular System</b>	<b>194</b>
		Heart	194
		Vessels	195
		<i>Main Vessels Associated with the Heart</i>	195
		<i>Vessels Anterior to the Diaphragm</i>	195
		<i>Vessels Posterior to the Diaphragm</i>	201
		<i>Vessels Associated with the Viscera</i>	205
		Key Terms: Cardiovascular System	207
		<b>Section VI—Urogenital System</b>	<b>212</b>
		Excretory System	212
		Key Terms: Excretory System	214
		Male Reproductive System	214
		<i>Opening the Pelvic Canal</i>	216
		<i>Male Reproductive System, Continued</i>	216
		Key Terms: Male Reproductive System	216
		Female Reproductive System	216
		Key Terms: Female Reproductive System	217
		<b>Section VII—Brain and Cranial Nerves</b>	<b>218</b>
		Meninges	218
		Telencephalon	218
		Diencephalon	220
		Mesencephalon	222
		Metencephalon	222
		Myelencephalon	222
		Sagittal Section of the Brain	222
		Cranial Nerves	224
		Key Terms: Brain and Cranial Nerves	224

## CHAPTER 8

# THE PIGEON

### Introduction 227

### Section I—Skeleton 227

Skull, Mandible, and Hyoid Apparatus 227

Postcranial Skeleton 229

*Vertebrae* 229

*Ribs* 230

*Sternum* 231

*Pectoral Girdle and Forelimb* 231

*Pelvic Girdle and Hind Limb* 233

Key Terms: Skeleton 233

### Section II—External Anatomy 234

Key Terms: External Anatomy 234

### Section III—Musculature 236

Key Terms: Musculature 241

### Section IV—Body Cavity, Viscera, and Vessels 241

Key Terms: Body Cavity, Viscera, and Vessels 250

*Selected References* 251

*Index* 253

# CONTENTS GUIDE

<b>CHAPTER 1</b>	<b>THE CRANIATA AND VERTEBRATA</b>	<b>1</b>
<b>CHAPTER 2</b>	<b>THE LAMPREY</b>	<b>19</b>
<b>CHAPTER 3</b>	<b>THE SHARK</b>	<b>27</b>
<b>CHAPTER 4</b>	<b>THE PERCH</b>	<b>77</b>
<b>CHAPTER 5</b>	<b>THE MUDPUPPY</b>	<b>89</b>
<b>CHAPTER 6</b>	<b>THE FROG</b>	<b>113</b>
<b>CHAPTER 7</b>	<b>THE CAT</b>	<b>131</b>
<b>CHAPTER 8</b>	<b>THE PIGEON</b>	<b>227</b>



# PREFACE

The past two decades have witnessed a rediscovery among researchers of the value of comparative vertebrate anatomy. In large part this has been due to the establishment of phylogenetic systematics and the renewed awareness of the vast contribution that morphology can make to our understanding of the history of vertebrates. However, the study of anatomy at the introductory and intermediate college levels has suffered, as both its stature and perceived importance have diminished. There are several reasons for this. Certainly, and regrettably, the trend at most major academic institutions has followed a path away from whole organism biology, as genetics and molecular biology have, for good reason, become popular. At the same time, there has been increased resistance from some quarters to the use of animals in various scientific endeavors. Further, easily accessible computer software has been developed that allows convenient visual journeys through vertebrate bodies without the effort, expense, and “mess” of actual dissection.

The study of anatomy and morphology has much to offer the student wishing to pursue a career in biological or medical fields. Proper training in vertebrate anatomy must include a practical component that involves dissection in addition to lectures. No other method, regardless of how intricate in presentation and scope, can replace the actual hands-on experience. It is only through a careful, patient, and repeated practical approach that one gains the expertise and practice required for understanding the spatial relationships that are essential to learning how a vertebrate body is constructed, how its component structures are related to each other, and how form and function interact.

There are those who would suggest that such a course of study is unnecessary and that anatomy can be learned solely through texts or software. While such materials (this text among them) may prove to be invaluable as aids or tools for learning, we ought not to substitute these adjuncts for the means through which we *must* come to know the vertebrate body. To do so would be akin to preparing for an acting career by watching films, rather than through rehearsing and acting workshops. Few of us would feel comfortable with mechanics

trained solely through the Internet, trust a surgeon who has learned the craft strictly through instructional videos, or fly with a pilot who has only flown missions on a flight simulator. It is not because such instructional methods are not useful that we would be suspicious. Rather, we recognize that, for fields whose subject matter includes components arranged in complex spatial relationships, these media are meant to be used as tools that supplement and guide the trainee through a methodical, first-hand experience with the subject matter itself. The debate on the value of dissection is particularly lively for human medical anatomy (see, for example, Elizondo-Omaña et al., 2005; Pawlina and Lachman, 2004; and Rizzolo, 2002). Many researchers are clearly in favor of dissection, but also see the need to incorporate the advanced imaging technologies currently available. The same logic should apply for any vertebrate, but similarly advanced technologies are unlikely to be applied to a broad range of vertebrates in the foreseeable future.

The central theme of most previous dissection manuals has been the structural changes in vertebrates through their evolution from fish to mammals, with the ultimate goal being to place mammalian anatomy in context. This is certainly a necessary prerequisite for one interested principally in mammalian systematics or medicine. However, not all students or instructors are interested primarily in mammals. Two of the important lessons emphasized by phylogenetics are that all living vertebrates are as evolved as mammals, and that their anatomy has as much to tell us about evolution, function, and morphology. Indeed, a common complaint among academic faculty is that comparative vertebrate anatomy courses have become courses on the anatomy of the cat. Be that as it may, it is important to remember that negative perceptions can often be detrimental to the well-being of a field of study and may sway departmental decisions on whether the continuation of some courses is worth the effort and expense. It is up to those of us who teach comparative anatomy to push forward and maintain its vigor and centrality, in part by relating its wide applicability to related fields, such as systematics, evolutionary biology, paleontology, paleobiology, and functional morphology; and as a



prerequisite for higher-level zoology courses, such as mammalogy, herpetology, ornithology, and vertebrate paleontology.

Our format and coverage is aimed at striking a balance between presenting an evolutionary sequence to “higher” vertebrates and treating the anatomy of each representative vertebrate as inherently important. The sequence of vertebrates is similar to those presented by other authors, but we emphasize throughout that the living vertebrates are not and cannot be used as intermediates. For this reason, we provide discussions of the important features of each group based on the derived features that diagnose a particular phylogenetic grouping. We thus do not treat vertebrates by traditional grouping methods; we would rather, from the beginning, present the student with information that reflects our formal thinking and classification.

The main goal of this text is to provide today’s visually oriented student population with a manual that links succinct and pedagogically effective textual direction with relevant, high-quality, accurate, and attractive visual references to promote efficient learning of the complex, spatially abstract subject matter in the limited time available in a laboratory setting. Thus, a critical feature of *The Dissection of Vertebrates* is the inclusion of numerous high-quality, didactic, color illustrations. Each depicts the vertebrate approximately as it would appear in a particular stage of dissection, rather than presenting an idealized figure or photographs, as is the case for most other manuals. This in itself facilitates the use of these illustrations, both in learning and later during recall for studying purposes. Photographs are used sparingly. We have chosen illustration over photography in the vast majority of cases because illustration is the method that affords the most control in communicating the pertinent features of a particular dissection. Photographs are indiscriminate, whereas illustration in combination with color allows minimization of unnecessary and distracting background anatomical detail, while still maintaining it. Indeed, we have taken great care to ensure that the background anatomy in the illustrations is accurate. This is important because it gives the user (instructor and student) a context for the anatomical structures under study.

Although students aspiring to careers in systematics, vertebrate paleontology, or functional morphology are the primary intended audience of this manual, *The Dissection of Vertebrates* is sufficiently flexible in scope and organization that it may be used in any course on vertebrate anatomy. We present a wide-ranging and encompassing reference manual that will both help students learn the basic anatomy of vertebrates and function as a guide once they are ready to venture into the primary literature.

*The Dissection of Vertebrates* presents dissection instructions on more vertebrates than is normally the case. The primary focus is on the shark, mudpuppy, and cat, as is usual, but it also provides detailed information on vertebrates either not usually considered or treated very superficially by most other manuals that include multiple vertebrates. It is ironic that the two most speciose groups of vertebrates, the birds and ray-finned fishes, are not adequately covered (if covered at all) in other dissection manuals. We hope that by providing reasonably detailed guides for these vertebrates, instructors will feel more inclined to include these readily available and inexpensive vertebrates in their courses.

This manual is organized by vertebrate. The anatomy of each is then presented systemically. This approach allows all the information on a particular vertebrate to be studied at one time and in sequence. We believe, based on years of instruction, that this method provides a more straightforward integration of the systems. The inclusion of many vertebrates and the organization by vertebrate makes *The Dissection of Vertebrates* more flexible for use in a broad-based full or half-year course at the introductory college level, and allows more convenient organization of course content, depending on time and availability of specimens and the instructor’s preferences.

At the same time, we omit many topics that are often covered in most other manuals. Sections on vertebrates or structures that students are unlikely ever to dissect at the intended level of study are not included. Instead, we have focused the material on examples that are likely to be encountered in an introductory lab course, leaving those topics best presented in texts that accompany the lecture portion of a course.

Much of the required background information is presented in the Introduction and Chapter 1. This includes sections on planes of dissection and orientational terminology (see below), as well as an introduction to vertebrates and their relatives (Chapter 1). We suggest that these sections be included as part of the assigned readings for a particular laboratory for each vertebrate. This method will expose students repeatedly to the broad evolutionary development of each system. Terms that are required learning are in boldface print throughout the manual. Bold-faced terms are listed in a Key Terms section (which also provides common synonyms in parentheses) following each major component. Students will know at a glance the structures for which they are responsible. We suggest that students use this section as a key to learning the structures by writing a short description for each. The Key Terms sections also allow instructors to adapt this manual to their personal preferences in running their course. Structures that are not required can be identified and crossed out, so that

students know they are not responsible for them. This method effectively allows an instructor to limit the detail of the dissection.

We believe that the concise presentation of dissection instructions combined with minimal background information results in a straightforward text that will facilitate and focus the student's learning of anatomy in laboratory. In contrast to most other manuals, much of the background material presented in lecture is

omitted here, so *The Dissection of Vertebrates* is less cumbersome to use even though it covers more vertebrates than do other manuals. All the information is relevant for laboratory purposes. This should facilitate matters for the instructor as well. Among other things, it will allow a clear answer to the often-asked question, "What am I responsible for reading?" The response can, without too much exaggeration, be, "All of it."



# ACKNOWLEDGMENTS

Many colleagues, students, friends, and members of our families have contributed to the production of this book, from carrying out simple tasks to proofreading to providing emotional encouragement and support. We are grateful to them all, although we can directly acknowledge only a few of them here: Thomas Carr (Carthage College) for preparing selected dissections and providing valuable input on text and illustrations; Hans-Dieter Sues (Smithsonian Institution), Jeff Thomason (University of Guelph), and Sergio F. Vizcaíno (Museo de La Plata) for providing particularly comprehensive reviews of earlier versions of the manuscript that greatly improved the final product; Rob Baker and Jim Thomson (University of Toronto) and Rivie Seaberg (George Brown College of Applied Arts and Technology) for academic and institutional support; Stephen Mader (Artery Studios Inc.) for his encouragement and support; Peter von Bitter, Kathy David, Brian Iwama, and Peter Reali for help with photography; Celestino De Iuliis for reading earlier drafts of the manuscript; Marco Zimmer-De Iuliis for expert preparation of specimens; Sandra Reali for logistic support; Kevin Seymour for access to the skeletal collections of the Royal Ontario Museum; Skulls Unlimited ([www.skullsunlimited.com](http://www.skullsunlimited.com)) for providing skeletons for study and photography; Barry Bruce (CSIRO Division of Marine Research, Tasmania), Mark McGrouther and Elizabeth Cameron (Australian

Museum) and Andrew and Silvy Fox (Rodney Fox Shark Museum, Australia) for providing shark dissection photos; a special thank you to Steven E. Campana (Bedford Institute of Oceanography, Canada; [www.marinebiodiversity.ca/shark/english/index.htm](http://www.marinebiodiversity.ca/shark/english/index.htm)) for also providing digital and labeled shark dissection photos, and very kindly allowing us to reprint the SEM photo of the spiny dogfish skin (Figure 3.12(g)). We thank several anonymous reviewers for their helpful comments, suggestions, and corrections. The efforts of Timothy Rowe (The University of Texas at Austin) on the Digital Morphology web site ([www.Digimorph.org](http://www.Digimorph.org)) are greatly appreciated. Although we did not make direct use of *Digimorph* images, several of them were extremely useful in the interpretation of anatomical features. We thank our editors Tamsin Kent, Nancy Maragioglio, and Kelly Sonnack and Jeff Freeland of Elsevier for their patience, guidance, and keeping us on target. We are also indebted to David Cella (formerly of Elsevier) for initial consideration of our proposal and recognizing the potential for this book and to Stephen G. Gilbert for showing us how to get started on creating our own book, and for his encouragement, support, advice, and continued inspiration. Lastly, we thank Virginia and Cinzia for being there beside us every step of the way in seeing this book through to the end—it has been a long and challenging journey.



# INTRODUCTION

The study of vertebrate anatomy is an interesting and valid field of study for gaining insight into the structure and function of vertebrates. But why should this be important? Of the numerous reasons, we mention only a few.

- It provides us with knowledge of the structures of different organisms and the great variety of form among vertebrates.
- It allows us to examine how the form of these structures is related to their function and thus how morphology is suited to a particular mode of life.
- The characteristics or features of vertebrates preserve information on their ancestry: The features are modified and passed on through the course of generations, and we may use such knowledge to discover the genealogical relationships among vertebrates.
- Comparative anatomical studies help us to understand how the major transitions in vertebrate design might have occurred. Soft tissues do not fossilize, meaning that (with rare exceptions) only transformations of the hard parts of the vertebrate body are preserved in the fossil record. For other parts of the body, we must rely on a sequence of living forms. There are problems with this approach, but if we begin with a robust phylogenetic hypothesis and keep in mind that the living members of some groups are highly derived, then we may be confident in this method as a reasonable approach for deducing the major steps in the evolution of different vertebrate groups.

We will consider all of these aspects in the following course on comparative vertebrate anatomy. Before beginning this study, however, there are several important terms that unambiguously describe position and direction. These indispensable terms greatly facilitate

navigating through the complex three-dimensional structure of vertebrate bodies.

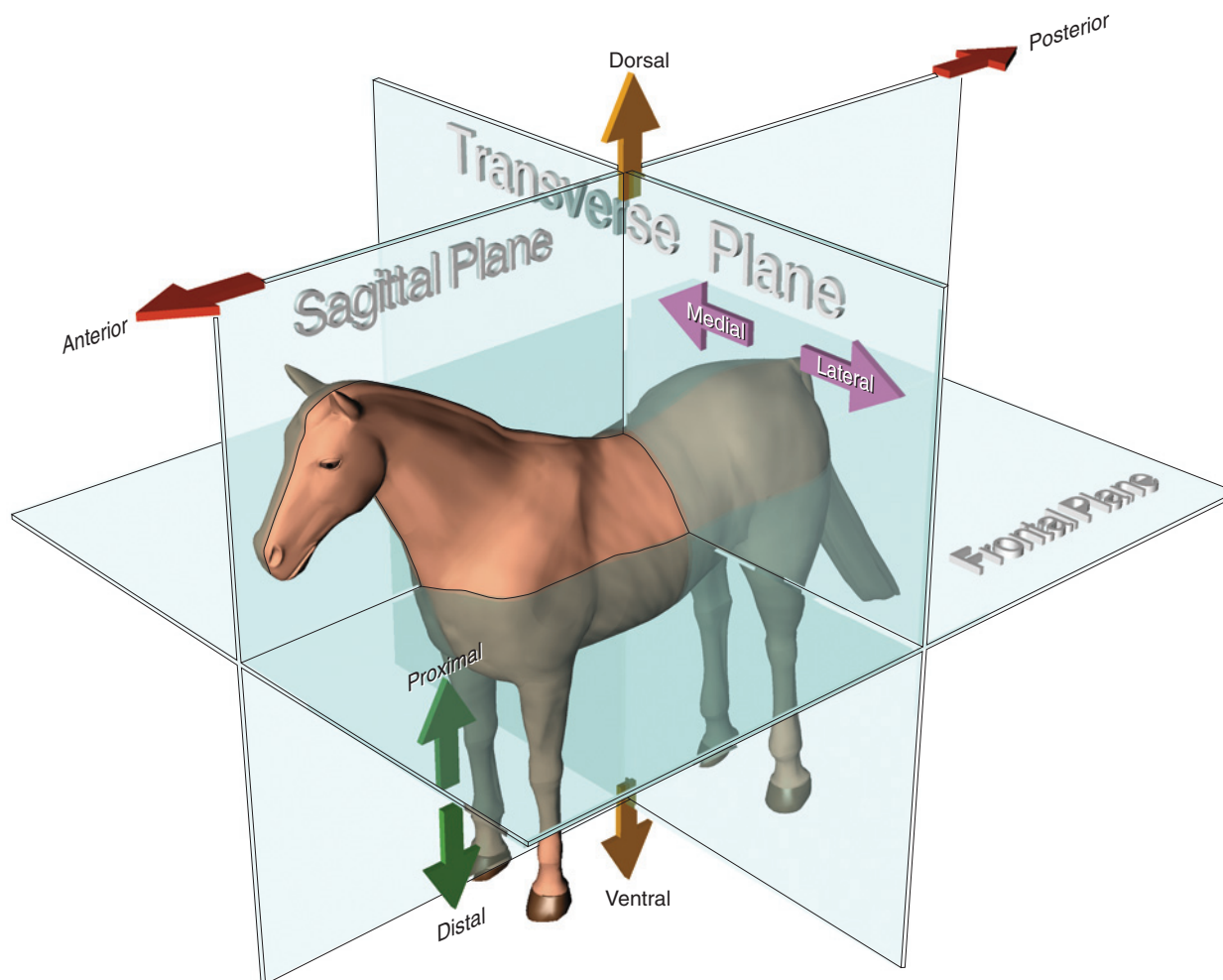
## DIRECTIONAL TERMINOLOGY AND PLANES OF SECTION

As with all advanced fields of research, anatomical study requires the use of specialized terminology. Such terminology includes not only special words for the anatomical structures themselves and concepts or processes (such as homology, for example) but also terms to designate unambiguously the orientation and direction of structures of the vertebrate body. These terms may at first seem superfluous, but that is because most people have never dealt with anatomy in a comprehensive and detailed manner. It is perfectly adequate in everyday life to say that the stomach is lower than the heart or the appendix is in the lower right part of the belly. But this is not anatomy. You will quickly come to realize the importance of the terms presented in this section, and you are urged to learn and become familiar with them.

There are two main sets of terms. One is used in medicine and by some anthropologists, the other by comparative anatomists, paleontologists, and veterinarians. To compound the problem, various synonyms exist for some terms in each set. These circumstances may be cause for confusion, but we may simplify matters by adhering to one set of terms. As we are studying comparative anatomy, we will use the system commonly used for nonhuman vertebrates.

Unlike humans, the vast majority of vertebrates go through life with the long axis of the body oriented horizontally or parallel to the substrate. It is with reference to this position that the main directional terms are defined. Most of these terms are coupled; that is, there are two terms that describe opposite directions along a single axis. Refer to Figure 1 while reading through the





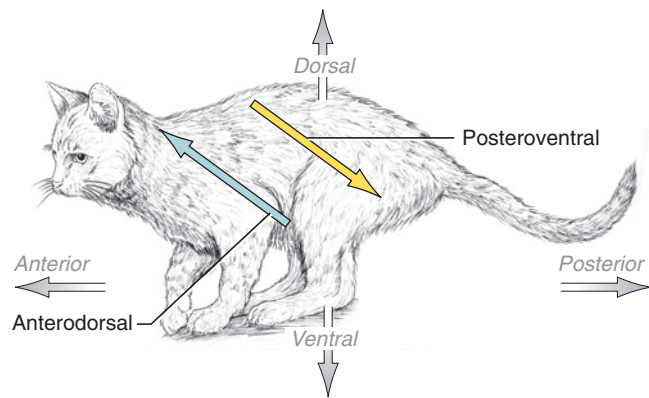
**FIGURE 1** Directional terms and main planes or sections through the body shown on a horse.

following explanations. **Anterior** and **posterior** refer to the horizontal longitudinal axis and respectively designate the directions toward the head and tail. Synonyms for these terms that you may encounter are *cranial* or *rostral* for anterior, and *caudal* for posterior. The vertical direction toward the belly or the ground is **ventral**; toward the back or up is **dorsal**. **Medial** refers to the horizontal direction toward the sagittal midline (see below) of the body, whereas **lateral** refers to the directions away from the midline. These are the main terms, but there is another set that is useful. **Proximal** and **distal** are terms usually used with a particular reference. At times this reference may be the trunk of the body; at other times a particular structure, such as the heart, may be the reference point. Proximal designates a position closer to the trunk or structure of reference, and distal furthest from the trunk or structure of reference. Thus, for example, the fingers (phalanges) are distal to the upper arm (brachium); and the proximal end of the brachium is that end closest to the trunk. If the reference point is another structure, say the heart, then the

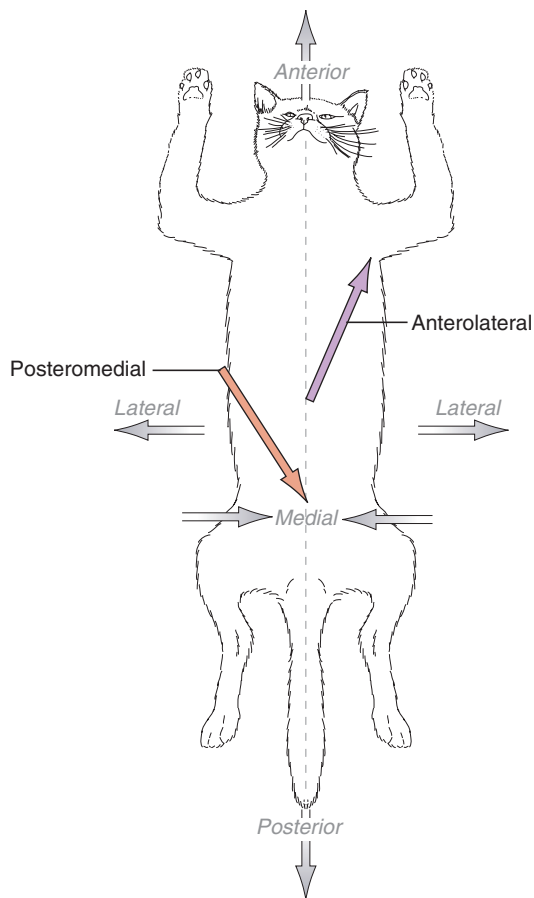
proximal part of a blood vessel is the part closest to the heart, and the distal end is that part furthest away.

Combinations of these terms may be used, and indeed are used often in this manual, to describe directions that are oblique to the main axes. For example, anterolateral combines anterior and lateral, and indicates a simultaneous direction toward the head and to the side. Thus, taking the umbilicus (navel or bellybutton) as a reference, we may describe the shoulder as anterolateral to the umbilicus. Figure 2 provides examples of these terms.

Dissection often involves cutting the body in various planes to obtain internal or sectional views, which are extremely useful for comprehending the spatial arrangement of structures. There are three main sections or planes that pass through the body (Figure 1). The **sagittal** section is vertical and lies in the midline longitudinal of the body. It separates the body into right and left halves. Sections that are parallel to and on one side of



(a)



(b)

**FIGURE 2 (a, b)** Combined directional terms shown on a cat.

the sagittal plane are termed **parasagittal**. A second major section is in the transverse plane, which is also vertical but is perpendicular to the sagittal plane. A **transverse** section cuts across the main longitudinal axis and subdivides the body into anterior and posterior parts. The last major section is in the frontal plane, which is horizontal and perpendicular to the sagittal and transverse planes. A **frontal** section separates the body into dorsal and ventral parts.

### KEY TERMS: INTRODUCTION

anterior (cranial,  
rostral)

distal

dorsal

frontal

lateral

medial

parasagittal

posterior

proximal

sagittal

transverse

ventral



# CHAPTER 1

## THE CRANIATA AND VERTEBRATA

The vertebrates or Vertebrata (see below) form an ancient group with a history spanning some 545 million years. On the one hand, they include the organisms most familiar to us, such as fish, birds, cats and dogs, as well as other humans; on the other, few people are aware of the great diversity in their form, structure, and habits. Indeed, they include some of the largest and more complex organisms ever evolved. But vertebrates are part of a larger grouping of animals, and to understand their history and the development of their structure, they must be placed in phylogenetic context.

In discussing vertebrates, several other groups of organisms are usually considered. A group of organisms is referred to as a *taxon* (plur., *taxa*). The taxa related to vertebrates include the Echinodermata (sand dollars, sea lilies, starfish, sea cucumbers, urchins), Hemichordata (acorn worms and pterobranchs), Urochordata (tunicates or sea squirts), and Cephalochordata (amphioxus). These are the typical nonvertebrate (or “invertebrate”) relatives of the group we are mainly interested in. The vertebrates themselves, or Vertebrata, are included in a larger taxon termed the Craniata. Within the Craniata and Vertebrata are many taxa. These taxa and the relationships among them (see Figure 1.1) are briefly outlined below to provide an organizational framework for undertaking the dissection of the vertebrates discussed in this manual. Before this, however, it is necessary to present an explanation of several important terms used in discussions of phylogeny.

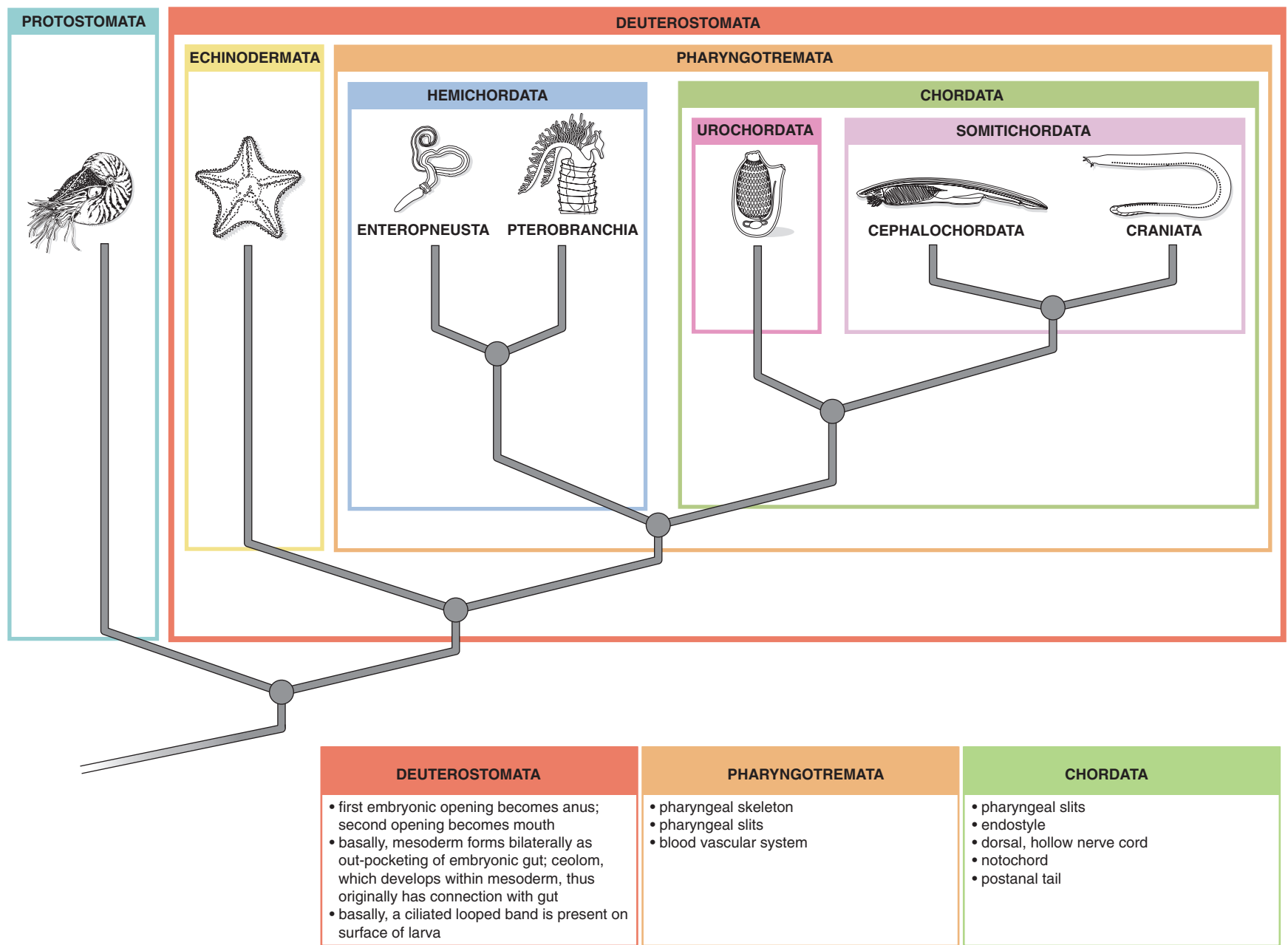
### PHYLOGENY AND CLASSIFICATION

For most of the past 250 years, the classification of organisms has followed the Linnean system, which uses ranks to designate levels of organization of the organisms being classified. Most readers will be familiar with the main formal Linnean ranks, ordered hierarchically from most to least inclusive: Kingdom, Phylum, Class, Order, Family, Genus, and Species. Researchers have differed in assigning rank to the vertebrates and their relatives. For example, some authors have recognized three phyla: Phylum Echinodermata, Phylum Hemichordata, and Phylum Chordata. Others consider the

Urochordata and Cephalochordata as phyla on their own, separate from the Chordata. Still others have viewed the Urochordata as a separate phylum, but the Cephalochordata as a subphylum of the Phylum Chordata. If you find this confusing, you’re not alone! The different designations did—or at any rate were meant to—have some grounding in biological reality. They reflected a particular researcher’s perception of the magnitude of the difference in the levels of organization (a quality that may be referred to as a *grade*) among the taxa under consideration. Thus, if a taxon was considered a phylum, it mainly implied that its members made their living in a very different way than if they were considered only a subphylum of a larger taxon. As you have probably already realized, researchers’ perceptions along these lines are subjective.

In recent years, however, the formal Linnean ranking system has fallen increasingly into disuse as systematists have become aware that there is no intrinsic or “special” value of any particular taxon that would justify its recognition as a higher or lower rank, compared to other taxa. In other words, there is no special reason for “elevating” birds or Aves to the rank of Class, equal and thereby excluded from, the Class Reptilia. In fact, it is improper to do so, because the birds are properly part of the taxon named Reptilia. Here, formal ranks are not used, and taxa are referred to simply by their name.

Formal names are applied to natural or monophyletic groups. A monophyletic group includes an ancestor and all of its descendants (provided that the phylogeny has been carefully reconstructed). Such groups are termed *clades*. Clades are recognized based on common ancestry. If two taxa are in a clade, it is because they are linked by a common ancestor. Biologists infer such ancestral relationships through the presence of shared derived characters or synapomorphies (see below). If two (or more) taxa share a character that is exclusive to them, then we assume that they share this feature because they have inherited it from a common ancestor, rather than each having evolved the character independently, and so infer that the taxa are descendants of the same ancestor (which we are not able to actually recognize, and thus refer to as *hypothetical*). This, of



**FIGURE 1.1** Cladogram showing phylogeny of the Deuterostomata. Some synapomorphies of the main groups are provided in the boxes below the cladogram.

course, is the idealized situation. In reality, biologists use many characters in trying to reconstruct phylogeny. The practice is complicated by the fact that organisms can and do evolve very similar characters independently of each other, an occurrence referred to as *homoplasy*. In reconstructing phylogeny, a researcher considers the totality of evidence. It is rare that only a single character can be used to reconstruct phylogeny.

The pattern of relationships among taxa is depicted visually by a *cladogram*, which is essentially a diagram of nodes and branches, with the nodes representing ancestors and the branches that diverge from a node representing the descendant taxa of the ancestor. The node, then, may be thought of as representing the hypothetical ancestor of the two taxa that diverge from it. The pattern of branching represents the pattern of relationship. Examine the cladogram in Figure 1.1. Note the node from which the Hemichordata and Chordata diverge. This node represents the ancestor species that split to produce two lineages, one that evolved into the Chordata and the other into the Hemichordata. The two branches that diverge from this ancestor represent the evolutionary paths to the divergent taxa.

Only the branching pattern is of concern. The length of the branches is immaterial in terms of absolute time, but relative time is implied by branching sequence. Clearly, the divergence of the Cephalochordata and Craniata occurred after the divergence of the Hemichordata and Somitichordata.

Informal names, set between quotation marks, are used to designate a group of organisms that do not descend from the same common ancestor but that do possess (or lack) some of the features of the taxon in which we are interested. Many of these terms were considered formal names in earlier classifications. For example, the term “*protochordates*” is commonly used to refer to the hemichordates, urochordates, and cephalochordates. Grouping them together is a shorthand way of referring to them as close relatives of chordates (no quotation marks here, so this is the vernacular form of the formal name Chordata), and that they lack various characters that chordates possess. We must be clear that informal groups, though convenient, do not reflect phylogeny; they are not monophyletic.

In discussing how biologists reconstruct phylogeny, the nature of the similarity among organisms must be considered, because it is necessary to differentiate between those similarities that are useful in reconstructing phylogeny and those that are not. One kind, termed *plesiomorphic*, refers to similarity based on the presence of primitive or ancestral conditions or states. Consider the Vertebrata, in which the presence of vertebrae is an ancestral feature—in other words, it was present in the

common ancestor of all vertebrates. These structures may inform us that all vertebrates share a common ancestor, but their presence per se cannot be used to decipher the relationships *among* vertebrates. As a practical example, let us consider a turtle, a bird, and a mammal. All possess vertebrae, and are therefore vertebrates, but the presence of these structures does not allow us to say which two of these forms are more closely related to each other than either would be to the third. This similarity, therefore, is due to the retention of a trait that is ancestral for vertebrates. When an ancestral character is shared by various forms, it is described as *symplesiomorphic*.

A second kind of similarity is due to the inheritance of a *modified* character state. Such modification is considered derived or *apomorphic*. When organisms share a derived trait, it is described as *synapomorphic*. Synapomorphies do indicate phylogenetic relationship. In the most basic sense, sharing a derived trait is a shorthand way of saying that the organisms under consideration possess a modified trait because it was inherited from an ancestor that first acquired or evolved the modification. An assortment of organisms united by synapomorphies forms a natural group or clade; that is, the clade is a real entity in evolutionary terms. It means that all the organisms included within the clade were ultimately derived from the same ancestor. All vertebrates that possess jaws do so because this character was inherited from an ancestor that had evolved jaws as a modification of the mandibular arch (see below). If we wish to understand the relationships among a lamprey, a fish, and a dog, the presence of jaws is a character state that indicates that the dog and fish are more closely related to each other than either is to a lamprey. When two groups are each other's closest relatives, they are said to be *sister groups*.

A natural or *monophyletic* group may be recognized formally by a name. The only restriction imposed is that a monophyletic group include the ancestor and all descendants of the ancestor, even though the latter cannot be identified. A monophyletic group may also be termed a clade, from which is derived the alternate term *cladistics* for phylogenetic systematics. Cladistics is the methodology that recognizes shared derived traits as the only valid indicators for inferring phylogenetic relationships.

The third type of similarity is termed *homoplastic* and results from morphologically similar solutions to particular selection pressures. For example, the fusiform body shape of fishes and of dolphins, which are mammals, is not due to inheritance from a common ancestor, but to selection pressure to adopt a form suitable for moving efficiently through water. Such similarity does not indicate phylogenetic relationship, although in some cases the similarity may be so profound that it may lead us inaccurately to infer a relationship.



rately to attribute its cause to phylogenetic proximity. The reliable method of recognizing homoplasy is to identify it as similarity in different monophyletic groups, following, of course, a phylogenetic analysis.

In addition to clades or monophyletic groups, we may speak of *grades*, which are not natural groups. A grade recognizes a group of organisms based on a shared level of organization or complexity. A new grade may be achieved through the accumulation of a number of derived characters so that a new “mode of living” is made possible. In the past, some groups were formally recognized, but they were united essentially because their members shared a particular grade of evolution. We now recognize such groups as artificial rather than natural.

Probably the most familiar example is the case of the Reptilia. Formerly the Reptilia included living and fossil crocodiles, turtles, snakes, and lizards, as well as their extinct relatives, such as dinosaurs, pterosaurs, and plesiosaurs. The Class Reptilia was given a rank equivalent to that of the Aves (birds) and Mammalia (mammals), even though the ancestors (and early relatives) of these two groups were considered reptiles. As so defined, however, the Reptilia is not a natural group because it does not include all of its descendants, as the birds and mammals are excluded and each belong to a group of equal rank. Current usage of Reptilia varies. As its traditional concept is so embedded in our thinking, some authors have preferred to abandon it entirely for formal purposes but retain it in its colloquial sense. In this latter meaning, *reptile* represents a grade that includes cold-blooded amniote tetrapods or land-dwelling vertebrates, with scales (lacking hair or feathers); that is, the features we usually associate with living reptiles such as crocodiles, snakes, and lizards. Other authors redefine Reptilia as a formal group that includes the typical reptiles and birds. The more primitive fossil allies of the mammals, termed *mammal-like reptiles*, are excluded from the Reptilia and properly united with their mammalian descendants in the Synapsida.

The discussion given here provides the basic background information required to interpret cladograms and how they are constructed. For more detailed discussions on cladistics and classification, consult a text in comparative anatomy that provides more detailed explanations of these concepts. Liem et al. (2002) provide a particularly thorough discussion.

## VERTEBRATE RELATIVES

All the taxa mentioned so far belong to the Deuterostomata, a major clade of coelomate triploblastic metazoans, multicellular animals that possess three primary body layers (ectoderm, mesoderm, and endoderm) and

have a true body cavity that houses the viscera. The other major clade is the Protostomata, which includes annelids, arthropods, mollusks, and various other smaller groups.

The synapomorphies (shared derived characters) of deuterostomes, at least among basal members, that indicate they are a clade are mainly similarities of early embryonic development. They include type of cleavage of the fertilized egg, pattern of mouth and anus formation, and formation of the mesoderm and coelom (body cavity). The clades within the Deuterostomata share these features, but several of them have become modified in some advanced members.

Next, we must consider the pattern of relationships, or *phylogeny*, among deuterostomes. For the most part, the phylogeny outlined here follows the traditionally recognized scheme based primarily on morphology. Be aware, however, that several recent analyses based mainly on mitochondrial or ribosomal gene sequences do not corroborate this scheme. Such discrepancies are noted appropriately below.

To review, the main clades of deuterostomes are the echinoderms, hemichordates, urochordates, cephalochordates, and craniates (Figure 1.1). It may seem surprising that the echinoderms, seemingly so different from what we usually think of as vertebrates, are closely related to vertebrates and included with them in the Deuterostomata. As noted above, however, they are clearly united by strong similarities in early developmental patterns.

One group traditionally considered important in vertebrate history is the Chordata, which includes the Urochordata, Cephalochordata, and Craniata. One reason the Chordata has been considered particularly important is that there are several easily recognizable characters that are clearly shared by chordates. Without belaboring the point, such distinctions as “important” or “major” often imply a status that may not be justified. There is no real reason why the chordates should be considered more “important” than the next most inclusive group, for example. It is more a matter of convenience and tradition and, perhaps, that we have only recently begun to fully comprehend that all branches in the tree of life may be considered equally important.

At any rate, beginning with the Chordata is convenient. The chordates are united by the presence of the following synapomorphies: pharyngeal slits; an endostyle; a dorsal, hollow nerve cord; a notochord; and a postanal tail. These features are present at some point during the lives of all chordates, although they may be expressed to varying degrees and restricted to part of the life cycle in different vertebrate groups, or modified in advanced

members. Humans, for example, do not possess a tail, notochord, or pharyngeal slits, but pharyngeal pouches, a notochord, and a tail are transient features that are present during embryonic development. The endostyle is represented by its homologue, the thyroid gland.

Pharyngeal slits are bilateral apertures that connect the pharynx (essentially the “neck” of the animal), which is the anterior part of the gut, with the outside. In forms that are familiar to us, such as fish, the slits are part of the respiratory system: The gills reside in the walls of the slits and perform gaseous exchange as water passes over them. In some fishes, like sharks, the slits open individually onto the surface of the body; in most other fishes, the slits open into a common chamber that then leads out to the surface of the body by a common opening. Originally the slits did not function in respiration. Ancestral vertebrates were suspension or filter feeders (as are urochordates and cephalochordates still), and the slits were the means for allowing water to exit the oral cavity and pharynx. As water passed out of the pharynx through the slits, food particles were filtered out and directed toward the digestive system. The endostyle, a midventral groove (on the floor of the pharynx), has ciliated cells that secrete mucus, which is spread around the walls of the pharynx. Food particles suspended in the water are trapped by the mucus, and the water then leaves the pharynx through the slits. The mucus and entrapped food particles are then passed back into the digestive system. The slits and endostyle were thus originally part of the feeding mechanism.

The notochord is a relatively thin rod-like structure running dorsally along the length of the trunk and tail in less derived chordates. It is an important support structure, and the name Chordata is derived from notochord. It is a hydrostatic structure, consisting of a fibrous sheath that encloses a fluid-filled central core. It is flexible along its length, but, as it is filled with fluid, cannot easily be compressed anteroposteriorly (or telescoped). The notochord provides support for the body and allows the side-to-side locomotory movements characteristic of primitive vertebrates. In advanced vertebrates, the notochord is largely replaced functionally by the bone of the spinal column. It is present embryologically, and in adult humans, notochordal tissue may persist as part of the intervertebral disks that lie between adjacent vertebrae.

The presence of a tubular nerve cord enclosing a fluid-filled central canal occurs only in chordates. There are additional distinctive features about the chordate nerve cord. It is formed by an embryological process called *invagination*, a rolling and sinking into the body of ectodermal tissue. Further, it is dorsal to the digestive tract, whereas in most nonchordates the nerve cord is solid and ventral in position.

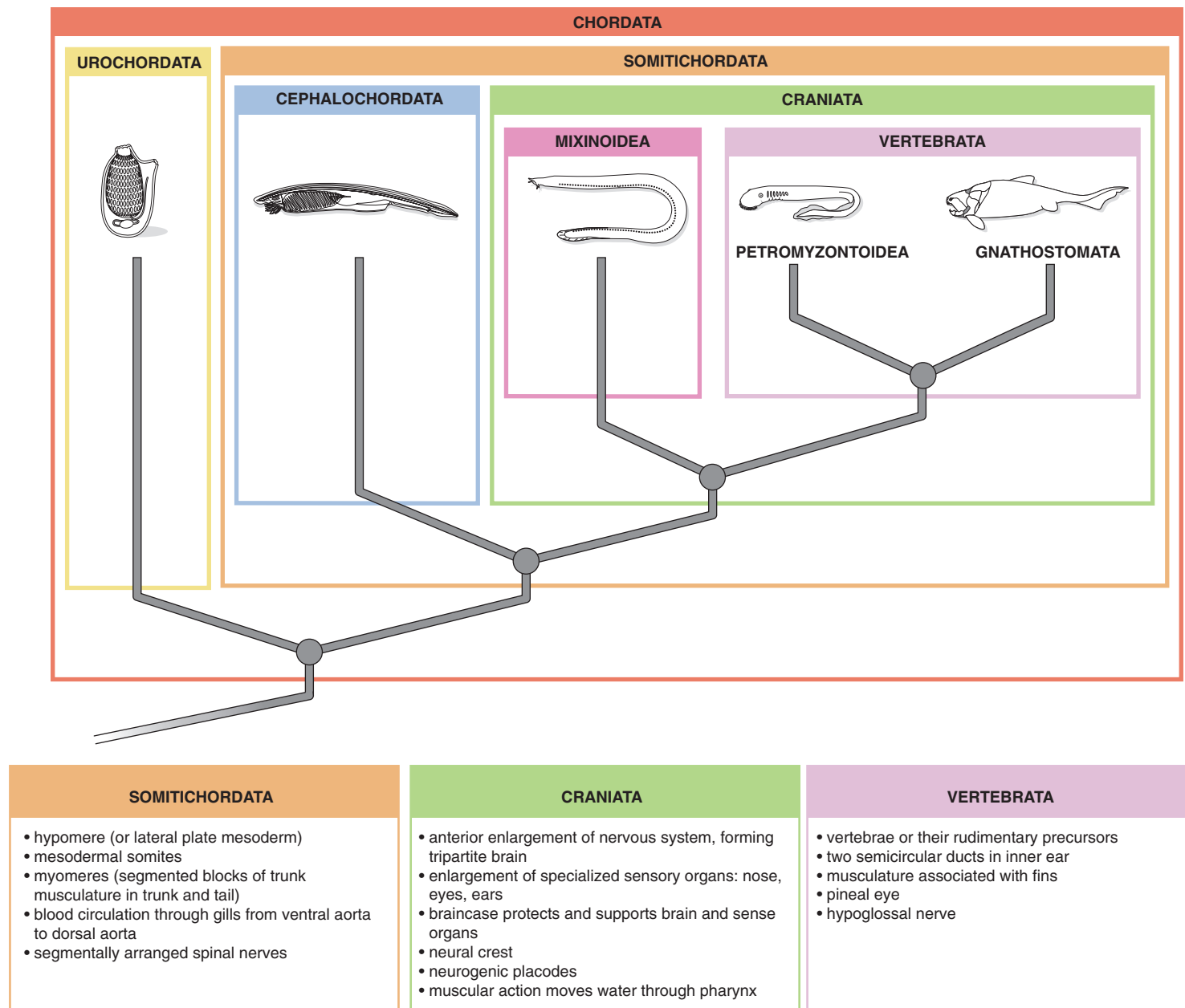
The postanal tail is a continuation past the anus of the trunk musculature and notochord. This extension is an important development that allows the locomotion particular to vertebrates. Many chordates do not possess a postanal tail as adults, humans being an obvious example. However, a tail is present in nearly all chordate larvae.

The Cephalochordata is usually considered the sister group to the craniates, a phylogenetic arrangement reflecting the idea that vertebrates and cephalochordates share a common ancestor. All five chordate characters are clearly present during the life of a cephalochordate. The name Cephalochordata is derived from the presence of a notochord extending from the tail nearly to the tip of the head (from the ancient Greek *kephalos*, head). The commonly studied cephalochordate is *Branchiostoma*. Cephalochordate species commonly are referred to as *amphioxus* (which means sharp at both ends) or *lancelet* (little spear). Given the fact that these little creatures essentially lack a head and so are pointed at both ends, amphioxus is an especially appropriate designation. Although amphioxus has a fish-like body (see below), it is not an active swimmer as an adult. Instead, it burrows into the substrate, usually just out from sandy beaches, and assumes a position with only its mouth exposed. Its filter-feeding lifestyle is similar to that described above for ancestral vertebrates. Intake of water and its movement through the pharynx is accomplished by ciliary action. The pharynx has numerous slits that collectively empty into a surrounding chamber, the atrium, before leaving the body through a common opening. The endostyle secretes mucus, which traps food particles suspended in the water.

The taxon including the Cephalochordata and Craniata is termed the Somitichordata (Figures 1.1, 1.2). Although there are several differences between these sister groups, we are interested in their synapomorphies, for these features provide evidence of their shared ancestry. Among these characters are similarity in development of mesoderm, including the hypomere (or lateral plate mesoderm) and mesodermal somites, which develop into myomeres (segmented blocks of trunk musculature, which in amphioxus extends through to the anterior tip of the body); arrangement of the circulatory system, with dorsal and ventral aortae; and segmentally arranged spinal nerves. Some researchers also recognize the retention of larval features—the notochord, the nerve cord, and the postanal tail—as synapomorphies. Others, however, consider these retention of ancestral features rather than a novel development, and that the loss of these features in the Urochordata, the sister group of the somitichordates (see below), is derived.

The Urochordates are the next most related group, sharing a common ancestor with the Somitichordata.





**FIGURE 1.2** Cladogram showing phylogeny of the Chordata. Some synapomorphies of the main groups are provided in the boxes below the cladogram.

Urochordates are characterized by sea squirts or tunicates, which are sessile, sac-like organisms as adults. In the larval stage, however, all five chordate characters are present. Predictably, the three characters lost in adults—the tail, notochord, and nerve cord—are used in locomotion by the free-swimming larva as it searches for a suitable place to anchor itself to metamorphose into the adult form. During this transformation, the tail is absorbed, along with the nerve cord and notochord, of which only small remnants remain in the adult. The name Urochordata is derived from the fact that the notochord is present in the tail (from the ancient Greek *uron*, tail). Conversely, the pharyngeal region expands dramatically into a barrel-shaped structure with numerous slits. Water and suspended food particles are drawn into this “barrel,” which is lined with mucus from the endostyle. Food particles are trapped by the mucus, and water leaves through the slits into the atrium, the chamber surrounding the pharynx.

This arrangement is the more commonly accepted phylogenetic scheme. Some, however, reverse the positions of the Urochordata and Cephalochordata, with the former considered the sister group to the Craniata. One recent study removed cephalochordates from chordata, and considered them as a sister group to the Echinodermata. Compare, for example, Beaster-Jones et al. (2006) with Delsuc et al. (2006).

The phylogenetic position of the Hemichordata is particularly uncertain. They were traditionally grouped with the chordates, as is done here, but this arrangement is far from stable. Molecular evidence has been mounting over the last decade that points to a monophyletic relationship of hemichordates with echinoderms; as well, morphological evidence suggests monophyly. Hemichordates comprise two clades, the Enteropneusta (acorn worms) and the Pterobranchia, both of which are marine animals. The acorn worms are reasonably diversified and well known, but the pterobranchs are not as well understood. Some but not all pterobranchs have a single pair of pharyngeal apertures, whereas all acorn worms have several such openings. The presence of these slits and embryonic invagination of the nerve cord are about the only definitive evidence of a relationship with the chordates. On the other hand, evidence suggests that echinoderms originally had slits as well, although no living echinoderm possesses them. If this is true, then a monophyletic relationship between Hemichordata and Chordata becomes tenuous indeed.

## CRANIATES AND VERTEBRATES

Difference of opinion exists in precisely which chordates are to be regarded formally as Vertebrata (Figure 1.2). In part this is because one of the main characters of ver-

tebrates is, of course, the presence of vertebrae, a repeating series of articulating cartilaginous or bony elements forming the spinal column, which provides support for the body, muscular attachment, and protection for the nerve or spinal cord. Vertebrae form around the notochord during embryonic development and enclose the spinal cord.

However, not all chordates traditionally included in the Vertebrata have complete vertebrae, as just noted above; and some have no trace of vertebrae at all. In large part, which chordates are actually recognized as vertebrates depends largely on the relationships of the most basal or primitive living vertebrates, the hagfishes (Myxinoidea) and lampreys (Petromyzontoidea), both to each other and to unquestioned vertebrates. The hagfishes and lampreys are clearly more advanced than cephalochordates, sharing various characteristics with unquestioned vertebrates (see below). However, they are undoubtedly less derived than the latter in the absence of jaws, the feature to which they owe their designation as “agnathans” (from the ancient Greek *a-*, without; and *gnathos*, jaw). Their mouths are circular, so they are also known as “cyclostomes” (round mouth). The undoubted vertebrates, united by the fact that they possess jaws, are grouped together as the Gnathostomata (jaw-mouthed). Traditionally, the hagfish and lamprey were considered to be each other’s closest relative, and so grouped in the “Cyclostomata” as a formal taxon. As well, several groups of jawless extinct forms were considered more closely related to cyclostomes than to gnathostomes, and the whole lot of these jawless forms were included in the “Agnatha,” again, as a formal taxon. At this stage of research, the “cyclostomes” (and other “agnathans”) were usually all included in the Vertebrata.

“Agnathans” diversified into many different forms early in craniate history, but only two forms, the hagfish mentioned above and the lamprey, represent the jawless condition among living craniates. Many of the early agnathans were excessively bony, but most of this bone was dermal and formed shields or plates that covered and protected the body. These forms are informally termed “ostracoderms,” and are not considered in the phylogenies presented here.

About 20 years ago, morphological analyses began to suggest that lampreys (and some extinct “agnathans”) are more closely related to gnathostomes than to hagfishes. Following cladistic procedure, the lampreys were then grouped together with the gnathostomes. Because lampreys possess rudimentary vertebrae (or, at least, precursors of true vertebrae), termed *arcualia*, which are essentially cartilaginous blocks on either side of the spinal cord, most researchers began to restrict the Vertebrata to the lamprey + gnathostome assemblage, with

the hagfishes considered the sister group to this Vertebrata. An important set of features shared by both hagfishes and Vertebrata (lampreys + gnathostomes) is the development of a true head (see below), and so the term Craniata was applied to this clade. We note in passing that some researchers have continued to consider the Vertebrata as including the hagfishes (while recognizing the sister group relationship between lampreys and gnathostomes), and so consider Craniata and Vertebrata as synonyms. Most recently, however, molecular studies have not corroborated the morphological evidence. Instead, these studies suggest that the hagfishes and lampreys may indeed be each other's closest relative, in which case the "Cyclostomata" would be monophyletic. The scheme followed here is based mainly on morphological evidence and recognizes the Craniata and Vertebrata as successive clades (Figure 1.2).

As noted above, a major feature of craniates is the development of a "true" head. A distinct anterior enlargement of the nervous system, forming a brain, and of sensory organs occurs in craniates. The brain of craniates is tripartite, with three main primary subdivisions; and the specialized sense organs—eyes, ears, and nose—are complex. These structures are protected and supported by a bony or cartilaginous cranium or braincase. Closely associated with a head is the neural crest, a unique feature of craniates. This comprises embryonic tissue formed of cells assembled near the developing neural tube that migrate through the embryo to give rise to a great variety of structures. In the head region, neural crest cells initiate and largely form the vast array of cranial structures characteristic of craniates. Another unique feature associated with the head are neurogenic placodes. Placodes are thickenings of the ectoderm occurring early in embryonic development that differentiate and help form a variety of structures of the body. Neurogenic placodes occur only on the head and are involved in forming sensory receptors and neurons, and contribute to the cranial nerves. Thus, the presence of the neural crest and neurogenic placodes, transitory though they may be, are distinguishing features of craniates. Pharyngeal slits are still present, of course, but in craniates they are associated with gills and are thus used for respiration rather than feeding. Yet another innovation of craniates is that moving water into the pharynx and out through the pharyngeal slits is accomplished by muscular, rather than ciliary, action (see Figure 1.2).

## EARLY STAGES IN THE EVOLUTION OF VERTEBRATES

Before continuing with the phylogenetic story of vertebrates, it is useful to examine the feeding habits of the earliest vertebrates, as evolutionary innovations of the feeding apparatus reflect the major transitions in verte-

brate evolution. It is generally hypothesized that the earliest step in becoming a vertebrate occurred in creatures considered to represent a prevertebrate stage, although such forms may have qualified as true vertebrates. Their precise phylogenetic position, in any event, is not of concern here, because we are interested in feeding mode. The prevertebrate was probably a suspension or filter feeder (that is, it filtered food material that was suspended in water) and used ciliary action to generate a current of water into its mouth and out of the pharyngeal slits; in other words, a creature very much like amphioxus. It did not have jaws, and its pharyngeal bars were probably collagenous. The ciliary pump imposed limits on size, as it restricted the amount and type of food the animal was capable of ingesting.

The next step involved a change from the ciliary pump with collagenous bars to a muscular pump with cartilaginous bars. This is the agnathan stage. The combination of these characteristics meant that the intake of water, and thus food, was controlled by active expansion and compression of the pharyngeal region, which allowed a diversification in size and type of food, and thus of the vertebrates themselves. The cartilaginous, rather than collagenous, bars were instrumental in this. Musculature could be used to compress the pharynx, including the bars, but once the muscles relaxed, the cartilaginous bars could spring back into shape, expanding the pharynx.

The third level of development is the gnathostome stage, which involved the development of jaws. Jaws conferred the ability to grasp prey and close the mouth to prevent its escape; hence, to seek and capture food. These features set the stage for the predaceous, active lifestyle of vertebrates, in sharp contrast to the sedentary lifestyles of protochordates.

## VERTEBRATA

As noted above, the lampreys, or Petromyzontoidea, represent the most basal living vertebrates. Several important synapomorphies mark this group. All vertebrates have at least two semicircular ducts in the inner ear, structures concerned with improving balance and position of the organism (the single duct in hagfishes possibly represents a secondary simplification of the two present in vertebrates, rather than being the primitive condition). Also, vertebrates have musculature associated with the fins, allowing better control of the fins and thus of their locomotion through water.

Several extinct early vertebrates have extensive fossil records, and were clearly the dominant forms during early vertebrate history. Several of these groups are rec-

ognized as being more closely related to more derived vertebrates. One particularly interesting group are the conodonts, which for nearly 200 years were considered as “invertebrates.” Recent fossil evidence clearly indicates that not only are they vertebrates, but according to some authors, they are more derived than lampreys. Several other extinct groups possessed excessive dermal bone arranged as protective broad plates or shields, particularly around the head, and so are termed “*ostracoderms*.” These, mentioned only in passing here and excluded from Figure 1.2, include Heterostraci, Anaspida, Osteostraci, and various others. A textbook will provide further discussion of their anatomy and phylogenetic relationships.

The remaining vertebrates form the clade Gnathostomata (Figure 1.3; ancient Greek, *gnathos*, jaw, and *stoma*, mouth). As their name implies, gnathostomes have jaws, structures that are modifications of an anterior or mandibular pharyngeal arch (see below). Their development was a significant evolutionary advancement, perhaps the most important in vertebrate history, because jaws controlled by muscles allow animals to grasp objects firmly. The development of teeth confer a more certain hold and further allow the reduction of food to smaller pieces. These abilities allowed the exploitation of many feeding opportunities. A second innovation was necessary before vertebrates could fully exploit potential new food sources, because the mouth, hence body, must be guided toward an object. The control of the body in three dimensions is allowed by the presence of paired fins with internal skeletal and muscular support that permitted control of the body in locomotion. A horizontal semicircular duct is added, so gnathostomes have three semicircular ducts. Other synapomorphies include the presence of five pharyngeal slits and jointed visceral arches. In gnathostomes, the arches are embedded deep in the body, adjacent to the pharyngeal wall, whereas in “agnathans,” they are not articulated structures and lie superficially, just beneath the skin toward the outside of the body. The traditional hypothesis on jaw origins considers jaws as an anterior visceral arch (located close to the original mouth) that was modified to form upper and lower jaws. This arch is termed the *mandibular arch*.

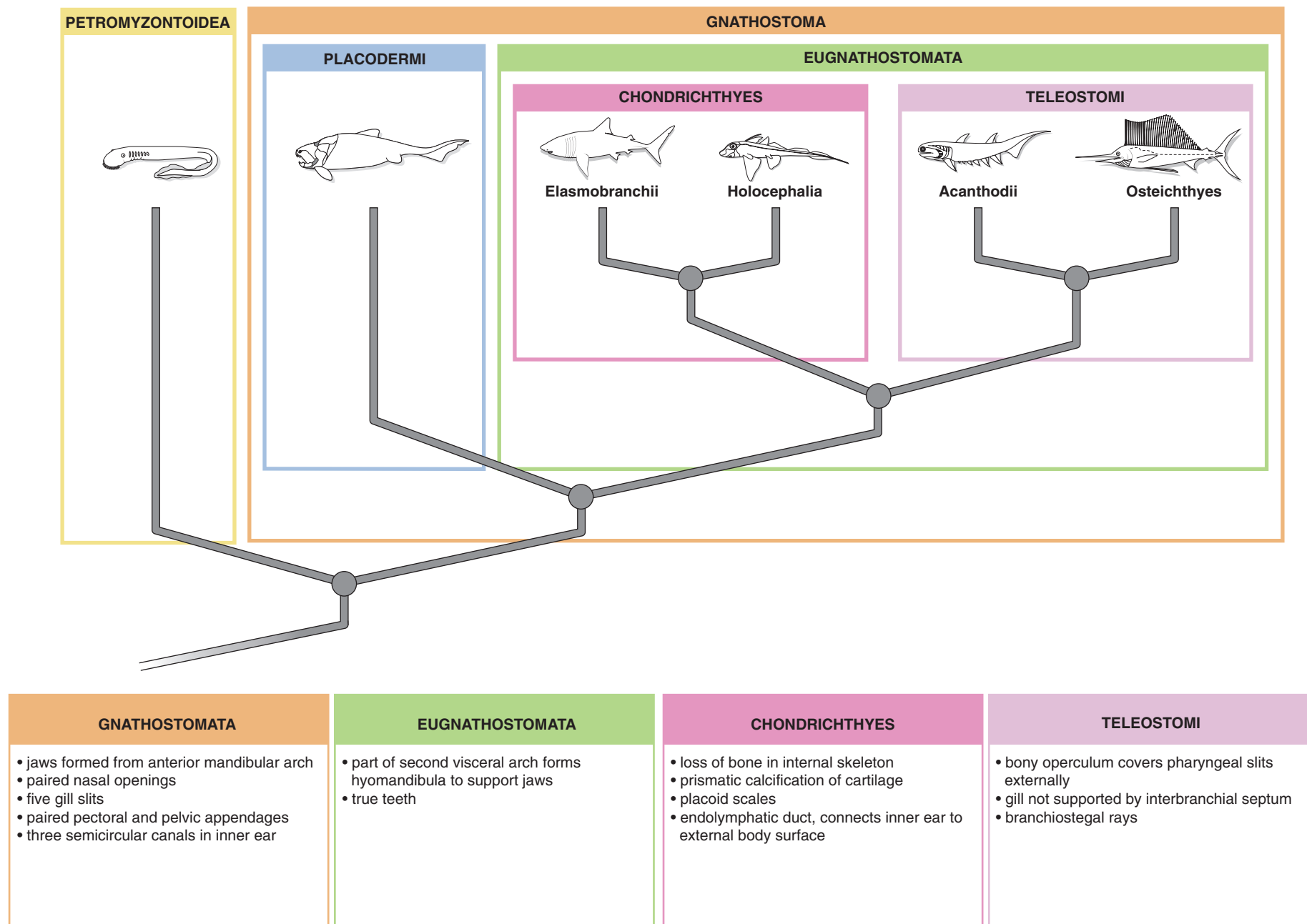
The familiar group of vertebrates that possess these features, at least initially, are the fishes, which are also the earliest and in many ways among the most primitive gnathostomes. Most people know what a fish is, but few recognize that not all fishes are the same with respect to their relationships to other vertebrates. Although they were once all included as “Pisces,” they do not form a natural group because some possess features that indicate a common ancestry with tetrapods. Therefore, if “Pisces” were to be retained as a formal term, then the tetrapods would have to be included in the taxon, but

it would then be equivalent to Gnathostomata (however, see below).

Fish, by and large, all have a similar way of getting on in the world, and it should thus be clear that our everyday concept of fish represents a grade rather than a clade. That they are fish conveys the general idea that locomotion is accomplished essentially through lateral undulations of the trunk and tail with guidance supplied by paired pectoral and pelvic fins; gas exchange occurs primarily through gills located in the walls of pharyngeal slits; the heart is a simple, tubular, single-barrelled pump; and so on. However, as some fish are more closely related to other types of vertebrates, including birds and mammals, our classification must reflect this.

The most primitive fishes are the extinct Placodermi. Placoderms (from the ancient Greek *placo*, plate, and *derma*, skin) had several large plates covering the head and anterior part of the trunk. These armored head and trunk sections were linked by a movable joint. Placoderms were generally small (though some were giants, reaching 6 m in length) and possessed extensive dermal coverings, as did the “ostracoderms,” but they share numerous features that unite them with all other gnathostomes, including jaws and paired fins. There is, however, considerable question as to the homology of their jaws with those of other jaw-bearing vertebrates. Various differences in the masticatory apparatus, such as an internal rather than external position for the jaw muscles, may indicate that jaws were independently derived in placoderms and other gnathostomes. If so, the immediate common ancestor of these two groups may have lacked functional jaws. Placoderms had numerous shared derived characters that indicate that they form a monophyletic group, such as a unique joint in the neck that allowed the head to be lifted and a distinctive upper jaw articulation. Most authors consider placoderms as the sister group to all remaining gnathostomes, as is done here, but some regard them as united with the cartilaginous fishes, the Chondrichthyes (see below), in a monophyletic group.

In the remaining gnathostomes, the Eugnathostomata, the second visceral arch is modified into a hyomandibula, a supporting element for the jaw (Figure 1.3). In addition, eugnathostomes possess true teeth. They include the remaining fishes and the terrestrial vertebrates. Among the fishes, three major radiations may be recognized, the most primitive being the Chondrichthyes (Figure 1.3). This clade includes the sharks (Elasmobranchii) and chimaeras (Holocephali), and is united by various derived features, such as placoid scales, a cartilaginous skeleton with prismatic calcification, an endolymphatic duct connecting the inner ear with the exterior, and the presence of claspers in males. Despite these and other specializations, chondrichthyeans retain numerous plesiomorphic



**FIGURE 1.3** Cladogram showing phylogeny of the Vertebrata. Some synapomorphies of the main groups are provided in the boxes below the cladogram.



features in their basic anatomy. The near absence of bone, however, is not primitive, but a secondary loss. The combination of this condition and of ancestral features is a main reason why the shark is used so extensively for dissection: The primitive features allow an understanding of the basic vertebrate systems, and the specialized absence of bone facilitates the dissection of these systems.

The Elasmobranchii includes the sharks and rays. Traditionally these were considered monophyletic groups, with the Squalomorpha including sharks and Batoidea including skates and rays. However, the former may not be monophyletic, with some being more closely related to batoids than to other sharks. Elasmobranchs (from the ancient Greek *elasmos*, thin plate, and *branchia*, gills) have partitions between the pharyngeal slits that bear the gills. The holocephalians (chimaeras or ratfishes) differ in having a fleshy operculum covering the slits. Also, the upper jaw is fused to the braincase, a feature from which the group gets its name (holocephalian: from the ancient Greek, *holos*, whole, and *kephale*, head), whereas the upper jaw is separate from the braincase.

The Teleostomi includes the bony fishes and tetrapods (Figure 1.3). The bony fishes, as their name implies, retained and improved on a bony skeleton. The acanthodians are a relatively minor group of very early, extinct bony fishes, characterized by long stout spines associated with their paired fins, of which more than two were often present. The other two major radiations of bony fishes form a clade (including the tetrapods) termed the Osteichthyes, and include the Actinopterygii and Sarcopterygii (Figures 1.3, 1.4). A lung or air sac is considered a primitive trait for this group. From it a swim bladder evolved in some derived bony fishes.

The Actinopterygii (Figure 1.4) or ray-finned fishes are the most diverse and numerous vertebrates (about half of all living vertebrates are actinopterygians) and inhabit nearly all aquatic habitats. Their fins are supported internally by lepidotrichia or rays and are controlled by muscles that lie within the body wall. Actinopterygians include a staggering diversity of fossil and living forms, and only the most general of evolutionary outlines of living actinopterygians is possible here, with additional detail provided in Figure 1.3. Several major groupings may be recognized. The most basal is the Polypteriformes (= Cladista), which include *Polypterus* (bichir). They retain several of the early features of early actinopterygians, such as ganoid scales, well-ossified skeleton, and paired ventral lungs (air sacs) connected to the pharynx for aerial respiration. Many students are surprised that lungs would be important in fishes, but aerial respiration is so important that bichirs drown if deprived of it.

The Actinopteri includes more derived actinopterygians, with the Chondrostei—sturgeons and paddlefishes, as well as extinct relatives—representing the basal forms of this clade. The Neopterygii are the sister group to chondrosteans. The Lepisosteidae (gars) are basal neopterygians. The sister clade to lepisosteids is composed of a relatively small group, Amiidae, which includes the bowfins, and the Teleostei, which includes the most advanced actinopterygians.

Earlier classifications recognized three groups of actinopterygians, the chondrosteans, “holosteans,” and teleosteans, as reflecting a sequence of primitive, intermediate, and advanced actinopterygians. These categories were more properly evolutionary grades, with “holosteans” including the lepisosteids and amiids (see Figure 1.4), and are useful in following, in broad outline, some of the main trends in actinopterygian evolution. These include changes in the feeding apparatus, fin form and position, and body shape.

The feeding apparatus of bony fishes is structured so that the lower jaw was primitively capable only of simple lowering and closing. In this system, the upper jaw was fused to the braincase. The upper and lower jaws were long, with the articulation far back under the skull, permitting a wide gape. These features are reflected by the orientation of the hyomandibula, which sloped posteroventrally. The feeding apparatus underwent modifications, resulting in a complex kinetic system in which the jaws are protruded and allow inertial suction feeding. The main anatomical changes are that the jaws shortened, so the hyomandibula swung forward to assume, in advanced teleosts, an anteroventral orientation. The maxilla, a bone of the upper jaw, was freed from the jaw margin and functions as a lever in participating in movements of the premaxilla, the most anterior element of the upper jaw. Inertial suction feeding opened up numerous opportunities and is one of the main features cited in the success of actinopterygians. Associated changes occurred in the position and form of the fins and of the body. Primitively, the tail was heterocercal and the paired fins were in positions similar to that in the sharks: relatively ventral, with the pectoral fins lying anteriorly and pelvic fins posteriorly. Also, the body is, again as in sharks, fusiform, or torpedo-shaped. These features make for fast swimming. In teleosts, the pectoral fins are moved dorsally and the pelvic fins anteriorly. The tail is homocercal (superficially symmetrical) and the body laterally compressed. These changes allowed for different swimming styles, with considerably more precision control (for example, the dorsal position of the pectoral fins allows them to function as “brakes”). These changes were also instrumental in the great radiation of actinopterygians.

The sister group of the Actinopterygii is the Sarcopterygii, the second group of bony fish (but including tetrapods), which possess paired fins with internal skeletal support and muscles, and so are known as the lobe-finned fish (Figure 1.5). As fish, sarcopterygians were never as diverse or successful as the actinopterygians. As a clade, however, sarcopterygians are extremely successful, owing to the radiation of tetrapods. The fleshy fins of sarcopterygian fishes were not used for walking on terrestrial environments, but for maneuvering in shallow waters. Interestingly, a group of living sarcopterygian fishes, coelocanth (see below), swim by moving their fins the same way a terrestrial vertebrate uses its limbs to move on land.

Other sarcopterygian synapomorphies are provided in Figure 1.4. The most basal clade is the Actinista or coelocanth, represented only by two living species. Its sister group, the Rhipidistia, includes the Dipnoi and Choanata (Figure 1.5). Dipnoans are the lungfishes, of which only three genera survive. The choanates include several fossil groups, which are not considered here, and the Stegocephali, all marked by, among other features, true internal nostrils. Prestegocephalian choanates include several fish groups. The sister group to stegocephalians are the Elpistostegidae, which are notable for an elongated humerus and loss of the dorsal and anal fins. Among the earliest stegocephalians are the Acanthostegidae and Ichthyostegidae, which possessed fully developed limbs with more than five digits (fingers or toes). Our most recent understanding of these groups indicated that limbs first evolved in vertebrates that lived almost entirely in an aquatic environment. It is thought that the limbs were useful particularly in shallow areas, helping maintain the animal's position so it could wait for prey and allowing it easy access to air. Perhaps these vertebrates could also clamber out of the water to escape predators. After all, the terrestrial environment would at that time have been relatively free of predators and competition.

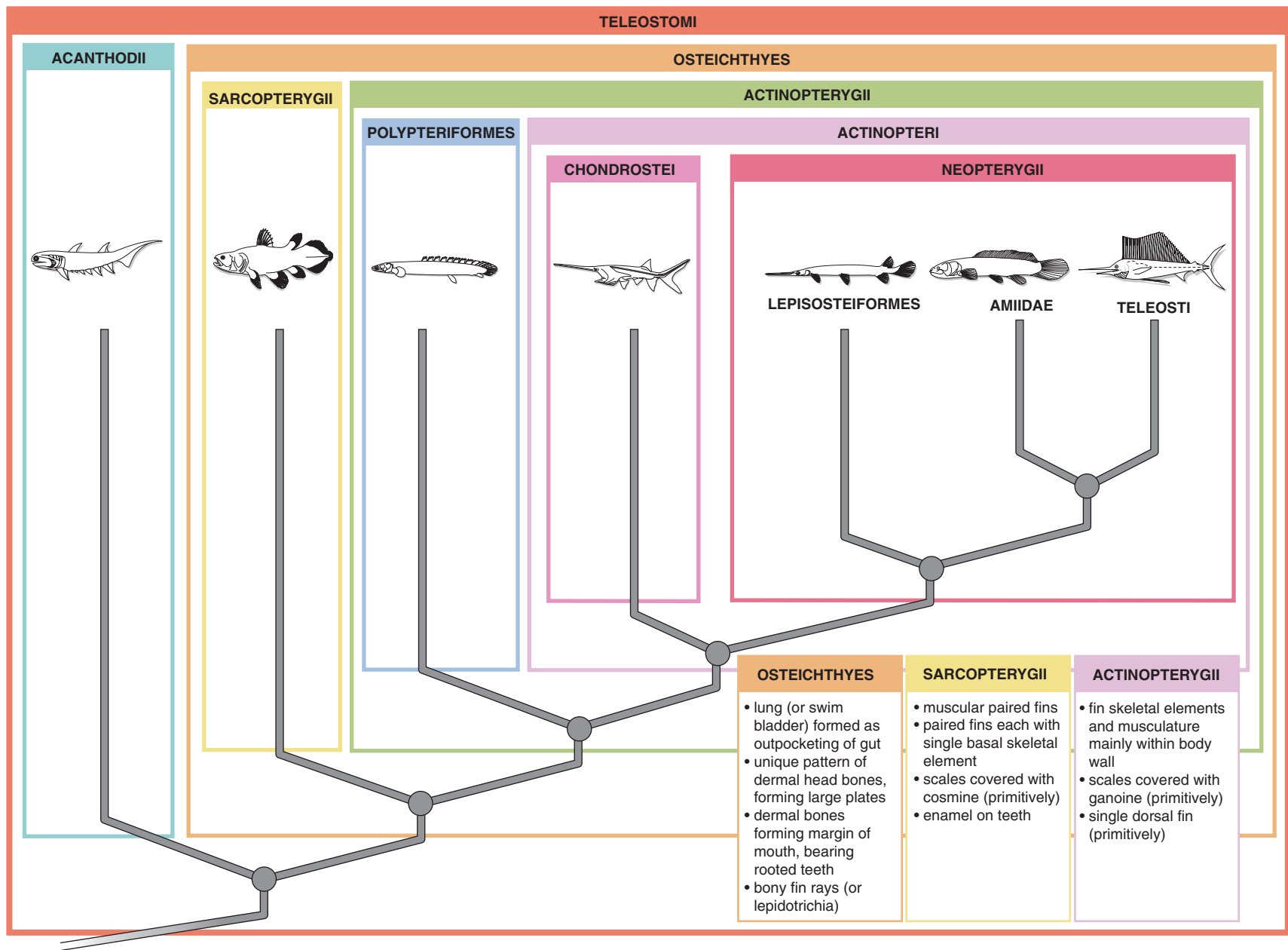
A short digression on other phylogenetic schemes is warranted at this point. The phylogenetic arrangement of vertebrates just presented is the conventionally accepted hypothesis. Several recent molecular analyses, however, are challenging this view. One analysis indicates that the Chondrichthyes do not occupy a basal position among gnathostomes. Some authors place Chondrichthyes and Placodermi in a single group as the sister clade to Teleostomi, thereby eliminating the Eugnathostomata as a clade. Another study suggests that, among living gnathostomes, all fishes do indeed form a monophyletic group, to the exclusion of the tetrapods, and thus that the Pisces is a natural group. The interested student is urged to consult the Selected References for further information (e.g., Arnason et al., 2004; Martin, 2001).

We may return to our discussion of stegocephalians (Figures 1.5, 1.6). Omitting several fossil groups for simplicity, we recognize a major stegocephalian clade, the Tetrapoda, defined as the clade that includes the last common ancestor of living amphibians and amniotes (see below). Tetrapods were and have remained mainly amphibious or terrestrial, although advanced members of several lineages have reverted to a mainly or entirely aquatic existence (e.g., the extinct ichthyosaurs among reptiles and the whales among mammals), and others are capable of flight (e.g., birds and the extinct pterosaurs among reptiles and bats among mammals). They share (together with several groups omitted here) five or fewer digits. Two tetrapod clades, the Amphibia and the Amniota, may be recognized.

Amphibians (from the ancient Greek *amphi*, both, and *bios*, life) are so called owing to the duality of their lifestyle—often a larval aquatic stage and a terrestrial adult stage are present. Amphibians are often viewed as intermediate between fishes and amniotes, mainly because their reproductive strategy is still tied to an aquatic environment (though this is not true of all amphibians), whereas amniotes' reproduction is more nearly independent of water. This general impression is true in the sense that amphibians do tend to retain an ancestral reproductive strategy. From this it is a small step to the view that all amphibians, including the living forms, are therefore primitive tetrapods. However, this is both misleading and incorrect. On the one hand, it is wrong to think of any living organism as primitive. A creature may retain ancestral or primitive features, but that does not make the creature itself primitive. Each living organism is the product of long evolutionary history and is a mosaic of both ancestral (primitive) and advanced (derived) features. For example, humans retain bone, an ancestral vertebrate character, whereas sharks are derived (advanced) in the loss of bone. The presence of this ancestral feature does not make humans “more primitive” or “less advanced” than sharks. Using the same logic, frogs are not more primitive than humans just because they retain an ancestral reproductive strategy.

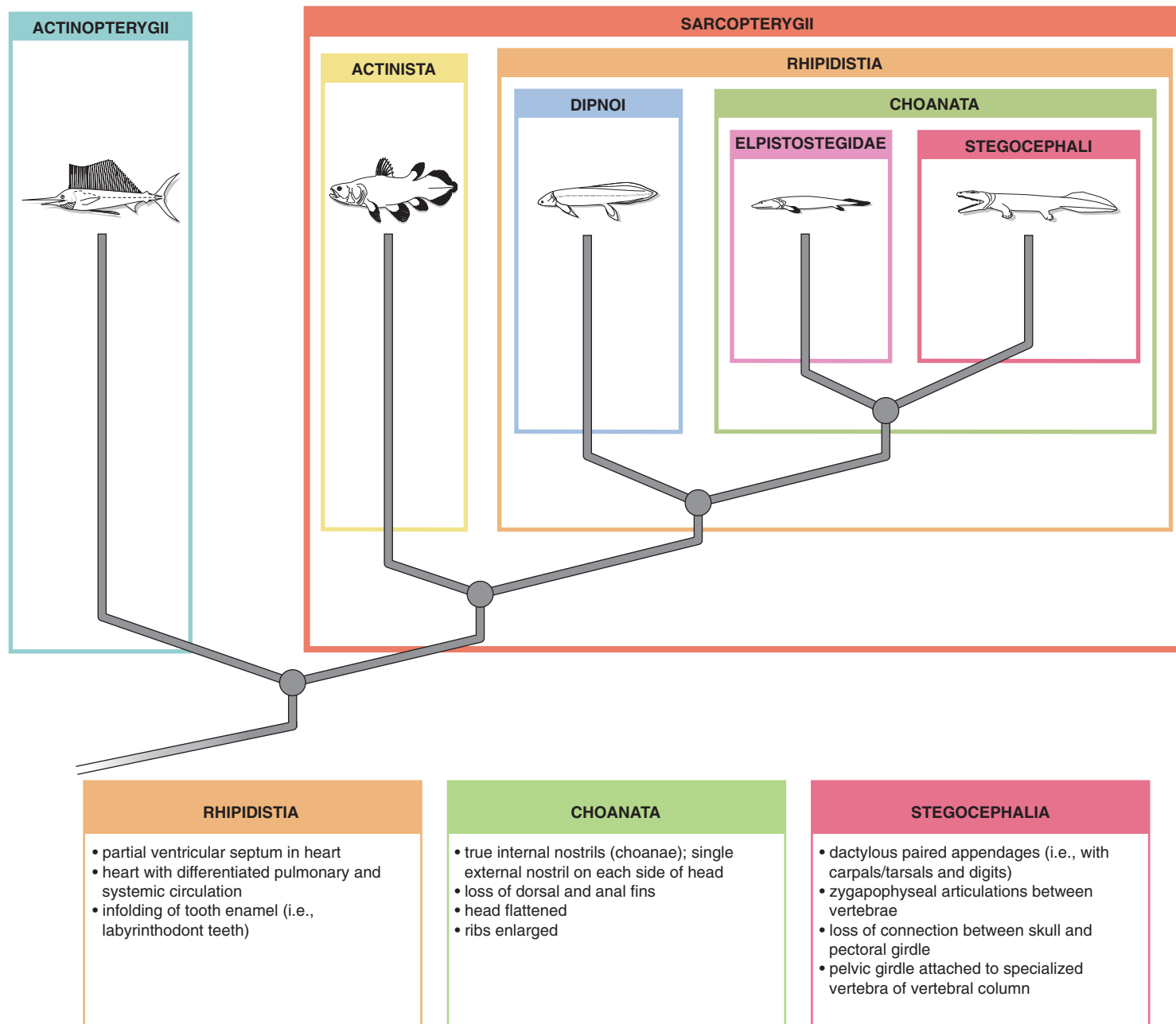
The second misconception is that living amphibians are representative of the lifestyle of the earliest stegocephalians. In some ways these early forms were intermediate between fishes and more derived terrestrial vertebrates, and in the past we have lumped these forms together with living amphibians. But we must be careful. Living amphibians, while retaining an ancestral reproductive mode, are clearly very specialized. They are not like the early stegocephalians, and in fact are highly derived vertebrates.

The Amphibia includes several fossil groups as well as the living forms. The latter form the clade Lissamphibia,

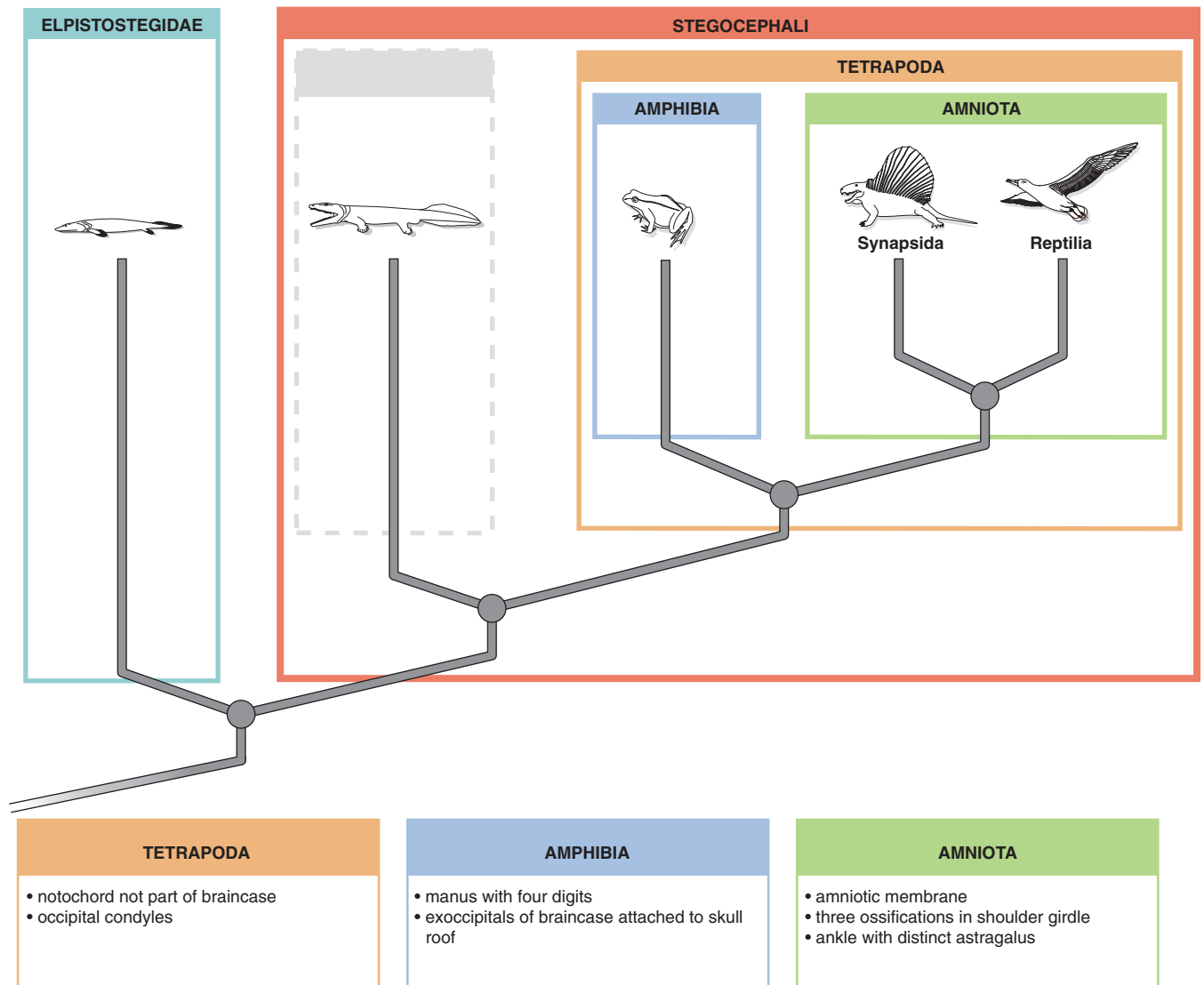


**FIGURE 1.4** Cladogram showing phylogeny of the Teleostomi. Some synapomorphies of the main groups are provided in the boxes below the cladogram.





**FIGURE 1.5** Cladogram showing phylogeny of the Sarcopterygii. Some synapomorphies of the main groups are provided in the boxes below the cladogram.



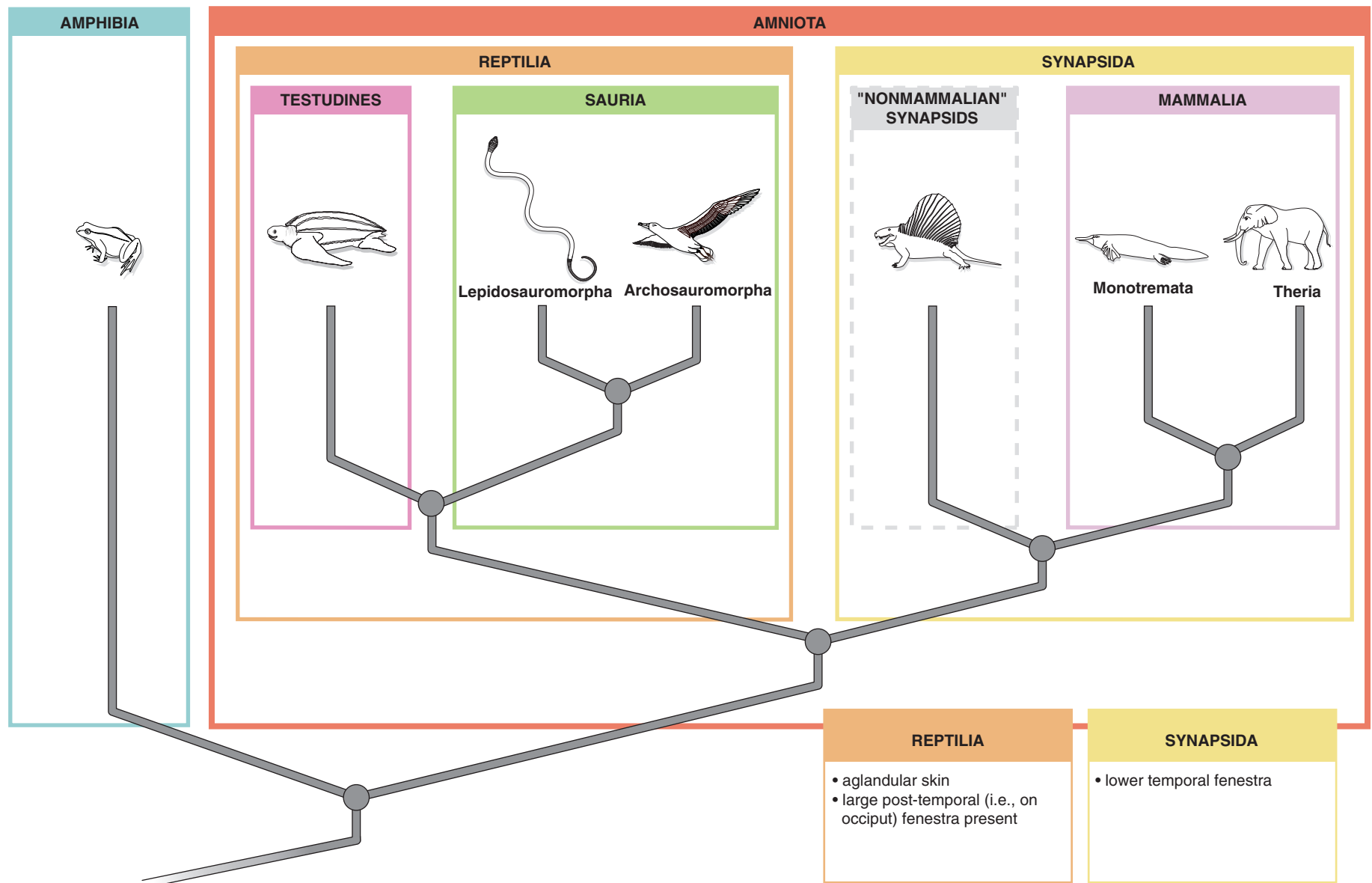
**FIGURE 1.6** Cladogram showing phylogeny of the Choanata. Some synapomorphies of the main groups are provided in the boxes below the cladogram. Dashed gray lines denote a paraphyletic group.

a term referring to their nature of their skin (*lissos*, smooth). The three lissamphibian groups are quite distinct. They are the Salienta (frogs), Urodela (salamanders), and Gymnophiona (caecilians). Frogs and salamanders are reasonably familiar vertebrates, and are considered sister groups. Frogs are highly specialized for saltational locomotion, whereas salamanders retain a more general body form and locomotion. Caecilians are specialized in being legless burrowers or swimmers.

The Amniota includes the remaining tetrapods (Figures 1.6, 1.7). The main innovation of amniotes is the amniotic egg. Amniote embryos develop within extraembryonic membranes that are usually encased in a calcareous or leathery egg (the term “*anamniotes*” refers to vertebrates whose eggs do not have extraembryonic mem-

branes). The membranes provide the embryo with a “watery” environment that is protected against desiccation, and thus amniotes’ reproduction has become essentially independent of an aqueous environment in which vertebrates ancestrally reproduced (however, a relatively moist environment is still essential).

The amniotes (Figure 1.7) include two great lineages, the Reptilia (ignoring some fossil members) and Synapsida, which have followed independent evolutionary paths since the early history of amniotes. The synapsids include mammal-like reptiles and mammals. The latter, the Mammalia, are the living synapsids. One mammalian group is the Monotremata, a relatively small clade, including the echidnas and platypus, that retains the ancestral reproductive strategy of laying eggs. The other group, the Theria, includes the marsupials



**FIGURE 1.7** Cladogram showing phylogeny of the Tetrapoda. Some synapomorphies of the main groups are provided in the boxes below the cladogram. Dashed gray lines denote a paraphyletic group.

(Marsupialia) and the placental mammals (Eutheria). These mammals have evolved reproductive modes where embryos are retained in and nourished by the mother's body.

The Reptilia includes the typical living and fossil reptiles, such as turtles, lizards, snakes, and crocodiles, along with other familiar and mainly extinct groups, such as dinosaurs (which includes the birds), pterosaurs,

and ichthyosaurs. Several groups may be recognized. The turtles (Testudines) apparently are the sister group to all other reptiles (though recent molecular evidence contradicts this, suggesting turtles may be more closely related to dinosaurs and crocodiles than was previously thought). The remaining living reptiles are usually placed in the Sauria, which includes Archosauromorpha (crocodiles and birds) and Lepidosauromorpha (lizards and snakes).

This page intentionally left blank

# CHAPTER 2

## THE LAMPREY

### INTRODUCTION

As noted in Chapter 1, the earliest craniates lacked jaws, and so are termed “*agnathans*.” Numerous extinct “agnathans” are known from the fossil record and most possessed a covering armor of dermal bone, from which is derived the term “*ostracoderms*.” Living craniates retaining the absence of jaws are the hagfishes (Myxinoidea) and lampreys (Petromyzontoidea). A characteristic feature of these craniates is an anterior, rounded, sucker-like structure used to attach themselves to the body of their prey, from which the term “*cyclostome*” is derived. The relationship between these “agnathans” is not settled. They were for many years considered to be each other’s closest relatives and classified as “Cyclostomata.” About two decades ago, morphologists began to note that some characteristics of lampreys indicated they were more closely related to the jawed vertebrates and classified with them in the Vertebrata. Most recently, molecular evidence is again suggesting a close relationship between “cyclostomes.”

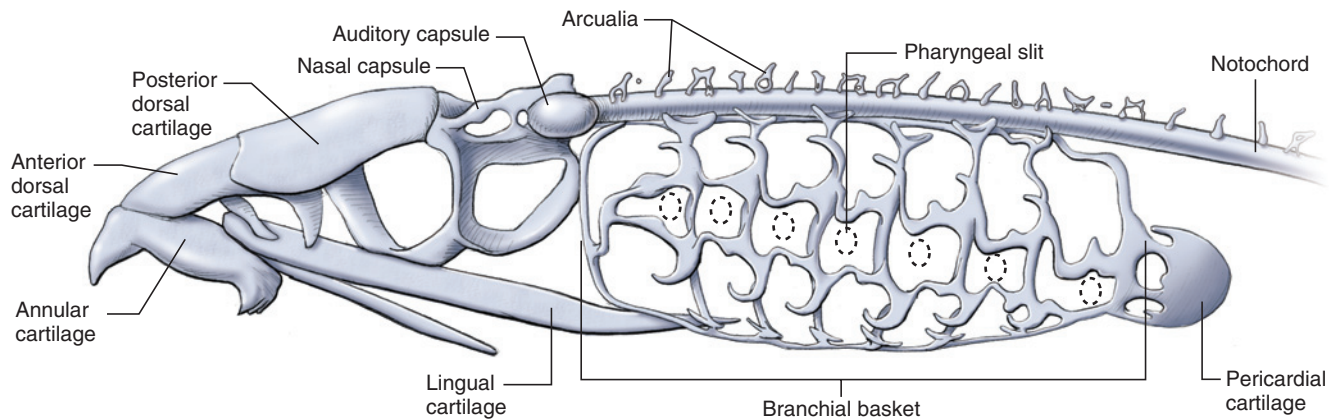
Of the approximately 50 lamprey species, the marine lamprey, *Petromyzon marinus*, of the Atlantic Ocean and North American Great Lakes, is the most commonly studied “cyclostome.” Hagfishes are about as diverse, with 60 species generally recognized, and are exclusively marine—indeed, they are the only vertebrates having their body fluids isosmotic with seawater. While lampreys and hagfishes share several similarities, such as an eel-like body shape and a sucker-like mouth, there are important differences between them. Lampreys are generally parasitic, attaching themselves to their prey and relying mainly on a liquid diet, while hagfishes are scavengers and tear off pieces of dead or dying prey. These differences are reflected in several innovative modifications. The lamprey, for example, has a subdivided pharynx, with the ventral part forming a respiratory tube that can be isolated from the mouth by a valve termed the *velum*. This ensures that its liquid diet neither escapes from the pharyngeal slits nor interferes with gas exchange through the gills. While the tube is isolated, the lamprey continues to ventilate its gills by pumping water in and out of the pharyngeal slits. The hagfish, on the other hand, has a more substantial diet

and does not require a respiratory tube that can be isolated. It ventilates its gills by having a nasal opening that continues past the nasal sac to communicate with the pharynx. A velum is also present in the hagfish. With the velum closed, muscular action compresses the pharynx and water moves over the gills.

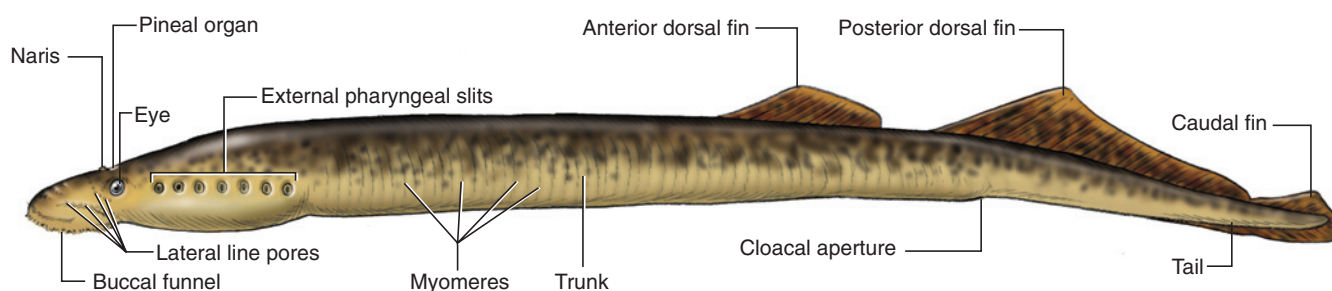
### SECTION I—SKELETON

The entirely cartilaginous skeleton of the lamprey is not particularly well developed (Figure 2.1). Study the skeletal elements in prepared specimens, which are usually embedded in acrylic. The head skeleton is complex and quite unlike that of other vertebrates. Endochondral elements forming a **chondrocranium** include large cartilages that partially enclose the brain and sense organs (nasal capsule, otic capsule), and others that extend anteriorly to support the **annular cartilage**, the ring-like structure that is the main skeletal element of the **oral funnel** (see below). Several of these cartilages are labeled in Figure 2.1. The median **lingual cartilage**, supporting the rasping **tongue**, extends posteriorly from the annular cartilage, ventral to the chondrocranium.

Extending posterior and connected to the chondrocranium is a network of cartilages forming the **branchial basket**, which supports the pharyngeal region. The somewhat hemispherical cartilage at the posterior end of the branchial basket is the **pericardial cartilage**, which lies on the posterior wall of the pericardial cavity, the space that contains the heart. There are three main differences between this pharyngeal skeletal support and that found in more derived fishes. One is that the structure is a connected network, rather than relatively separate and articulated arches. Another difference is the connection to the pericardial cartilage. Yet another is that the branchial basket lies superficially, lateral to the gills and thus just beneath the skin. In contrast, in other fishes the branchial arches lie more deeply, medial to the gills, and thus in the medial wall of the pharynx. Because the branchial basket lies just under the skin, it may be observed by carefully skinning one side of the head of your specimen. If you wish to do this, postpone



**FIGURE 2.1** Skeletal elements of the lamprey in left lateral view.



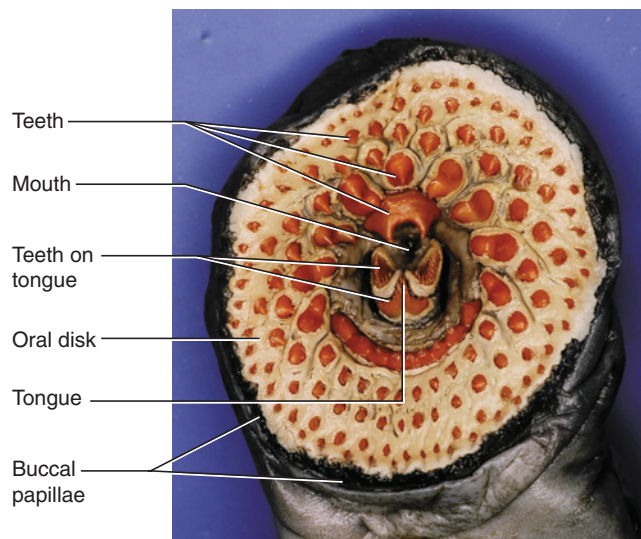
**FIGURE 2.2** External features of the lamprey in left lateral view.

your dissection until you have studied the remaining lamprey structures described below.

The large **notochord** is the axial support of the body. It is an elongated rod extending from beneath the posterior half of the brain to the tip of the tail. The vertebrae are represented by small, cartilaginous structures, termed **arcualia**, that lie dorsal to the notochord on either side of the spinal cord (see below). They are usually embedded in connective tissue or lost in prepared specimens, and are not particularly evident. Indeed, they are difficult to find, but may occasionally be observed in cross sections.

## SECTION II—EXTERNAL ANATOMY

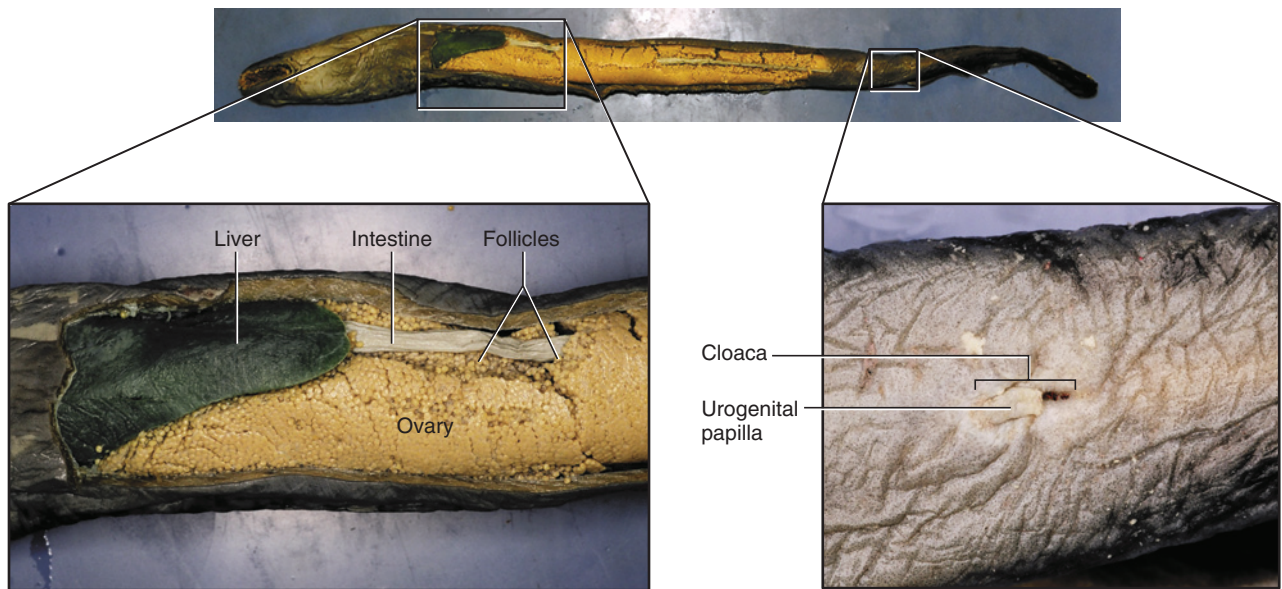
The body of the lamprey is elongated and cylindrical, and covered by smooth, scaleless skin (Figure 2.2). The **head** extends posteriorly to include the slanted row of seven rounded or oval apertures, the **external pharyngeal slits**, which lie posterior to each of the laterally placed, lidless eyes. The eyes, of moderate size, are covered by transparent skin. In preservatives, however, this skin turns opaque. Anteriorly the **oral funnel** forms a wide, sucking disk that attaches to the body of the lamprey's prey (Figures 2.1, 2.3). The funnel's margin



**FIGURE 2.3** Anterior view of buccal funnel of the lamprey showing mouth and oral disk with teeth.

bears small, soft projections, the **buccal papillae**, which are primarily sensory structures. The funnel's interior surface is termed the **oral disk**, and it is lined with numerous **horny teeth**, which are cornified epidermal derivatives and thus not homologous with the teeth of more derived vertebrates. Remove a tooth with forceps





**FIGURE 2.4** Ventral view of the lamprey, with pleuroperitoneal cavity exposed (top). Detail of anterior end of pleuroperitoneal cavity and contained structures (left). Detail of cloacal region (right).

to observe a replacement tooth immediately underneath it. At the pit of the funnel lies the rasping tongue, which also bears horny teeth and, like them, is not homologous with the structure of the same name in more derived vertebrates. The tongue is used to abrade the skin of prey, so that its blood and body fluids may be ingested. Dorsal to the tongue is the **mouth**. The lamprey, being an “agnathan,” lacks jaws.

A single, median **naris** lies middorsally between the eyes (Figures 2.1, 2.8). A lighter patch of skin immediately posterior to the nostril denotes the position of the **pineal complex**, which lies just below the skin and functions as a photoreceptor that detects changes in light. A **lateral line system**, which functions in detecting vibrations in the water, is present in the lamprey, but not typically conspicuous. Usually, however, pores for the canals are noticeable in the head region. The pores are arranged in rows. One occurs just posterior to each eye, and several others may be found between the eye and the anterior end of the oral funnel.

The trunk extends from the head to the **cloaca**, a rather shallow midventral depression (Figure 2.4). The intestine opens into the cloaca through a slit-like **anus**. Posterior to the latter, there is a small **urogenital papilla** with a terminal **genital pore** through which gametes and excretory products leave the body. The **tail** extends posteriorly to the tip of the body and becomes laterally compressed. The lamprey has no trace of paired fins, but there are three median fins (Figure 2.2), the **anterior dorsal** and **posterior dorsal fins** and the **caudal fin**. The fins are supported by **fin rays**, which can be seen if the

specimen is held against the light. Examine the lateral surface of the trunk or tail to observe the outline of the segmented series of muscular blocks, the **myomeres**. These are composed of longitudinal fibers extending between successive connective tissue partitions, the **myosepta**. Contraction of the myomeres on one side of the body flexes the body toward that side, and alternating contraction of the myomeres on opposite sides of the body produces the characteristic side-to-side swimming motion of fishes.

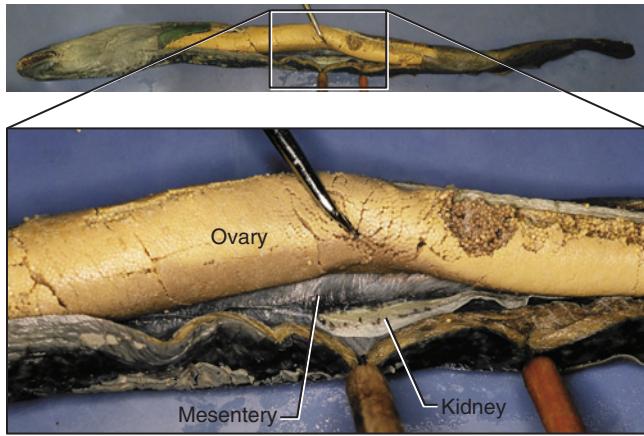
### SECTION III—PLEUROPERITONEAL CAVITY AND VISCERA

Open the **pleuroperitoneal cavity** by making an incision through the midventral body wall extending from about 1 cm posterior to the last pharyngeal slit to just anterior to the cloaca. Make several vertical cuts on one side of the body from the ventral incision so the body wall may be reflected. The wall, or portions of it, may be removed to facilitate exposing the contents of the cavity, but be careful not to injure the underlying organs.

The most notable feature of the lamprey viscera, as with much of the lamprey’s anatomy, is its relative simplicity. This is often manifest in the apparent absence of structures, as noted below. Keep in mind, however, that an absence or apparent lack of complexity in a particular structure does not necessarily indicate primitiveness.

On opening the cavity, the **gonad** may be the first structure visible (Figures 2.4, 2.5). It is normally of moder-

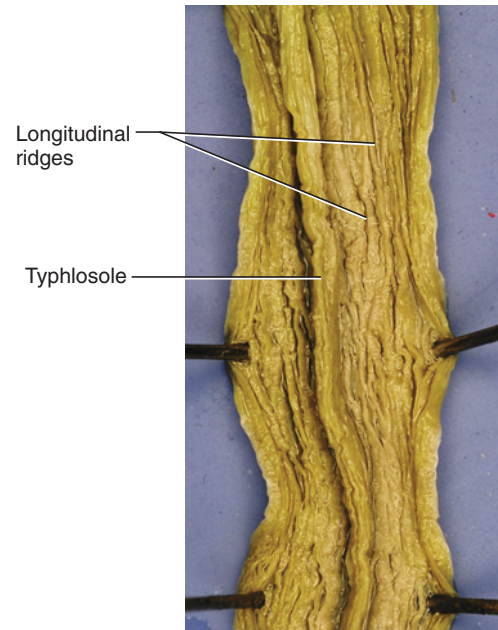




**FIGURE 2.5** Ventral view of pleuroperitoneal cavity of the lamprey, showing detail of gonad, kidney, and mesentery.

ate size but in breeding season it may be huge, occupying much of the pleuroperitoneal cavity. The **ovary** and **testis** are, secondarily, single median structures, supported by a mesentery from the middorsal line (Figure 2.5), and lying dorsal to the **liver** and **intestine**. The ovary and testis are difficult to distinguish from each other. Just before breeding, however, the ovary contains many follicles, giving it a granular appearance compared to the testis. **Genital ducts** are absent in the lamprey, and gametes are shed into the **coelom**. They must make their way to the posterior end of the pleuroperitoneal cavity, where they exit by way of **genital pores** to enter the urogenital sinus (the single median cavity within the urogenital papilla). You may, after removing the gonad (see below) gently probe the posterior end of the pleuroperitoneal cavity, on either side of the urogenital sinus, to locate the genital pores; they are, however, difficult to find.

The liver (Figure 2.4) is the large, greenish organ at the anterior end of the pleuroperitoneal cavity. If the ovary is very large, it may cover the posterior end of the liver. A gall bladder and bile duct are present in the larval stage, but absent in adult lampreys. The digestive system is relatively simple, and consists mainly of a long, narrow, tubular **intestine** (though it may be distended in some specimens) extending the length of the pleuroperitoneal cavity. There are none of the bends and folds so common in more derived vertebrates. The anterior part of the intestine extends from the “**esophagus**” (see below and Figure 2.8) and is dorsal to the liver, but more posteriorly it is easily seen in ventral view. Note the lack of any real regional specialization along the digestive tract. There is no stomach, for example. Given the mainly liquid diet of lampreys, there is no need for a separate stomach to temporarily store food and “feed” it to the intestine. Nor is there a distinct pylorus. A terminal swelling, sometimes present, may be recognized as a rectum. Make a longitudinal slit along a portion of



**FIGURE 2.6** Intestine of the lamprey, cut to show its internal structure.

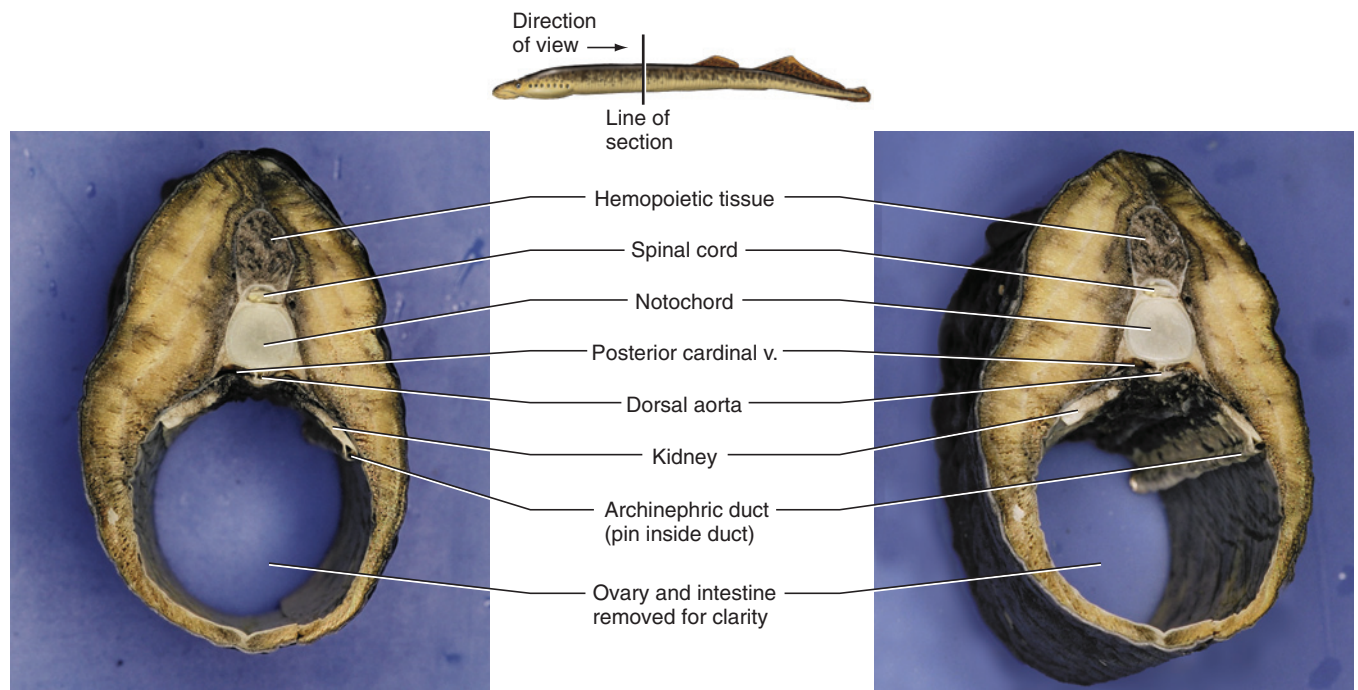
the intestine and spread it open. Numerous longitudinal folds are present on its interior surface to increase surface area (Figure 2.6). One of these, the **typhlosole**, is notably larger than the others. It is also termed a *spiral valve* but its relationship to the spiral valve of other vertebrates is ambiguous. Also note the virtual absence of either dorsal or ventral mesenteries. A few small mesenteric sheets of dorsal mesentery, carrying blood vessels to the gut, are present near the posterior end of the intestine.

A spleen is absent, as is a distinct pancreas. Tissue performing pancreatic functions is present, however, and scattered through some viscera. Exocrine pancreas is present in parts of the intestinal wall and islet tissue (endocrine) occurs in the liver, but they are not visible grossly.

A long, thin, ribbon-like **kidney** lies on either side of the middorsal line and extends for much of the length of the pleuroperitoneal cavity (Figure 2.7). The **archinephric duct**, which drains the kidney, lies along its free lateral margin. Make a transverse cut through the kidney and examine the cut section to observe the duct. Posteriorly the archinephric ducts enter the urogenital sinus, but it is impractical to attempt tracing them.

## SECTION IV—SAGITTAL SECTION

A sagittal section of the head and anterior part of the trunk reveals a number of interesting features, and, in particular, allows the observation of the extreme spe-



**FIGURE 2.7** Cross section through body of the lamprey, seen in anterior view. The left and right views are of the same section, seen at slightly different angles.

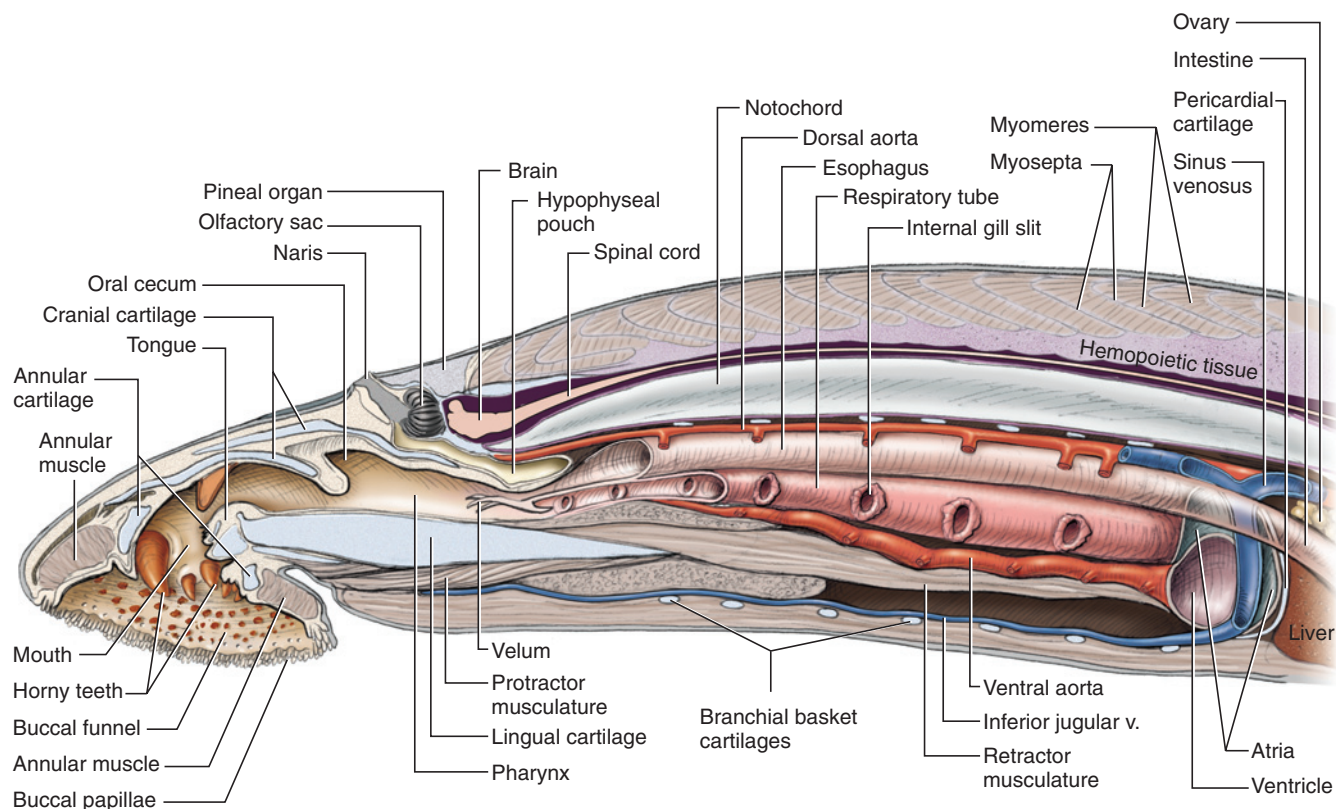
cializations of the lamprey's digestive and respiratory systems. Using a large, sharp scalpel, make a clean sagittal section through the head of the lamprey. Maintain your cut as close to the sagittal plane as possible and extend the section about 10 cm posterior to the level of the last external pharyngeal opening. Compare your specimen to Figure 2.8. If your section is not quite sagittal, use a new scalpel blade and carefully shave tissue from the larger half until you reach midsagittally.

Examine the anterior part of the head to reidentify structures already noted, such as the annular cartilage, oral funnel, horny teeth, mouth, and tongue. Trace posteriorly from the mouth, over the anterodorsal surface of the tongue, into the oral cavity, which has a short anterodorsal extension, the **oral cecum**. Posteriorly the oral cavity passes into the “**esophagus**” dorsally and the **respiratory tube** or “**pharynx**” ventrally. The terms set in quotation marks denote subdivisions of the embryonic pharynx, and so are not homologous with the esophagus and pharynx of other vertebrates (although, of course the “pharynx” is partly homologous with the pharynx). This anatomical condition in the lamprey reflects its highly specialized feeding mode. It would make little sense to feed on fluids if they could easily escape through pharyngeal openings. During metamorphosis from the larval stage, a horizontal partition develops that subdivides the originally single pharynx in dorsal and posterior portions. The dorsal subdivision, as indicated, is the “esophagus” and serves to conduct

food to the intestine. It is thin-walled and usually collapsed, thus difficult to identify. The respiratory tube is the ventral subdivision. It ends blindly posteriorly. A valve, the **velum**, can close its anterior opening into the oral cavity, thereby isolating the tube. This system is necessary because the lamprey spends much of its time with the oral funnel attached to its prey, so that the mouth cannot function in ventilating the gills. With the respiratory system isolated from the ingestion mechanism, food is passed back into the intestine. The lamprey continues to ventilate its gills with respiratory water currents going both in and out through the gill openings.

The **tongue** is supported by the large **lingual cartilage**. Note the complex of muscles arranged around the lingual cartilage. This musculature is responsible for working the tongue. Protractor muscles extend anteriorly ventral to the cartilage, whereas the retractor muscles extend posteriorly from it.

The small **brain** lies dorsally. It is not particularly similar to that of more derived vertebrates, but it is tripartite, having the same major subdivisions. Trace it posteriorly as it passes into the **spinal cord**. Note the large **notochord**, which begins ventral to the posterior half of the brain and extends posteriorly, ventral to the spinal cord, for the rest of the lamprey. Note the slender sections of the cartilaginous elements that contribute to the chondrocranium. There are not true vertebrae, but cartilaginous blocks termed **arcualia**, on either side of the spinal



**FIGURE 2.8** Schematic sagittal section through head and pharyngeal region of the lamprey. The vessels, esophagus, respiratory tube, and parts of the heart are shown with portions cut away, rather than in sagittal section.

cord. As noted above, however, these are difficult to find, and are lost in most prepared specimens.

Locate the naris. It opens into a short tube that leads to the dark-walled **olfactory sac**, directly anterior to the brain. The sac's interior surface has numerous folds to increase surface area. The tube continues past the opening of the olfactory sac as the **hypophyseal pouch**, which ends blindly ventral to the brain and anterior end of the notochord. Dorsal to the nasal sac and anterior end of the brain is the **pineal eye complex**, a region specialized primarily for light detection.

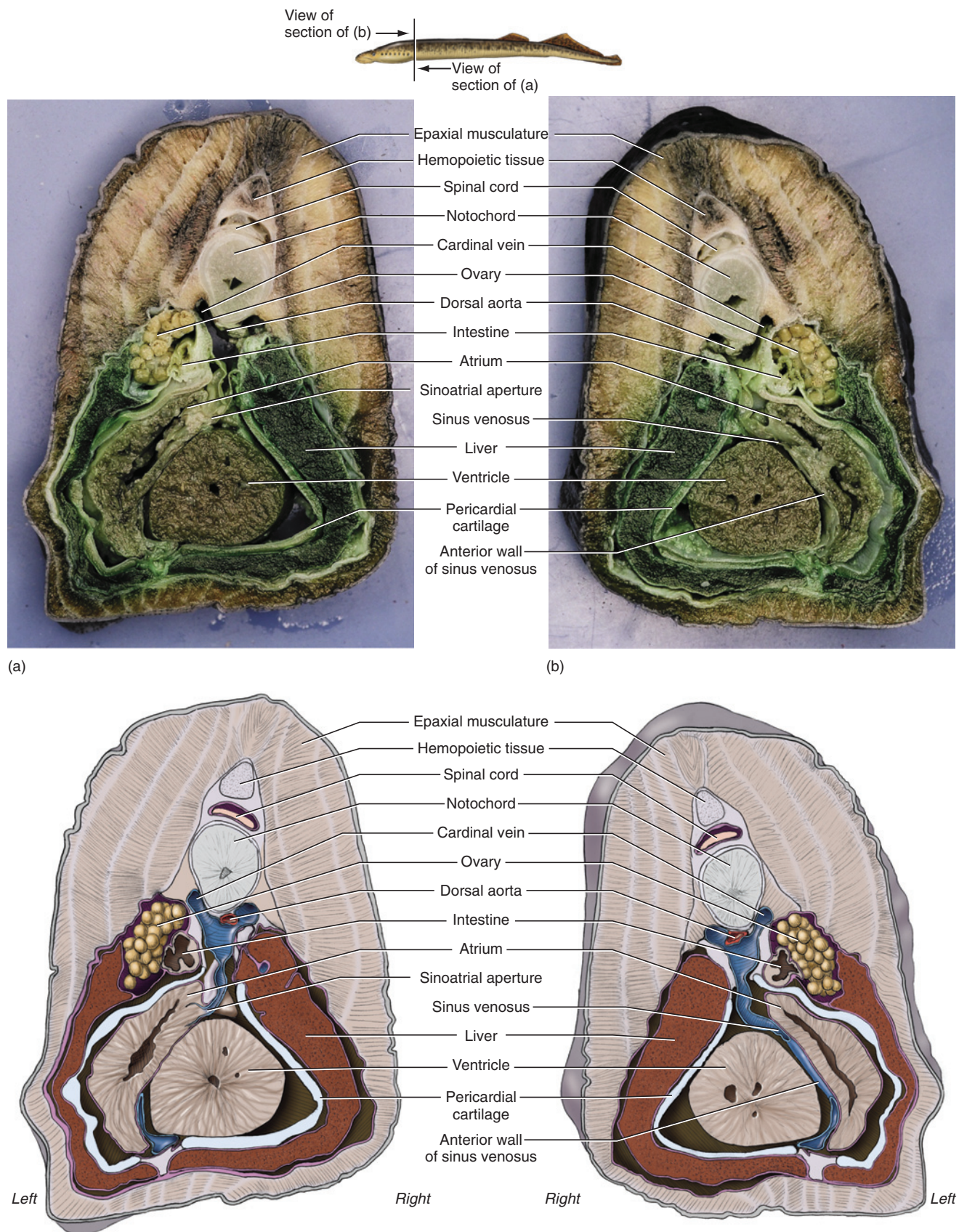
The **heart** lies in the pericardial cavity, posterior to the respiratory tube. Posteriorly it is separated from the pleuroperitoneal cavity by the **transverse septum**, which is stiffened by the pericardial cartilage. The heart has three chambers, in contrast to the four present in more derived vertebrates. These are, in order of blood flow, the **sinus venosus**, **atrium**, and **ventricle**. The spatial positions of these chambers do not follow the sequential posterior-to-anterior progression typical of the heart of most fishes. Instead, the sinus venosus is a tubular structure, oriented dorsoventrally, that lies between the atrium and ventricle. The atrium mainly occupies the left side of the pericardial cavity and the ventricle mainly occupies the right side. The depiction of the heart in

sagittal section (Figure 2.8) is somewhat idealized, as structures such as the intestine and inferior jugular vein are shown in their entirety, rather than as sectioned, as they would be in a true sagittal section. Compare these structures with Figure 2.9, which shows the relationships of these and other structures in transverse view.

The flow of blood passes forward from the ventricle through the **ventral aorta**, which sends out seven **afferent branchial arteries** to the capillaries in the septa between the pharyngeal slits. The blood is recollected by the **efferent branchial arteries**, which channel it into the **dorsal aorta** for distribution to the body. It is easiest to observe the dorsal aorta in a transverse section. It is a median structure extending just ventral to the notochord (Figures 2.7, 2.9). In the tail, it is known as the **caudal artery**.

Blood from the head returns to the heart mainly through the paired **anterior cardinal veins** dorsally and the median **inferior jugular vein** ventrally. Much of the posterior part of the body is drained by the paired **posterior cardinal veins**, as well as the **hepatic portal vein**. The latter is difficult to identify and not considered further here except to note that it comprises a system of veins that drains blood from the intestine and conducts it to the heart. Dorsal to the heart, the right anterior





**FIGURE 2.9** Cross section through body of the lamprey to show structure of the heart. A shows the anterior portion of the section in posterior view. B shows the posterior section in anterior view. Interpretative illustrations are below each photograph.

and posterior cardinal veins join to form a right common cardinal vein, which then enters the dorsal end of the sinus venosus (Figure 2.9). The left anterior and posterior cardinal veins join the right common cardinal vein. Note that this condition is distinct from that present in most jawed fishes, such as the shark, where the anterior and posterior cardinal veins of each side of the body unite to form their own common cardinal vein that enters the sinus venosus separately. The inferior jugular vein is a median structure and enters the ventral end of the sinus venosus. For most of its length, it is a median structure, but near the sinus venosus it veers slightly to the left.

In the tail, the **caudal vein** accompanies the caudal artery. The lamprey does not have a renal portal system, as do jawed fishes, so the caudal vein does not bifurcate into renal portal veins that then enter the kidneys. Instead the caudal vein bifurcates into the right and left posterior cardinal veins (Figure 2.7), which receive blood from the kidneys.

### KEY TERMS: LAMPREY

afferent branchial  
arteries

annular cartilage

anterior cardinal veins

anterior dorsal fin

anus

archinephric duct

arcualia

atrium

brain

branchial basket

buccal papillae

caudal artery

caudal fin

caudal vein

chondrocranium

cloaca

coelom

dorsal aorta

efferent branchial  
arteries

“esophagus”

external pharyngeal  
slits

eyes

fin rays

genital ducts

genital pore

gonad

head

heart

hepatic portal vein

horny teeth

hypophyseal pouch  
(nasohypophyseal  
pouch)

inferior jugular vein

intestine

kidney

lateral line system

lingual cartilage (piston  
cartilage)

liver

mouth

myomere

myoseptum (plur.,  
myosepta)

naris (nostril)

notochord

olfactory sac

oral cecum

oral funnel

ovary

pericardial cartilage

pineal eye complex

pleuroperitoneal cavity

posterior cardinal veins

posterior dorsal fin

respiratory tube  
 (“pharynx”)

sinus venosus

spinal cord

tail

testis

tongue (piston)

transverse septum

typhlosole

urogenital papilla

velum

ventral aorta

ventricle

# CHAPTER 3

## THE SHARK

### INTRODUCTION

The spiny dogfish shark, *Squalus acanthias*, belongs to the Chondrichthyes, which first appeared in the Silurian Period and are among the earliest to branch off from the rest of the gnathostomes (jawed vertebrates). Living chondrichthyans comprise the sharks and rays (Elasmobranchii, meaning plate-gilled) and the chimaeras (Holocephali, meaning whole or entire head). Among the specialized features that unite these groups are unique perichondral and endochondral mineralization, distinctive placoid scales, an inner ear that opens externally through the endolymphatic duct, pelvic claspers in males (an adaptation for the internal fertilization practiced by modern chondrichthyans), and a cartilaginous skeleton. As the earliest agnathan vertebrates were bony, the cartilaginous condition of the chondrichthyan skeleton is apparently derived. In addition to these specialized features, they retain numerous ancestral characteristics, which is one reason why they are ideally suited as subjects for the study of a basic vertebrate. Chondrichthyans lack the swim bladder or lung that evolved early among the bony fishes, and modern sharks all possess a large, oil-filled liver that dramatically reduces their specific gravity.

Modern chondrichthyans are a fairly large and diverse group due mainly to the success of the sharks or Neoselachii, which are arranged in two groups, although it is not clear that they are sister groups. Sharks have fusiform bodies with well-developed paired fins and a powerful heterocercal tail. Five to seven branchial slits and, usually, a spiracle are present. A row of serrated, triangular, and pointed teeth commonly line each of the upper and lower jaws and are followed by rows of teeth that can rapidly replace broken or worn teeth. Efficient swimmers with a well-armed mouth, sharks are formidable slashing predators. However, not all sharks fit this mold. Indeed, the largest of them, the basking and whale sharks, feed by straining food from the water.

The skates and rays are closely related to the sharks and are placed in the Batoidea. They are dorsoventrally flattened, largely due to greatly expanded pectoral fins.

The branchial slits open ventrally (the group is thus also known as Hypotremata, meaning *under slits*) and the prominent spiracle dorsally. The tail and caudal fin are generally reduced and often whip-like. Locomotion is accomplished through wave-like flapping of the fins rather than lateral undulations of the trunk and tail. Some rays can generate electric shocks, produced by modified muscles, to repel an attack or capture prey. The flattened condition of the body is typical of bottom-dwelling forms. The teeth are modified into flattened plates for crushing bottom-dwelling small vertebrates, molluscs, and crustaceans. Like the largest sharks, however, the largest rays, such as the manta ray, tend to strain food from the water.

Holocephali, the other main chondrichthyan group, includes the chimaeras. Holocephalans are so called because they possess an operculum that covers the gills (thus there is a single opening on either side of the head, as occurs in bony fishes) and gives the head an undivided appearance. The peculiar globular head with dental plates and long, thin tail have inspired their alternate designation as *ratfish*. Additional features of chimaeras are that the upper jaw is fused to the braincase, a spiracle is present only as a transitory structure during ontogeny, the anterior vertebrae form a synsacral that articulates with an anterior dorsal fin, and the male has, in addition to pelvic claspers, a cephalic clasper. They also lack scales except for the modified spine at the base of the dorsal fin.

### SECTION I—SKELETON

Study a prepared specimen of the dogfish skeleton. It may be immersed in fluid, in a sealed glass jar, or set in clear acrylic blocks and available only for visual inspection. Separate specimens of the head skeleton may be available for closer inspection. Place such specimens in a tray and cover them with preservative fluid. As they are delicate and easily broken, handle them cautiously. Segments of the vertebral column and the fins are often set in acrylic blocks. Although these are not easily broken, handle them carefully. Do not, for example, slide them across a table or poke them with needles or pens.



Examine a specimen of a dogfish skeleton (Figure 3.1). Anteriorly, the skeleton of the head includes the **chondrocranium** and **splanchnocranium**. The **vertebral column** extends from the chondrocranium to the tail and supports the **anterior dorsal fin**, **posterior dorsal fin**, and **caudal fin**. The **pectoral girdle**, supporting the **pectoral fins**, lies just posterior to the splanchnocranium; the **pelvic girdle**, supporting the **pelvic fins**, lies further posteriorly. Note that the pectoral and pelvic girdles are isolated components, without direct attachment to the rest of the skeleton.

## Chondrocranium

The chondrocranium is the large single element of the head skeleton (Figure 3.2). It surrounds and provides support for the brain and sense organs. The scoop-like **rostrum** projects anteriorly and contains the **precerebral cavity**. The cavity communicates posteriorly with the cranial cavity by way of the **precerebral fenestra**. The rostrum is supported ventrally by the **rostral carina**. Paired **rostral fenestrae** lie on either side of the carina. The paired **nasal capsules** lie laterally to the base of the rostrum. Paired openings, the **nares**, may be preserved on the ventral surface of each capsule.

Posterior to the capsules lies the optic region of the chondrocranium. An orbit, the space occupied in life by the eyeball, lies on either side of this region. The **antorbital shelf** forms the anterior orbital wall. The orbit is defined dorsally by the **antorbital process**, **supraorbital crest**, and **postorbital process**. Posteriorly and ventrally the orbit expands into paired **basitrabecular processes**. Various openings into the chondrocranium are present in this region. On the dorsal surface between the antorbital processes is the median **epiphyseal foramen**. Several smaller openings, the **superficial ophthalmic foramina**, pierce each supraorbital crest. The medial wall of the orbit bears numerous openings, the largest being the **optic foramen** lying ventrally in the central part of the orbit. Another large opening, the **trigeminafacial foramen**, is located posteroventrally in the orbit. The **optic pedicle**, which supports the eyeball, takes root from the orbit just anterior to the trigeminafacial foramen. Other openings such as the **trochlear**, **abducens**, and **oculomotor foramina** may be identified.

Behind the orbits is the squared otic region, which contains the **otic capsules** that house the inner ears. The **basal plate** is the wide, flattened ventral part. The carotid foramen lies at the very anterior end of the basal plate. On the dorsal surface, near the junction of the postorbital processes and otic regions, the chondrocranium bears a large, median depression, the **endolymphatic fossa**. Within the fossa are two pairs of openings. The smaller, anterior two are the **endolymphatic foramina**;

the posterior pair the **perilymphatic foramina**. The **hyomandibular foramen** pierces the chondrocranium at the anteroventral part of the otic region.

The occipital region forms the posterior part of the chondrocranium. The large median opening is the **foramen magnum**. An **occipital condyle** lies on either side and just below it. The paired condyles articulate with the first vertebra. A **vagus foramen** lies lateral to each condyle. A **glossopharyngeal foramen** lies at each ventrolateral corner of the occipital region.

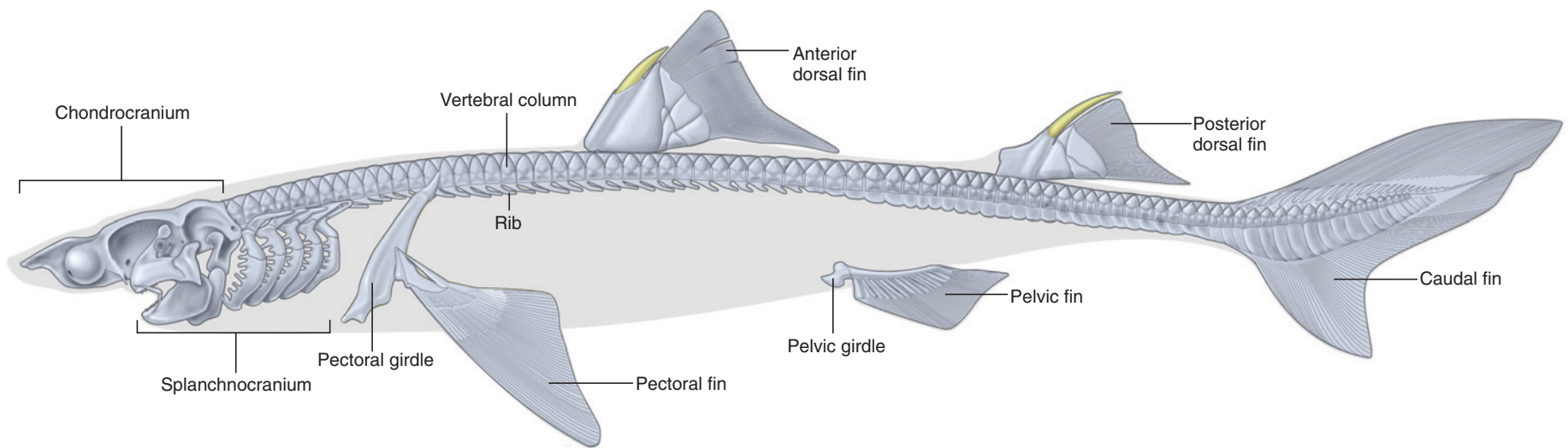
## Splanchnocranium

The splanchnocranium includes the seven visceral arches: the **mandibular arch**, **hyoid arch**, and five **branchial arches** (Figures 3.3 and 3.4). Each arch comprises various segments. The mandibular and hyoid arches are highly modified for their use as jaw elements. The branchial arches support the interbranchial septa (see Figure 3.20) and lie between successive gill slits.

The mandibular arch, the largest of the arches, forms the jaws. Paired **palatoquadrate cartilages** fuse anteriorly to form the upper jaw, which articulates with the chondrocranium. The palatoquadrate cartilage bears two prominent dorsal projections. Anteriorly, the **orbital process** contacts the medial wall of the orbit. Posteriorly, the **adductor mandibulae process** serves for the attachment of the jaw-closing musculature, the adductor mandibulae, which is considered later. The ventral half of the mandibular arch forms the lower jaws, which consists of paired **Meckel's cartilages** fused anteriorly. The slender **labial cartilage**, supporting the labial folds (see page 37), is attached to Meckel's cartilage, but may not be preserved in your specimen.

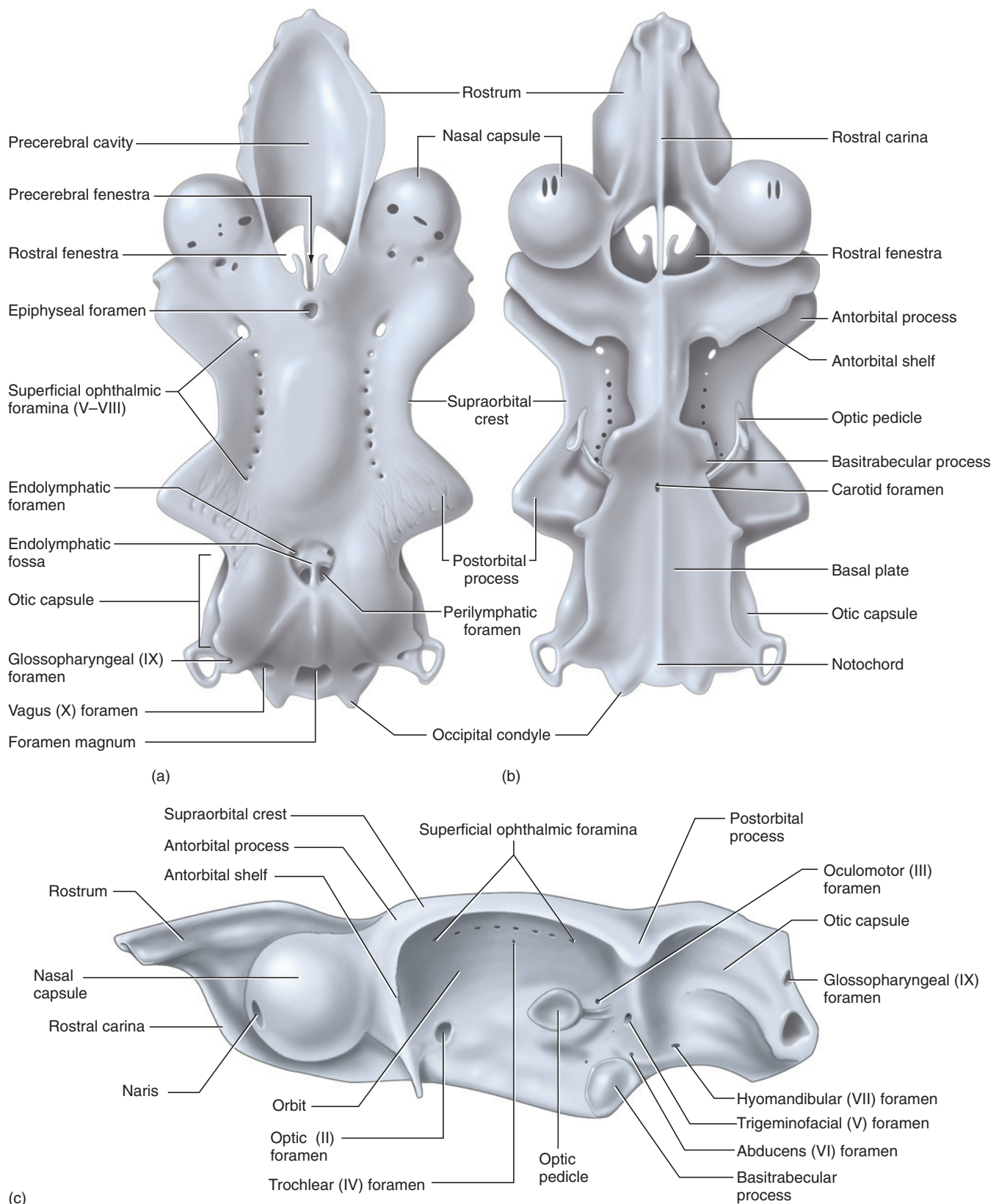
The hyoid arch is modified to support the jaws (or mandibular arch). The dorsal segment of the hyoid arch, on each side, is the **hyomandibular**, which abuts against the otic capsule. A **ceratohyal** articulates with the other end of the hyomandibular. The ceratohyals from either side articulate ventrally with the median **basihyal**. Ligamentous attachments exist between the mandibular arch and hyoid arch, which, through articulation with the otic regions, acts as a support or suspensor of the jaw.

The remaining arches are branchial arches. Each arch is formed, in dorsal to ventral order, from paired **pharyngobranchials**, **epibranchials**, and **ceratobranchials**. Ventrally the arches are completed by three paired **hypobranchials** and two median, unpaired **basibranchials**. The pharyngobranchials of visceral arches 6 and 7 are fused.

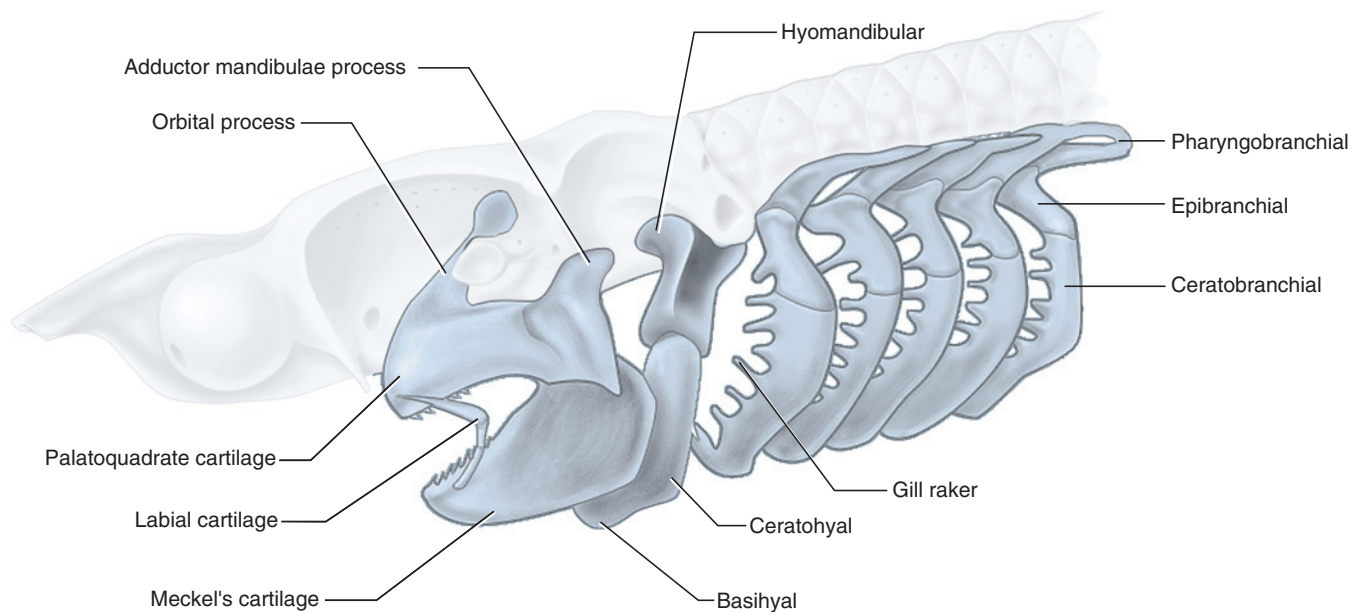


**FIGURE 3.1** Skeleton of the shark in left lateral view.

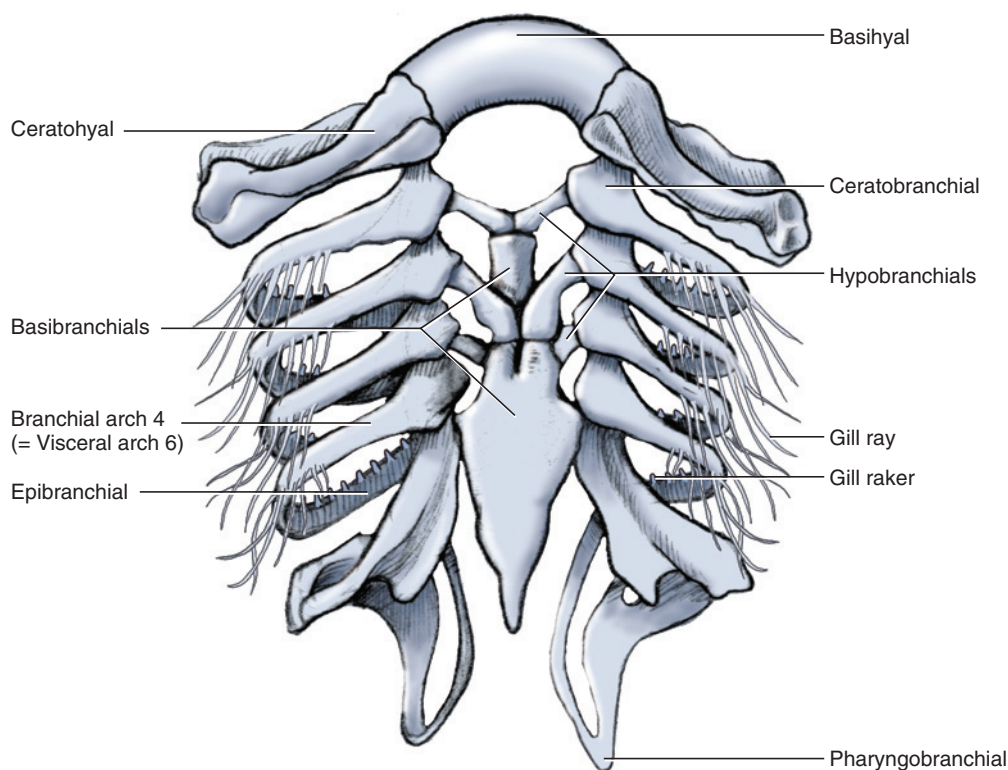




**FIGURE 3.2** Chondrocranium of the shark. a. Dorsal view. b. Ventral view. c. Left lateral view.



**FIGURE 3.3** Visceral arches of the shark in left lateral view.

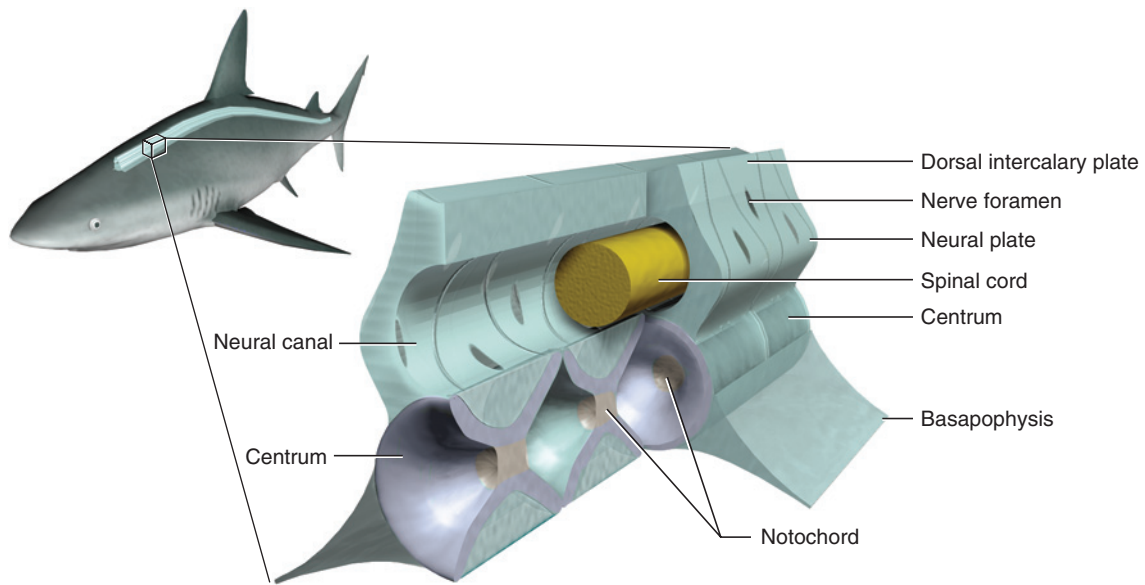


**FIGURE 3.4** Hyoid arch and branchial arches of the shark in ventral view. Note that mandibular arch, illustrated in Figure 3.3, is absent here.

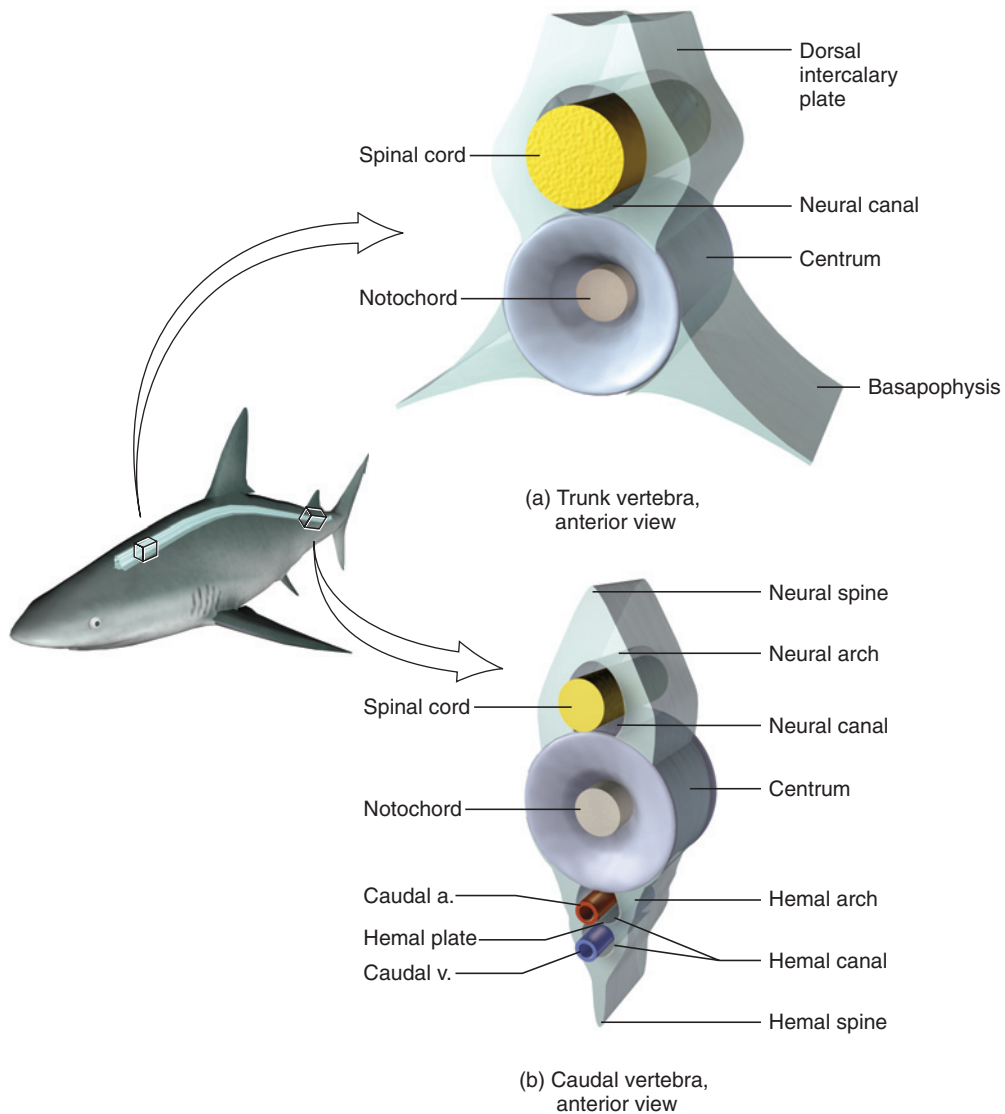
## Vertebrae and Fins

There are two vertebral types: trunk and caudal (Figures 3.5 and 3.6). Sections of these types are usually set in acrylic blocks for examination. Although the vertebral column has a dorsal passageway in both the trunk and tail, a ventral passageway is present only in the tail.

Each segment of the vertebral column is formed largely from an hourglass-shaped vertebral body or **centrum**. Notochordal tissue can be observed within the centrum in sagittal section. Dorsal to each centrum is a triangular **neural plate**, the base of which sits on the centrum. The tips of the neural plates bear a low ridge termed the **neural spine**. Between successive neural plates are

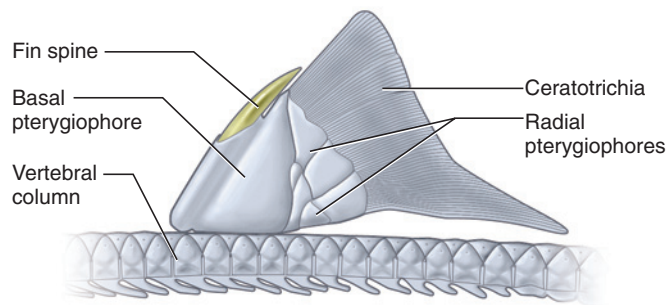


**FIGURE 3.5** Anterolateral view of sagittally sectioned and whole articulated trunk vertebrae of the shark.



**FIGURE 3.6** Vertebrae of the shark in anterolateral view. a. Trunk vertebra. b. Caudal vertebra.





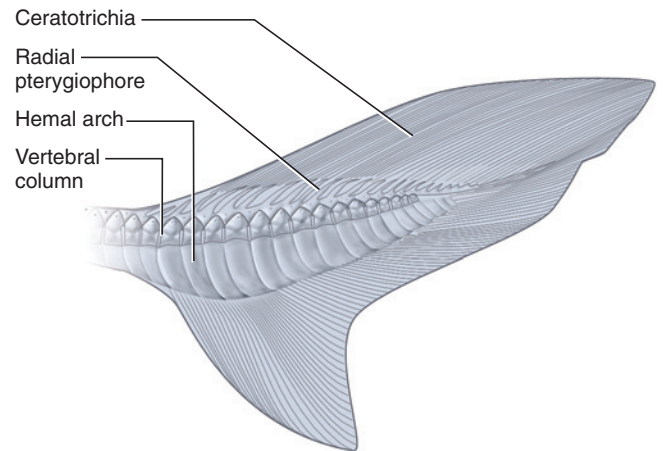
**FIGURE 3.7** Skeletal elements of the anterior dorsal fin of the shark in left lateral view.

**intercalary plates**, also triangular but inverted so that neural and intercalary plates together form the **neural arch**. The arch helps form a passageway, the **neural canal** (for passage of the spinal cord), above the centra. Each plate is pierced by a foramen for the root of a spinal nerve. A **basapophysis** projects, on either side, from the ventrolateral surfaces of the centra of the trunk vertebrae. A slender **rib** (Figure 3.1) attaches to the basapophysis.

Caudal vertebrae also bear a vertebral arch. In addition, the ventral surface of each centrum bears, on either side, a plate of cartilage that forms with its opposite number the **hemal arch**. The **hemal canal**, for the caudal artery and vein, passes within the arch. A thin horizontal partition, the **hemal plate**, may separate the passage for the artery dorsally and the vein ventrally. A **hemal spine** extends ventrally from the hemal arch.

The vertebral column helps support the anterior and posterior dorsal fins, and the caudal fin. The anterior (Figures 3.1 and 3.7) and posterior (Figure 3.1) dorsal fins are similar in structure. Each has a large proximal **basal pterygiophore**, to which the **fin spine** is anchored anteriorly. More distally are a series of **radial pterygiophores** and, finally, the **ceratotrichia**, which are fibrous dermal rays, rather than cartilaginous elements. The **caudal fin** (Figure 3.8) is of the heterocercal type—symmetric, with the vertebral axis curving into the dorsal half of the fin. It is supported proximally by the hemal arches and radial pterygiophores.

The paired appendages, the pectoral and pelvic fins, are supported by cartilaginous girdles. The **pectoral girdle** (Figure 3.9) includes a stout, U-shaped cartilage to which the fins attach on either side. The portion between the fins is the **coracoid bar**, and the part extending dorsally past the attachment of each fin is the **scapular process**. The area that articulates with the fin is the **glenoid surface**. A separate slender element, the **suprascapular cartilage**, attaches dorsally to each scapular process. The pectoral fin (Figures 3.9 and 3.10) has proximal basal and radial pterygiophores, followed by ceratotrichia. Three basals are recognized: the **proptery-**



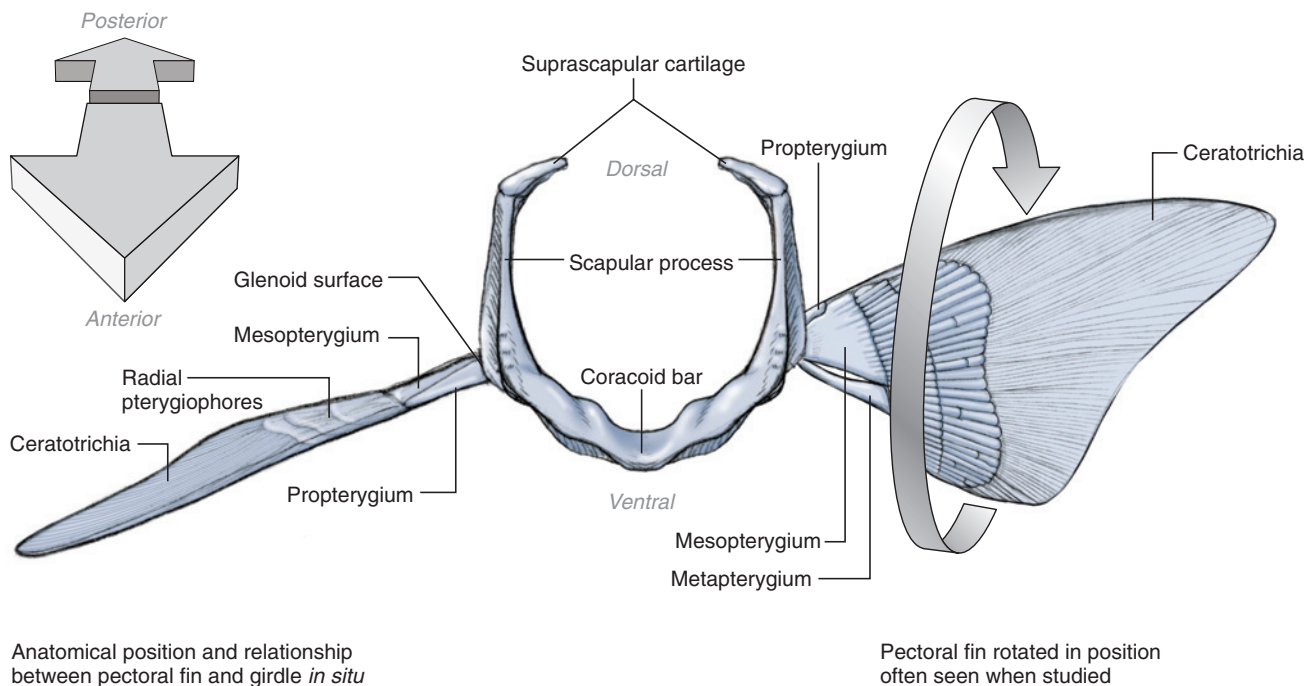
**FIGURE 3.8** Skeletal elements of the caudal fin of the shark in left lateral view.

**gium**, **mesopterygium**, and **metapterygium**, in anterior to posterior order. The glenoid surface of the fin is borne mainly by the mesopterygium. The radials of the pectoral fin are rod-like structures, more regularly shaped than in the median dorsal fins, and are arranged in rows.

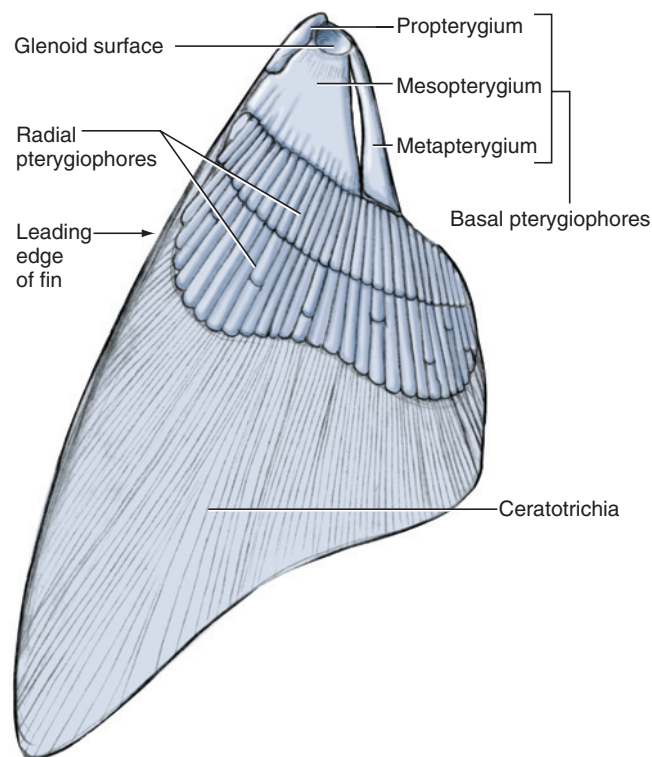
The pelvic girdle (Figure 3.11) consists of a single element, the **puboischiadic bar**. The pelvic fins articulate on either end of the bar at the **acetabular surfaces**. An **iliac process** lies near each acetabular surface. The pelvic fin of the female and male are similar in bearing a short **propterygium** and a stout, elongated **metapterygium** that extends posteriorly (Figure 3.11). A row of cylindrical radial pterygiophores articulates mainly with the metapterygium and supports the ceratotrichia. The pelvic fin of the male differs in bearing a **clasper**, formed from modified radials, that functions in the intromission of sperm into the cloaca of the female. The clasper extends posteriorly from the metapterygium and bears a **hook** and **spine** distally (Figure 3.11a).

### KEY TERMS: SKELETON

abducens foramen	branchial arches
acetabular surfaces	caudal fin
adductor mandibulae process	centrum (vertebral body)
anterior dorsal fin	ceratobranchials
antorbital process	ceratohyal
antorbital shelf	ceratotrichia
basal plate	chondrocranium
basal pterygiophore	clasper
basapophysis	coracoid bar
basibranchials	endolymphatic foramina (sing., foramen)
basihyal	
basitrabecular processes	



**FIGURE 3.9** Pectoral girdle and skeletal elements of pectoral fins of the shark in anterior view.



**FIGURE 3.10** Skeletal elements of the left pectoral fin of the shark in dorsal view.

endolymphatic fossa (plur., fossae)

epibranchials

epiphyseal foramen

fin spine

foramen magnum

glenoid surface

glossopharyngeal foramen

hemal arch

hemal canal

hemal plate

hemal spine

hook of clasper

hyoid arch

hyomandibular

hyomandibular foramen

hypobranchials

iliac process

intercalary plates (interneural arch)

labial cartilage

mandibular arch

Meckel's cartilage (mandibular cartilage)

mesopterygium

metapterygium

nares (sing., naris)

nasal capsules

neural canal (vertebral canal)

neural plate

neural spine

occipital condyle

oculomotor foramina (sing., foramen)

optic foramen

optic pedicle

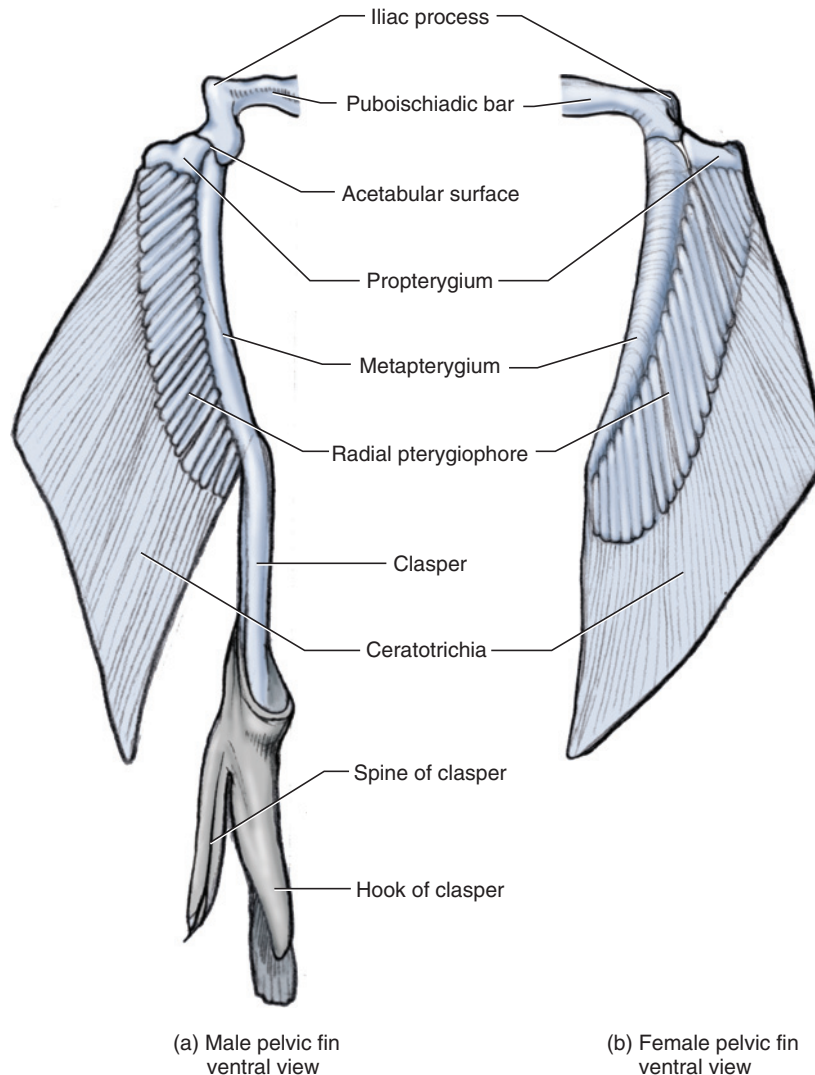
orbital process

otic capsules

palatoquadrate cartilages

pectoral fins

pectoral girdle



**FIGURE 3.11** Skeletal elements of the pelvic fin of the shark in dorsal view. a. Left fin of the male. b. Right fin of the female.

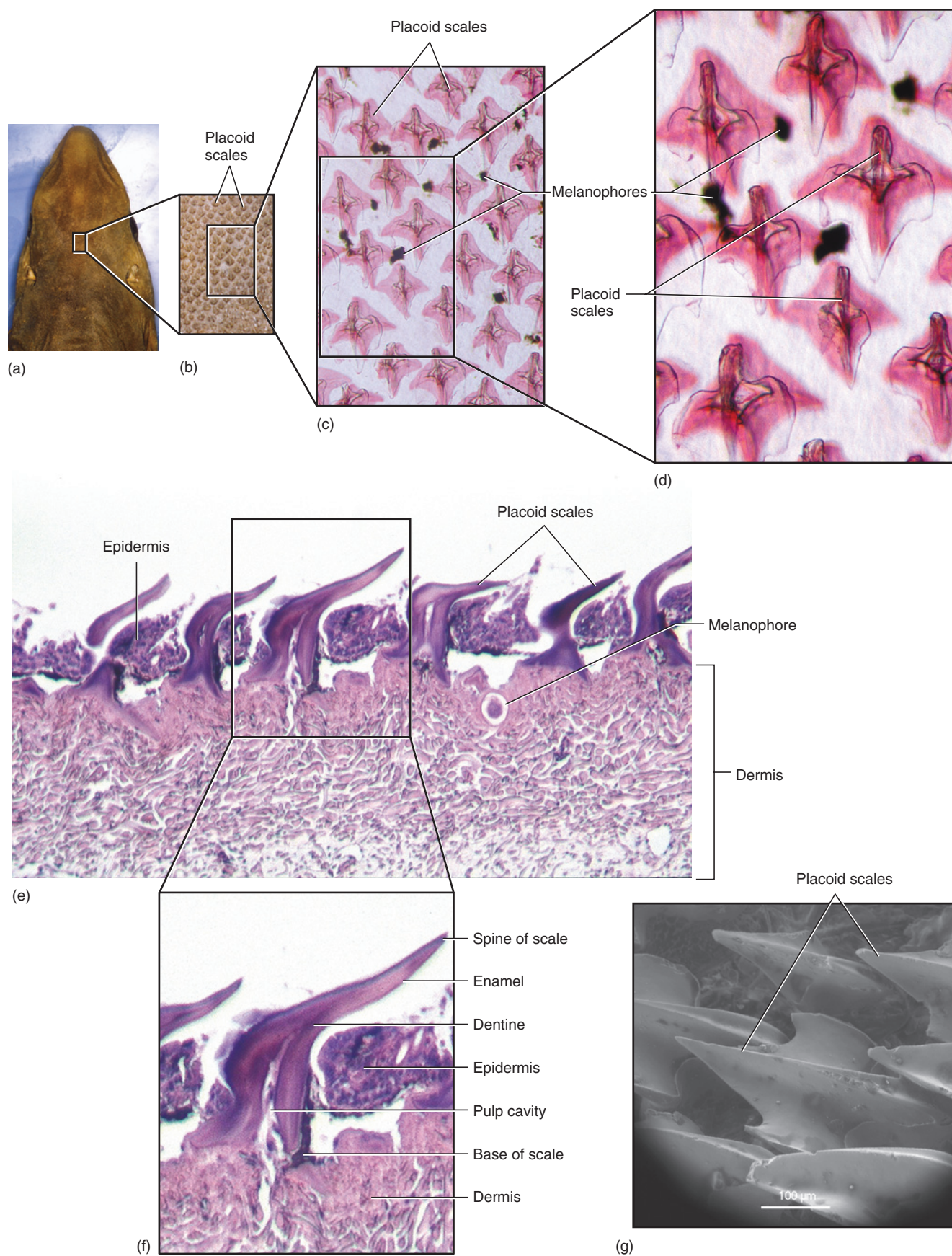
pelvic fins  
pelvic girdle  
perilymphatic foramina  
pharyngobranchials  
posterior dorsal fin  
postorbital process  
precerebral cavity  
precerebral fenestra  
propterygium  
puboischiadic bar  
radial pterygiophores  
rib  
rostral carina  
rostral fenestra (plur.,  
fenestrae)

rostrum  
scapular process  
spine of clasper  
splanchnocranium  
superficial ophthalmic  
foramina  
supraorbital crest  
suprascapular cartilage  
trigemino-facial foramen  
trochlear foramen  
vagus foramen  
vertebral arch  
vertebral column

## SECTION II—EXTERNAL ANATOMY

The integument of sharks is relatively thin. It is subdivided into dermis and epidermis, but the latter is not keratinized and comprises a layer of live cells, which, in life, is covered by mucus. As noted earlier, bone is almost entirely absent in sharks, and so they lack extensive bony coverings. However, **placoid scales** or denticles are embedded in the skin (Figure 3.12a). A scale is built like a tooth, formed from dentine, covered by enamel, and containing a pulp cavity (Figure 3.12b). Such scales, which reduce the drag of water passing over the skin during swimming, are uniformly distributed over the skin and can be seen under low magnification, but their presence can be felt by running your hand over the skin. The integument also contains various specialized cells, such as melanophores that control pigmentation of the skin and secretory cells, but these cannot be seen grossly.





**FIGURE 3.12** Skin of the shark. a.–d. Successive blowups of the surface of the skin to show structure of scales. e.–f. Vertical section through skin and scales. g. SEM image of skin showing scales. *Source:* Dr Steven Campana, Bedford Institute of Oceanography, Canada.

The body regions (Figure 3.13) of the shark, and fishes in general, are not as neatly differentiated as in tetrapods. This is due to the elongated and fusiform body, which facilitates movement through the water. The **head** extends posteriorly to the end of the pharyngeal slits and includes the laterally placed **eyes**. The **nares** (sing. **naris**) lie ventrolaterally on the tapered **snout**. Examine a **naris** closely, and note that it is incompletely subdivided by a flap of skin into incurrent and excurrent apertures (see Figure 3.18). The naris leads into the blind-ended **olfactory sac** (see Figure 3.41). The ventrally located **mouth** is supported by upper and lower jaws that have rows of sharp teeth. A **labial pocket** lies on either side of the mouth (Figures 3.13 and 3.18). Mouth and pocket are separated by a flap, the **labial fold**, which is supported by the labial cartilage. The **spiracle** is a relatively large opening into the pharynx and lies directly posterior to each eye. Its anterior wall contains a fold of tissue, the **spiracular valve**, that can be folded over the opening to close the spiracle. The valve bears a **pseudobranch**, a reduced gill, on its posterior surface. A row of five **pharyngeal slits**, separated by four **interbranchial septa** (Figure 3.13), lie posterolaterally on either side and lead into the pharynx. The slits are the means by which water leaves the pharynx as it passes over the respiratory structures or gills. Manipulate the interbranchial septa and note that on its anterior and posterior surfaces each carries **gill lamellae** (see Figure 3.23), which are injected with red latex. Note that lamellae are present on the anterior wall of the first slit, but not on the posterior wall of the last slit.

The **trunk** follows the head and extends posteriorly to the midventrally located **cloaca** (Figure 3.14), a large chamber into which the urinary, reproductive, and digestive tracts exit. Pull the pelvic fins laterally to expose the cloaca more clearly. In the male (Figure 3.14a), the genital ducts and urinary ducts open at the tip of the **urogenital papilla**, a large cone-like structure lying in the cloaca. A similar structure occurs in females (Figure 3.14b), but as only the urinary ducts open at its tip, it is termed the **urinary papilla**. The **anus**, the posterior opening of the digestive tract, opens into the cloaca anterior to the papilla; you will see this presently. Locate the **abdominal pores**, one each on the posterolateral side of the cloaca (Figure 3.33). The pores extend into the pleuroperitoneal cavity and may allow removal of excess fluid from the cavity.

The median **anterior dorsal fin** (Figure 3.13) lies mid-dorsally on the trunk and carries a sharp spine anteriorly. The paired large **pectoral fins** lie anteriorly, just behind the gill slits, while the paired **pelvic fins** lie at the end of the trunk, one on either side of the cloaca. In the male an elongated, cylindrical, and dorsally grooved **clasper**, a copulatory organ, lies between the cloaca and pelvic fin (Figure 3.14a).

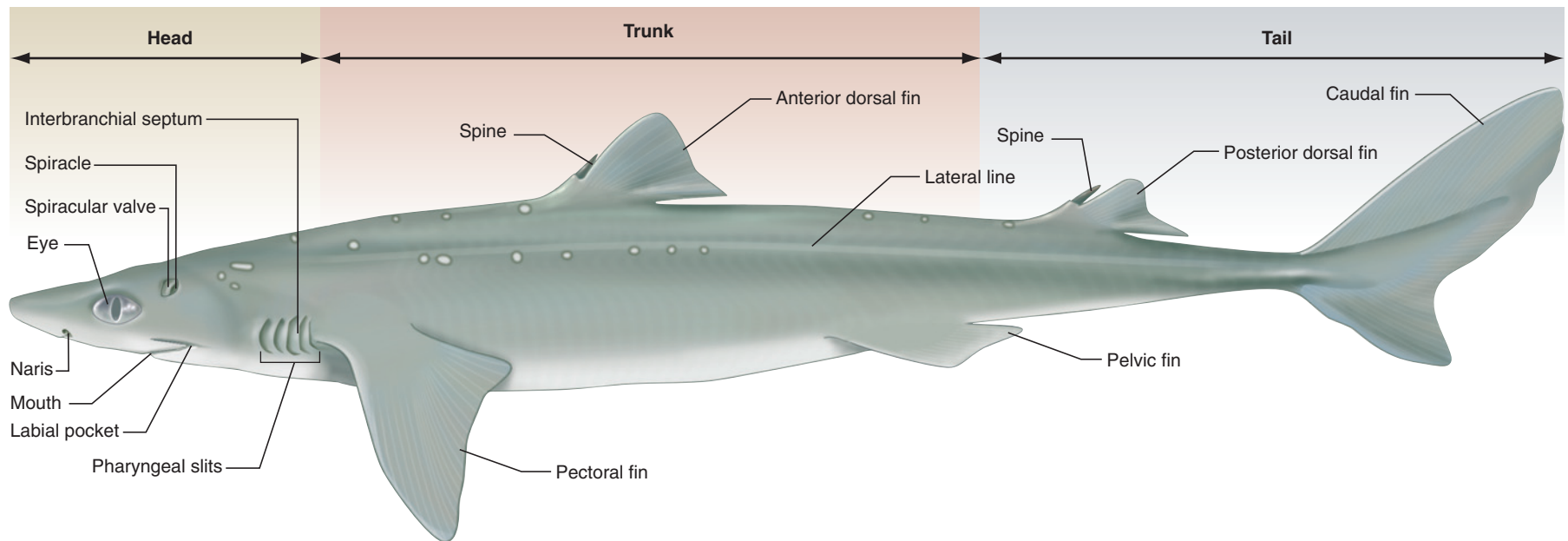
The **tail** (Figure 3.13) extends posteriorly from the cloaca and carries the well-developed **caudal fin**. Lateral undulations of the tail and caudal fin produce the propulsive force that moves the shark forward. The **posterior dorsal fin**, another medial fin, lies at the anterior part of the tail and also has an anterior spine. The spiny dogfish, the common name of *Squalus acanthias*, is derived from the presence of the spines on the anterior and posterior dorsal fins.

Examine the lateral surface of the body, just dorsal to the midlateral plane, and note the faint, pale stripe extending anteroposteriorly. It marks the position of the **lateral line canal** (Figure 3.13), a cutaneous tube that contains sensory nerve endings and opens to the surface by way of tiny pores. The lateral line canal is the predominant part of the lateral line system, a system of sensory cells responsive to pressure changes caused by vibrations and movements in the water. The distribution of this system into the head and other parts of the body will be considered later. The lateral line system is modified to provide two other functions. The balancing apparatus is contained within the otic capsule of the chondrocranium. It is mentioned here because this system is connected to the surface by a pair of endolymphatic ducts (recall the endolymphatic foramina, page 28) that open through the **endolymphatic pores** (Figure 3.15). These lie mid-dorsally on the head between the levels of the eyes and spiracles. The second modification consists of the **ampullae of Lorenzini**, which function in electroreception. The ampullae open in numerous pores on the dorsal and lateral surface of the head and may be noted by gently squeezing these regions to extrude a gel-like substance.

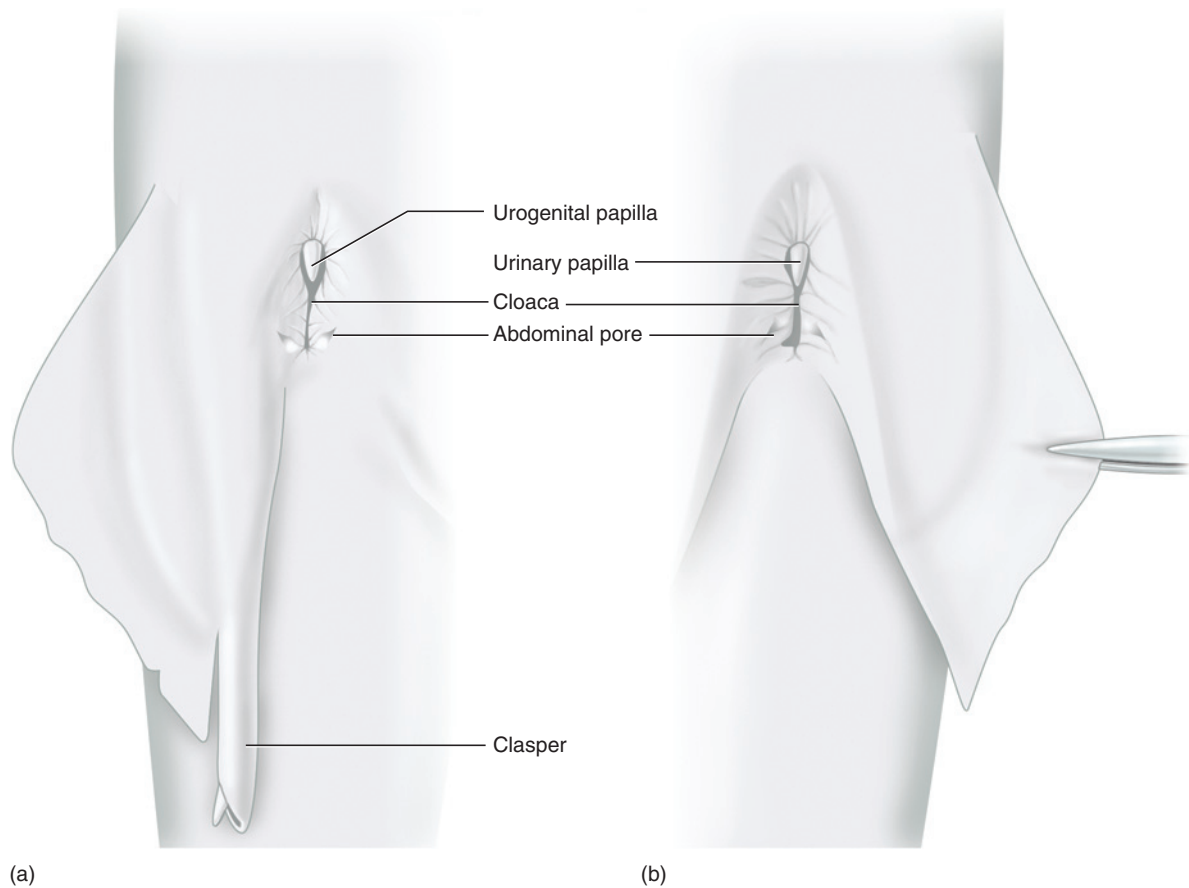
### KEY TERMS: EXTERNAL ANATOMY

abdominal pores	naris (plur., nares)
ampullae of Lorenzini	olfactory sac
anterior dorsal fin	pectoral fins
anus	pelvic fins
caudal fin	pharyngeal slits
clasper	placoid scales
cloaca	posterior dorsal fin
endolymphatic pores	pseudobranch
eyes	snout
gill lamellae	spiracle
head	spiracular valve
interbranchial septa	tail
labial fold	trunk
labial pocket	urinary papilla
lateral line canal	urogenital papilla
mouth	





**FIGURE 3.13** External features of the shark in left lateral view.



**FIGURE 3.14** Ventral view of posterior portion of the shark to show cloaca and pelvic fin. a. Right side of the male. b. Left side of the female.

### SECTION III—MUSCULAR SYSTEM


Study of the musculature requires that the skin be removed. There are various techniques that allow efficient skinning. One of these is that a scalpel, in most cases, be used as little as possible. Remember that dissection does not have as its goal the frequent use of a scalpel, as many students would like to believe. Instead, one may recognize skill in dissection by selection of the proper implement for the task at hand. The scalpel has limited application. It may be used to cut the skin and then to help reflect it. In the latter procedure, the scalpel should be used in a sideways scraping motion. Turning the blade axially 180° and using its point as a pick can also be very effective. Its cutting edge should rarely be used in separating skin from underlying body structures.

#### Trunk and Appendicular Muscles

The trunk musculature is considered first for various reasons: It is relatively easy to examine as an introduction to the musculature; it comprises the bulk of the musculature of the body; and the procedure will give

you practice in skinning a region where mistakes and inexperience will not produce serious damage.

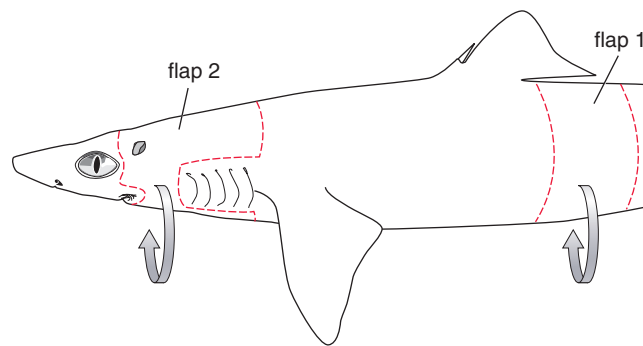
Peel back a strip of skin, about 10 cm in width, from one side of the trunk region just posterior to the anterior dorsal fin (Figure 3.16, flap 1). Cut with a scalpel three sides of a rectangular section of skin. Begin the incisions middorsally and continue ventrally down the body to the midventral plane. The skin is thin, so cut carefully to avoid damaging underlying structures. Do not cut the fourth side. This will produce a flap of skin that can be wrapped around exposed tissues at the end of a lab period to help protect them. After cutting the edges of the flap, lift one corner and begin to pull the skin away from the trunk musculature. As the skin begins to pull away, scrape the connective tissue between skin and muscles. Use the non-cutting edge of your scalpel, as described above. Skin will come off easily in some spots but will stick in others because muscle fibers attach directly to the dermis. Patiently scrape the muscle fibers from the inside of the skin toward the body with a scalpel. In some areas, a probe or the ends of narrow forceps will suffice.



**FIGURE 3.15** Enlarged views of the surface of the skin of the shark. a. Ampullae of Lorenzini. b. Endolymphatic pores.

Once flap 1 is reflected, notice that the trunk musculature is divided into the dorsal **epaxial musculature** and the ventral **hypaxial musculature** by the **horizontal skeletogenous septum**, a connective sheet lying in the frontal plane (Figure 3.17). Each of these primary divisions consists of longitudinally segmented, Z-shaped **myomeres**, separated by connective tissue sheets termed **myosepta**. The **linea alba** is connective tissue separating left and right myomeres midventrally (Figures 3.18 and 3.19). The myomeres are complex internally, extending further anteriorly and posteriorly than their margins at the surface of the body.

To examine the appendicular muscles, skin portions from the dorsal and ventral surfaces of a pectoral fin and note the musculature revealed. The **pectoral abductor** lies dorsally (Figure 3.17) and the **pectoral adductor** lies ventrally (Figure 3.18). *Abductor* and *adductor* are terms that describe the actions of muscles. Abductor muscles pull a structure away from the midventral line; adductor muscles pull toward the midventral line. The pelvic adductor and abductor may be found associated with the pelvic fin. However, be careful if you decide to remove the skin from the ventral surface of the pelvic



**FIGURE 3.16** Sketch of the shark in left lateral view showing guidelines for cutting the skin.

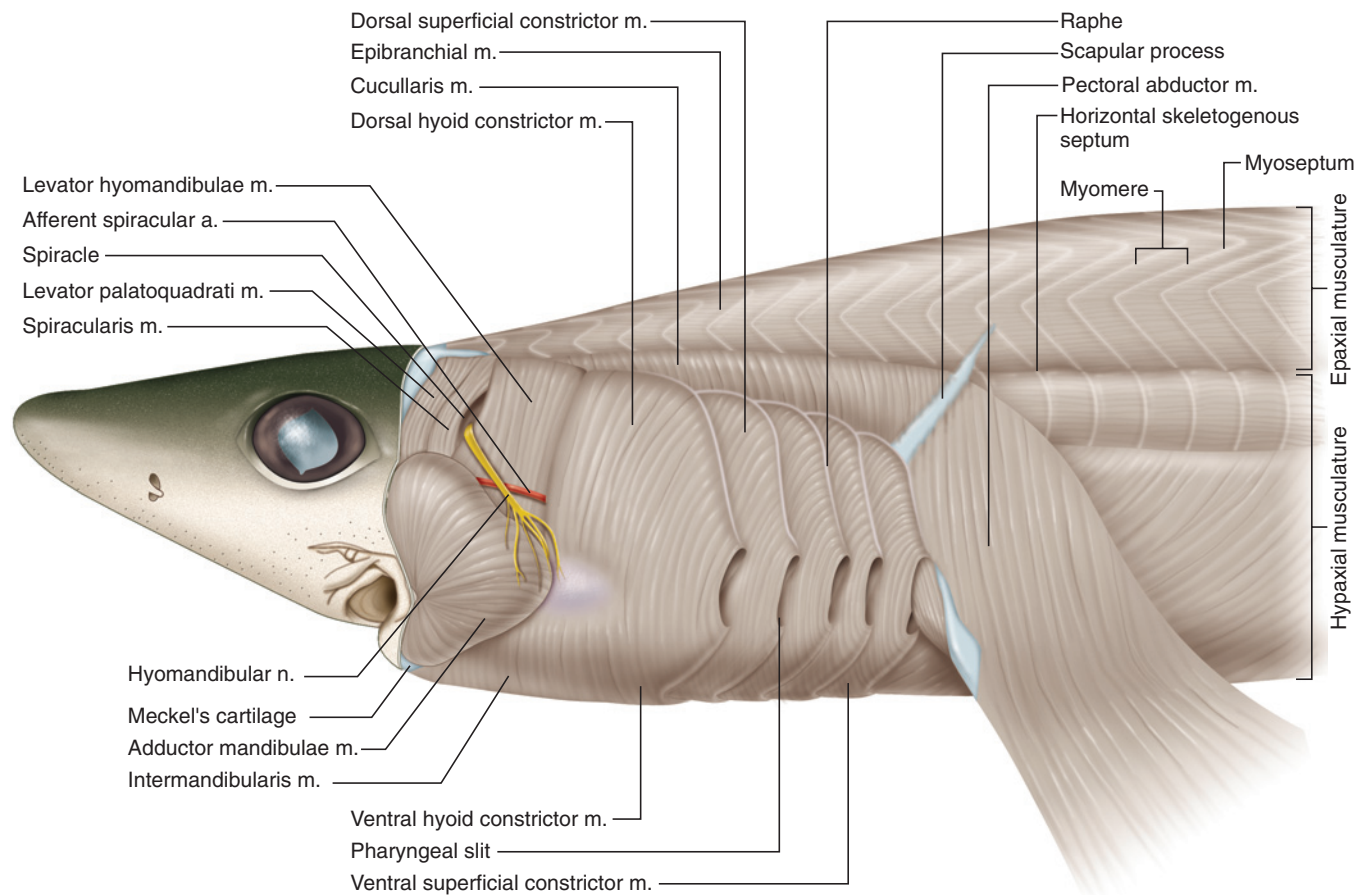
fin of a male. The **siphon** (see page 62; Figure 3.33), a structure associated with the reproductive system, lies on the ventral surface of the fin musculature.

### Muscles of the Head and Branchial Region

Examine next the musculature of the head and branchial region. Ideally, the head would be skinned from snout to the pectoral girdle, but this is not necessary. Instead, skin only half the head (as in Figure 3.16, flap 2). Make an incision through the skin middorsally between the eyes that extends posteriorly to the level of the pectoral fin. Continue the incision ventrally to the dorsal edge of the fifth pharyngeal slit. The skin may be removed from around the pharyngeal slits, but this is difficult and time-consuming, as the skin adheres tightly here. This effort can be avoided without missing much anatomical detail by leaving a rectangular flap around the slits, as follows (Figure 3.16, flap 2). From the fifth slit, cut anteriorly to the first slit, ventrally along the anterior margin of this slit, and then posteriorly to the ventral end of the fifth slit. Continue the incision ventrally around the body to about 2 cm past the midventral line. Do not cut midventrally. Return to the beginning of the incision between the eyes and cut posteroventrally around the eye to the angle of the mouth. Proceed along the edge of the jaw until you reach ventrally approximately to the same level as the posterior cut. Separate the skin from the body using the methods described above for the axial musculature.

### Branchiomic Musculature

On exposing the musculature, view the shark in lateral view (Figures 3.17 and 3.37) and locate the spiracle. There are two muscles anterior to it, but careful dissection is required to separate them, so proceed cautiously. The small **spiracularis** is on the anterior wall of the spiracular valve. The larger **levator palatoquadrati** lies anterior to it. The muscles pass from the otic capsule to the upper jaw and serve to lift or stabilize it. The **levator hyomandibulae** lies posterior to the spiracle (Figures



**FIGURE 3.17** Head, branchial region, and anterior part of the trunk of the shark in left lateral view, skinned to reveal musculature.

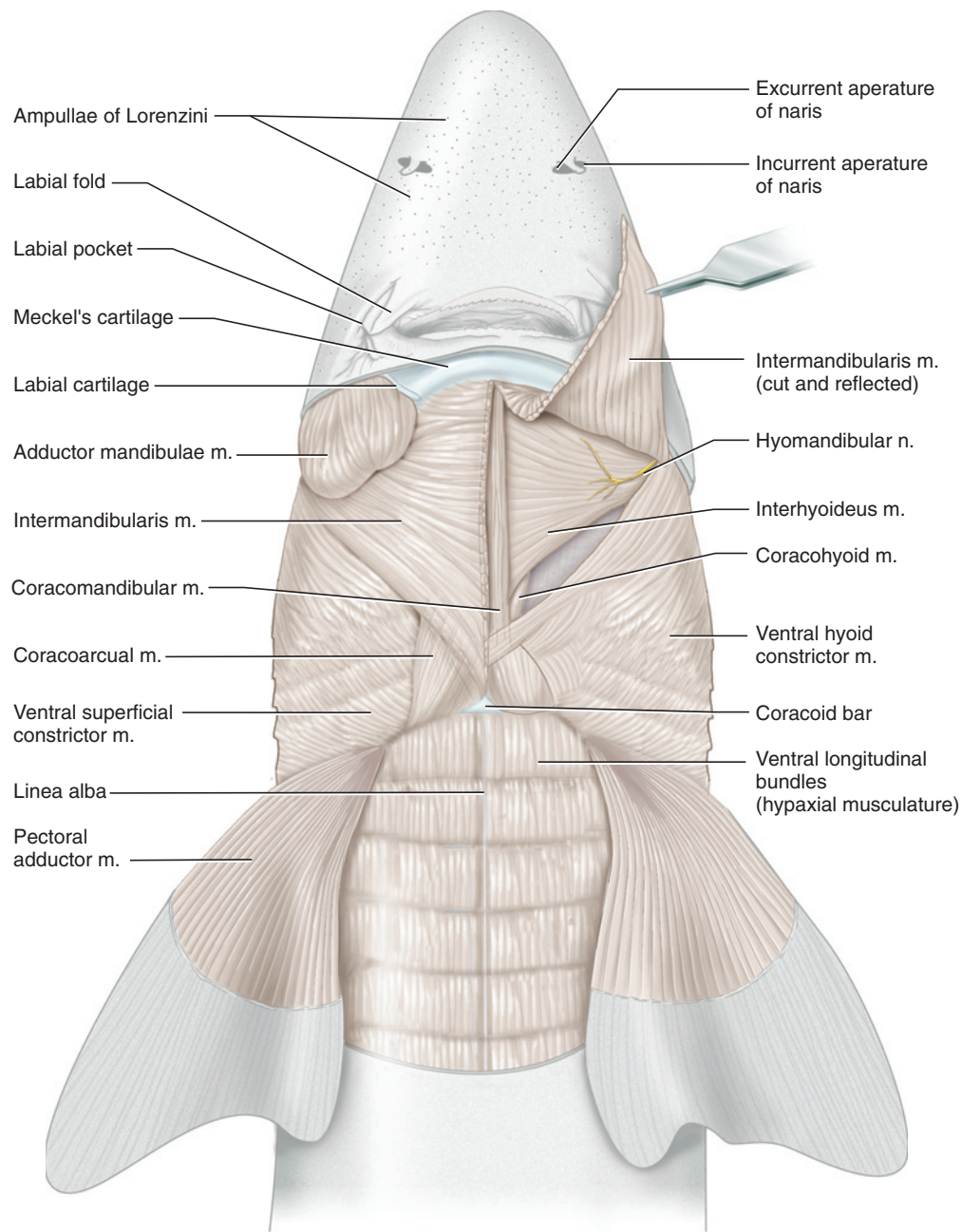
3.17 and 3.37). It extends between the otic capsule and hyomandibular and compresses the pharyngeal pouches. Ventral to these muscles and just posterior to the angle of the mouth is the large **adductor mandibulae**, which extends between upper and lower jaws and closes the mouth (Figures 3.17 and 3.18). Two other structures may be noted briefly at this time. The conspicuous **hyomandibular nerve** passes across the posterior part of the levator hyomandibulae toward the spiracle. The **afferent spiracular artery** passes deep to the nerve, and should be injected with red latex.

Posterior to the muscles just discussed are the five superficial constrictors, comprising a block of muscles that surrounds the pharyngeal slits (Figures 3.17–3.19). The constrictors are subdivided into dorsal and ventral portions. They are arranged sequentially from front to back and separated by vertical connective tissue partitions termed **raphes**, which look like white lines on the muscle surface. The first constrictor, more complex than the others, includes the **dorsal and ventral hyoid constrictors**, which lie between the adductor mandibulae and the first pharyngeal slit. Raphes extending dorsally and ventrally from the first slit separate the hyoid constrictors

from the first of four superficial constrictors. The **dorsal and ventral superficial constrictors**, properly constrictors 3–6, are similar in form and extend between the raphes associated with each slit. The constrictors, which compress the branchial region, extend medially. Superficially, however, they overlap one another so that only their outermost portions are visible. The triangular **cucullaris** lies dorsal to the constrictors. Dorsal to the cucullaris are the dorsal longitudinal bundles of the **epibranchial** muscles, which attach anteriorly to the back of the chondrocranium and represent the anterior continuation of the epaxial musculature into the head. The cucullaris arises from fascia covering the longitudinal bundle and inserts on the epibranchial of each branchial arch and the scapular process of the pectoral girdle.

Examine the ventral surface of the shark (Figure 3.18). The **intermandibularis** lies between the Meckel's cartilages. Composed of left and right halves separated mid-ventrally by a raphe, the fibers of the intermandibularis run posteromedially from mandibular Meckel's cartilage toward the midline. The muscle is some 2 mm thick, but posteriorly it may be lifted from the underly-



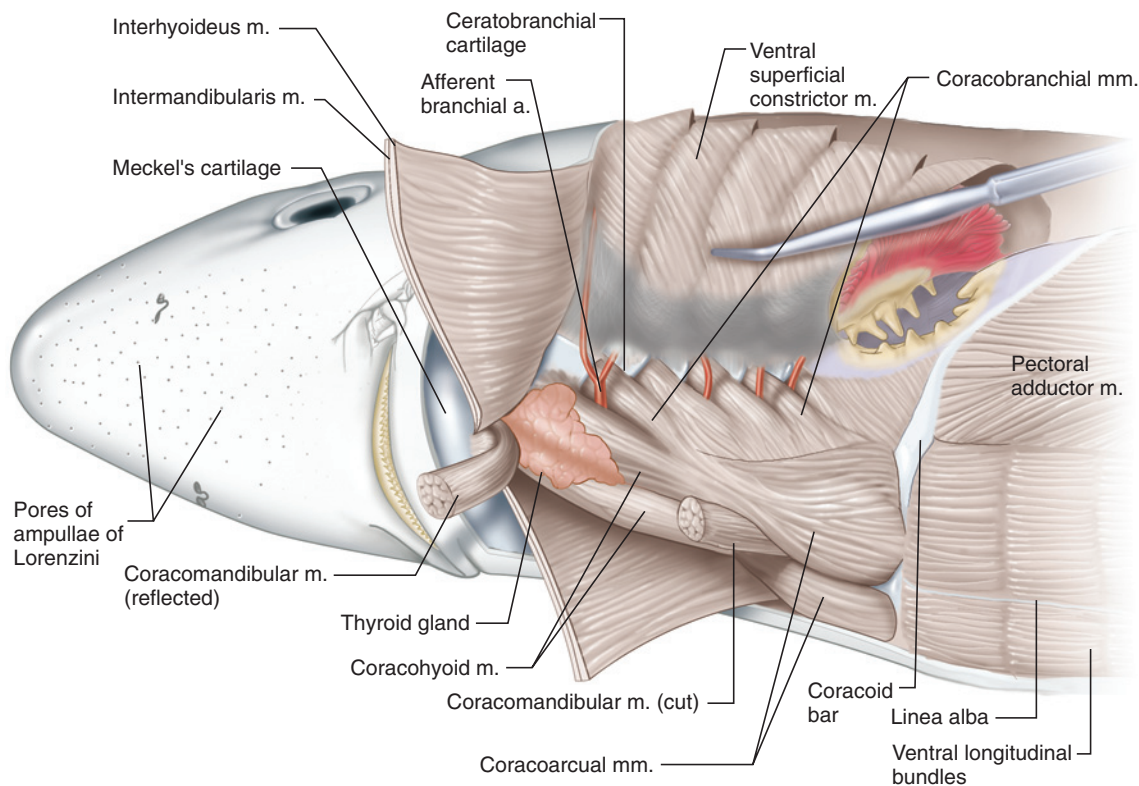


**FIGURE 3.18** Branchial region and anterior part of the trunk of the shark in ventral view, skinned to reveal musculature.

ing muscle. Carefully cut through the intermandibularis parallel to and about 2–3 mm to one side of the raphe. A second, thin, and less extensive muscular sheet lies deep to it. This is the **interhyoideus** which, as its name implies, extends between the cartilages of the hyoid arch, specifically the ceratohyals. The muscle adheres tightly to the intermandibularis. It is difficult to separate them, but attempt to do so from the anterior end of the interhyoideus. The fibers of the interhyoideus are less obliquely oriented and do not extend as far anteriorly as the intermandibularis. The hyomandibular nerve may be seen lying ventrolaterally on the interhyoideus

(Figure 3.18). If it becomes too difficult and time-consuming to separate the muscles, you may instead view the interhyoideus by cutting through it as well and reflecting the sheets (Figure 3.19).

The muscles discussed in this section are part of the branchiomeric musculature (there are others, but they lie more deeply and will be studied shortly). Now that their distribution has been noted, their relationships may be summarized. The muscles are each associated with particular visceral arches. Presumably in early vertebrates there were at least seven such arches, each



**FIGURE 3.19** Branchial and hypobranchial musculature of the shark in ventrolateral view.

supporting a muscular septum that lay between pharyngeal slits. The musculature was probably a repeating series of units, one for each arch, with each in the series resembling the relatively simple arrangement of a typical branchial arch in the shark. During the evolution of jawed vertebrates, the two most anterior arches were modified into the mandibular arch, which forms the upper and lower jaws, and behind it, the hyoid arch, which supports the jaws. The musculature associated with these arches was thus modified to meet the new functions of these arches. In the shark, the muscles of the mandibular arch are the levator palatoquadrati, spiracularis, adductor mandibulae, and intermandibularis. The levator hyomandibulae, hyoid constrictors, and interhyoideus belong to the hyoid arch. Each of the branchial arches, except for the last, has the typical constrictor setup that has just been described. The constrictors are differentiated into various parts; only the more superficial portions have been examined so far.

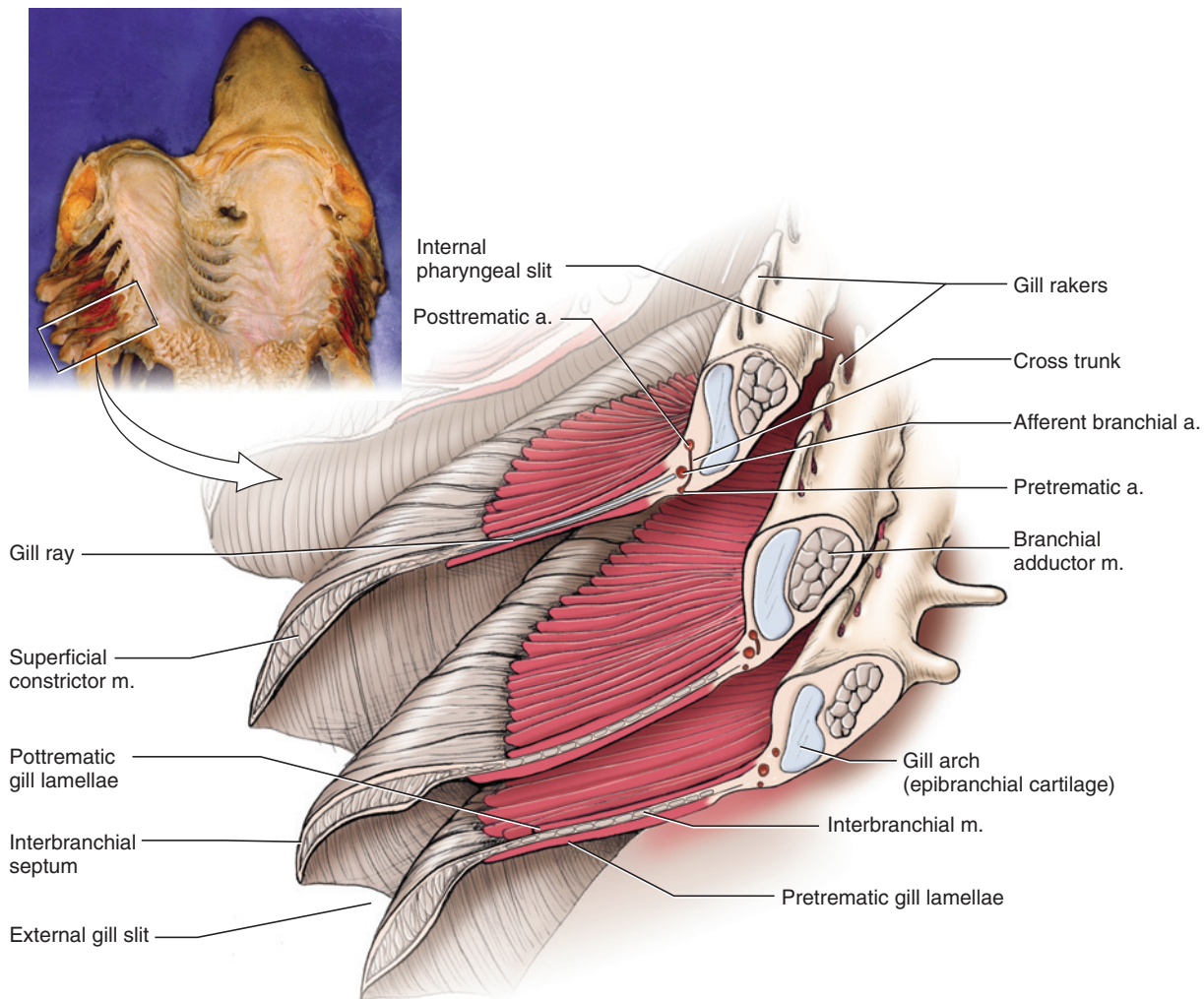
The deeper portions require further dissection. Insert scissors into the third slit and cut vertically through the dorsal and ventral superficial constrictors so that the slit may be spread open. You will thus be able to view the interbranchial septa of the third and fourth branchial arches. Compare your specimen with Figures 3.20 and 3.23. Note that most of each septum is covered by gill lamellae. This portion of the septum is formed by the **interbranchial** muscle. Its fibers are circularly

arranged. Carefully remove, by scraping, the lamellae from one septum to see them. The interbranchial is a deep portion of the constrictor musculature, and the superficial branchial constrictor lies lateral to it. Next snip frontally and completely through the middle of a septum and locate the cartilaginous arch. The small circular section of muscle that has been cut is the **branchial adductor**, a short muscle extending between the ceratobranchial and epibranchial that represents a deep derivative of the constrictor sheet.

Using a probe, separate the epibranchial musculature from the cucullaris and levator hyomandibulae and push these regions apart to expose the anterior cardinal sinus, which is part of the cardiovascular system (Figure 3.21). On the medial side of the sinus lie the dorsal surfaces of the branchial arches. Pick away connective tissue to expose the muscles, but do not injure the nerves that lie in this region. Find two sets of small, thin muscles. The strap-like and elongated **dorsal interarcuals** lie between successive pharyngobranchial cartilages of branchial arches 1–4. Lateroventral to these lie the shorter and wider **lateral interarcuals**, which run between the epibranchial and pharyngobranchial cartilages of each of branchial arches 1–4.

### *Hypobranchial Musculature*

Return to the ventral surface (Figures 3.18 and 3.19). If you have not already cut through the interhyoideus, do



**FIGURE 3.20** Section through branchial septa of the shark.

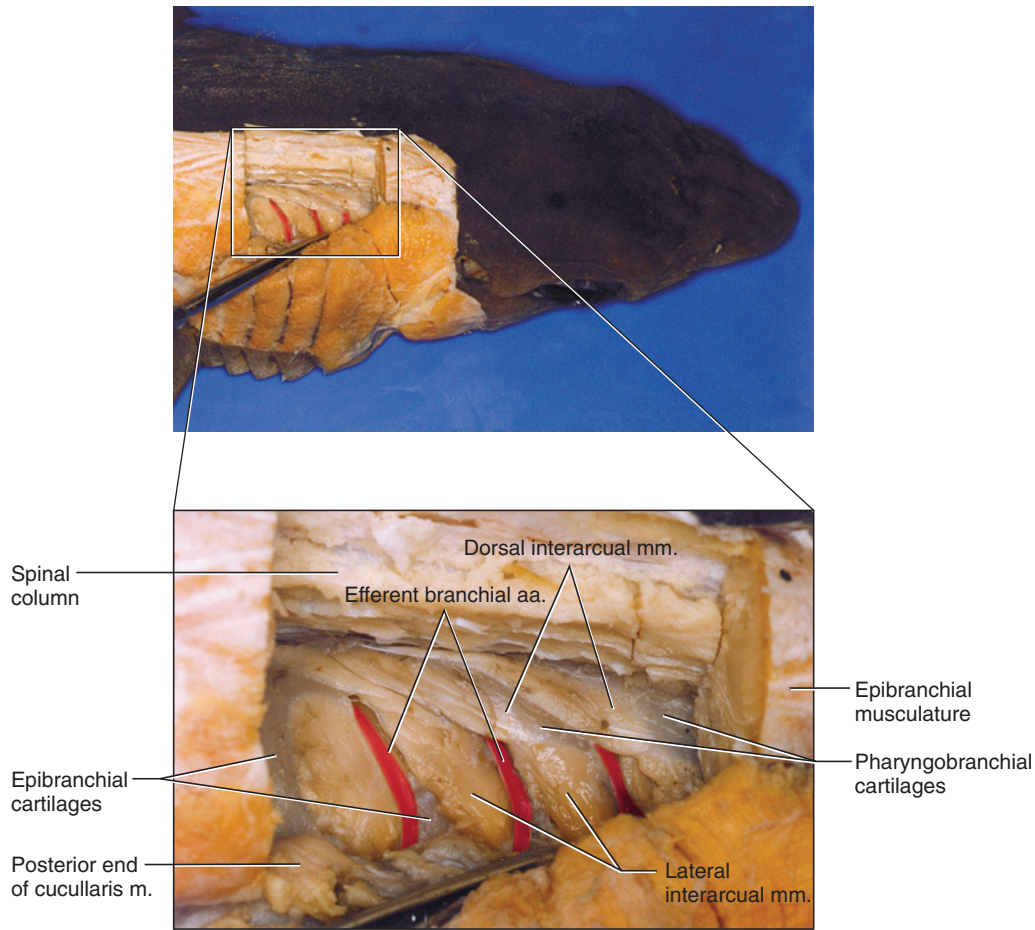
so now and reflect it. The muscles visible between the hypaxial muscles and the lower jaw constitute nearly all of the hypobranchial musculature. They may be divided into a prehyoid group, including the **coracomandibular**, and posthyoid group (see below). The coracomandibular is the long, midventral, and nearly cylindrical muscle exposed on reflection of the intermandibularis and interhyoideus. It extends between the lower jaw and the muscles posterior to it, which attach to the coracoid bar. Cut the coracomandibular near its posterior end, reflect it, and note the dark, pinkish thyroid gland deep to the muscle's anterior end (Figure 3.19).

The remaining muscles belong to the posthyoid group. Deep to the coracomandibular lie the elongated, paired **coracohyoids** (Figures 3.18 and 3.19), which insert anteriorly on the basihyals. Posteriorly the coracohyoids are continuous with the broader, nearly triangular **coracoarcuals**, which lie medially between the ventral superficial constrictors and anterior to the hypaxial

musculature. Cut the ventral superficial branchial constrictor by snipping, on the same side that is skinned, from the last branchial slit to (but NOT through) the posterolateral end of the coracoarcual. Then dissect forward between the coracoarcual and ventral superficial constrictor to separate these muscular regions. Spread them apart to reveal the **coracobranchials** (Figure 3.19), a series of five muscles that fan out from the coracoid bar, the coracoarcuals and the walls of the pericardial cavity to the ceratobranchial and basibranchial cartilages. Do not attempt to dissect these muscles at this point; doing so would require the removal and destruction of structures that have yet to be seen.

The names of the hypobranchial muscles contain the common component “coraco-” that refers to the coracoid bar, but only the coracoarcuals and parts of the coracobranchials attach directly to this structure. The others gain an indirect attachment by way of the coracoarcuals.





**FIGURE 3.21** Blowup of branchiomeric and epibranchial musculature of the shark in right lateral view. The epibranchial musculature has been dissected to reveal the interarcual muscles.

### KEY TERMS: MUSCULAR SYSTEM

adductor mandibulae  
afferent spiracular artery  
branchial adductor  
coracoarcuals  
coracobranchials  
coracohyoids  
coracomandibular  
cucullaris  
dorsal hyoid constrictors  
dorsal interarcuals  
dorsal superficial constrictor  
epaxial musculature  
epibranchial

horizontal skeletogenous septum  
hyomandibular nerve  
hypaxial musculature  
interbranchial  
interhyoideus  
intermandibularis  
lateral interarcuals  
levator hyomandibulae  
levator palatoquadrati  
linea alba  
myomeres  
myosepta  
pectoral abductor  
pectoral adductor

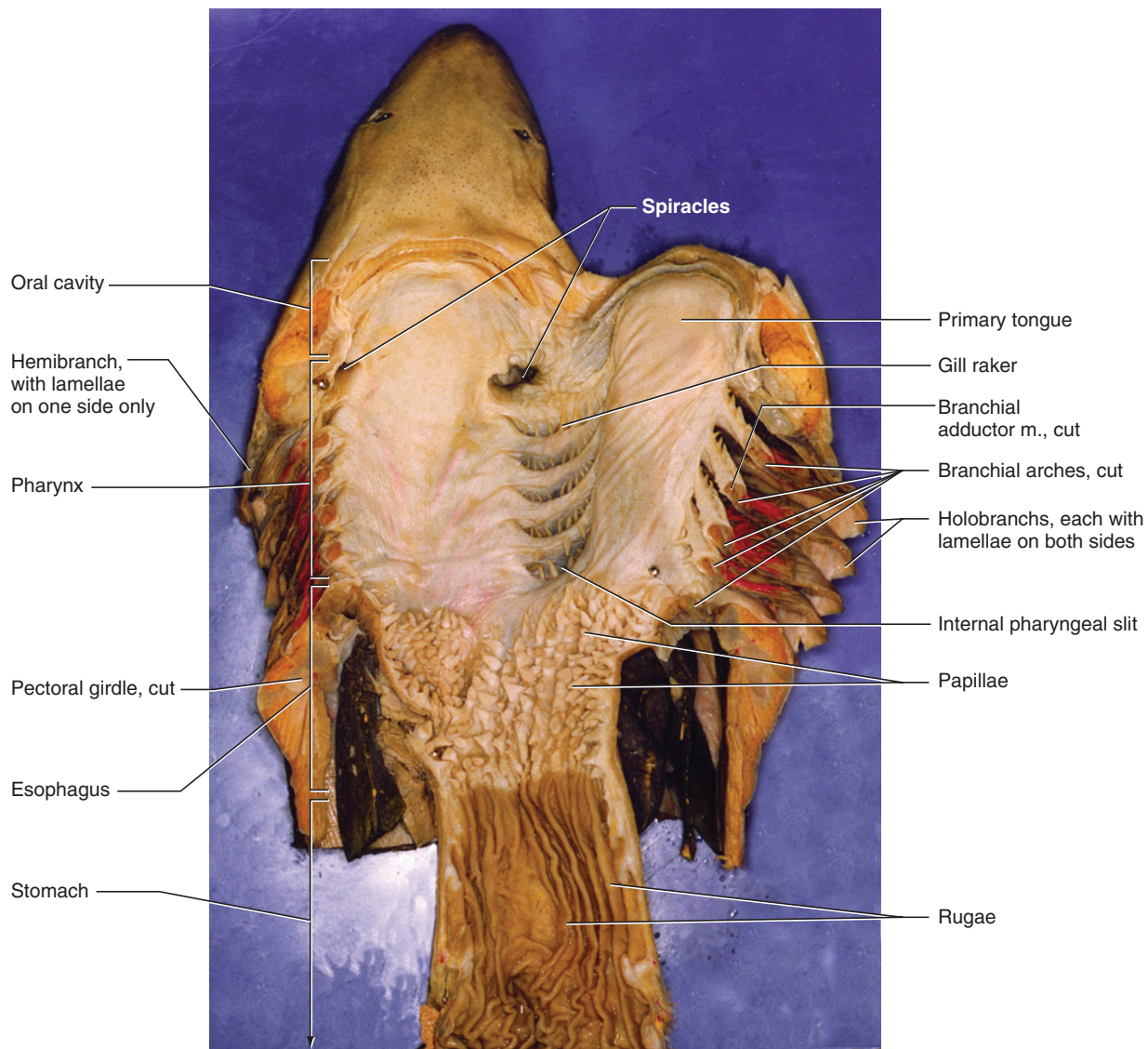
raphe  
siphon  
spiracularis

ventral hyoid constrictors  
ventral superficial constrictor

### SECTION IV—DIGESTIVE AND RESPIRATORY SYSTEMS

Anteriorly the digestive system includes the mouth, oral cavity, and pharynx, but these structures also function in the respiratory system. To observe them, make a frontal cut, using scissors, through the gills on the side of the head that was skinned for the muscles. Insert the scissors into the angle of the mouth and cut posteriorly through the gills. Stop once you have cut into the last branchial slit. Swing open the floor of the mouth as far as you can. Refer to Figure 3.22, but do not make a transverse cut through the ventral body wall at this time.



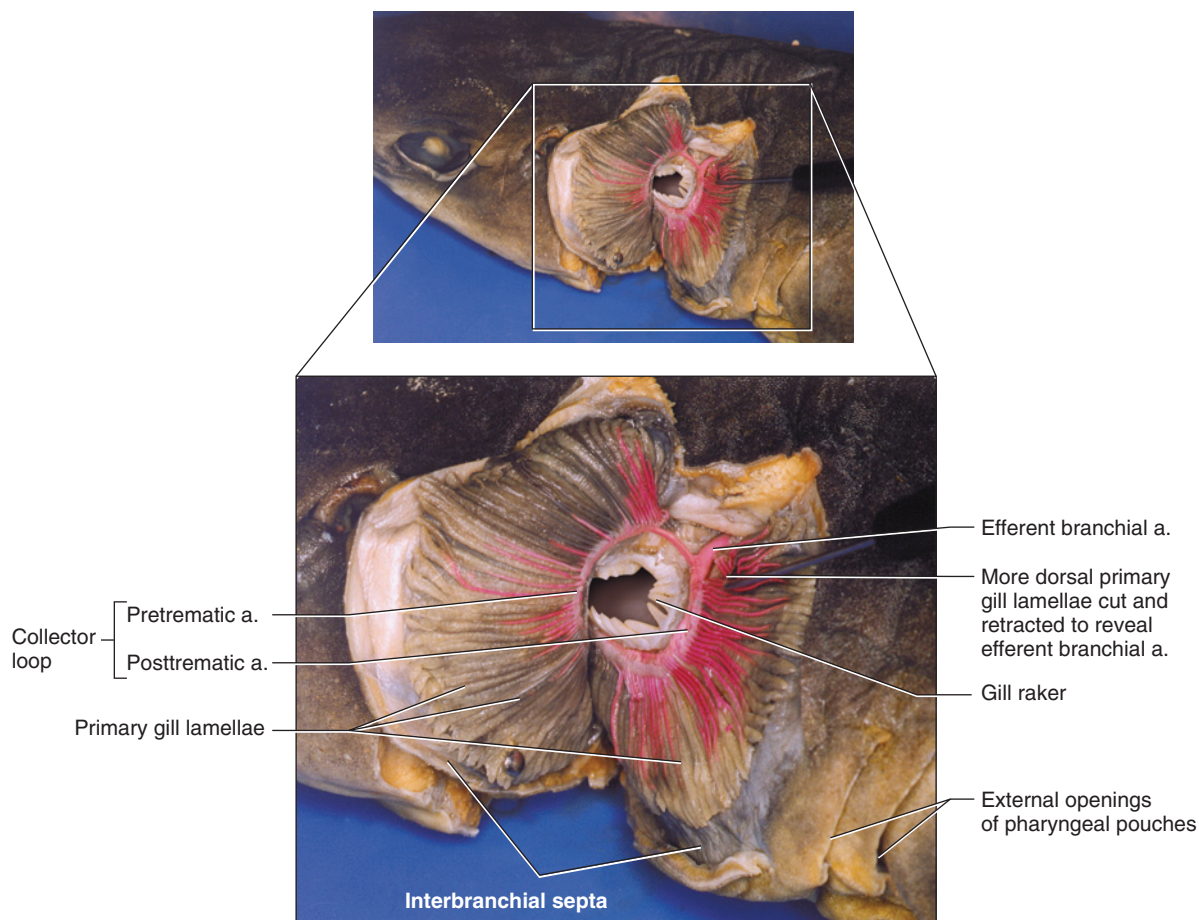


**FIGURE 3.22** Anterior portion of the shark in ventral view. The right side visceral arches have been cut through to reflect the floor of the oral cavity and pharynx. The esophagus and stomach have also been cut and reflected.

The mouth is the opening into the oral cavity. The oral cavity is bounded anteriorly by the **teeth**. Its floor is formed by the **primary tongue**, which is not a true tongue as occurs in tetrapods. The boundary between the oral cavity and pharynx is not clearly defined in the adult. The pharynx is considered the region into which the pharyngeal slits lead. Posteriorly it narrows into the esophagus, which leads to the stomach. Observe the five internal pharyngeal slits. **Gill rakers** are the finger-like structures projecting across the slit that help keep food from escaping through the slits or damaging the **gills**, which are the organs of respiration (i.e., across which gas exchange occurs). The **spiracle**, a smaller and dorsally placed opening, lies in front of the first pharyngeal slit. The spiracle, along with the mouth, allows water to enter the pharynx, from which it passes out through

the pharyngeal slits. The spiracle is larger and more important as a passageway for water in bottom-dwelling skates and rays.

Examine the branchial region along the cut you made to open the mouth. Note the four **interbranchial septa**, the partitions that separate the five pharyngeal slits. The anterior and posterior surfaces of each septum bear a gill (Figures 3.20, 3.22), which is made of parallel, ridge-like **primary gill lamellae**. A septum that has lamellae on both anterior and posterior surfaces is termed a **holobranch**. A **hemibranch** has lamellae on only one side, as occurs with the first gill, in which lamellae are present on the posterior wall. Keep in mind that *holobranch* and *hemibranch* are used with reference to lamellae or septa and not to pharyngeal slits.



**FIGURE 3.23** Branchial region of the shark in dorsolateral view, with blowup showing detail of pretrematic and posttrematic surfaces of successive interbranchial septa.

Reexamine a septum in section (Figures 3.20 and 3.22). It consists of a medial cartilaginous support, the branchial arch. Review the cartilages of the arch if necessary. A **branchial adductor muscle** lies medial to the arch. Extending laterally is a muscular wall, the **interbranchial muscle**, which supports lamellae on its anterior and posterior surfaces. Cartilaginous **gill rays** (see Figure 3.20) extend from the arch into and help support the interbranchial muscle. Further laterally, the septum is completed by the superficial constrictor muscle. A **pretrematic artery** lies at the base of the lamellae on the posterior surface of the septum, and a **posttrematic artery** lies anteriorly. These names are used with reference to a pharyngeal slit, *trema* being the ancient Greek word for *hole* or *slit*. Probe the septum for **cross trunks** linking these arteries. An **afferent branchial artery** lies near the middle of the septum between the pretrematic and posttrematic arteries.

The **celom** or body cavity includes the **pericardial cavity** anteriorly and the **pleuroperitoneal cavity** posteriorly. They are separated by the **transverse septum**, lying very near the pectoral girdle. The pericardial cavity, which contains the heart, will be considered below together

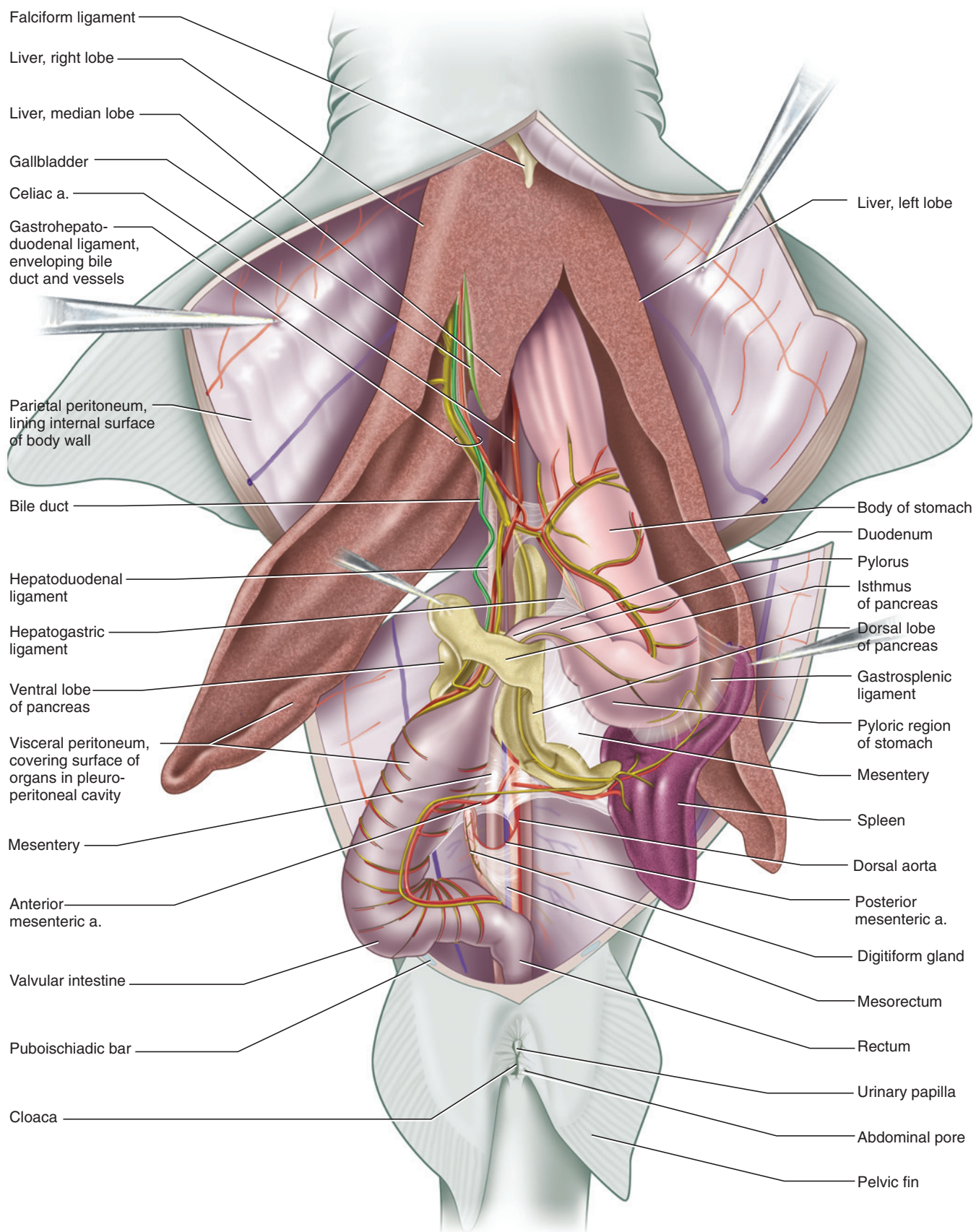
with the cardiovascular system. The pleuroperitoneal cavity contains the viscera, mainly digestive organs, and various other structures.

To gain access to this cavity, make a longitudinal cut, slightly to one side of the midline, from the posterior side of the pectoral girdle to the base of the tail. In doing so, cut through the puboischiadic bar and to one side of the cloaca. Then make two transverse cuts on either side to produce four flaps as shown in Figure 3.24.

Note that you have cut through various layers to open the pleuroperitoneal cavity: skin, musculature, and **parietal peritoneum**, the epithelium that lines the body cavity (Figure 3.24). The epithelium covering the organs within the cavity is the **visceral peritoneum**. The organs are suspended from the body wall or connected to each other via membranes termed **mesenteries**. Any membrane in the peritoneal cavity that supports an organ may be called a mesentery. One mesentery is simply called *the* mesentery, and you will meet that below.

First, examine the viscera. The most conspicuous is the **liver**, which occupies most of the anterior part of the





**FIGURE 3.24** Pleuroperitoneal cavity of the shark in ventral view, showing viscera and vessels.

cavity. **Right** and **left lobes** extend posteriorly on either side. Do not cut off these lobes (otherwise, you will have to contend with a continuous leakage of the oil present in the liver that reduces the shark's specific gravity). A small, **median lobe** extends for a short distance between them and contains an elongated **gall bladder**.

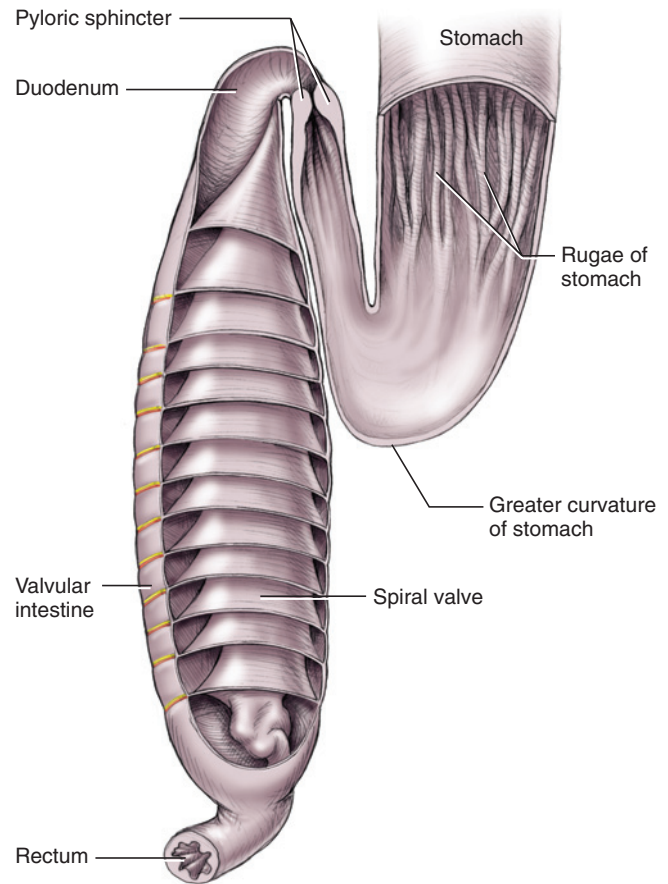
Spread the lobes of the liver to expose the viscera completely. Entering the cavity dorsal to the liver is the **esophagus**. It passes posteriorly into the **stomach**, a large J-shaped organ. There is no external distinction between the stomach and esophagus. Internally, however, the esophagus bears finger-like projections or **papillae**, whereas the stomach bears longitudinal ridges termed **rugae** (Figure 3.22). Slit open a portion of the esophagus and stomach to observe these structures. Note the possible presence of stomach contents.

The main part of the stomach is the **body**. The smaller, narrower, posterior part is the **pyloric region**. It constricts at the **pylorus**, which marks the separation between the stomach and intestine. Two organs lie near the junction of the stomach and intestine. The triangular **spleen** is the large, dark-colored organ at the posterior end of the stomach. It is not part of the digestive system, but belongs to the cardiovascular system. The **pancreas** consists of two parts linked by a narrow **isthmus**. A flattened, oval **ventral lobe** (Figure 3.24) lies on the anteroventral surface of the intestine. The narrow, elongated **dorsal lobe** extends posteriorly.

The intestine of the shark is subdivided into a short **duodenum**, a **valvular intestine**, and a narrow **colon**. The **valvular intestine** bears a **spiral valve**, an internal subdivision that increases the effective length of the intestine. Slit open the intestine to see the valve (Figure 3.25). The **colon**, lacking a spiral valve, extends from the valvular intestine. It is joined by the salt-excreting **digitiform gland**, before continuing into the cloaca as the **rectum**.

Other structures in the pleuroperitoneal cavity should be noted only briefly at this time. The **gonads**, either paired **testes** or **ovaries**, lie anteriorly, dorsal to the liver (see Figures 3.33 and 3.34). The **kidneys** extend longitudinally along the dorsal wall of the cavity on either side of the sagittal plane as two narrow strips. These organs, as well as various ducts associated with the urogenital system, will be considered later.

Next, consider the mesenteries. Pull the digestive tract ventrally and to the right. Note the dorsal mesentery, the thin, translucent sheet that suspends the gut mid-dorsally (Figure 3.26). It is subdivided into various parts. The **mesogaster** (or greater omentum) extends to the esophagus and stomach. The **mesentery** (in the limited sense of this word; in the general sense, mesen-

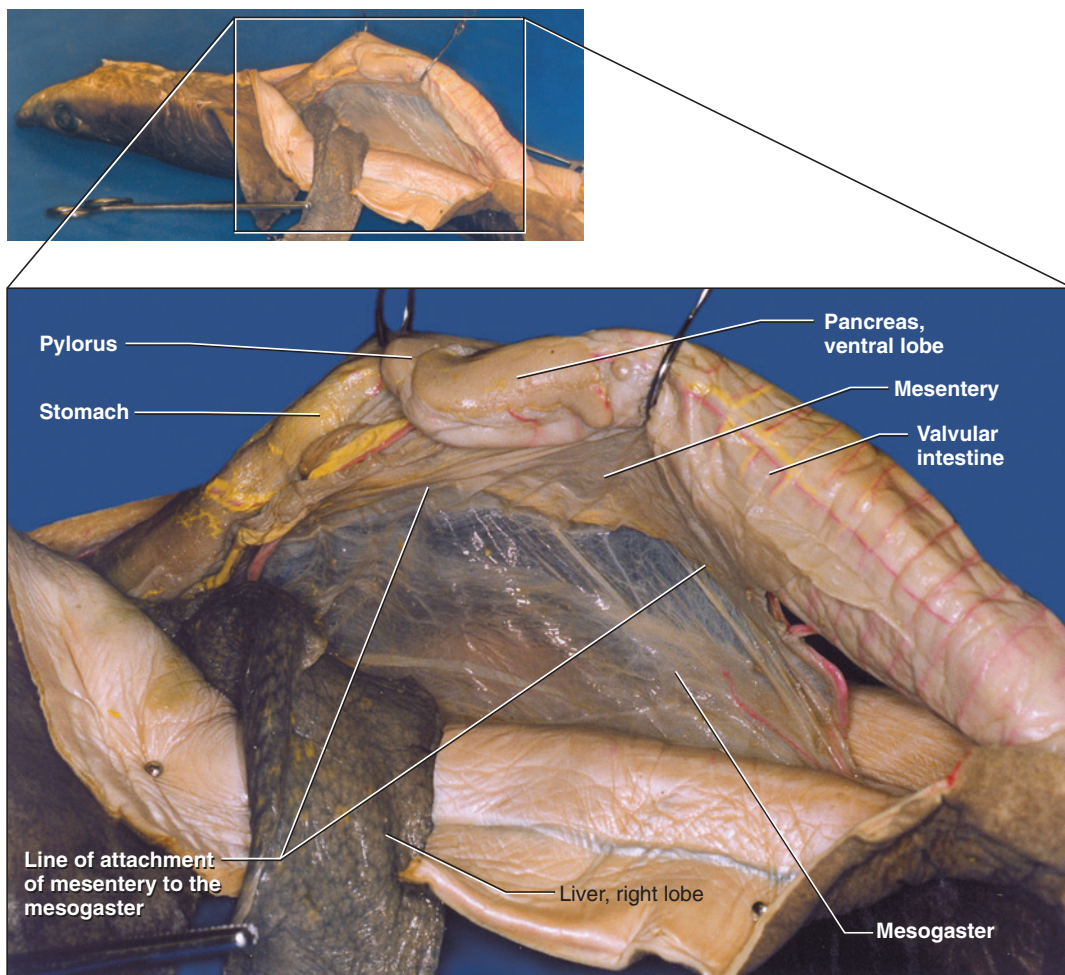


**FIGURE 3.25** Cutaway view of the valvular intestine and posterior end of stomach of the shark in ventral view, revealing the structure of the spiral valve.

tery can refer to any membrane that supports viscera) supports the anterior part of the intestine. Gently probe the mesentery and note that it arises from the mesogaster. Pull the digitiform gland ventrally to observe the **mesorectum**. Finally, gently pull the spleen posteriorly and note that it is attached to the stomach via the **gastrosplenic ligament**.

In the embryo a complete ventral mesentery is also present, but only portions of this membrane remain in the adult. Spread the median and right lobes of the liver. A ribbon-like strand, the **gastrohepatoduodenal ligament** (or lesser omentum) will be seen extending from the liver toward the gut. Near the liver it is a single bundle, carrying the **bile duct** and supporting blood vessels between the liver and gut. As it approaches the pyloric region, it divides into a **hepatoduodenal ligament** that carries the bile duct to the duodenum, and a **hepatogastric ligament** that passes into the adjacent portions of the body and pyloric region of the stomach. Look between these ligaments and note that the pancreas is supported by a part of the dorsal mesentery. The **falciform ligament** extends between anteroventral surface of the liver and the mid-ventral body wall. This





**FIGURE 3.26** Pleuroperitoneal cavity of the shark in right lateral view, with intestine pulled ventrally and liver reflected to expose mesenteries.

short mesentery also supports the common openings of the oviducts, described later. Other mesenteries supporting the reproductive tract are discussed with the urogenital system.

### KEY TERMS: DIGESTIVE AND RESPIRATORY SYSTEMS

afferent branchial artery  
bile duct  
body of stomach  
branchial adductor muscle  
celom  
colon  
cross trunks between pretrematic and posttrematic arteries  
digitiform gland (rectal gland)

duodenum  
esophagus  
falciform ligament  
gall bladder  
gastrohepatoduodenal ligament (lesser omentum)  
gastrosplenic ligament (lienogastric ligament)  
gill rakers  
gill rays

gills  
gonads  
hemibranch  
hepatoduodenal ligament  
hepatogastric ligament  
holobranch  
interbranchial muscle  
interbranchial septa  
isthmus of pancreas  
kidneys  
left lobe of liver  
liver  
median lobe of liver  
mesenteries—general sense

mesentery—specific sense  
mesogaster (greater omentum)  
mesorectum  
ovaries  
pancreas, dorsal lobe  
pancreas, ventral lobe  
papillae (sing., papilla)  
parietal peritoneum  
pericardial cavity  
pleuroperitoneal cavity  
posttrematic artery  
pretrematic artery  
primary gill lamellae  
primary tongue

pyloric region of  
stomach  
pylorus  
rectum  
right lobe of liver  
rugae (sing., ruga)  
spiracle  
spiral valve

spleen  
stomach  
teeth  
testes (sing., testis)  
transverse septum  
valvular intestine  
visceral peritoneum

## SECTION V—CARDIOVASCULAR SYSTEM

### Heart and Arterial Circulation

#### Heart

The pericardial cavity contains the heart, the muscular pump that drives the blood around the cardiovascular system. To expose the pericardial cavity, continue the incision into the pleuroperitoneal cavity forward through the coracoid bar and the hypobranchial musculature. Spread the flaps to reveal the heart (Figure 3.27). Note the **parietal pericardium**, the shiny epithelium lining the cavity, and the **visceral pericardium**, covering the heart. The **transverse septum** separating the pleuroperitoneal and pericardial cavities is incomplete; they communicate through a small opening, the **pericardioperitoneal canal**, that lies ventral to the esophagus.

The **ventricle** is the most conspicuous structure of the heart. It is a large, oval, muscular chamber; a coronary artery, supplying the heart, will be seen on its surface. Lift the ventricle's posterior end to expose the **sinus venosus** and **atrium**. The sinus venosus is the thin, triangular, posterior, sac-like chamber attached to the transverse septum. It receives venous blood from the body and passes it anteriorly into the atrium. Anteriorly the ventricle narrows into the fourth chamber of the heart, the muscular, tube-like **conus arteriosus**, through which blood leaves the heart.

#### Arteries of the Branchial Region

Once blood leaves the heart, it enters the **ventral aorta** and passes through the **afferent branchial arteries** on its way to being aerated in the gills. To trace this arterial route, continue dissecting forward from the conus arteriosus. The ventral aorta gives off five pairs of afferent branchial arteries. The most posterior are the 4th and 5th afferent branchial arteries, which may arise separately or by a short common trunk. The 3rd afferent branchials emerge further anteriorly. Trace the ventral aorta anteriorly to its bifurcation. Each of the divisions divides again into the 1st and 2nd afferent branchial arteries. Follow the arteries as far as possible without causing damage into the interbranchial septa. The arter-

ies pass between bundles of the coracobranchial muscles (Figures 3.19 and 3.27).

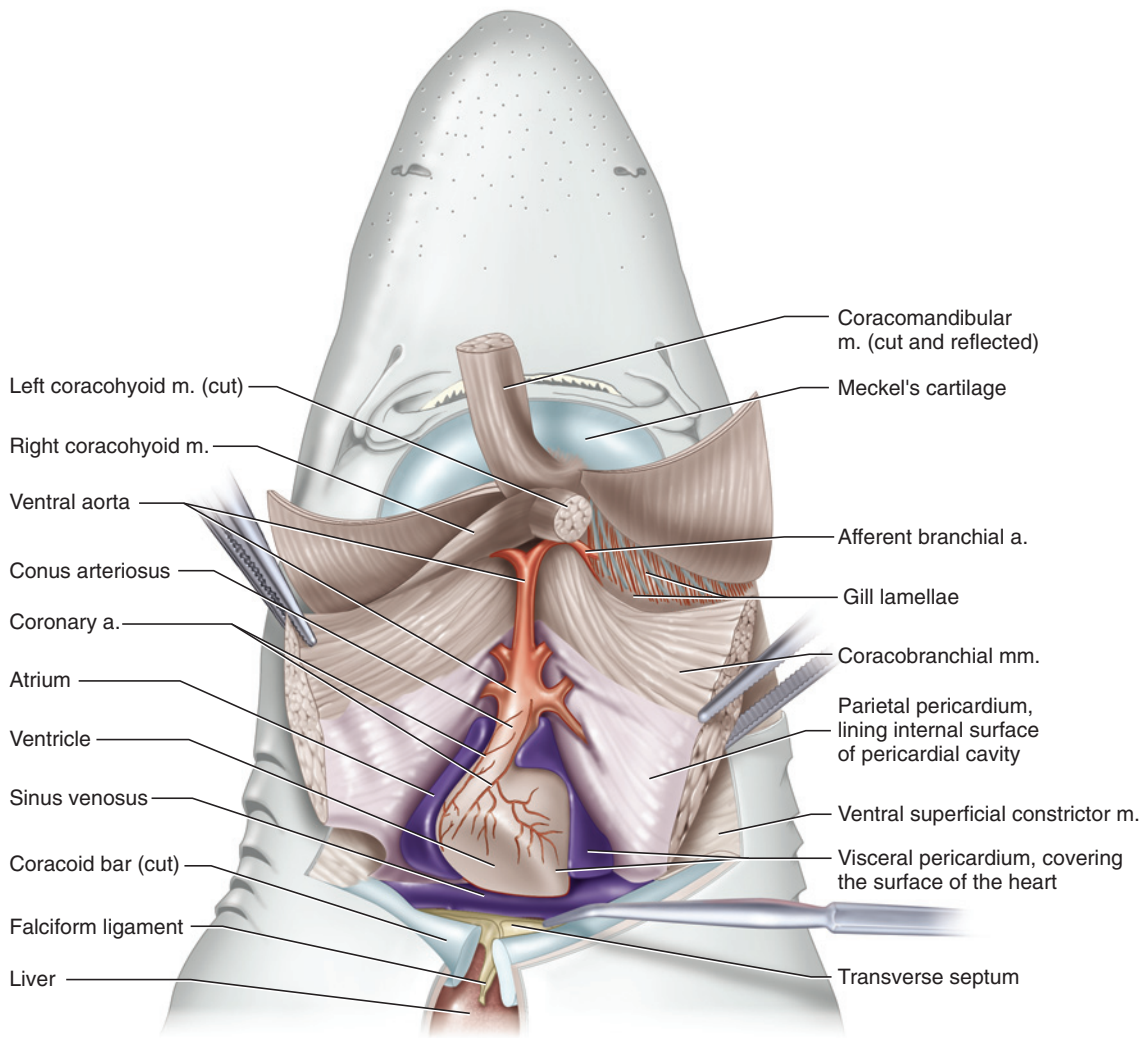
Blood passing through the afferent branchial arteries enters the gill lamellae, where gas exchange occurs. The aerated blood is then collected again so it may be sent to the rest of the body. To view the system that recollects the blood, delicately remove the membrane lining the roof of the oral cavity and pharynx and the area around the uncut internal branchial openings (Figures 3.28–3.30). Aerated blood is initially collected from the lamellae into the pretrematic and posttrematic arteries. These arteries join dorsally and ventrally to form a complete **collector loop** around a pharyngeal slit (Figure 3.23). Note that there are only four collector loops, as the last slit has only a pretrematic artery. From the dorsal end of each loop, an **efferent branchial artery** carries blood away from a gill (Figure 3.28). The four pairs of arteries pass posteromedially and empty into the **dorsal aorta** on the roof of the pharynx, which passes posteriorly to supply most of the body with aerated blood. Its branches are considered below.

Examine first the vessels that supply the head. A **hyoidean artery** arises from the anterodorsal part of the first collector loop, just anterior to the first efferent branchial artery, and extends anteriorly. **Paired dorsal aortae** arise from the first efferent branchial arteries. They pass anteriorly and then veer laterally and join a hyoidean artery. The union of the hyoidean and a paired dorsal aorta forms the **internal carotid artery**. The internal carotid extends anteriorly a short distance and, near the level of the spiracle, gives rise to the **stapedial artery**, which extends anterolaterally a short distance before passing into the chondrocranium. Past the origin of the stapedial artery, the internal carotids from either side extend anteromedially and meet middorsally to form a single vessel that enters the chondrocranium.

The **afferent spiracular artery** arises from near the middle of the pretrematic artery of the first loop. Do not dissect for it here. It was noted earlier (page 41; Figure 3.17) as it passed deep to the hyomandibular nerve on the levator hyomandibulae muscle. Return to the dissection of the muscles, and trace the afferent spiracular artery anteriorly into the pseudobranch of the spiracle and posteriorly into the collector loop. The **efferent spiracular artery** collects blood from the pseudobranch. Find it on the roof of the oral cavity. It extends anteromedially, passing ventral to the stapedial artery, and enters the chondrocranium. The lower jaw is supplied by the **external carotid artery**, which arises from the anteromedial corner of the first collector loop (Figure 3.30).

The **hypobranchial artery** (Figure 3.30) usually arises from the ventral end of the second collector loop, but





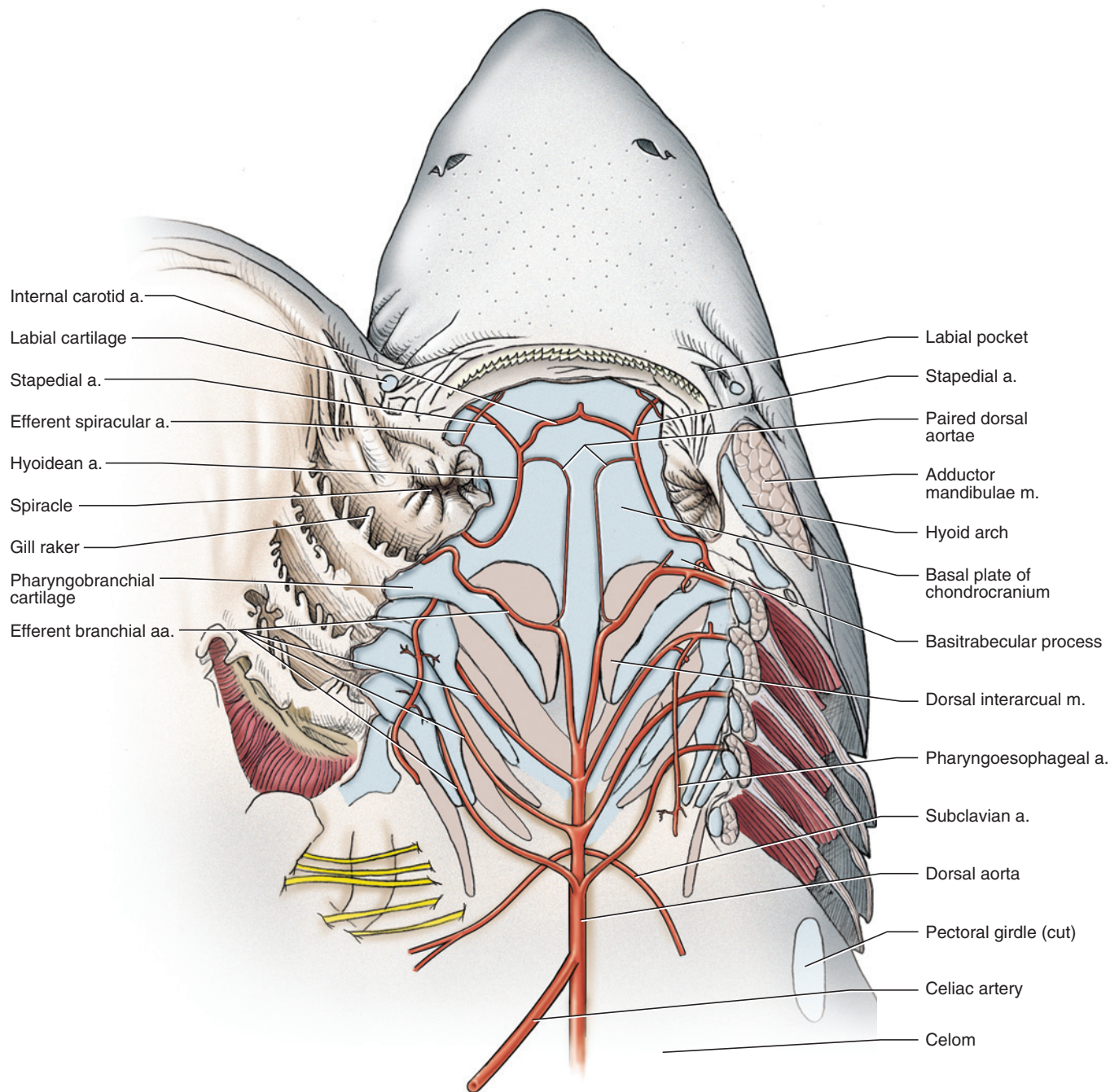
**FIGURE 3.27** Head and branchial region of the shark in ventral view, with the hypobranchial musculature dissected and reflected to expose the heart and ventral aorta.

branches from the other loops may contribute to it. The hypobranchial passes posteriorly to the conus arteriosus, where it divides into the **coronary** and the **pericardial arteries**. The former is clearly observed on the conus arteriosus and ventricle (Figure 3.27), the latter on the wall of the pericardial cavity. The narrow, sinuous **pharyngoesophageal artery** arises from the second efferent branchial artery and extends posteriorly to give off branches to the pharynx and esophagus (Figure 3.28). The rest of the blood flow passing back to the body goes through the dorsal aorta, which gives off various large branches.

### *Branches of the Dorsal Aorta*

The paired **subclavian arteries** are the first major branches of the dorsal aorta (Figures 3.28 and 3.29). These arise usually between the 3rd and 4th efferent branchial arteries. Initially they pass posterolaterally. At the pectoral girdle each subclavian veers lateroventrally, passing deep to the posterior cardinal sinus, along the

scapular process. Follow the artery on the side for which the sinus was dissected. It gives rise to two main branches, the **brachial** and **anterior ventrolateral arteries**, but it is difficult to neatly dissect the origins of these vessels. The brachial supplies the pectoral fin (do not confuse its spelling with *branchial*: brachial = arm, branchial = gill). To find it, pull the pectoral fin away from the body and cut through the skin between the body and posteromedial surface of the fin. This will free the fin from the body. Picking away the connective tissue from the medial surface of the fin will soon reveal the brachial artery as it passes along the medial cartilaginous fin support. Trace the artery back toward the subclavian to note the position of its origin. After the origin of the brachial, the anterior ventrolateral artery continues, on the inside of the body wall, passing first slightly anteriorly and then curving markedly posteriorly, about midway between the lateral and midventral lines. Follow it as it continues back, giving off branches that supply the myomeres, and eventually anastomoses with



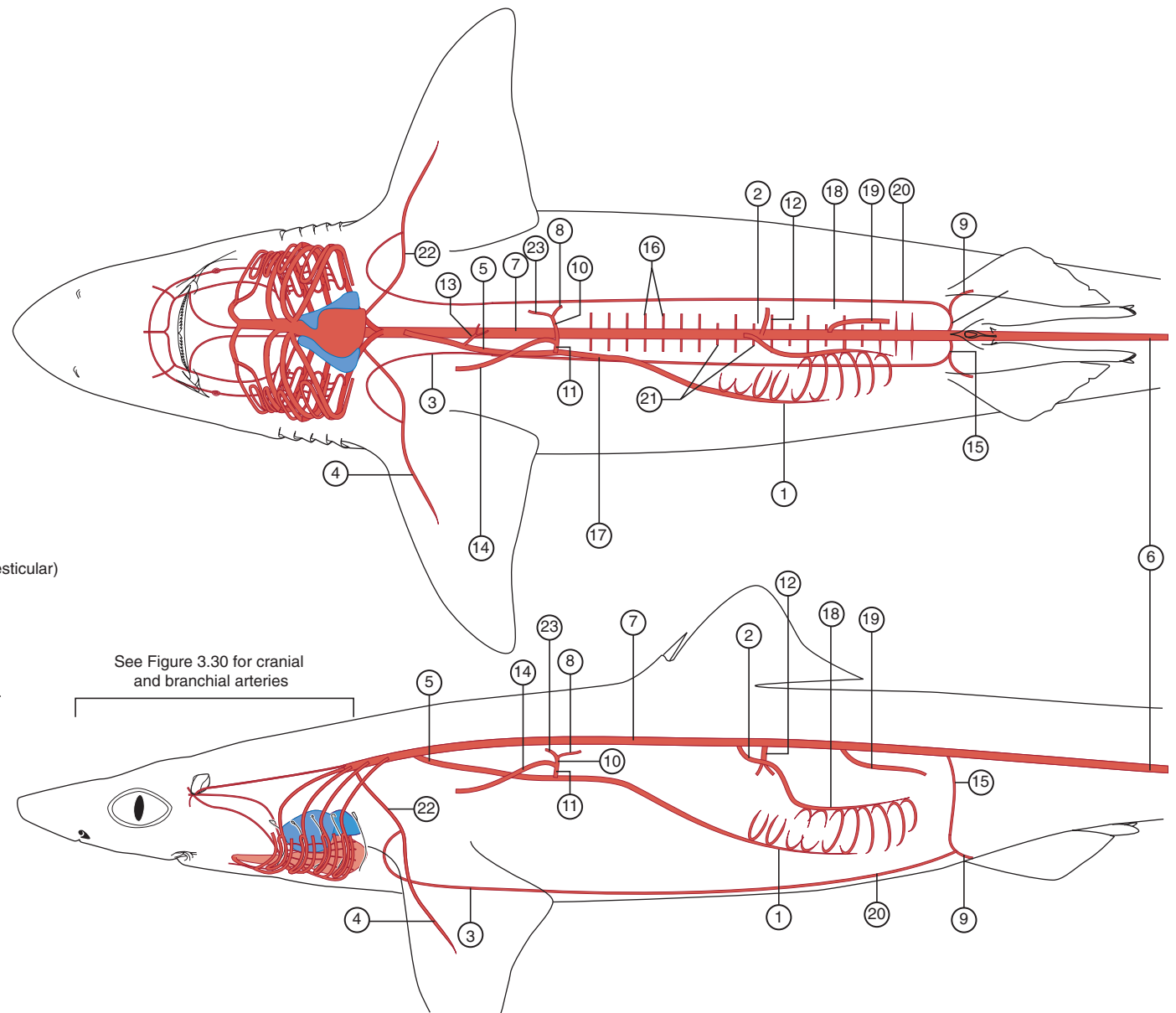
**FIGURE 3.28** Roof of the oral cavity and pharynx in the shark in ventral view, showing the pattern of the arterial circulation. The left side visceral arches have been cut. The floor of the oral cavity and of the pharynx have been swung open.

the posterior ventrolateral artery (a branch of the iliac arteries; see page 55).

After giving off the subclavian arteries, the dorsal aorta continues posteriorly into the pleuroperitoneal cavity. Return to this cavity to examine the following vessels (Figures 3.29 and 3.31). The first branch of the dorsal aorta in the cavity is the **celiac artery**, a large, unpaired vessel that continues posteriorly along the right side of the stomach. Near its origin, it gives rise to a pair of tes-

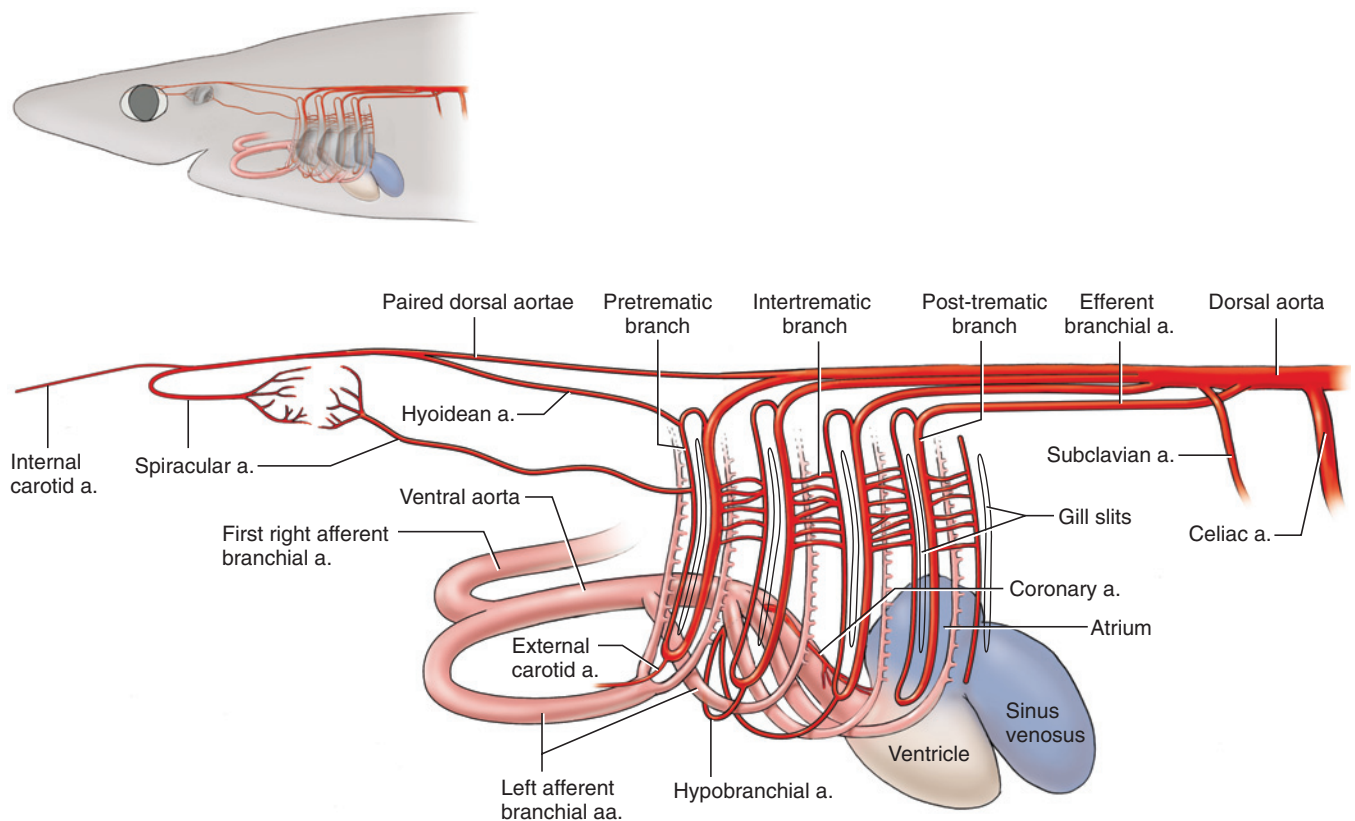
**ticular** (in males) or **ovarian** (in females) **arteries** (Figure 3.29) to supply the gonads. The celiac artery continues to the anterior tip of the dorsal lobe of the pancreas, where it divides into the **pancreaticomesenteric** and **gastrohepatic arteries**. The latter is a very short branch that subdivides almost immediately into a small **hepatic artery** and a larger **gastric artery**. The hepatic artery turns anteriorly toward the liver, accompanied by the hepatic portal vein (see below) and the anterior part of the bile duct. The gastric artery passes to the stomach,

- ① Anterior intestinal a.
- ② Anterior mesenteric a.
- ③ Anterior ventrolateral a.
- ④ Brachial a.
- ⑤ Celiac a.
- ⑥ Caudal a.
- ⑦ Dorsal aorta
- ⑧ Dorsal gastric a.
- ⑨ Femoral a.
- ⑩ Gastric a.
- ⑪ Gastroheptic a.
- ⑫ Gastrosplenic a.
- ⑬ Gonadal a. (ovarian or testicular)
- ⑭ Hepatic a.
- ⑮ Iliac a.
- ⑯ Intersegmental aa.
- ⑰ Pancreaticomesenteric a.
- ⑱ Posterior intestinal a.
- ⑲ Posterior mesenteric a.
- ⑳ Posterior ventrolateral a.
- ㉑ Renal aa.
- ㉒ Subclavian a.
- ㉓ Ventral gastric a.



**FIGURE 3.29** Schematic illustration showing the pattern of the arterial system of the shark superimposed on ventral (top figure) and left lateral (bottom figure) views of the body outline.





**FIGURE 3.30** Schematic illustration showing the pattern of the arterial system in the head and branchial region of the shark superimposed on ventral (top figure) and left lateral (bottom figure) views of the head.

where it branches into the **dorsal** and **ventral gastric arteries** to the dorsal and ventral parts of the stomach, respectively. Return to the pancreaticomesenteric artery and trace it posteriorly as it passes dorsal to the pylorus and onto the ventral side of the intestine as the **anterior intestinal artery**. Before doing so it gives off several smaller branches near the pylorus (which you do not need to name).

Trace the dorsal aorta further posteriorly. At about the level of the spleen, two arteries arise close together. The anterior one is the **anterior mesenteric artery**, which extends onto the intestine as the **posterior intestinal artery**. The posterior artery is the **gastrosplenic artery**, which mainly supplies the spleen and the posterior part of the stomach. Note that the anterior mesenteric and gastrosplenic arteries lie in the posterior edge of the greater omentum. Sometimes these arteries come off in reverse order (i.e., the gastrosplenic is the more anterior); trace them to identify the arteries in your specimen. After a short distance the dorsal aorta gives off a **posterior mesenteric artery**, which passes along the anterior edge of the mesorectum and onto the digitiform gland.

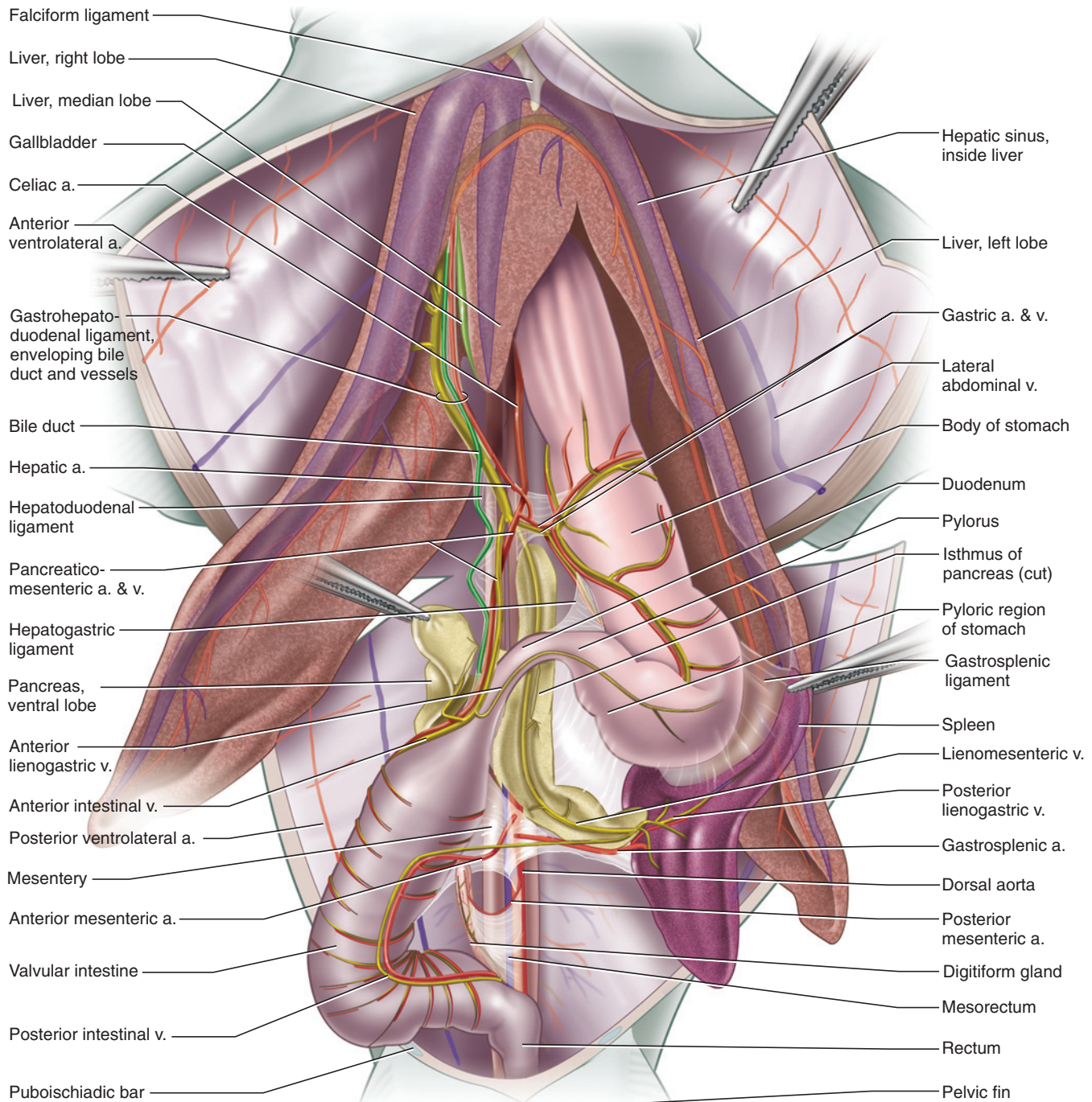
The final branches of the dorsal aorta are the paired **iliac arteries** and the **caudal artery** (Figure 3.29). At about

the level of the cloaca, the iliac arteries arise and pass posterolaterally dorsal to the kidneys. They emerge from under the kidneys and extend toward the pelvic fins. Before entering the fin, each iliac branches into the **femoral artery**, which enters the fin, and the **posterior ventrolateral artery**, which turns anteriorly along the body wall and eventually unites with the anterior ventrolateral artery, noted above. The caudal artery is the posterior continuation of the dorsal aorta into the tail. Finally, the dorsal aorta gives rise to numerous **inter-segmental arteries** (Figures 3.29, 3.34) to the axial musculature. Free the lateral margin of a kidney and lift it to observe these arteries.

## Venous Circulation

### Hepatic Portal System

The hepatic portal system is the venous system that returns blood from the alimentary tract to the liver (where raw nutrients in blood are processed before the blood returns to the heart). Essentially, it drains the structures supplied ultimately by the celiac (except for the gonads), anterior mesenteric, gastrosplenic, and posterior mesenteric arteries. Thus, the branches of the hepatic portal system closely follow many of the branches of these arteries, and it is convenient to study



**FIGURE 3.31** Pleuroperitoneal cavity of the shark in ventral view, showing the pattern of the arteries and veins.

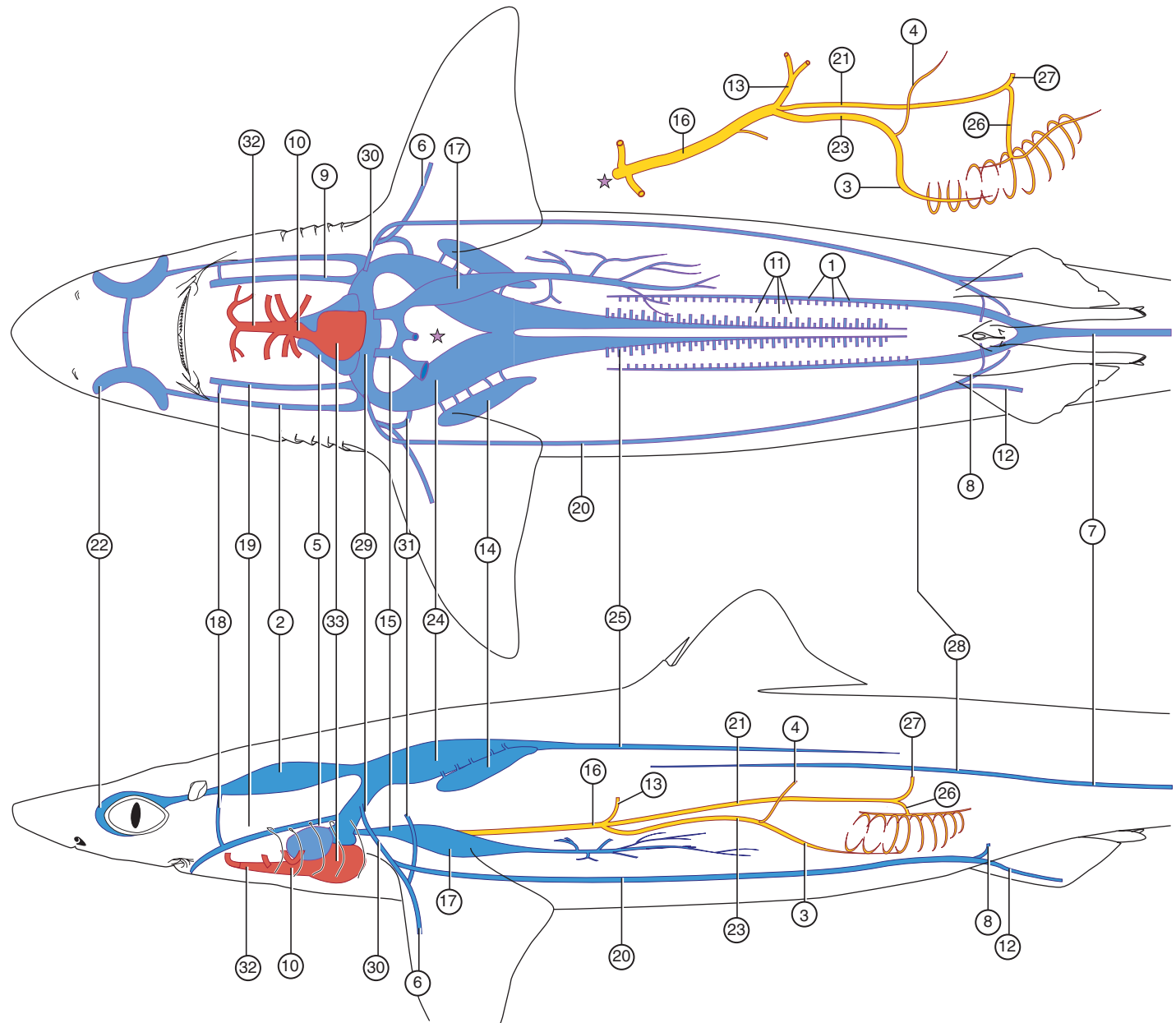
them following your identification of the arteries. In some specimens the hepatic portal system is injected with yellow latex, which greatly facilitates its study. You may follow its branches in an uninjected specimen, but also briefly examine a shark that has the system injected.

The main vessel of the hepatic portal system is the **hepatic portal vein** (Figure 3.32), a large vein that lies in the lesser omentum alongside the hepatic artery and

anterior part of the bile duct. The hepatic portal vein is formed by the confluence of three main vessels, the **gastric, pancreaticomesenteric, and lienomesenteric veins**. They unite to form the hepatic portal near the anterior tip of the dorsal lobe of the pancreas. Recall that the celiac artery splits into its branches very near this point as well. Occasionally, the gastric and lienomesenteric veins join to form a very short vessel that then unites with the pancreaticomesenteric to form the hepatic portal vein.



- ① Afferent renal vv.
- ② Anterior cardinal sinus
- ③ Anterior intestinal v.
- ④ Anterior lienogastric v.
- ⑤ Atrium
- ⑥ Brachial v.
- ⑦ Caudal v.
- ⑧ Cloacal v.
- ⑨ Common cardinal v.
- ⑩ Conus arteriosus
- ⑪ Efferent renal vv.
- ⑫ Femoral v.
- ⑬ Gastric v.
- ⑭ Genital sinus
- ⑮ Hepatic v.
- ⑯ Hepatic portal v.
- ⑰ Hepatic sinus
- ⑱ Hyoidean sinus
- ⑲ Inferior jugular v.
- ⑳ Lateral abdominal v.
- ㉑ Lienomesenteric v.
- ㉒ Orbital sinus
- ㉓ Pancreaticomesenteric v.
- ㉔ Posterior cardinal sinus
- ㉕ Posterior cardinal v.
- ㉖ Posterior intestinal v.
- ㉗ Posterior lienogastric v.
- ㉘ Renal portal v.
- ㉙ Sinus venosus
- ㉚ Subclavian v.
- ㉛ Subscapular v.
- ㉜ Ventral aorta
- ㉝ Ventricle



**FIGURE 3.32** Schematic illustration showing the pattern of the venous system in the shark superimposed on ventral (top figure) and left lateral (bottom figure) views of the body outline. In the top figure, the hepatic portal system has been moved outside the body outline for clarity. The stars indicate the position of the hepatic portal system.

The gastric vein accompanies the gastric artery onto the dorsal and ventral surfaces of the stomach. Follow the lienomesenteric vein as it runs along the dorsal lobe of the pancreas. Rotate the spleen toward the left to observe that the vein is formed by the confluence, near the posterior end of the dorsal lobe, of the **posterior lienogastric vein** and the **posterior intestinal vein** (Figure 3.32). The former comes from the spleen and posterior part of the stomach (i.e., in parallel with the lienogastric artery), the latter from the posterior part of the intestine (recall that this region is supplied by the anterior mesenteric artery, which becomes the posterior intestinal artery). The pancreaticomesenteric vein accompanies the pancreaticomesenteric artery to the beginning of the intestine. Here it is formed by various tributaries. Among these are the **anterior intestinal** and the **anterior lienogastric veins** (Figure 3.32). As you might expect, the former vein extends parallel to the anterior intestinal artery. It is larger than the anterior lienogastric vein, which comes from the spleen and adjacent regions of the pyloric region of the stomach.

### Renal Portal System

Blood from the tail passes through the kidneys through the renal portal system before returning, through the posterior cardinal veins and sinus, to the heart. The main vessels of the renal portal system are the **caudal vein** and the **renal portal veins**. The latter arise through bifurcation of the caudal vein (Figure 3.32). The caudal vein passes anteriorly through the hemal arches of the vertebrae. Make a partial transverse section—deep enough to cut through the vertebrae—of the tail just posterior to the level of the cloaca. Note the caudal artery, which will be injected, lying in the dorsal part of the hemal arch. The caudal vein, which should not be injected, lies ventral to the artery (see Figure 3.6). Make additional partial sections, spaced about 1 cm apart, anterior to the first. As these sections are anterior to the cloaca, they will be at the level of the posterior end of the body cavity. Thus, cut deeply enough to go through the caudal artery and vein, but avoid cutting the kidneys, which lie ventral to and on either side of the vertebrae. You will thus be able to observe, near the posterior end of the kidneys, the bifurcation of the caudal vein into left and right renal portal veins. The latter continue anteriorly along the dorsolateral margins of the kidneys. **Afferent renal veins**, which you will not be able to observe (but see Figure 3.32), branch from the renal portal veins and carry blood to the sinuses of the kidneys.

### Systemic Veins

The systemic veins (Figure 3.32) are those that drain most of the body other than the viscera. Each side of the head and branchial region are drained mainly by the **anterior cardinal sinus** and **inferior jugular vein**. The

anterior cardinal sinus is a relatively large space (compared with the diameter of most veins) lying dorsal to the pharyngobranchial cartilages. It was exposed during the dissection of the musculature to find the dorsal and lateral interarcual muscles (page 43). The sinus receives vessels that drain the eye, brain, and head, and leads blood posteriorly toward the heart. The **orbital sinus**, for example, surrounds the eye, but it is impractical to attempt to find it. The inferior jugular vein is a thin vessel draining the floor of the branchial region and you will not see it. The anterior cardinal sinus and inferior jugular vein on each side of the head are connected via the **hyoidean sinus**. Pass a probe into the hyoidean sinus to determine its course. It lies along the posterior surface of the hyoid arch, and so it was sectioned during the cut made to open the oral cavity and pharynx.

Return to the heart, and slit the ventral wall of the sinus venosus from side to side. Gently probe its walls and note that there are a number of openings that lead into it. Probing its posterior wall just to either side of the sagittal plane will lead into the opening of a **hepatic vein** and then into a **hepatic sinus**, which collects blood from the liver (Figures 3.31 and 3.32). Each posterolateral corner of the sinus venosus leads to a short though large vessel, the **common cardinal sinus**, which receives the rest of the main vessels leading blood back to the heart (Figure 3.32). Pass a blunt, curved probe along the posterior wall of the common cardinal sinus. It should lead, without much effort, into the posterior cardinal sinus (described below). The anterior cardinal sinus enters the common cardinal at about the same level, but it is much more difficult to probe for by this method. Here, merely note that the tip of the probe veers anteriorly and dorsally.

The other vessels that enter the common cardinal are the inferior jugular vein and the subclavian vein (Figure 3.32). Gently probing the anterior wall of the common cardinal will lead into the inferior jugular vein. You may follow its course by palpating for the probe in the hypobranchial region. The **subclavian vein** enters the common cardinal just lateral to the entrance of the inferior jugular.

Return to the pleuroperitoneal cavity. Lift the gonad and anterior part of the liver so that the roof of the cavity may be observed. Lying dorsolateral to the esophagus is the posterior cardinal sinus (noted above), a large space bounded by a thin-walled membrane. It is filled with blue latex and therefore appears bluish. Note that the sinus curves toward the dorsal midsagittal line. Slit open the sinus and carefully remove the latex. Probe gently to verify that this sinus is continuous with the sinus from the other side of the body. Veins from the gonads and esophagus empty into the sinus, but it is impractical to trace them.

Follow the sinus posteriorly, moving the viscera to one side as you do so (Figure 3.32). The sinus narrows into a **posterior cardinal vein** that lies laterally to the dorsal aorta. The posterior cardinal veins appear as thin, translucent vessels because they are probably not injected, and so may be difficult to discern. Do not confuse them with the oviducts of a female or the archinephric duct of immature males. These thin, flattened, and straight structures are easily identified because they continue anteriorly to lie on the posterior cardinal sinus. Note that the veins lie along the medial margins of the kidneys. They receive **efferent renal veins** that collect blood from the kidneys and the segmentally arranged **intersegmental veins** that drain blood from the body wall. These veins, however, may not be easily observable.

A **lateral abdominal vein** extends along the inside of the ventrolateral body wall on each side (Figures 3.31 and 3.32). Trace one of these veins posteriorly. It is formed, at about the level of the cloaca, by the confluence of the **cloacal vein** (from the cloaca) and the **femoral vein** (from the pelvic fin). Trace the lateral abdominal forward to the pectoral girdle. Here, you will observe a number of veins coming together. You will probably see a conspicuous **subscapular vein** (Figure 3.31), which essentially runs parallel to the subclavian artery (but does not share its name). Find the **brachial vein** on the medial surface of the fin, in company with the brachial artery. It will probably be uninjected. Trace the brachial vein toward the body. It unites with the lateral abdominal to form the subclavian vein, already noted as entering the common cardinal sinus. The subscapular vein actually joins the brachial vein, but the brachial, subscapular, and lateral abdominal veins all come together very near each other in forming the subclavian vein, the vessel that continues the blood's journey toward the heart. Follow the subclavian vein as it arches dorsomedially.

### KEY TERMS: CARDIOVASCULAR SYSTEM

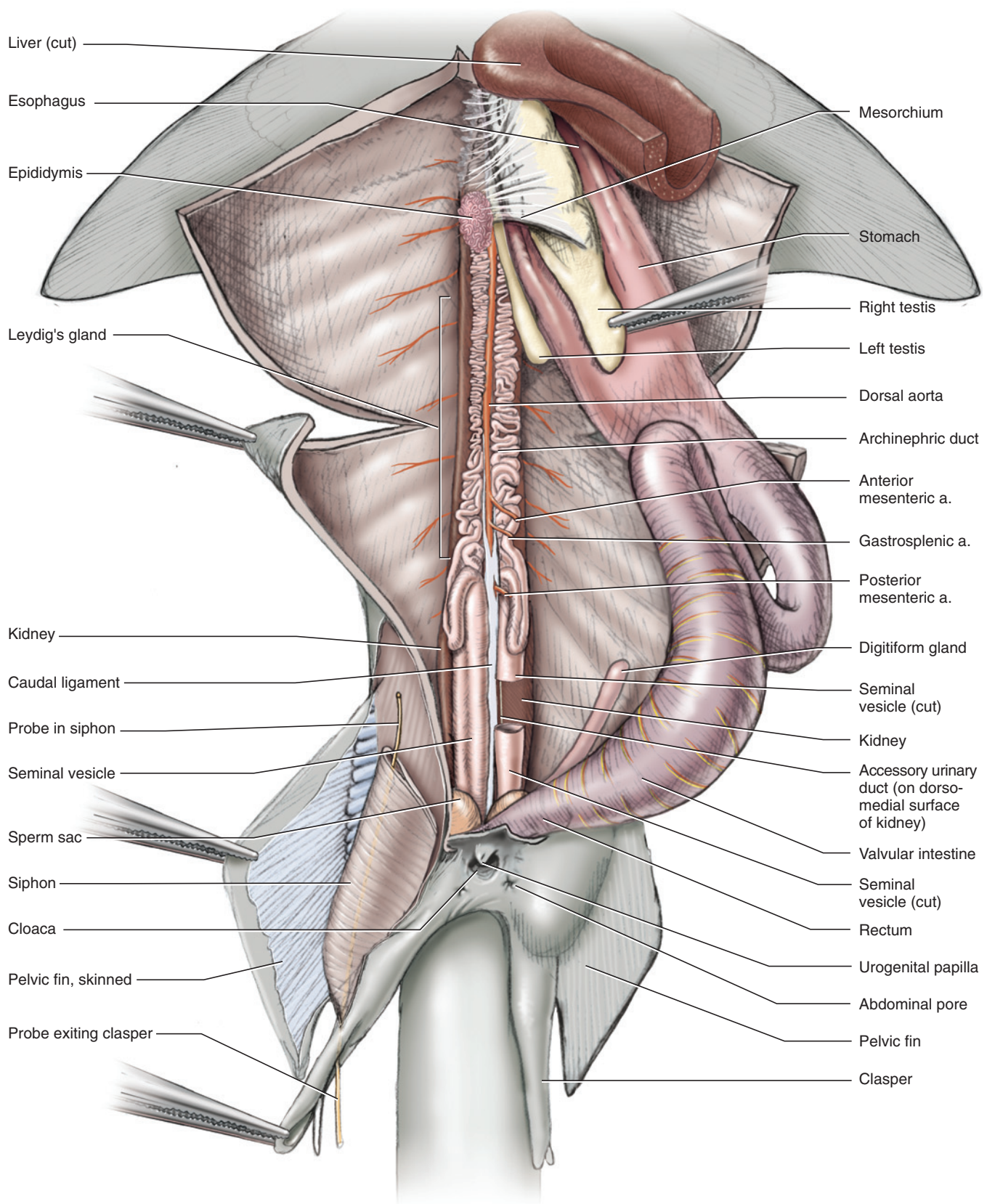
afferent branchial arteries	anterior ventrolateral artery (anterior epigastric artery)
afferent renal veins	atrium
afferent spiracular artery	brachial artery
anterior cardinal sinus	brachial vein
anterior intestinal artery	caudal artery
anterior intestinal vein	caudal vein
anterior lienogastric vein	celiac artery
anterior mesenteric artery	cloacal vein
	collector loop of gill

common cardinal sinus	paired dorsal aortae
conus arteriosus	pancreaticomesenteric artery
coronary artery	pancreaticomesenteric vein
dorsal aorta	parietal pericardium
dorsal gastric artery	pericardial artery
efferent branchial artery	pericardioperitoneal canal
efferent renal veins	pharyngoesophageal artery
efferent spiracular artery	posterior cardinal vein
external carotid artery	posterior intestinal artery
femoral artery	posterior intestinal vein
femoral vein	posterior intestinal vein
gastric artery	posterior lienogastric vein
gastric vein	posterior mesenteric artery
gastrohepatic artery	posterior ventrolateral artery (posterior epigastric artery)
gastrosplenic artery	renal portal vein
hepatic artery	sinus venosus
hepatic sinus	stapedial artery
hepatic portal vein	subclavian arteries
hepatic vein	subclavian vein
hyoidean artery	subscapular vein
hyoidean sinus	testicular artery
hypobranchial artery (commissural artery)	transverse septum
iliac arteries	ventral aorta
inferior jugular vein	ventral gastric artery
internal carotid artery	ventricle
intersegmental arteries	visceral pericardium
intersegmental veins	
lateral abdominal vein	
lienomesenteric vein	
orbital sinus	
ovarian artery	

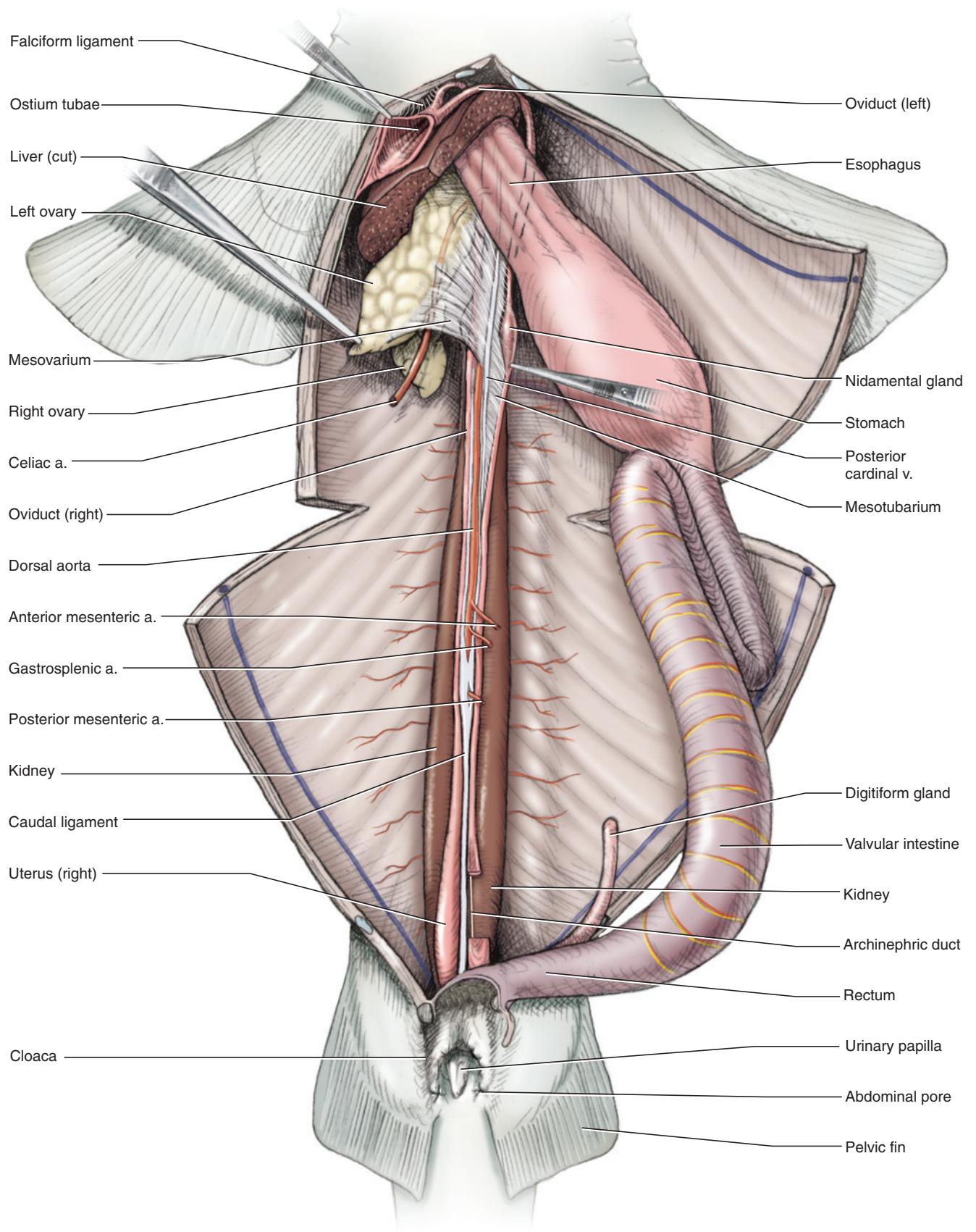
### SECTION VI—UROGENITAL SYSTEM

As various ducts of the excretory and reproductive systems become associated during embryonic development, it is convenient to discuss these systems together. The kidneys and gonads, noted earlier (page 49), are the main organs of the excretory and reproductive systems, respectively. Manipulate the digestive tract and liver to observe them. The paired **kidneys** are long, narrow structures on either side of the dorsal aorta on the roof of the body cavity (Figures 3.33 and 3.34). They extend nearly the length of the cavity. As they lie dorsal to the





**FIGURE 3.33** Pleuroperitoneal cavity in ventral view, showing the urogenital system of the male shark. Much of the viscera has been removed. The right testis is reflected to the left. The anterior end of the right siphon has been cut away. The bristle inserted into the siphon shows the path leading out of the siphon on the clasper.



**FIGURE 3.34** Pleuroperitoneal cavity in ventral view, showing the urogenital system of the female shark. Much of the viscera has been removed. The left ovary is reflected to the right.



parietal peritoneum lining the pleuroperitoneal cavity, the kidneys are retroperitoneal. The paired, elongated gonads, **testes** (sing., **testis**) in the male and **ovaries** (sing., **ovary**) in the female, lie dorsal to the liver in the pleuroperitoneal cavity. Note the **caudal ligament** between the posterior ends of the kidneys. It arises from the vertebrae and passes to the tail. The posterior mesenteric artery pierces the ligament on its way from the dorsal aorta to the **digitiform gland**.

## Male Urogenital System

The kidney of the male (Figure 3.33) has two distinct functional parts. The anterior part is related to sperm transport. It includes tubules that help transport sperm in the most anterior part of the kidney, often referred to as the **epididymis**, and tubules that form secretions that help transport sperm. The latter tubules lie in approximately the middle third of the kidney, a region known as **Leydig's gland**. The posterior thickened end of the kidney functions in excretion.

Each testis is supported by the **mesorchium**, a mesentery that suspends the organ from the middorsal wall of the body cavity. Within the anterior part of the mesorchium are small tubules (**efferent ductules**, which may be observed as strand-like structures) that extend from the testis to tubules in the epididymis of the kidney, which in turn are connected to the **archinephric duct**. Sperm take this route from the testes to reach the archinephric duct (originally a duct of the kidney) and then to be transported posteriorly for eventual release from the body (see below). In a mature male the archinephric duct is tightly convoluted and embedded in the ventral surface of the kidney. In an immature male it is nearly straight and resembles the oviduct of the female (see below).

As the archinephric duct approaches the cloaca, it straightens and expands into the **seminal vesicle**. Trace it posteriorly into the **sperm sac**, a small, anteriorly blindly ending pouch that lies on the ventral surface of the seminal vesicle. Free the anterior end of the sperm sac from the seminal vesicle and slit the sperm sac ventrally. Probe its roof and note the entrance of the seminal vesicle. Probe the posterior part of the sperm sac. Left and right sperm sacs unite to form the **urogenital sinus**, a median space that continues posteriorly through the **urogenital papilla**, which is used for the passage of urine and sperm.

As noted above, urine is produced almost entirely (and probably exclusively in the adult male) by the posterior part of the kidney. However, it does not enter the archinephric duct or seminal vesicle. Instead, a thin, delicate **accessory urinary duct** carries urine to the urogenital sinus. The entrance of the duct is posterior to

the entrance of the seminal vesicle into the sperm sac, but is difficult to locate. The accessory urinary duct extends along the medial margin of the kidney. Expose it by carefully lifting up the medial border of the kidney and delicately dissecting along its dorsomedial surface.

The remaining reproductive structures of the male are associated with the pelvic fin. The **clasper** is an intermittent organ inserted into the cloaca and oviduct of the female during copulation. A groove lies along the medial side of the clasper. Sperm is released from the urogenital papilla and travels along the groove to the cloaca of the female. Associated with each clasper is the elongated, sac-like **siphon**, which lies just below the skin on the ventral surface of the pelvic fin. Expose the siphon by removing the skin, and then cut open the siphon. Using a thin probe, search its posteromedial region for a passageway. Follow it as it passes along the groove of the clasper. The siphon expels fluid through this route that contributes to seminal fluid.

## KEY TERMS: MALE UROGENITAL SYSTEM

accessory urinary duct	mesorchium
archinephric duct	ovary (plur., ovaries)
caudal ligament	seminal vesicle
clasper	siphon
digitiform gland (rectal gland)	sperm sac
efferent ductules	testis (plur., testes)
epididymis	urogenital papilla
kidneys	urogenital sinus
Leydig's gland	

## Female Reproductive System

The ovaries are suspended from the roof of the anterior pleuroperitoneal cavity by the **mesovarium** (Figure 3.34). The ovaries are smooth and oval in immature females, but in mature females their surfaces have swellings that represent ova in various stages of development. An **oviduct** lies on the ventral surface of each kidney. Each is a narrow tube unsupported by a mesentery in immature specimens, but more conspicuous and supported by a **mesotubarium** in mature individuals. Trace an oviduct anteriorly. It passes dorsal to the ovary and then curves ventrally around the anterior surface of the liver. The left and right oviducts pass within the falciform ligament and join to form a common opening, the **ostium tubae**, in the free, posterior edge of the ligament. It is conspicuous in mature females and can easily be probed, but may be difficult to find in immature females. Note that there is no direct connection between the ovaries and the ostium: Eggs are shed into the pleu-

roperitoneal cavity and must make their way to the ostium, where they can enter an oviduct.

Trace the oviducts posteriorly and note that each eventually enters the cloaca through an opening on either side of the **urinary papilla**. An oviduct has two enlarged regions. The first, appearing as a slight anterior swelling dorsal to the ovary, is the **nidamental gland**, which secretes a thin membrane around groups of eggs as they pass through the oviduct. It is also the location where eggs are fertilized. The second enlargement, the **uterus**, occurs posteriorly. The uterus is greatly enlarged in pregnant specimens because it contains the developing pups. If you have a gravid female, cut open one of the uteri to observe the developing embryos. If not, observe embryos from another specimen. Depending on the stage of gestation, the pups will vary in length. They are nourished mainly with yolk, much of it stored in the **external yolk sac**, which enters the embryo via a stalk. Cut open the pleuroperitoneal cavity and observe that the stalk is continuous with the **internal yolk sac**.

The anterior part of the female kidney is greatly reduced and, unlike in the male, the kidney is not involved in the reproductive system. However, an archinephric duct, which is formed from the kidney, is present. In the female it is uncoiled, much smaller than in the male, and transports urine. Accessory urinary ducts are not present in female *Squalus*, but may be present in females of other sharks.

#### KEY TERMS: FEMALE REPRODUCTIVE SYSTEM

external yolk sac	ostium tubae
internal yolk sac	oviduct
mesotubarium	urinary papilla
mesovarium	uterus
nidamental gland (shell gland)	

## SECTION VII—SENSORY ORGANS

### Ampullae of Lorenzini

The **ampullae of Lorenzini** (Figures 3.15 and 3.35) are a modified part of the lateral line system (see below) and primarily sensitive to electrical fields (they can help a shark sense prey by detecting the electrical fields generated by activities of the prey). They form a series of tube-like structures just beneath and parallel to the skin. The ampullae are concentrated on the head, particularly on the ventral and dorsal surfaces of the snout and posterior to the eye. Squeeze the snout. Thick fluid emerges from the ampullae through pores in the skin. Remove a portion of skin from the snout and top of the head

between the eyes and observe the pattern formed by the ampullae.

### Lateral Line System

The lateral line system is composed of a series of canals and sensory receptors that provide sensory information by detecting disturbances in water. The position of the **lateral line canal**, extending midlaterally along the length of the body and into the tail, was noted earlier (page 37). The canal lies within the skin. Make a cut in the skin, perpendicular to the canal, and examine the cut surface. The canal appears as a small hole. The canal leads to various other canals in the head. If you skinned the head to find the ampullae of Lorenzini, you should be able to observe, about midway between the eye and sagittal plane, a groove for one of these canals (the supraorbital) heading toward the snout. Another canal (the infraorbital) passes down behind the eye and then forward toward the snout. Trace the canals on the head, which are named in Figure 3.35, if time permits.

### Nose

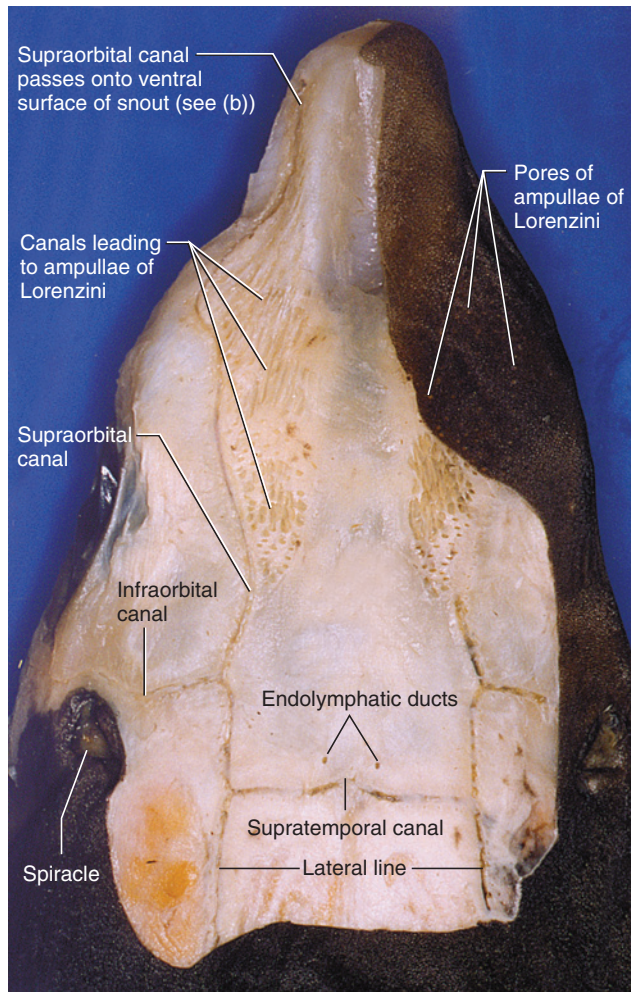
The **olfactory sacs** function in olfaction (Figures 3.36, 3.41–3.44). Reexamine the nares and note that each is subdivided into lateral incurrent and medial excurrent apertures that direct the flow of water into and out of the olfactory sac. Skin the region adjacent to one of the nares. Carefully pick away and remove the cartilaginous nasal capsule to expose the olfactory sac. It is a delicate, light-colored, spherical structure. Cut into the sac and note within it the parallel folds, or lamellae, on which the sensory receptors lie. The sac has no connection with the oral cavity.

### Eye

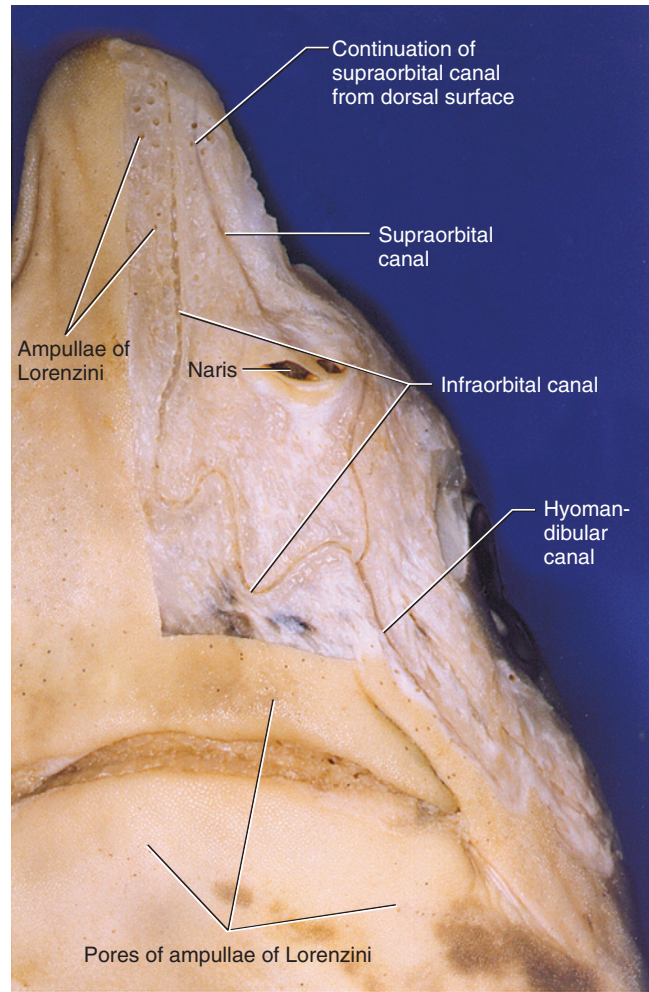
Lift the edge of an eyelid and note its soft and thin inner surface, which consists of a portion of soft, modified skin. The skin folds over and fuses onto the surface of the eyeball as the transparent **conjunctiva**. Begin the exposure of the eye by removing the soft tissue of the upper eyelid. Then cut two or three very thin slices from the top of the supraorbital crest, holding the scalpel horizontal. This will clearly reveal the semicircular margin of the **orbit**, the space housing the **eyeball** and various other structures. Continue to remove the crest. Make a few vertical slices and follow the semicircular margin as you make your way toward (but not to) the medial wall of the orbit. Stop after you have removed a thickness of about 3 mm of cartilage. The eyeball is covered by a gelatinous connective tissue. Carefully remove the latter.

Observe the eyeball's medial surface as well as some of the extrinsic muscles of the eyeball that extend between it and the orbital wall. Identify the **superficial ophthalmic nerve**, a strand about one-third the width of the





(a)



(b)

**FIGURE 3.35** Head of the shark partially skinned in (a) dorsal and (b) ventral views to reveal the lateral line system.

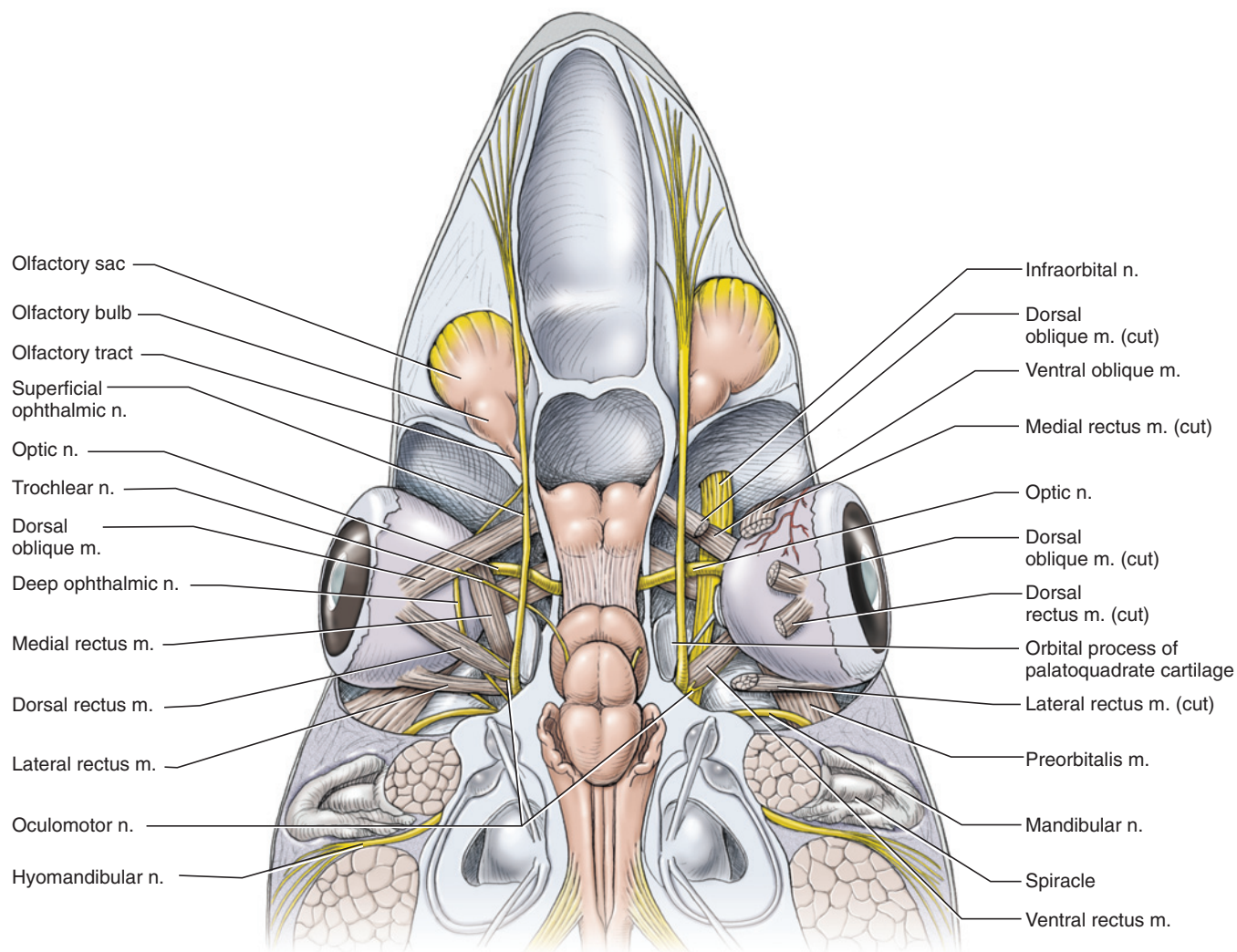
muscles, which passes anteroposteriorly along the dorso-medial wall of the orbit. Once the nerve is located, continue to remove cartilage to expose the orbit more completely, but do not cut into the otic capsule. Remove any other connective tissue, but avoid injuring the nerves in the orbit. You now have a dorsal view of the orbit and its contents (Figure 3.36).

The two groups of extrinsic eye muscles are the obliques and rectus muscles. There are two obliques, which pass posterolaterally from the anteromedial wall of the orbit. In dorsal view the **dorsal oblique muscle** is clearly evident. To find the **ventral oblique muscle**, push the lateral part of the eyeball posteriorly and peer below the dorsal oblique.

The four rectus muscles radiate toward the eyeball from the posteromedial wall of the orbit. Three are clearly evident in dorsal view. The **lateral rectus muscle** extends almost directly laterally and attaches to the posterior surface of the eyeball. The **medial rectus muscle** passes

anteriorly and attaches to the medial surface of the eyeball. The **dorsal rectus muscle** extends between the lateral and medial rectus muscles and attaches to the top of the eyeball. The fourth muscle, the **ventral rectus muscle**, will be seen more completely once the eyeball has been removed. For now, probe gently between the dorsal and lateral rectus muscles to find the ventral rectus. Avoid injuring the thin nerves that wind around the muscles.

By probing between the medial and dorsal rectus muscles, observe how the **optic pedicle** provides support for the eyeball (Figure 3.37). Tug the eyeball laterally and identify the **deep ophthalmic nerve**, a thin, whitish strand passing anteroposteriorly through the orbit and adhering to the medial surface of the eyeball. Using needle and forceps, separate the nerve from the eyeball. Next, look deep within the orbit, where the ventral oblique and medial rectus muscles converge toward the eyeball. Note the thick **optic nerve** extending from the medial wall of the orbit laterally to the eyeball.



**FIGURE 3.36** Head of the shark in dorsal view showing the chondrocranium shaved down to reveal the brain, sensory organs, and nerves.

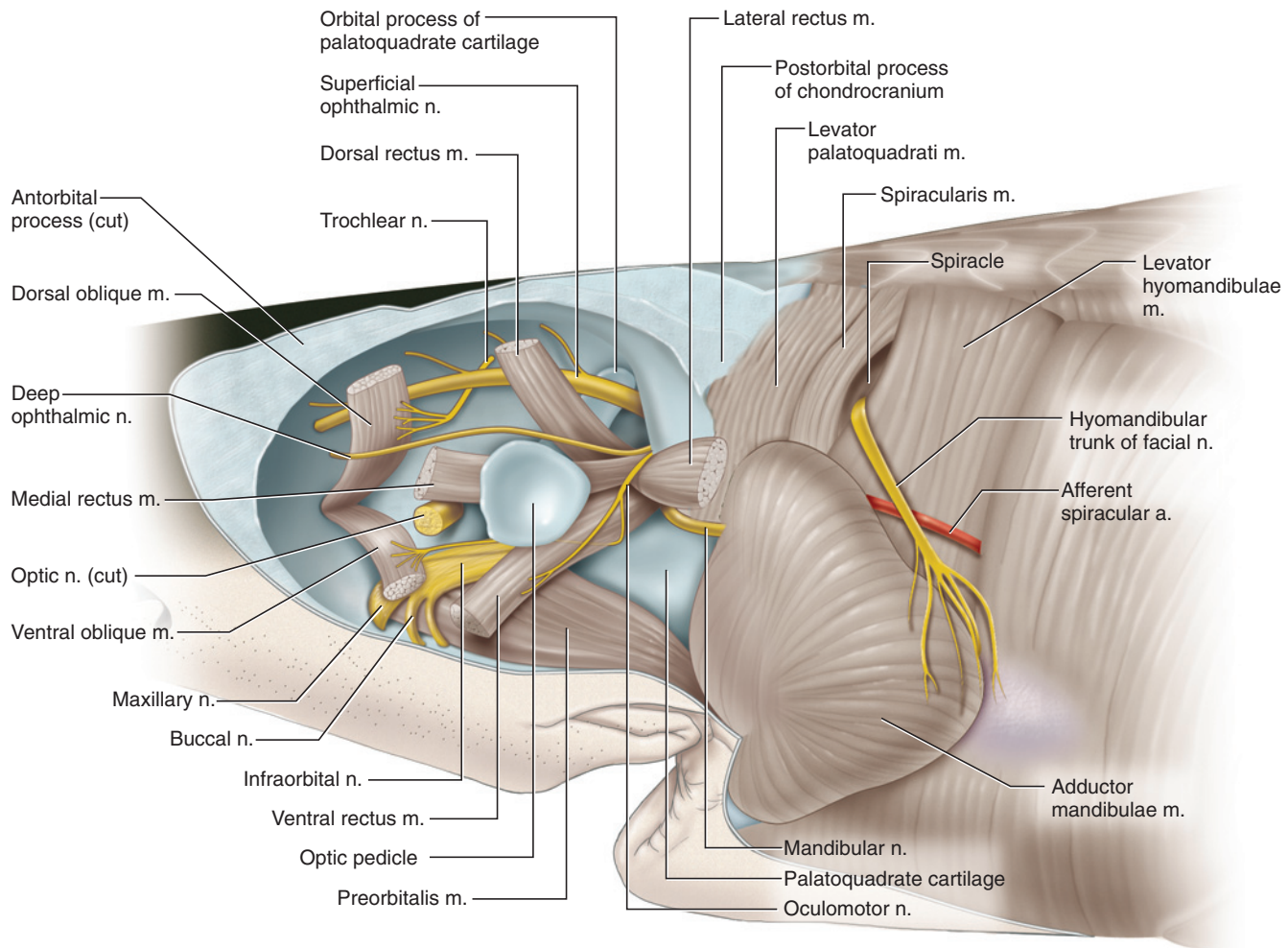
Remove the eyeball by cutting the oblique and rectus muscles near their insertions. Be careful not to injure the thin, whitish strands that pass to or near the muscles. These are nerves that must still be identified. Separate the eyeball from the optic pedicle. Also, cut through the optic nerve and the tissue between the eyeball and lower eyelid. Finally, pick away connective tissue ventrally in the orbit.

Observe the orbit in lateral view and review the structures already identified: oblique and rectus muscles, superficial and deep ophthalmic nerves, optic nerve and optic pedicle (Figure 3.37). Lift the ventral rectus and observe the thick **infraorbital nerve** passing anteriorly and slightly ventrally (Figures 3.36 and 3.37). It is nearly as wide as any of the extrinsic muscles. Carefully picking away tissue where the nerve meets the anteroventral orbital wall reveals that the infraorbital

nerve subdivides. As the nerve passes through the orbit, it crosses over the **preorbitalis muscle** (Figure 3.41). The preorbitalis muscle is about twice as wide as the extrinsic muscles and passes anteromedially across the floor of the orbit.

Trace the path of the superficial ophthalmic nerve and note the orbital process of the palatoquadrate (Figure 3.37; see also page 28 and Figure 3.3) that lies medial to the posterior half of the nerve. Next, follow the course of the deep ophthalmic nerve. It passes forward in the orbit, ventral to the dorsal rectus and dorsal oblique muscles. Lift the dorsal oblique muscle and observe the deep ophthalmic nerve and stalk of the optic pedicle. Just ventral to the deep ophthalmic is the **oculomotor nerve**. The latter passes almost immediately ventrally and around the margin of the ventral rectus. The lateral rectus muscle is innervated by the **abducens**





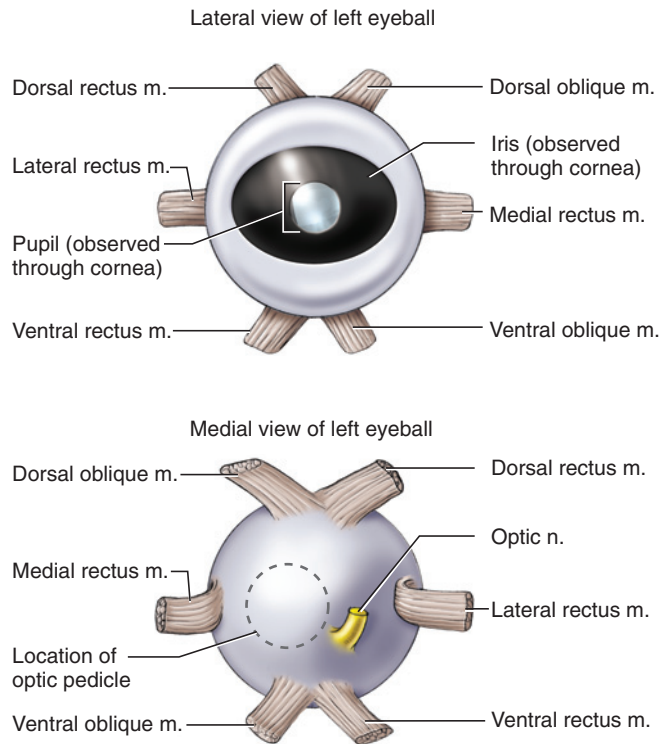
**FIGURE 3.37** Head of the shark in left lateral view. The head has been skinned and the left eyeball removed to show muscles and nerves in the orbit.

nerve, which you will probably not see now (see page 74). Gently tug the dorsal oblique muscle anteriorly and note the thin strand-like **trochlear nerve** passing to it. Lastly, identify the **mandibular nerve**. It lies on the posterior wall of the orbit, almost directly posterior to the lateral rectus muscle, and extends laterally.

Examine the eyeball removed earlier (Figure 3.38) and note the insertions of the extrinsic muscles. The outer surface of the eye is the **fibrous tunic**. Its lateral portion is modified into the transparent **cornea**. The remainder is the mainly cartilaginous **sclera**, which helps support the eyeball. The pigmented structure visible through the cornea is the **iris**, which has a circular opening, the **pupil**, at its center, through which light enters the eye. Section the outer eyeball transversely and refer to Figure 3.39 to help identify the following structures. The **lens** is the hard spherical structure. Carefully cut through the pigmented tissue, the **ciliary body** (see below), that attaches to the lens, but only cut around half of the circumference of the lens so that it remains attached to the

half of the eyeball that you will examine. The **vascular tunic** is the dark pigmented layer internal to the sclera, and most of it consists of the **choroid**. The medial wall of the eyeball, where the optic pedicle attaches, contains the **suprachoroidea**, a vascular tissue between the choroid and sclera.

The iris, noted above, is a modified part of the vascular tunic. It extends between the cornea and the lens; the pupil is the opening in the iris. The iris contains some of the eye's intrinsic musculature. These smooth muscles act to control the size of the pupil, thus regulating the amount of light that enters the eye. Another modified part of the vascular tunic forms the ciliary body, which holds the lens in place. It is the tissue you cut through to free the lens from one half of the eyeball. The ciliary body also contains some of the eyeball's intrinsic musculature that here helps control the shape of the lens. The light-colored tissue internal to the choroid is the **retina**, the light-sensitive layer that contains the photoreceptors responsible for absorbing light. Note that it



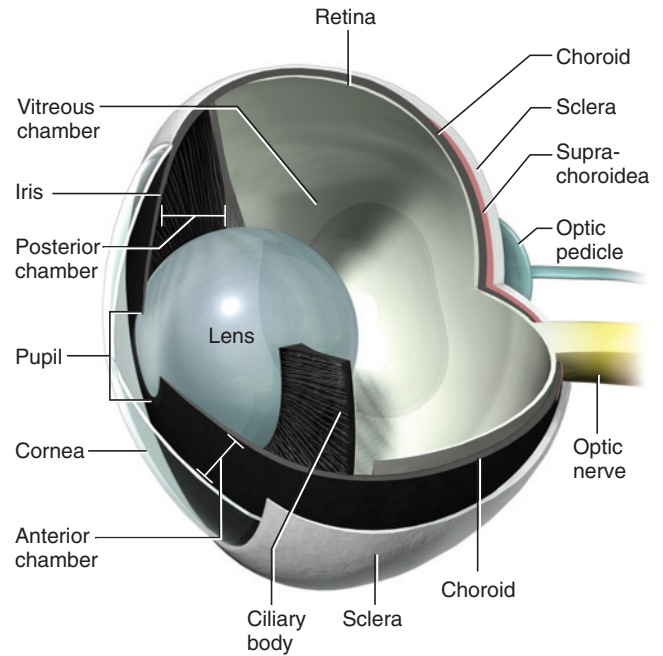
**FIGURE 3.38** Eyeball of the shark in lateral and medial views.

is an incomplete layer, extending to about the base of the ciliary body. It is not tightly interconnected with the choroid, and when the eye is cut open the retina tends to become detached. The large cavity of the eye medial to the lens is the **vitreous chamber**. It is filled by a gelatinous mass, the **vitreous humor**, which helps maintain the eyeball's shape and holds the retina in place. The smaller cavity lateral to the lens is subdivided by the iris into the **anterior chamber** and the **posterior chamber**, and filled with the watery **aqueous humor**.

## Ear

The paired inner ears of the dogfish are organs of balance or equilibrium and are embedded in the otic capsules of the chondrocranium. Each ear consists of a series of ducts and sacs, collectively termed the *membranous labyrinth*. The ducts and sacs are suspended in a series of canals and chambers, the cartilaginous labyrinth, within the otic capsule. The membranous labyrinth is filled with a fluid termed *endolymph*. Movement of the endolymph within the canals leads to perception of the orientation and position of the body.

The membranous labyrinth is formed of three thin, semicircular ducts and the saccus (Figures 3.40 and 3.41). The **anterior** and **posterior semicircular ducts** are vertically oriented. The third duct, the **lateral semicircular duct**, lies mainly horizontally. The **sacculus**, a large, triangular, sac-like structure, extends between

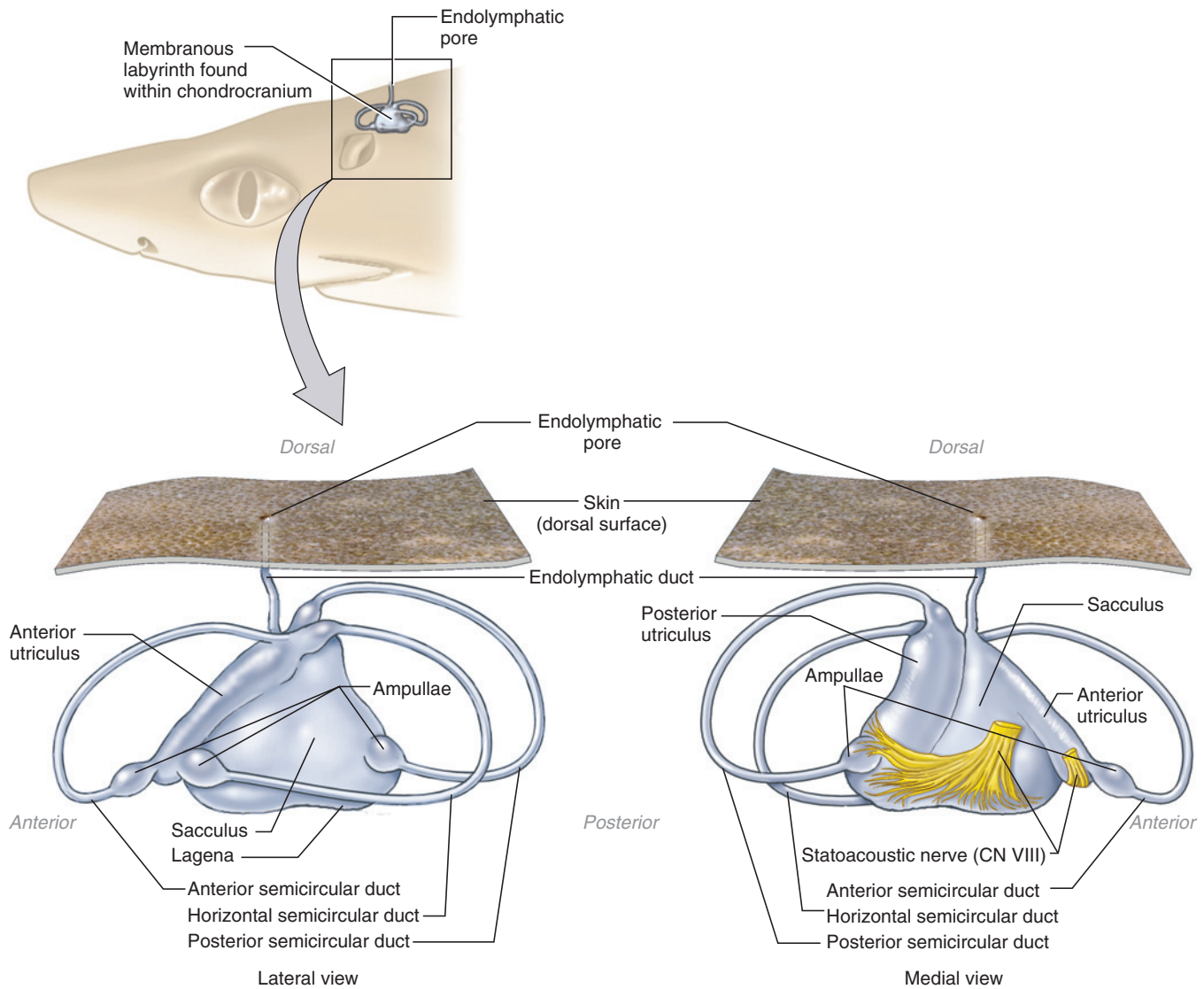


**FIGURE 3.39** 3-D cutaway illustration of the left eyeball of the shark in posterolateral view revealing internal structures.

the vertical ducts and medial to the lateral duct. The **endolymphatic duct** extends dorsally from the saccus and reaches the exterior surface of the head through the endolymphatic pores. Two cylindrical chambers, the **anterior** and **posterior utriculi**, are closely associated with the saccus. Each utricle communicates with the saccus by way of small openings. The ends of each duct attach to one of the utriculi. Those of the anterior and lateral semicircular ducts attach to the anterior utricle, those of the posterior semicircular duct to the posterior utricle.

The ear may be examined by shaving away the cartilage of the otic capsule. Before beginning, study a preparation of the ears. Such preparations usually have the chondrocranium embedded in an acrylic block. The form and position of the canals and chambers, injected with red latex, are clearly discernable.

Start your dissection by removing skin and musculature from around an otic capsule. Using a fresh scalpel blade, shave away thin slices of cartilage from one of the otic capsules, beginning dorsally. The slices should be thin enough so that you clearly see the blade through the cartilage. As you progress ventrally, you will probably need to remove more musculature laterally, as well as the spiracle. The dorsal portions of the anterior and posterior semicircular canals will become apparent through the cartilage. Carefully continue to remove cartilage to cut into the canals. The thin, tube-like semicircular ducts of the membranous labyrinth will then be exposed. As you proceed ventrally, you will also



**FIGURE 3.40** Membranous labyrinth of the inner ear of the shark in lateral and medial views.

uncover the large central cavity housing the saccus. The cavity lies medial to the lateral semicircular canal and increases in size ventrally. Careful dissection will reveal the saccus, but it is often collapsed in the floor of the cavity. The position of the **lagena**, a posteroventral extension of the saccus, may be discerned by probing the floor of the saccus.

### KEY TERMS: SENSORY ORGANS

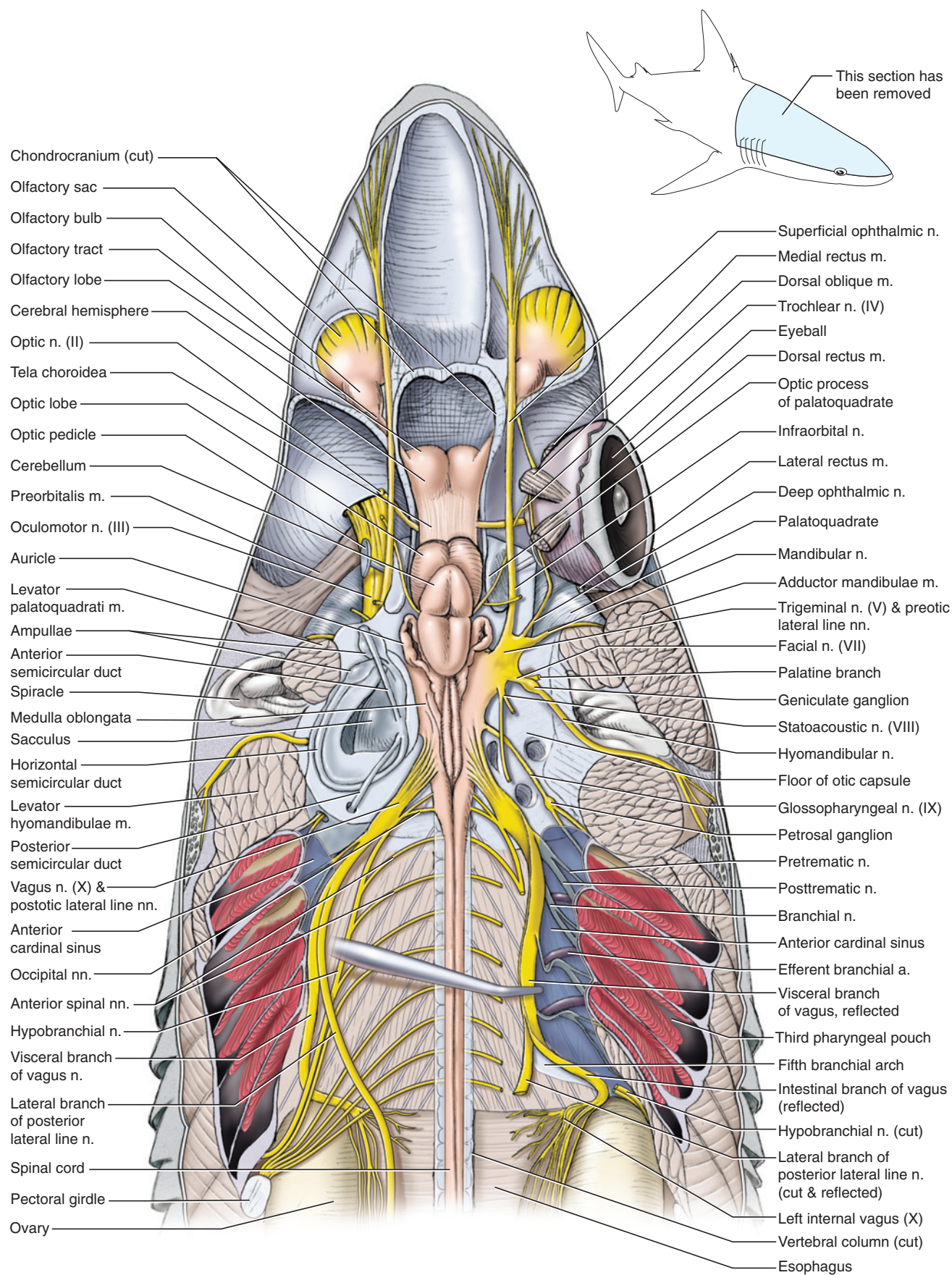
abducens nerve  
 ampullae of Lorenzini  
 anterior chamber  
 anterior semicircular duct  
 anterior utricle  
 aqueous humor

choroid  
 ciliary body  
 conjunctiva  
 cornea  
 deep ophthalmic nerve  
 dorsal oblique muscle

dorsal rectus muscle  
 endolymphatic duct  
 eyeball  
 fibrous tunic  
 infraorbital nerve  
 iris  
 lagena  
 lateral line canal  
 lateral rectus muscle  
 lateral semicircular duct  
 lens  
 mandibular nerve  
 medial rectus muscle  
 oculomotor nerve

olfactory sacs  
 optic nerve  
 optic pedicle  
 orbit  
 posterior chamber  
 posterior semicircular duct  
 posterior utricle  
 preorbitalis muscle  
 pupil  
 retina  
 saccus  
 sclera





**FIGURE 3.41** Head and branchial region of the shark in dorsal view. Cartilage and soft tissue have been shaved down to reveal brain, nerves, and sensory organs. The right side auditory region has been shaved down farther ventrally than the left side. Left eyeball has been removed.



superficial ophthalmic  
nerve  
suprachoroidea  
trochlear nerve  
vascular tunic

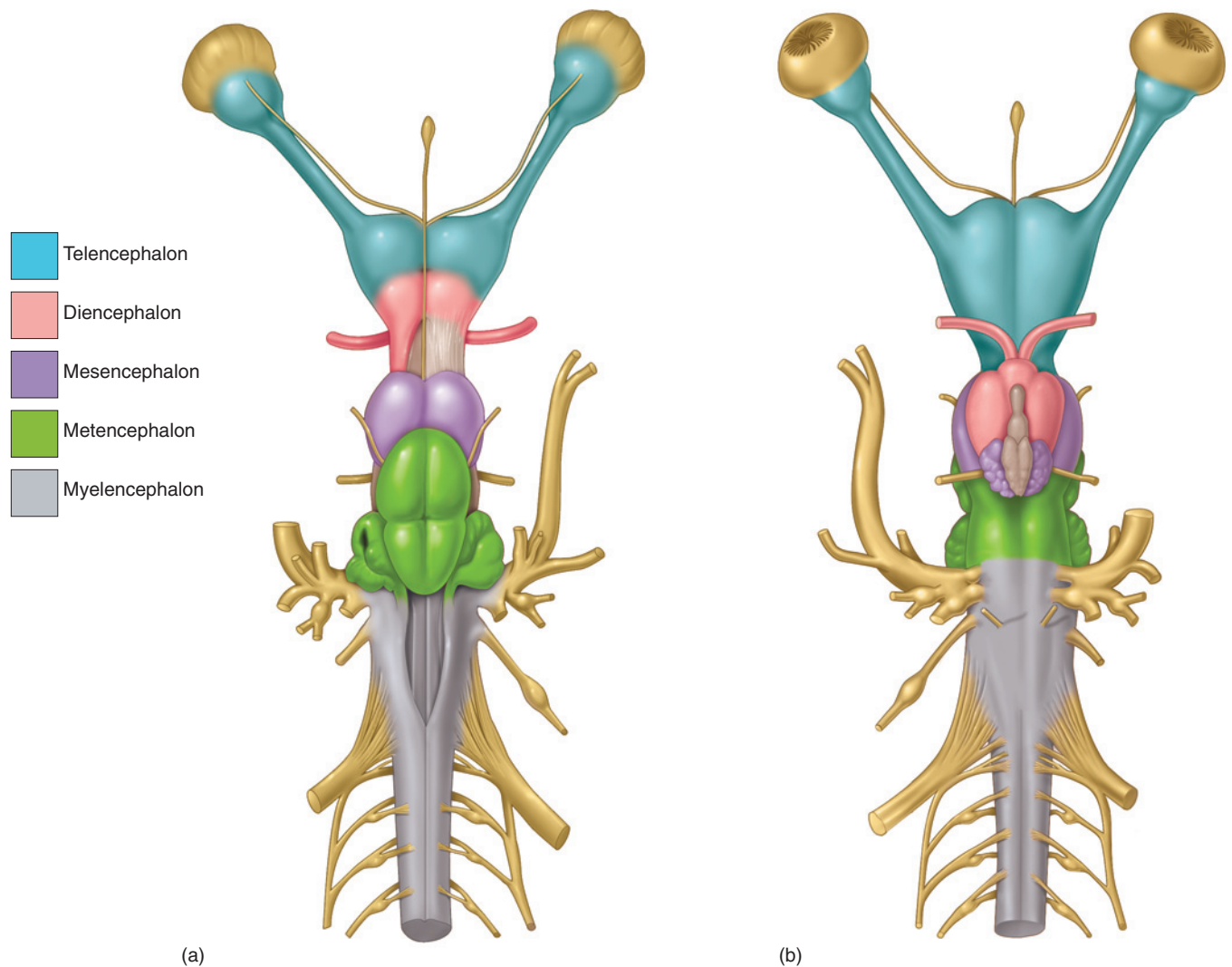
ventral oblique muscle  
ventral rectus muscle  
vitreous chamber  
vitreous humor

## SECTION VIII—BRAIN AND CRANIAL NERVES

The brain and cranial nerves (Figures 3.41–3.45; Table 3.1) should be exposed by removing thin slices of cartilage from the roof of the chondrocranium, as was done

**TABLE 3.1** The cranial nerves and their branches of the shark.

NUMBER	NERVE	BRANCHES	NERVE FORMED
CN 0	Terminal n.		
CN I	Olfactory n.		
CN II	Optic n.		
CN III	Oculomotor n.	Various branches, mainly to the ventral rectus, and dorsal, ventral, and medial oblique muscles	
CN IV	Trochlear n.		
CN V	Trigeminal n.	Superficial ophthalmic branch Deep ophthalmic branch Mandibular branch Maxillary branch	Infraorbital n. Superficial ophthalmic n.
Preotic lateral line nerves	ADLLN	Anterodorsal lateral line n. Buccal branch Superficial ophthalmic branch	
	OLLN	Otic lateral line n.	
	AVLLN	Anteroventral lateral line n.	Hyomandibular n.
CN VI	Abducens n.		
CN VII	Facial n.	Hyomandibular branch Palatine branch	
CN VIII	Statoacoustic n.		
CN IX	Glossopharyngeal n.	Pretrematic branch Posttrematic branch Pharyngeal branch	
Postotic lateral line nerves	MLLN	Middle lateral line n.	
	STLLN	Supratemporal lateral line n.	
	PLLN	Posterior lateral line n. Lateral branch Dorsal branch (not discussed in text) Ventral branch (not discussed in text)	
CN X	Vagus n.	Visceral branch: four branchial branches, each with pretrematic, posttrematic, and pharyngeal branches Intestinal branch Accessory branch (not discussed in text)	
	Occipital nn.		Hypobranchial n.
	Anterior spinal nn.		



**FIGURE 3.42** Brain of the shark in (a) dorsal and (b) ventral views, with regions of the brain color-coded.

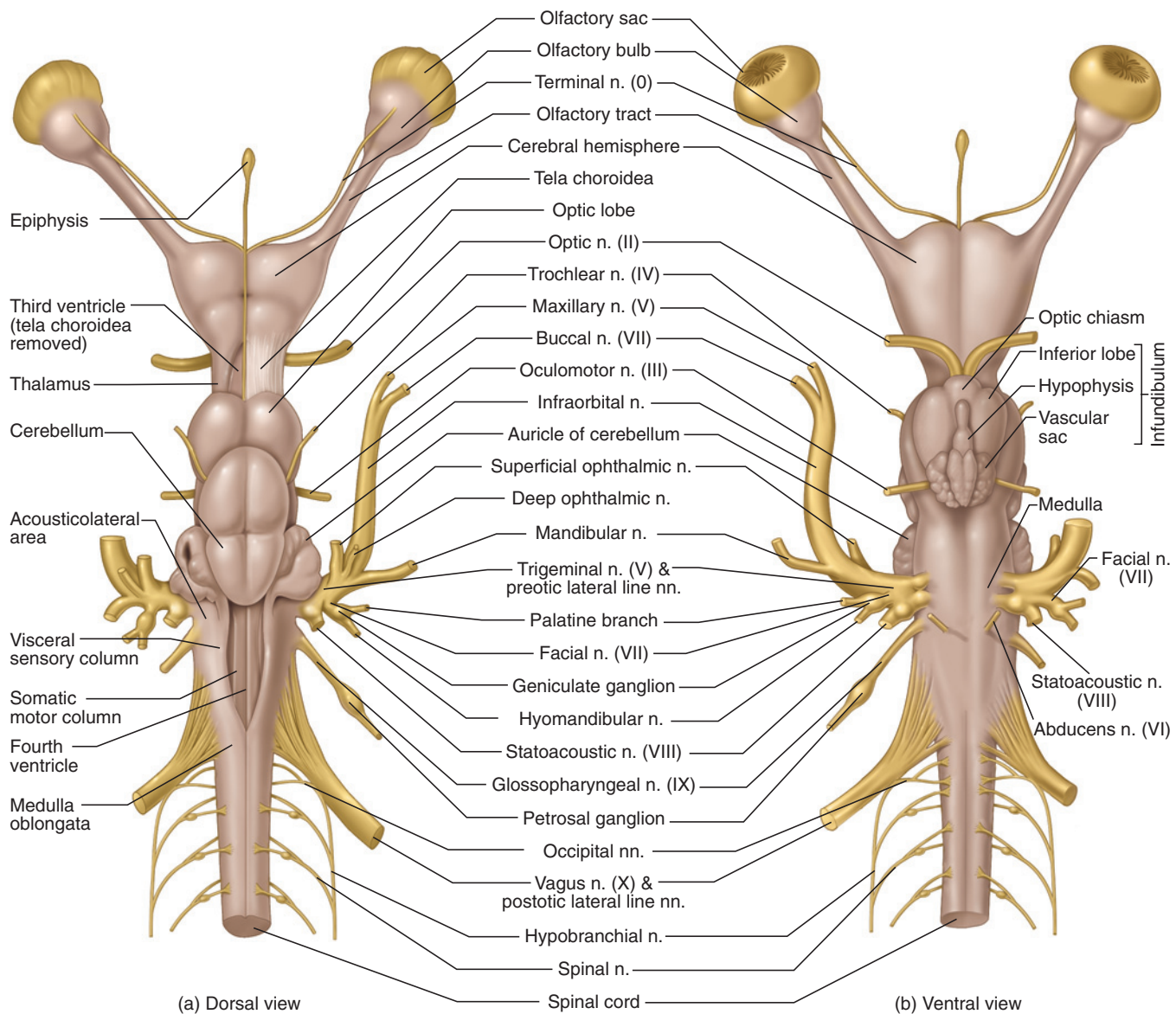
for the ear. Earlier dissections of the ear and eye probably destroyed some of the cranial nerves that must still be identified, so look for these structures mainly on the intact side of the head. Work carefully in removing the cartilage forming the dorsal roof of the orbit to avoid injuring the superficial ophthalmic nerve. The nerve was noted on page 63, but its connections to the rest of the nervous system may now be followed.

The brain sits in the large cranial cavity within the posterior part of the chondrocranium. Begin exposing the brain posteriorly, between the otic capsules. As you work your way forward, peer into the anterior part of the cranial cavity and you may be able to see the thin, strand-like **epiphysis** (Figures 3.43–3.45) extending from the brain dorsally to the epiphyseal foramen (see page 28) in the roof of the chondrocranium. Continue to shave the roof and as much of the lateral walls of the cavity as you can without injuring the nerves. When you have finished opening the cranial cavity, the dorsal

surface of the brain will be revealed. Work carefully, as the brain is easily scrambled by poking with sharp instruments. Also remove thin frontal slices, mainly of muscle tissue, posterior to the chondrocranium until you expose the vertebral column. Shave down the neural arch dorsally and laterally. Stop when you can clearly see, through the cartilage, the **spinal nerves** extending laterally from the spinal cord.

## Brain

The brain is subdivided into the following five regions, in anterior to posterior order: **telencephalon**, **diencephalon**, **mesencephalon**, **metencephalon**, and **myelencephalon** (Figure 3.42). The telencephalon includes the **olfactory bulbs** anteriorly (Figure 3.43). The olfactory sacs (see page 63) lie anterior to the bulbs. The bulbs narrow into the **olfactory tracts**, which in turn extend into the **cerebral hemispheres**. Together these constitute the **cerebrum**. The diencephalon lies posterior to the



**FIGURE 3.43** Brain and cranial nerves of the shark in (a) dorsal and (b) ventral views.

cerebral hemispheres. Its roof is the **epithalamus**, its sides the **thalamus**, and its floor the **hypothalamus**. The epiphysis attaches posteriorly on the epithalamus. Most of the epithalamus is formed by a thin, vascular **tela choroidea**. Anteriorly the tela choroidea attaches to the cerebrum. Carefully remove the tela choroidea to reveal the **third ventricle** (Figures 3.43 and 3.45), the cavity of the diencephalon that contains various vascular structures such as the **choroid plexus**, which is an extension of the tela choroidea and is involved in production of cerebrospinal fluid. Anteriorly the third ventricle leads, through the **foramen of Monro**, into left and right **lateral ventricles**, which lie respectively within the left and right cerebral hemispheres.

The mesencephalon includes a pair of rounded **optic lobes**. The main structure of the metencephalon is the

large **cerebellum**, which partially overhangs the optic lobes anteriorly and the myelencephalon posteriorly. The **auricles** of the cerebellum project anterolaterally from the posterior end of the metencephalon. The myelencephalon includes nearly all of the **medulla oblongata**, the posterior part of the brain than narrows into the spinal cord. The roof of the medulla oblongata is covered by a tela choroidea, which extends anteriorly to cover the roof of each auricle as well. Removing the tela choroidea reveals the **fourth ventricle**, the cavity of the medulla. The internal floor and sides of the medulla have various longitudinal ridges and grooves. The two large midventral ridges, one on either side of the midventral groove, are the **somatic motor columns**. Lateral to each column is a deep longitudinal depression. A second, large pair of ridges extends longitudinally on the wall of the medulla lateral to these depressions.

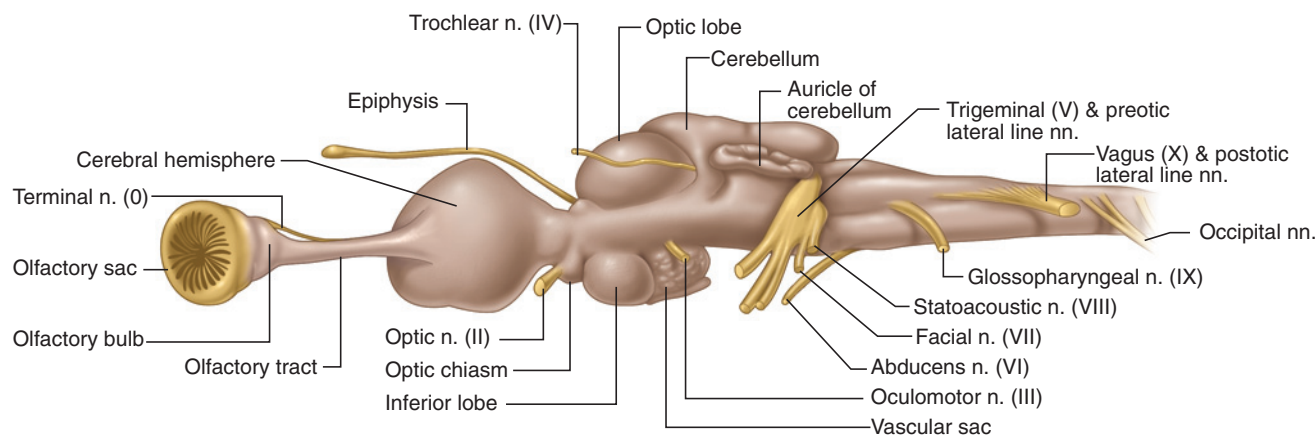


FIGURE 3.44 Brain and cranial nerves of the shark in left lateral view.

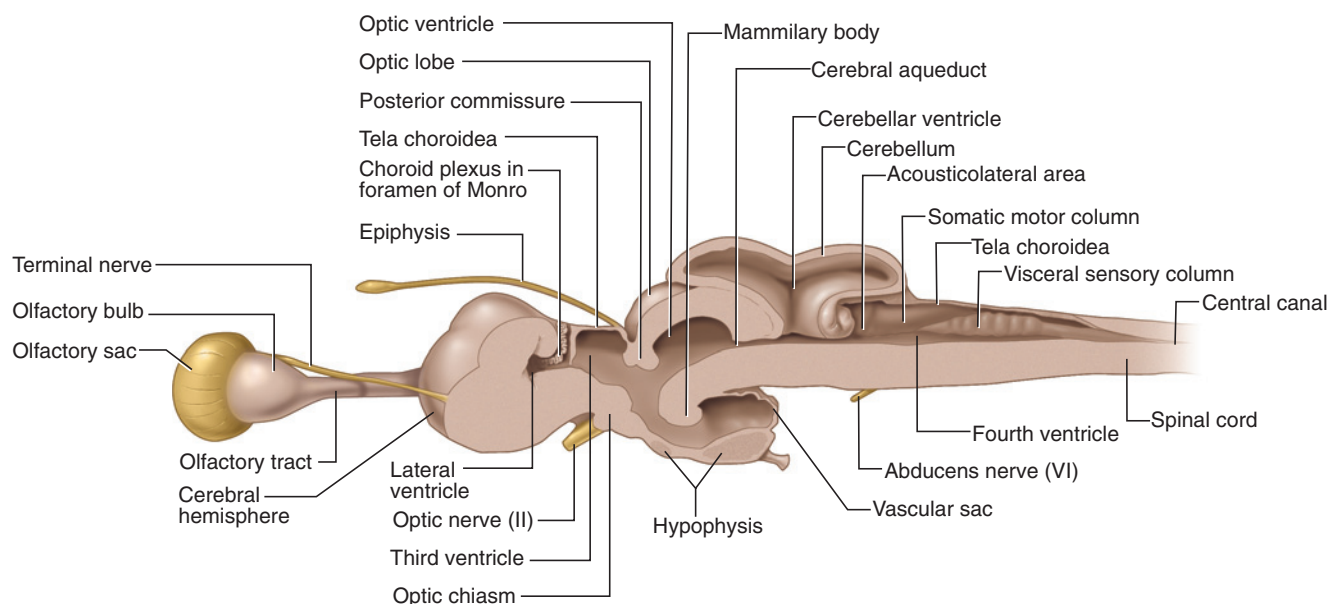


FIGURE 3.45 Right half of the brain of the shark, showing sagittal surface.

These are the **visceral sensory columns**. Deep within the depression (thus between the somatic motor column and visceral sensory column) is a much smaller column, the **visceral motor column**. Finally, there is a large longitudinal ridge dorsal to each visceral sensory column. This is the **somatic sensory column**, and its surface has the form of small, bead-like swellings. Anteriorly the somatic sensory column becomes enlarged and forms the **acousticolateral area**.

### Cranial Nerves (CNN 0, I–X, and Lateral Line Nerves)

This section mainly examines the cranial nerves, but the occipital and the anterior spinal nerves must also be considered to properly comprehend the pattern and distribution of the nerves arising from the brain. Many of the nerves attach to the ventral surface of the brain, but their proximal ends will be examined shortly. Thus, unless

otherwise instructed, do not jump ahead and study the other structures of the brain. Remove as much cartilage as possible from the lateral wall of the cranial cavity and of the neural arch without damaging the nerves. Also, clean the orbit of connective tissue, as was done for the other eye during examination of the orbit.

The cranial nerves of vertebrates were first studied in humans, and the sequence and names of the nerves were based on the pattern in humans. Twelve nerves were initially recognized and they were given both name and Roman numeral designations (see Table 7.5). A small anterior nerve, the terminal nerve, was discovered later to be present in almost all vertebrates (but not birds). As it is anterior to CN I, it was designated as “0” (zero—which is not a Roman numeral!). These cranial nerves and their designations became commonly accepted, as their pattern is generally applicable to all amniotes.



This sequence, however, does not apply equally well to anamniotes, in which the final two nerves, the **accessory (CN XI)** and **hypoglossal nerves (CN XII)**, are not definitively recognized. Further, many anamniotes also have a set of six additional cranial nerves associated with the lateral line and electroreceptor organs. As these six nerves, termed **lateral line nerves**, are lacking in amniotes, they were never numbered and were considered to be components of some of the conventionally recognized cranial nerves. However, the lateral line nerves have their own roots and they are currently considered separate nerves, even though their separate emergence from the brain is difficult to identify grossly. They enter the brain very near cranial nerves VII and X and so may be referred to as either **preotic** or **postotic lateral line nerves**. More distally, the fibers of some do accompany those of other cranial nerves (see Table 3.1). For these reasons, they will not, with one exception, be considered in detail.

The most anterior cranial nerve is the **terminal nerve (CN 0)**, a thin nerve passing along the medial side of the olfactory tract. It is often difficult to find, but look for it where the olfactory tract meets the cerebrum. The **olfactory nerve (CN I)** is formed by many fine fibers that pass from the olfactory sac into the olfactory bulb, but they will not be seen grossly. The **optic nerve (CN II)** has already been seen (see page 64). Trace it from its attachment to the medial surface of the eyeball into the cranial cavity and then to its attachment on the diencephalon.

The **oculomotor nerve (CN III)** arises from the ventral surface of the mesencephalon and branches out to innervate four eye muscles (ventral oblique, and dorsal, ventral, and medial rectus muscles). Examine the ventral oblique and find the branch of the oculomotor that passes to it, and then trace the nerve posteriorly (see Figure 3.37). The nerve passes ventral to the ventral rectus muscle, then curves dorsally and gives off a branch to the ventral rectus muscle. It continues dorsally, crosses anterior to the base of the lateral rectus muscle and dorsal to the base of the dorsal rectus muscle, and passes medially. It gives off branches to the dorsal and medial rectus muscles and then enters the chondrocranium. The oculomotor nerve can be seen leaving the brain by pushing the brain gently to the side. The slender **trochlear nerve (CN IV)** extends anterolaterally from the dorsal surface of the mesencephalon. It crosses over the optic lobe, and passes to innervate the dorsal oblique muscle.

The **abducens nerve (CN VI)**; this is discussed here, out of sequence, so that the nerves discussed in the next paragraph can be treated together) arises from the ventral surface of the medulla. Its origin will be seen later. The abducens passes anterolaterally to innervate the lateral rectus muscle. It can be found on the ventral surface of this muscle.

The next three nerves, the **trigeminal (CN V)**, **facial (CN VII)**, and **statoacoustic (CN VIII)** nerves share a close origin from the surface of the brain. In addition, the roots of the preotic lateral line nerves arise from between the roots of the trigeminal and facial nerves. All of these nerves arise in this sequence from the anterior part of the medulla, beginning just behind the auricles of the cerebellum. However, they emerge so closely together that it is difficult to identify them separately. Their peripheral distributions, however, can be readily traced. The preotic lateral line nerves include the **anterodorsal lateral line nerve (ADLLN)**, the **anteroventral lateral line nerve (AVLLN)**, and the **otic lateral line nerve (OLLN)**.

Some branches of the trigeminal, facial, and lateral line nerves merge to form larger nerves or trunks. Although some branches of the trigeminal, facial, and lateral line nerves were observed during dissection of the orbit, use the following description to review them carefully and ascertain their pattern of distribution.

The trigeminal\* is a large nerve that divides into four branches on emerging from the cranial cavity into the orbit. These are the **superficial ophthalmic**, **deep ophthalmic**, **mandibular**, and **maxillary branches**. The first branch is accompanied by the superficial ophthalmic branch of the ADLLN, the second branch by the buccal branch of the ADLLN (Table 3.1). The superficial ophthalmic branch is the most dorsal and passes just ventral to the dorsal margin of the orbit. Anteriorly, the infra-orbital divides into separate maxillary (medially) and buccal (laterally) nerves. The deep ophthalmic branch passes through the orbit but adheres to the dorsomedial surface of the eyeball. The mandibular branch extends laterally along the posterior wall of the orbit, almost directly posterior to the lateral rectus muscle. The maxillary branch contributes to the formation of the **infra-orbital nerve**, the large nerve passing along the floor of the orbit and crossing the preorbitalis muscle.

The facial nerve has two branches. One is the **hyomandibular branch**, which forms the hyomandibular nerve with the AVLLN. The hyomandibular nerve was observed as it passed toward the spiracle on the external surface of the levator hyomandibulae muscle (page 41). Trace it now from the brain, carefully cutting away portions of the musculature, ear, and spiracle. Near its origin, the hyomandibular branch bears a swelling, the **geniculate ganglion**. The second branch of the facial is the **palatine branch**, which participates in the innervation of the lining of the oral cavity.

\*The Trigeminal nerve (CN V) is termed the trigeminal because in amniotes it has three branches. These branches are named but also designated as V<sub>1</sub>, V<sub>2</sub>, and V<sub>3</sub>. The trigeminal of anamniotes, however, has four branches.

The statoacoustic nerve is a short nerve that innervates the ear. Remove cartilage of the otic capsule to see branches passing, in particular, to the ampullae of the semicircular ducts and the sacculus.

The **glossopharyngeal nerve (CN IX)** arises posterior to the statoacoustic nerve. It extends posterolaterally through the floor of the otic capsule to the first pharyngeal pouch. Pick away the cartilage of the otic capsule to follow the nerve. Note the swelling, the **petrosal ganglion**, along the nerve just before it emerges from the capsule. Very near the dorsal margin of the pharyngeal pouch, the glossopharyngeal divides into pretrematic and posttrematic branches (remember that *trema* refers to the slit, or opening, of the pouch).

The three postotic lateral line nerves are the **middle lateral line nerve (MLLN)**, the **supratemporal lateral line nerve (STLLN)**, and the **posterior lateral line nerve (PLLN)**. Their roots emerge from the brain between the glossopharyngeal (CN IX) and vagus (CN X) nerves. The peripheral distribution of the PLLN will be traced below.

The **vagus nerve (CN X)** mainly innervates the remaining pharyngeal pouches and the viscera. Note the series of fan-like rootlets emerging from the medulla just posterior to the glossopharyngeal nerve. These include the roots of the lateral line nerves, more anteriorly, and of the vagus, more posteriorly. However, it is not practical to attempt to separate them. The roots of the vagus and PLLN merge and pass posterolaterally through the otic capsule. Follow them posteriorly, removing cartilage and soft tissue as required. The vagus and PLLN separate just medial to the first pharyngeal pouch. The PLLN lies medial to the vagus and curves posteromedially as it extends between the epaxial and hypaxial musculature to innervate the lateral line canal in the trunk.

The vagus has two main parts, the visceral and intestinal branches. The visceral branch may be observed as it passes over the pharyngeal pouches and gives rise to four **branchial branches**, one each to all but the most anterior pharyngeal pouch (which is innervated by the glossopharyngeal nerve). Reflect the visceral branch of the vagus and follow the branchial branches laterally (Figure 3.4). They lie along the floor of the anterior cardinal sinus (see pages 43 and 58). Like the glossopharyngeal, each branchial branch subdivides into pretrematic, posttrematic, and pharyngeal branches. The intestinal branch continues posteriorly after the last of the branchial branches. Medial to the last branchial pouch, it turns sharply medially. Dissect carefully here, as other nerves cross it dorsally (see below). The intestinal then continues ventrally into the pleuroperitoneal cavity, passing initially along the esophagus. This portion may also be seen by turning your specimen on

its dorsal surface, slitting open the posterior cardinal sinus, and examining the dorsomedial wall of the sinus.

Return to the nerves crossing the intestinal branch of the vagus, noted in the preceding paragraph. The large nerve is the **hypobranchial nerve**, which passes ventrally to innervate the hypobranchial musculature. A smaller nerve, a spinal nerve, passes just posterior to the hypobranchial in this region. Trace the hypobranchial antero-medially as it passes deep to the PLLN. Note that the hypobranchial becomes gradually thinner as you trace it toward the brain. It initially arises from the brain as two or three occipital roots (see below).

The nerves immediately posterior to the vagus of the shark, and most anamniotes, are not directly comparable to those of more derived vertebrates. In the shark these nerves merge from roots that arise from the transition between the medulla and spinal cord. They are thus formed from roots that are occipital and spinal. As a result, they are not entirely within the chondrocranium and thus are not “cranial.” There is ambiguity because the posterior end of the cranium is phylogenetically variable among anamniotes. However, they are in part homologous with cranial nerves of higher vertebrates and so are considered here.

Usually, the first two slender roots that emerge posterior to the vagus unite to form the **occipital nerve**, which then partially merges with the vagus nerve. The occipital nerve continues posteriorly and receives contributions from the first few spinal nerves, which arise posterior to the occipital nerve. The union of the occipital and spinal nerves is the hypobranchial nerve, as noted above. Each spinal nerve results from the union of a dorsal root and a spinal root that arise from the spinal cord. The roots unite a short distance from the spinal cord, and the dorsal root bears a swelling, or ganglion. In amniotes the transition between the head and the trunk becomes fixed and the occipital nerves clearly arise from the brain within the skull as a “cranial” nerve termed the **hypoglossal nerve** (see page 222). Thus, the hypobranchial nerve of the shark (and other anamniotes) is homologous with the hypoglossal (CN XII) of amniotes. As noted above, the accessory nerve (CN XI) of higher vertebrates (mainly derived from the vagus), is not represented as a distinct nerve in the shark.

## Ventral View of the Brain

When you are familiar with the cranial nerves, the brain may be removed from the chondrocranium. Cut the olfactory tracts and then across the spinal cord just posterior to the medulla. Lift the anterior part of the brain, and locate and cut the optic nerves. Continue to cut each of the cranial nerves, leaving as long a stump as possible. Lift the brain laterally and note the ventral extension, the

**hypophysis**, just behind the optic nerves. Cartilage posterior to the hypophysis will have to be removed in order to free the brain entirely without damage.

Examine the ventral surface of the brain, noting its regions as described above (page 70) and the cranial nerves, particularly those that arise from ventral surface—the optic, oculomotor, and abducens. The optic nerves converge toward the anterior part of the hypothalamus and form the **optic chiasm**, where the optic nerves cross over to the opposite side of the brain (Figures 3.43 and 3.44). The rest of the hypothalamus is formed mainly by the **infundibulum**, which bears several important structures. The paired inferior lobes of the infundibulum lie just posterior to the optic chiasm. Posterior to each inferior lobe, the infundibulum continues as a **vascular sac**. Between the left and right inferior lobes and vascular sacs lies the hypophysis, noted above. The hypophysis is usually torn during removal of the brain. If this occurs in your specimen, examine another student's specimen.

## Sagittal Section of the Brain

The brain and spinal cord are hollow, with various connected cavities or ventricles in the brain itself, and a narrow **central canal** in the spinal cord. In life, the ventricles and central canal are filled with cerebrospinal fluid. Some of the ventricles have already been noted (see page 71), but to examine all the ventricles and their relationships to each other, cut the brain in half by making a midsagittal section using a new scalpel blade. Observe one of the halves in sagittal view and briefly review the regions of the brain before studying the ventricles (Figure 3.45).

The **third ventricle**, noted above (page 71), is the cavity of the diencephalon and communicates anteriorly with each of the **lateral ventricles** (one each in the cerebral hemispheres) through the **foramen of Munro**. The third ventricle extends into the optic lobes as the **optic ventricle**, as well as into the hypophysis. The **fourth ventricle** is the cavity of the medulla, and continues into the cerebellum as the **cerebellar ventricle**. The third and fourth ventricles are connected by a narrow canal, the **cerebral aqueduct**.

## KEY TERMS: BRAIN AND CRANIAL NERVES

abducens nerve (CN VI)	anterodorsal lateral line nerve (ADLLN)
accessory nerve (CN XI, not recognized in shark) (spinal accessory)	anteroventral lateral line nerve (AVLLN)
acousticolateral area	auricles of cerebellum

branchial branches of visceral branch of vagus nerve	oculomotor nerve (CN III)
buccal branch of facial nerve	olfactory bulbs
central canal	olfactory nerve (CN I)
cerebellar ventricle	olfactory tracts
cerebellum	optic chiasm
cerebral aqueduct (aqueduct of Sylvius)	optic lobes
cerebral hemispheres	optic nerve (CN II)
cerebrum	optic ventricle
choroid plexus	otic lateral line nerve (OLLN)
deep ophthalmic branch of facial nerve (profundus nerve)	palatine branch of facial nerve
diencephalon	petrosal ganglion
epiphysis	posterior lateral line nerve (PLLN)
epithalamus	somatic motor columns
facial nerve (CN VII)	somatic sensory column
foramen of Munro (interventricular foramen)	spinal nerves
fourth ventricle	statoacoustic nerve (CN VIII) (vestibulocochlear, octaval)
geniculate ganglion	superficial ophthalmic branch of ADLLN
glossopharyngeal nerve (CN IX)	superficial ophthalmic branch of trigeminal nerve
hyomandibular branch of facial nerve	superficial ophthalmic nerve
hypobranchial nerve	supratemporal lateral line nerve (STLLN)
hypoglossal nerve (CN XII, not recognized in shark)	tela choroidea
hypophysis	telencephalon
hypothalamus	terminal nerve
infraorbital nerve	thalamus
infundibulum	third ventricle
lateral ventricles	trigeminal nerve (CN V)
middle lateral line nerve (MLLN)	trochlear nerve (CN IV)
medulla oblongata	vagus nerve (CN X)
mesencephalon	vascular sac
metencephalon	visceral branch of vagus nerve
myelencephalon	visceral motor column
occipital nerve	visceral sensory columns

# CHAPTER 4

## THE PERCH

### INTRODUCTION

The yellow perch, *Perca flavens*, is an actinopterygian. Besides the sharks and their relatives, there are two groups of living fish-like vertebrates, the Actinopterygii, the ray-finned fishes, and the Sarcopterygii, which includes the lobe-finned fishes and their tetrapod relatives. The latter is a relatively small group, at least in terms of their fish-like forms, and includes the coelacanth and lungfishes, barely a handful of species, which is a rather dismal record as far as fish go. Conversely, the actinopterygians are a huge success story, both in terms of diversity and numbers, with about 25,000 species known (although this number varies depending on author). The fins of actinopterygians are supported by slender, rod-like rays or lepidotrichia radiating from the base of the fin; the musculature controlling the fin are within the body wall.

The actinopterygians are subdivided into two broad groups, the “palaeoniscids”, a small, paraphyletic grouping of some 40 species that includes basal forms such as bichirs (Polypteriformes) and sturgeons and paddlefishes (Acipenseriformes), and the Neopterygii, a clade that includes, clearly, the great majority of ray-finned fishes. In older classifications, the basal forms were considered chondrosteans, representative of a more primitive stage of ray-finned fishes. Neopterygians include several basal forms, such as gars and bowfins, that were grouped as “holosteans”, intermediate between the chondrosteans and the advanced ray-finned fishes, the Teleostei.

Teleosts have undergone extensive radiations to produce fishes that have invaded nearly every aquatic niche. There are far too many groups to discuss here, but we may mention the Elopomorpha (eels and tarpons), the commercially important Clupeomorpha (anchovies and herrings), and the Paracanthopterygii, another commercially important group that includes codfishes. The perch belongs to the Perciformes, a member of the Acanthopterygii, the spiny-finned fishes. Another interesting group is the Ostariophysi, which includes catfishes, characins, and minnows. These fish share a unique sound detection system, the Weberian apparatus, which

involves the swim bladder and modified elements of the first few trunk vertebrae. The vertebrae act as a conduction system between the swim bladder and the inner ear at the back of the skull. Vibrations of the swim bladder caused by sound waves are transmitted by the bony elements to a posterior extension of the ear’s membranous labyrinth, stimulating the auditory center of the brain.

### SECTION I—SKELETON

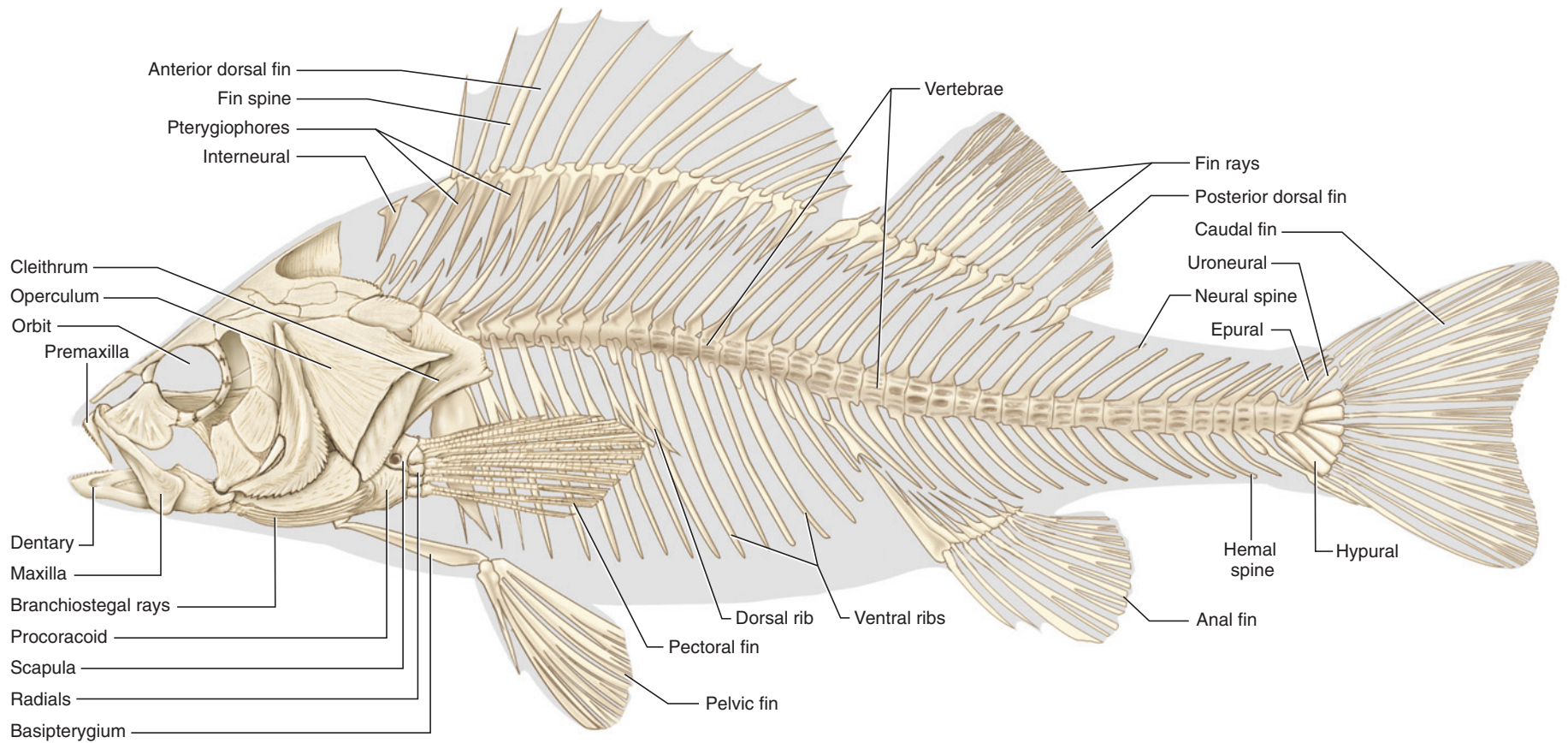
#### Skull

Examine a mounted skeleton of the perch and differentiate the **head**, **trunk**, and **tail** regions (Figure 4.1). Unlike the Chondrichthyes, the Actinopterygii have well-developed bony skeletons. This is especially evident in the head, where numerous dermal bony elements (as well as endochondral elements) produce a complex skull. It is difficult and impractical to attempt identification of all the bones of the skull unless detailed preparations of skulls in various stages of disarticulation are available. Instead it is more productive to focus on various features that are particular to bony fishes, such as the bones of the jaw mechanism and opercular region. Several other easily identifiable bones are included in this discussion for context.

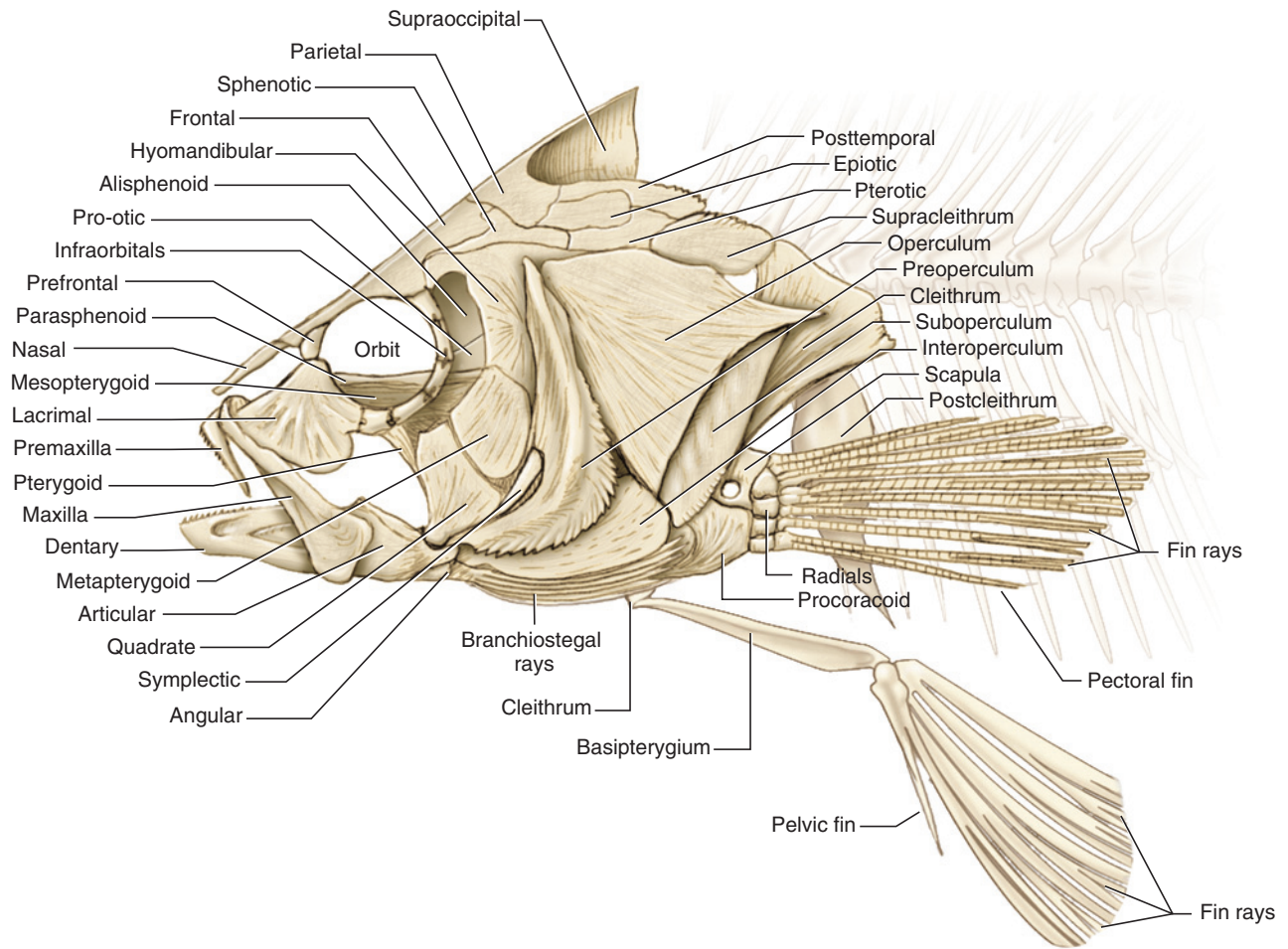
Begin by locating the opercular bones on the pharyngeal region that cover the gills (Figures 4.1 and 4.2). The **operculum** is the large, triangular bony plate. Several bones surrounding the operculum can be easily identified. The L-shaped **preoperculum** lies anterior to the operculum; the **suboperculum** posteroventral to the operculum. Ventral to the preoperculum is the **interoperculum**. The four **branchial arches** that support the gills lie deep to the opercular bones. Peer beneath the operculars to observe the arches.

Next, locate the large, circular **orbit** that houses the eyeball. Some of the deeper bones of the skull, such as the parasphenoid, are visible within the orbit. A series of bones surround and help form the orbit. Several are large and easily identifiable, such as the **frontal**, which





**FIGURE 4.1** Skeleton of the perch in left lateral view.



**FIGURE 4.2** Skull and branchial skeleton of the perch in left lateral view.

forms much of the skull roof, and the **lacrimal**, which forms the anteroventral margin of the orbit. The **maxilla** is the slender, edentulous bone articulating with the lacrimal. Its widened posterior end extends laterally and is embedded in soft tissue. Note that it does not form part of the margin of the mouth. The **premaxilla**, which bears teeth on its anteroventral surface, is the most anterior bone of the upper jaw. It articulates with the premaxilla from the opposite side, and the **nasal** and **maxilla** posteriorly. A main feature of advanced actinopterygians is their ability to protrude the premaxilla during opening of the mouth. The maxilla acts as a lever for the jaw muscles in helping to protrude the premaxilla forward.

A series of three main bones, lying between the orbit and preoperculum, extend anteroventrally. These are, in dorsal to ventral order, the **hyomandibular**, **metapterygoid**, and **quadrate**. These bones contribute to the suspensorium, the apparatus that supports the jaws on the rest of the skull. The hyomandibular and metapterygoid support the quadrate, which forms the articulation with

the lower jaw. The lower jaw is formed by three bones. The **articular** forms most of the posterior end of the lower jaw and articulates with the quadrate of the upper jaw. The **dentary**, which bears teeth, may be seen anterior to it. The **angular** is a small bone posteroventrally on the lower jaw.

### KEY TERMS: SKULL

angular	metapterygoid
articular	nasal
branchial arches	operculum
dentary	orbit
frontal	premaxilla
head	preoperculum
hyomandibular	quadrate
interoperculum	tail
lacrimal	trunk
maxilla	suboperculum

## Postcranial Skeleton

The vertebral column includes **trunk vertebrae** anteriorly and **caudal vertebrae** posteriorly (Figure 4.1). The main part of a vertebra is the **centrum**. All the vertebrae bear elongated **neural spines** dorsally. The caudal vertebrae also bear elongated **hemal spines** ventrally. The trunk vertebrae bear ribs. There are two types of ribs in the perch, the **dorsal** and the **ventral ribs**. The ventral ribs are much more prominent and are usually present in prepared specimens. These curved structures, which form in the myosepta adjacent to the body cavity (celom), extend ventrally. More delicate dorsal ribs extend laterally. They are attached ligamentously to the posterior surface of the more anterior ventral ribs, and are often missing in prepared specimens.

Examine the **anterior** and **posterior dorsal fins** on the middorsal line (Figure 4.1). The fins are supported by thin, elongated **fin rays**. These rays may be ossified, as are those supporting the anterior dorsal fin, and usually termed *spines*. Other fin rays, termed *soft fin rays*, are flexible and unossified and may branch distally. Each fin ray is supported at its base by a **pterygiophore**, a ventrally tapered bony element. The tip of a pterygiophore extends ventrally into the connective tissue between two neural spines. Note that the pterygiophore series is continuous—they extend all the way along the dorsum beneath and between the anterior and posterior dorsal fins. The separation between these fins, in fact, is due to reduction of the spines between them. The posterior dorsal fin is structured similarly to the anterior dorsal fin, except that only the first two fin rays are spines, the remainder being soft fin rays.

The **anal fin** lies along the midventral line, opposite the position of the posterior dorsal fin. As in the latter, all but the first two fin rays are soft rays. Pterygiophores support the fin rays, essentially as in the dorsal fins, but taper dorsally. The anterior few (usually two) pterygiophores fuse into a large element that extends dorsally to attach to one or two ventral ribs, which here are quite reduced in size. It is posterior to this point of attachment that the series of hemal spines begins.

The **caudal fin** is supported by soft fin rays, which are arranged to form a homocercal tail. This type of fin is superficially symmetrical with about equal numbers of fin rays dorsal and ventral to the longitudinal axis extending posteriorly from the vertebral column. However, the body axis itself turns abruptly dorsally, so it is not symmetrical internally, although this is not easy to detect with the naked eye (see below). This upward turn is easily noted in less derived teleosts, such as sturgeons. It may still be appreciated in advanced forms such as the perch by the orientation of the **uroneurals**, the last few neural spines, and the position of the **hypu-**

**als** immediately posterior to them. The hypurals, also present ventral to the uroneurals, are the flattened hemal spines of the last few caudal vertebrae and provide most of the support for the fin rays of the caudal fin. Several neural spines, termed **epurals** and unattached to vertebrae, provide some support for the dorsal part of the fin.

Lastly, examine the paired fins (Figures 4.1 and 4.2). The **cleithrum** is the main supporting element of the pectoral girdle. It is a large, dorsoventrally elongated bone that lies mainly deep to the operculum and suboperculum, and extends to the ventral midline to articulate with the cleithrum from the other side of the body. Dorsally it articulates with the **supracleithrum**, which, in turn, articulates with the **posttemporal**. The latter is attached to the posterior end of the skull. This chain of connections links the head and shoulder girdle. The **scapula** and **procoracoid** are the large skeletal elements of the shoulder girdle that directly support the fin. The scapula lies dorsal to the procoracoid. Their anterior ends lie deep to and are covered by the cleithrum. The **postcleithrum** is an elongated triangular bone that extends dorsoventrally. Its widened end lies deep to the cleithrium. It tapers ventrally, passes medial to the fin, and extends toward the pelvic fin. The **radials**, of which there are usually four, extend from the scapula or procoracoid and distally articulate with the soft fin rays supporting the fin. Movement is possible proximally (between the scapula or procoracoid and radials) and distally (between the radials and fin rays).

The pelvic girdle is formed by paired **basipterygia**. Each is a triangular plate of bone oriented anteroposteriorly and with base located posteriorly. As it passes anteriorly, the basipterygium tapers and passes dorsal to the articulation between the right and left cleithra. The fin rays of each fin attach directly to the posterior end of a basipterygium, and, except for the medial ray, are soft fin rays.

### KEY TERMS: POSTCRANIAL SKELETON

anal fin	epurals
anterior dorsal fin	fin rays
basipterygium (plur., basipterygia)	hemal spines
caudal fin	hypurals
caudal vertebrae	neural spines
centrum	postcleithrum
cleithrum	posterior dorsal fin
dorsal ribs	posttemporal



procoracoid  
pterygiophore  
radials  
scapula

supracleithrum  
trunk vertebrae  
uroneurals  
ventral ribs

## SECTION II—EXTERNAL ANATOMY

The external anatomy of the perch (Figure 4.3) is similar in several aspects to that of the dogfish shark. The body, which may be subdivided into **head**, **trunk**, and **tail** regions, is generally streamlined, not surprising in a swimming fish, and there are several fins. The constricted region connecting the trunk and tail regions is the **caudal peduncle**. Several differences are immediately apparent, however. The skin, for example, has numerous **scales**. Also, there is only a single opening on each side of the body for the exit of water from the pharynx, and the positions of the paired fins are quite different.

Examine the head (Figure 4.3). On each side it bears a large **eye**, lacking lids. Posterior to it, the preopercular region, containing the bones that help support the jaws, and the opercular region, containing the opercular bones covering the gills, are easily recognizable. The large **mouth** is terminal in the perch but may be slightly dorsal or ventral in other teleosts. Note that the **maxilla**, a bone of the upper jaw, is free posteriorly, embedded in a fold of skin, and lacks **teeth** (see also Figure 4.1). The **premaxilla** is recognizable also, at the anterior end of the upper jaw, and can slide back and forth, thus allowing the perch (and most other teleosts) to protrude its jaws. Teeth are present on the premaxilla, as well as

on the lower jaw or **mandible**. A **naris** can be found anterior to each eye. On each side of the head there are two nostrils, one anterior and the other posterior, opening into the nasal cavities. Water enters the nasal cavity through the anterior nostril and exits through the posterior nostril.

On the trunk and caudal peduncle, the prominent **lateral line** forms a distinct ridge along the scales. Other canals occur on the head but they are much less conspicuous. Using forceps, pull out one of the scales from the trunk (Figure 4.4). Most of the scale is embedded in the skin, and only a small posterior portion is exposed. This posterior end, termed the bony portion (though it is distinct from true bone), has numerous small tooth-like projections called *ctenii*. This type of scale is termed **ctenoid** (comb-like), based on the structure of its posterior end (other teleosts may have circular or cycloid scales because they lack ctenii; some lack scales). The embedded portion of the scale is made of fibrous connective tissue. Scales grow as the fish age. The concentric growth rings on the embedded portion of the scale can be used to age an individual.

There are four median fins, the **anterior dorsal fin**, **posterior dorsal fin**, **anal fin**, and **caudal fin** (Figure 4.3). Identify the anterior and posterior dorsal fins along the dorsal midline. The anterior dorsal fin is larger and is supported by ossified fin rays, as noted above. Most of the supporting fin rays in the posterior dorsal fin are unossified and flexible. The anal fin is on the ventral midline, just anterior to the tail, and is supported mainly by soft fin rays. The homocercal caudal fin is superficially symmetrical. Note the paired fins, the **pectoral** and

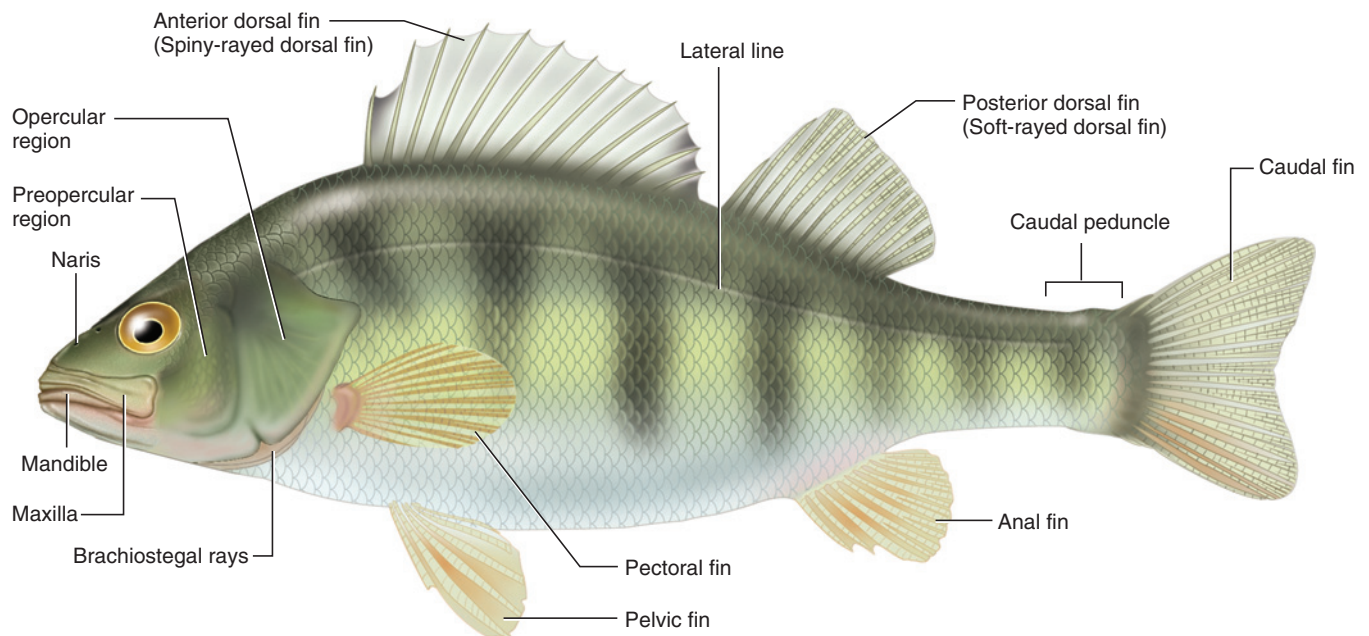


FIGURE 4.3 External features of the perch in left lateral view.



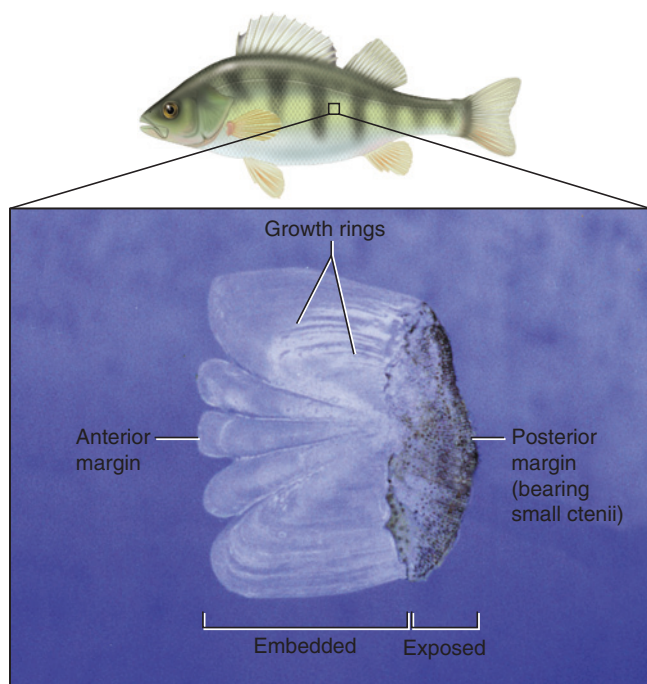


FIGURE 4.4 Detail of scale of the perch in lateral view.

**pelvic fins.** Although some teleosts (for example, the catfish) have these fins in positions comparable to those in the shark, in the perch the pectoral fin is displaced dorsally and the pelvic is displaced anteriorly.

Lastly, examine the posterior openings of the urogenital and digestive tracts. Unlike the shark, the perch does not have a cloaca. Instead, the digestive tract has a separate opening, an **anus**, the large, circular opening anterior to the anal fin. The **urogenital aperture** is considerably smaller and less evident, and lies immediately posterior to the anus. In some females (see below), however, the urogenital opening may be as large as and even larger than the anus.

### KEY TERMS: EXTERNAL ANATOMY

anal fin	mouth
anterior dorsal fin	naris (nostril)
anus	pectoral fin
caudal fin	pelvic fin
caudal peduncle	posterior dorsal fin
ctenoid	premaxilla
eye	scales
head	teeth
lateral line	trunk
mandible	urogenital aperture
maxilla	

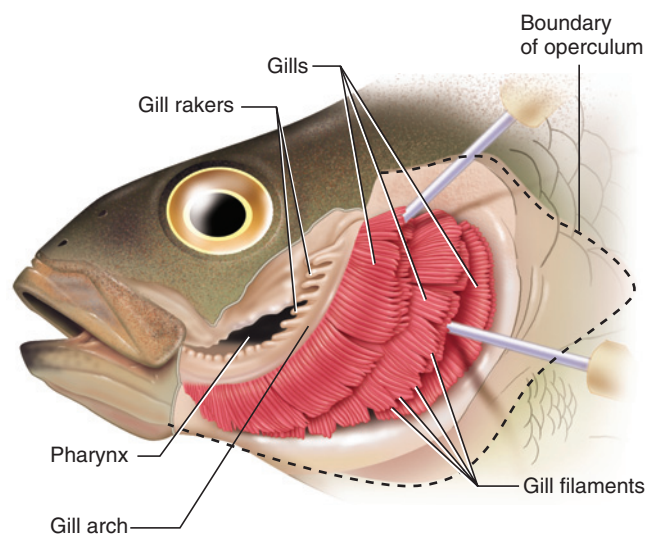


FIGURE 4.5 Gills of the perch in left lateral view.

## SECTION III—MOUTH, ORAL CAVITY, AND PHARYNX

Examine the **mouth**, which forms the anterior opening of the digestive tract. It is terminal, a position common in fish that swim to overtake their prey. Note the posterior end of the maxilla. Embedded in soft tissue, it is free to move laterally, an important feature during expansion of the oral cavity during feeding. Note the marginal series of **teeth** in the upper and lower jaws. In addition to the marginal series, there are **palatal teeth** in the roof of the **oral cavity**, and **pharyngeal teeth**, both upper and lower, in the posterior part of the **pharynx**. Postpone identifying them until the pharynx is opened (see below).

Expose the oral cavity and pharynx by removing the opercular bones as follows. Lift the free, posterior end of the operculum. Insert one blade of a stout pair of scissors beneath the surface of the operculum, at approximately the midheight of the posterior margin. Keeping the blade close to the deep surface of the operculum, cut through the bones, heading toward and through the angle of the mouth. Spread the flaps to observe the **gills**, each composed of numerous **gill filaments**, which are involved with respiration (or gas exchange) with the water flowing over them. Then cut away, bit by bit, the opercular flaps covering the gill until you have exposed the region, as shown in Figure 4.5. The most anterior of the four **branchial arches**, and the gill it supports, should be plainly visible. Manipulate the arches and gills to identify the remaining three arches. **Gill rakers** should be plainly visible on the first arch. The rakers are projections that extend inward across the pharyngeal slit. They help in feeding, preventing prey (and other

debris) from passing through the pharyngeal openings and escaping.

In respiration, water passes through the mouth and oral cavity into the pharynx. It passes over the gills and into the opercular chamber (which corresponds to the parabronchial chambers seen in the shark), the space between the gills and operculum, and then leaves posteriorly through the opening at the posterior end of the operculum. The floor of the opercular chamber is supported by the **branchiostegal rays**.

There are five passages or slits through the pharynx: Three are between the four brachial arches, one is anterior to the first arch, and another is posterior to the last arch. Each arch bears a double set of filaments. This is similar to the condition in the **holobranch** of the shark, in which gill lamellae are present on the anterior and posterior surfaces of the interbranchial septum (see page 46). In the holobranch of the perch, however, the septum is absent, so the gill filaments are positioned almost side by side. Still, they correspond to the anterior and posterior sets of lamellae of the shark, with the anterior filaments being **posttrematic** (“after the slit”) and the posterior being **pretrematic** (“before the slit”). The perch thus has four holobranchs. Unlike in the shark, there is no hemibranch (and, of course, no pseudobranch, as the spiracle is absent).

#### KEY TERMS: MOUTH, ORAL CAVITY, AND PHARYNX

branchial arches	oral cavity
branchiostegal rays	palatal teeth
gill filaments	pharyngeal teeth
gill rakers	pharynx
gills	posttrematic
holobranch	pretrematic
mouth	teeth

#### SECTION IV—PLEUROPERITONEAL CAVITY AND VISCERA

To expose the pleuroperitoneal cavity and viscera, make an incision along the midventral line, proceeding as follows. In a female with an enlarged urogenital opening, insert a scissor blade into the anterolateral margin of the aperture. Make a small incision, approximately 0.5 cm, in this direction, and then turn back anteromedially toward the midline, anterior to the anus. This will avoid injuring the digestive tract. In a specimen with a small urogenital aperture, proceed as just described, but begin by inserting the scissor blade into the anus. Continue to cut anteriorly along the midline, keeping close to the deep surface of the body wall, past

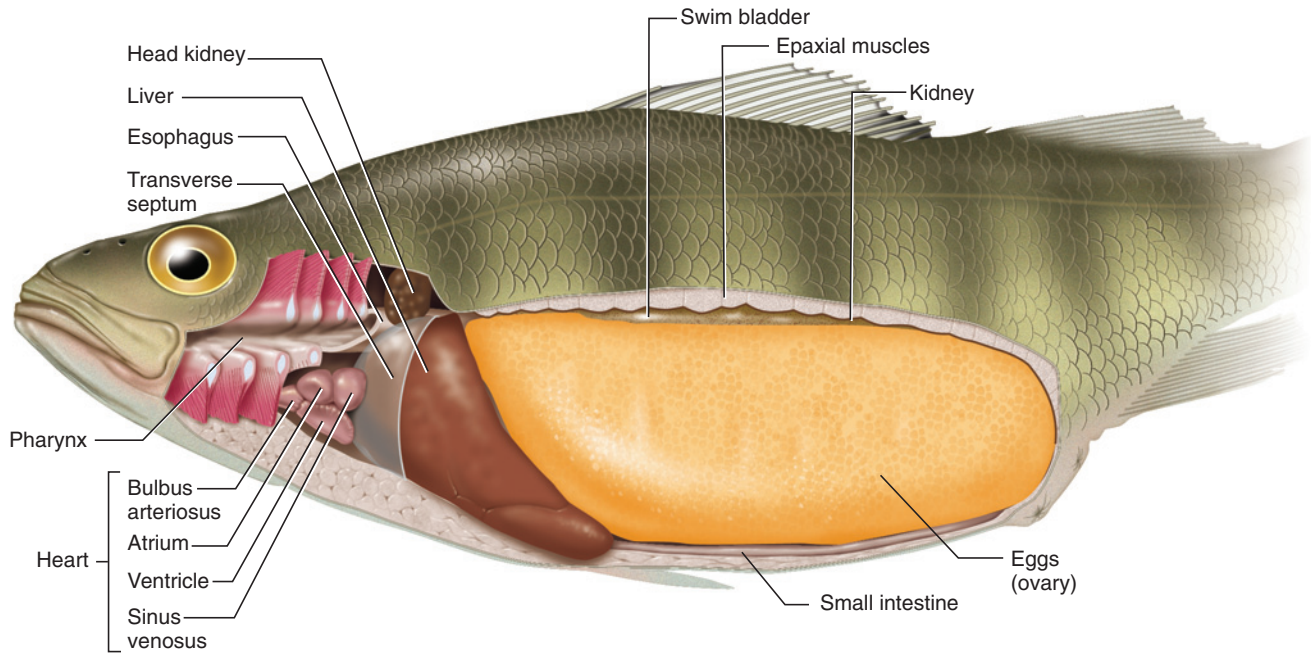
the pelvic girdle. Turn your incision dorsally to pass posterior to the attachment of the pectoral fin on the body. Cut dorsally past the pectoral fin approximately to the level posterior to the eye.

Return to the posterior end of the midventral incision. Cut dorsally for about 1 cm, then reflect the flap of body wall and examine the dorsal part of the cavity. You should see a dark, membranous sac, the **swim bladder**. Probe it gently. Resume cutting through the body wall until you reach the level just ventral to the swim bladder (this point will be ventral to the position of the dorsalmost point of the anterior vertical incision). Then cut anteriorly, more or less parallel to the swim bladder, to join the anterior vertical incision. Your incision should veer slightly dorsally as you cut. In addition to the musculature of the body wall, you will also cut through the ventral ribs. Once finished, remove the section of body wall and examine the underlying structures. The viscera are covered by **visceral peritoneum**, whereas the cavity itself is lined by **parietal peritoneum**.

Many female specimens will possess a very large **ovary** that seems to fill most of the pleuroperitoneal cavity (Figure 4.6). In such specimens you will probably only be able to see the darkly colored **liver** at the very anterior end of the cavity. Find the narrow **small intestine** ventral to the ovary. It is normally midventral, but may be displaced to one side by a massive ovary. Note the swim bladder dorsal to the ovary. In specimens with smaller gonads, several other visceral structures may be observed without further dissection. The small intestine is easily identifiable on the floor of the cavity. Posterior to the liver, you should observe the short, thick **stomach**, and perhaps the **spleen** and **gall bladder** if you have opened the right side of the cavity.

Once you have identified these structures, remove more of the body wall, preferably in small pieces, as follows. Remove the wall anterior to the liver, keeping close to the deep surface of the wall and continuously checking that you are not destroying underlying structures. Immediately anterior to the liver is the **transverse septum**, a thin membrane that separates the pleuroperitoneal cavity and the pericardial cavity. Cut through the transverse septum along its attachment to the body wall to expose the **heart** within the pericardial cavity.

At this stage, continue the midventral incision anteriorly to the posterior margin of the mouth, as shown in Figures 4.8 and 4.9. The musculature is thicker here, so cut carefully to avoid damaging the heart. You may wish to use a scalpel. Also cut away the lateral portions of the branchial arches to expose the pharynx. Then remove more of the lateral body wall dorsal to the liver. This will expose a small, dark, lobulated mass, the **head**



**FIGURE 4.6** Left lateral view of the perch with body wall cut away to reveal pharynx and pleuroperitoneal cavity.

**kidney**, lying immediately dorsal to the liver. Once you have exposed the head kidney, use a scalpel to cut a parasagittal section through the musculature dorsal to the swim bladder. This will allow you to expose the **kidneys**, which lie against the dorsal wall of the cavity, dorsal to the swim bladder. Be careful in using the scalpel. It is worth removing a row or two of scales along the path you intend to cut. If this method proves too awkward, find the kidneys by removing the swim bladder, but do so after you have examined the remaining structures described below.

The preparation described above is time-consuming, but it reveals the pattern, context, and arrangement of the various systems and their structures in a single view. Although you can begin with any of the structures, it is best to examine the gonads first, because in many specimens they will be so large that they will have to be removed.

The ovary of the female will vary considerably in size with the reproductive cycle of the fish, and may be massive, filled with eggs (Figure 4.6). The ovary of the perch is secondarily fused into a single structure (although this is not true of most teleosts, which retain paired ovaries) that is enveloped during embryonic development by bilateral peritoneal folds. This envelopment continues posteriorly and meets a funnel-like internal elongation of the urogenital aperture, lying just posterior to the anus. This combination (i.e., of the peritoneum and internal elongation of the aperture) forms

an **ovarian duct** for passage of the eggs, although it is not comparable to that (usually considered a Mullerian duct) of other vertebrates. Gently tugging the posterior end of the ovary will pull taut the funnel-shaped posterior end of the ovarian duct and make it easier to distinguish. In other teleosts the ovarian duct is formed differently. For example, a common pattern is that the ovary contains an internal cavity, formed by envelopment of a small part of the celomic cavity during embryonic development. The eggs are shed into this cavity, the lining of which extends posteriorly to form an ovarian duct. In most teleosts, therefore, the eggs are released directly into a tube, the ovarian duct, rather than into the pleuroperitoneal cavity, as occurs in almost all other vertebrates.

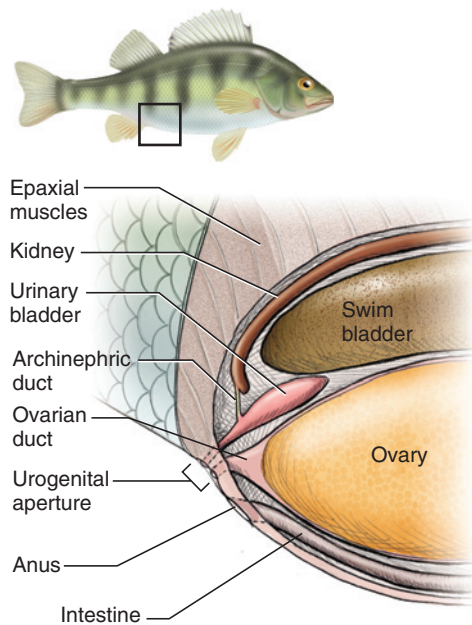
Cut transversely through the ovary, approximately 3 cm from its posterior margin, and carefully remove the anterior portion. This will leave a cone-shaped posterior end in place. Gently reflect it ventrally and delicately dissect between the ovary and swim bladder, now clearly visible, to expose the small, light-colored, elongated, and oval **urinary bladder** (Figure 4.7). The bladder continues posteroventrally into the urinary opening of the urogenital pore, but postpone tracing it.

The paired **testes** of the male perch are lobulated, light-colored, and posteriorly tapered structures (Figure 4.8). Each testis has its own duct, the **testicular duct**, that carries only sperm. The testicular duct is a specializa-



tion of teleosts (although not all teleosts, such as salmonids, possess a duct for the testis; instead, sperm are released by the testes into the body cavity and leave the body through pores) and is not comparable to the archinephric duct observed in sharks. It is fairly small and thus difficult to find without a dissecting micro-

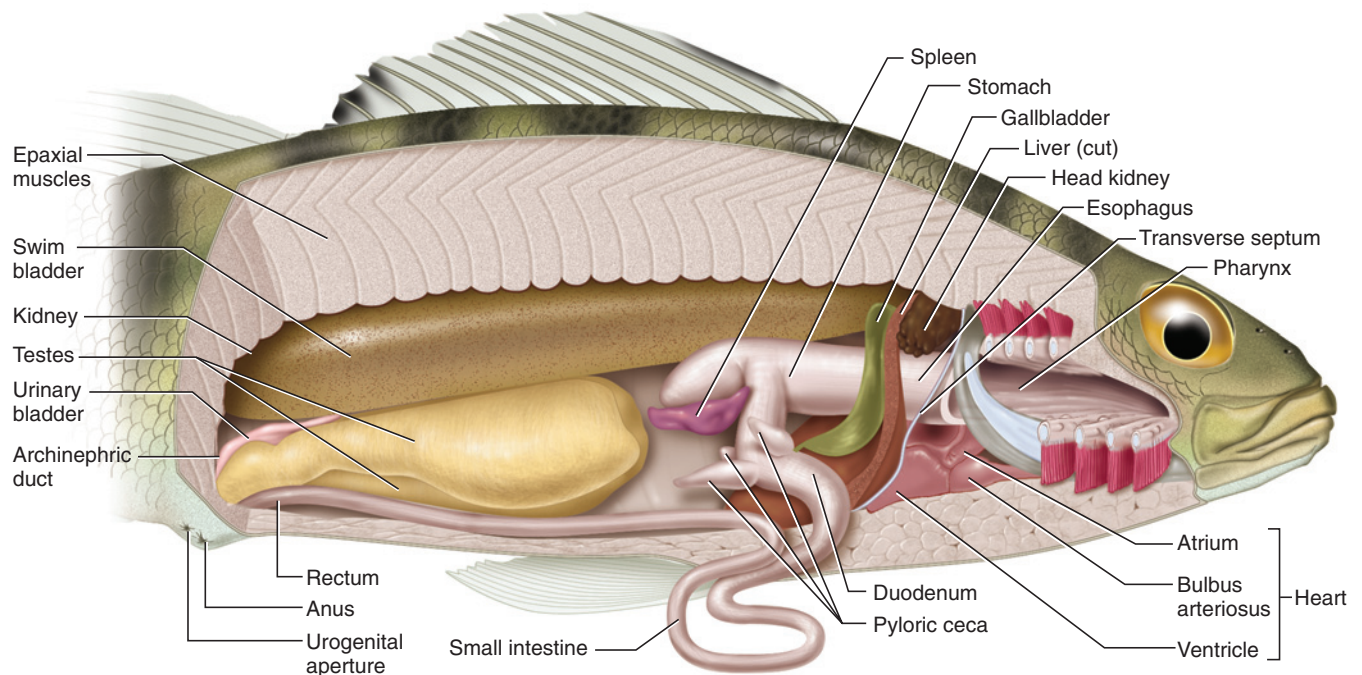
scope. Right and left testicular ducts unite near the posterior end of the testes into a single duct that leads out of the body through the urogenital pore just posterior to the anus. The opening of the duct can be distinguished from that of the **archinephric duct** (see below) with a magnifying glass. The urinary bladder lies dorsal to the posterior end of the testes.



**FIGURE 4.7** Schematic illustration showing the urogenital structures of the female perch in right lateral view.

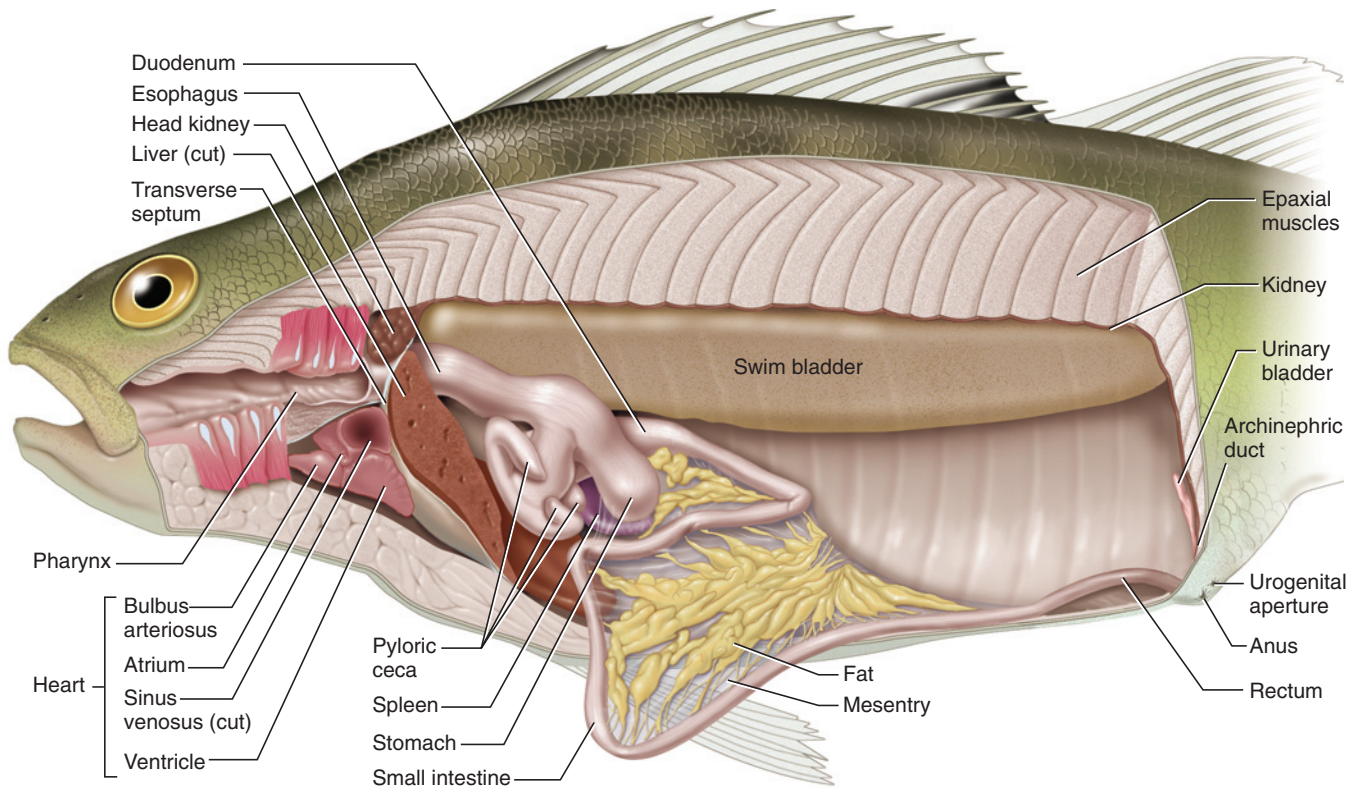
Turn your attention to the anterior end of the animal (Figures 4.8 and 4.9). Identify the oral cavity—look now for the various teeth described above—and follow it posteriorly into the pharynx. The pharynx leads into the wide, short, and straight **esophagus** that passes posteriorly into the stomach. The stomach is “T”-shaped, with a broad horizontal portion and a short, vertical, pyloric portion forming the stem of the “T”. The coiled intestine follows the pyloric portion. Note the three finger-like projections, the **pyloric ceca**, at the anterior end of the intestine. These are typically present in teleosts, though their number varies. The anterior part of the intestine, the **duodenum**, is somewhat wider than the remaining distal portion. Although its terminal portion may be referred to as a **rectum**, it is not sharply demarcated from the rest of the intestine.

Note various structures associated with the digestive tract. The large, massive liver has already been noted. It may be necessary to remove part of it, as shown in Figures 4.8 and 4.9, in order for the stomach and other organs to be seen properly. The gall bladder is a small, elongated sac. The bile duct leads to the duodenum, but



**FIGURE 4.8** Cutaway view of the male perch in right lateral view, to reveal structures of the pharynx and pleuroperitoneal cavity.





**FIGURE 4.9** Cutaway view of the female perch in left lateral view, to reveal structures of the pharynx and pleuroperitoneal cavity. Ovary has been removed.

it is difficult to find. The **pancreas** cannot be seen grossly. Bits of pancreatic tissue are scattered throughout the mesentry, often embedded in the fatty tissue there (Figure 4.9). The spleen, not properly an organ of the digestive system but concerned with production of blood cells, is an elongated, dark-colored structure near the posterior end of the stomach.

The swim bladder is the large, hollow sac lying, as noted above, dorsally in the body cavity. It is not enclosed by the peritoneum, and so is retroperitoneal in position. It is a hydrostatic organ used to control buoyancy. Its inflation decreases the fish's density, thus increasing buoyancy. Its deflation has the opposite effect. The bladder develops as an outgrowth of the anterior part of the digestive tract, and in many teleosts it retains an open duct connection to the esophagus, a condition termed *physostomus*. In the perch, however, the connection between the bladder and gut is lost, the *physoclistous* condition.

The kidneys lie dorsal to the swim bladder and are thus also retroperitoneal. They are long, narrow, ribbon-like structures with somewhat scalloped lateral margins lying on either side of the dorsal midline of the body cavity. Posteriorly, the kidneys curve ventrally, following the surface of the body cavity (Figure 4.7). Each

kidney is drained by an archinephric duct (in the males of some species it may also receive sperm, but the more common condition is that represented by the perch, in which a separate testicular duct serves for sperm passage). The right and left ducts enter the urinary bladder. Urine exits the body through a single duct leading to the urinary opening of the urogenital aperture. Dissection of this region to reveal the ducts is difficult without a microscope and considerable patience. Figure 4.7 indicates the structures and their relationships.

Finally, examine the heart, which has already been exposed and noted. As in the shark, the heart is an S-shaped, four-chambered structure that receives venous blood posteriorly and pumps it anteriorly into the gills (Figures 4.8 and 4.9). The most posterior chamber is the **sinus venosus**, which directs blood into the **atrium** lying immediately anterior to it. From the atrium, blood enters the **ventricle**, which lies ventrally. The ventricle pumps blood through the fourth chamber, the **bulbus arteriosus**, which leads into the ventral aorta. Afferent branchial arteries branch off the ventral aorta, leading blood through the gills. Efferent branchial arteries recollect the blood into the dorsal aorta, which distributes it to the various parts of the body. Unless you have an injected specimen, the vessels will be difficult to follow.

## KEY TERMS: PLEUROPERITONEAL CAVITY AND VISCERA

archinephric duct  
(Wolffian duct)

atrium

bulbus arteriosus

duodenum

esophagus

gall bladder

head kidney

heart

kidneys

liver

ovarian duct

ovary

pancreas

parietal peritoneum

pyloric cecum (plur.,  
ceca)

rectum

sinus venosus

small intestine

spleen

stomach

swim bladder

testes

testicular duct

transverse septum

urinary bladder

ventricle

visceral peritoneum

This page intentionally left blank

# CHAPTER 5

## THE MUDPUPPY

### INTRODUCTION

The common mudpuppy, *Necturus maculosus*, is a member of the Caudata, which together with Anura (frogs and toads) and Gymnophiona (caecilians or apodans) form the Lissamphibia. The Caudata, including the salamanders and newts, are the least specialized amphibians in body form and locomotion. The body is elongated and stout, with well-developed axial musculature and tail. Salamanders use their limbs in combination with the side-to-side body undulations characteristic of fish, and thus probably resemble the earliest land vertebrates in locomotion. In contrast, frogs (see Chapter 6) are characterized by a shortened body and specialized saltatory locomotion, while gymnophionans are limbless burrowers.

There are several clades of salamanders, of which the Plethodontidae includes by far the most species. Salamanders range from being fully aquatic to fully terrestrial. Members of several families do not metamorphose. *Necturus* is commonly included with *Proteus* in the Proteidae, a small group of fully aquatic, neotenic (i.e., retaining juvenile features) salamanders that retain their larval, filamentous external gills, two pairs of pharyngeal slits, and caudal fins as adults. *Necturus* includes six species. *N. maculosus* is apparently closely related to *N. lewisi*, the Red River mudpuppy. The remaining species of *Necturus* are commonly referred to as *waterdogs*.

### SECTION I—SKELETON

#### Cranial Skeleton

##### Skull

Examine the skeleton of the head on a mounted specimen (Figure 5.1) to identify the **skull**, **mandible**, and **hyoid apparatus**, but examine these cranial skeletal components on isolated specimens as well. The skull (Figure 5.2) is formed from a dermal skull roof, chondrocranium (Figure 5.3), and palatal complex, itself formed from dermal bones and a remnant of the splanchnocranium (see below). Other parts of the

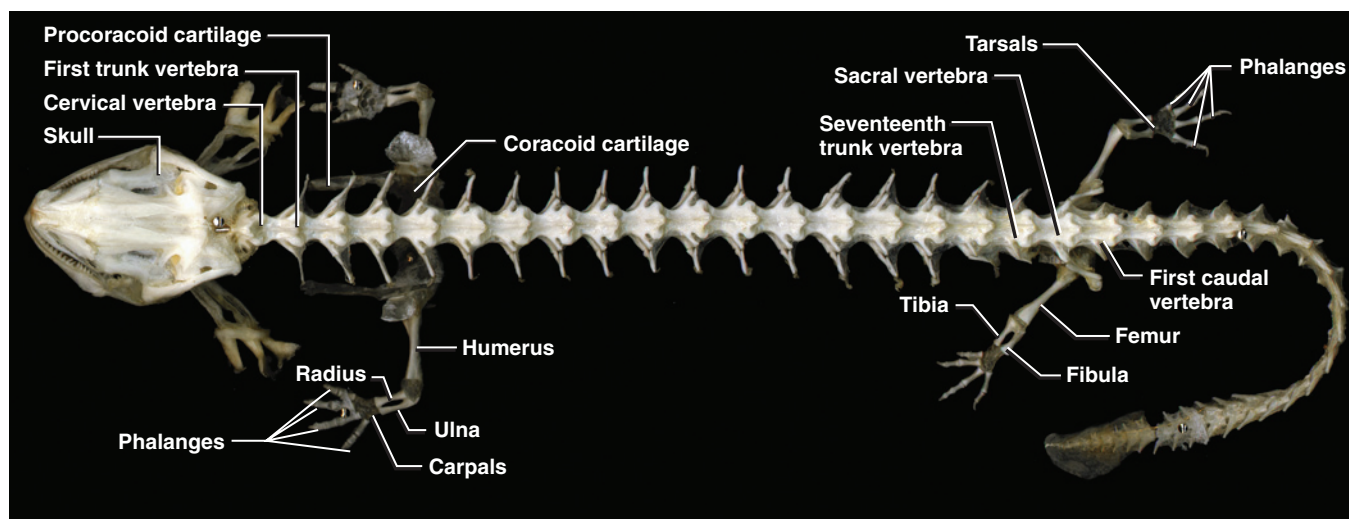
splanchnocranium form the mandible (Figure 5.3) and hyoid apparatus (see below; Figure 5.4).

The dermal skull roof covers the brain and major sense organs dorsally. The ventral surface, or underside, of the skull is formed mainly by the palatal complex. Between the dermal roof and palatal complex is the chondrocranium, which remains mainly cartilaginous and has only small exposures on the outside of the skull. In the shark (page 28), the chondrocranium forms a nearly complete enclosing and supportive structure for the brain and major sense organs. The chondrocranium is highly developed in the shark and other chondrichthyeans, but this is necessary because of the near-absence of bone in these vertebrates. In most other vertebrates, bone covers the brain dorsally and forms the floor of the skull, so the chondrocranium is a relatively minor structure. This is particularly true in *Necturus*, in which the chondrocranium (Figure 5.3) retains larval characteristics, as do many other parts of the body, and is even less developed than in most vertebrates.

Examine an isolated skull. In dorsal view (Figure 5.2a) the paired **premaxillae** are seen anteriorly, followed by the paired **frontals** and **parietals**. Note the long slender anterior extension of the parietal that runs along the lateral margin of the frontal. The cartilaginous **antorbital processes**, which are part of the chondrocranium (Figure 5.3), project laterally near the anterior end of the parietal bones, but these delicate elements are often missing in prepared specimens. The **vomer** forms the anterolateral margin of the skull and, posterior to the antorbital process, the **pterygoid** forms the central portion of the lateral margin.

The otic capsules lie at the posterolateral corners of the skull (Figures 5.2a–c). The paired bones that contribute to each capsule are the **prootics** and the **opisthotics**. The prootic lies lateral to the parietal near the suture of the parietals and frontals, and the opisthotic lies posterior to the parietal. A cartilaginous region, containing the oval window, lies between the prootic and opisthotic. The **squamosal** extends anterolaterally from the opisthotic, forming the posterolateral margin of the skull. The **quadrate** articulates with the anterior end of





**FIGURE 5.1** Skeleton of the mudpuppy in dorsal view.

the squamosal and inclines anteroventrally (Figure 5.2b). It contacts the pterygoid anteriorly and forms the jaw joint through an articulation with the mandible. The **quadrate cartilage** forms a slender bridge extending from the anterior end of the quadrate toward the lateral margin of the parietal.

Examine the skull in lateral view (Figure 5.2c) and re-identify the elements described above. Just anterior to the opisthotic, and thus essentially covering the cartilaginous region between the prootic and opisthotic, is the disc-shaped **columella**. The columella covers the oval window, mentioned above. A small **stylus** projects from its lateral surface. The columella, with its stylus, is a small delicate bone that transmits vibrations to the inner ear. It may be missing in your specimen, in which case the oval window should be clearly visible. The **foramen magnum** (Figures 5.2a, b) is the large opening on the posterior surface of the skull through which the spinal cord passes. The **exoccipitals**, each bearing an **occipital condyle**, form the skull lateral and ventral to the foramen magnum.

Examine the skull in ventral view (Figure 5.2b) and identify the premaxillae, vomers, and pterygoids. Note that the premaxillae and pterygoids each bear a short row of relatively large anterior teeth, whereas the vomers bear a longer row of teeth. Close inspection reveals a row of smaller teeth lying along the lingual margins of the larger teeth. The large, triangular, and plate-like **parasphenoid** forms nearly all of the rest of the skull's ventral surface. A portion of the cartilaginous **ethmoid plate** is visible anterior to the parasphenoid.

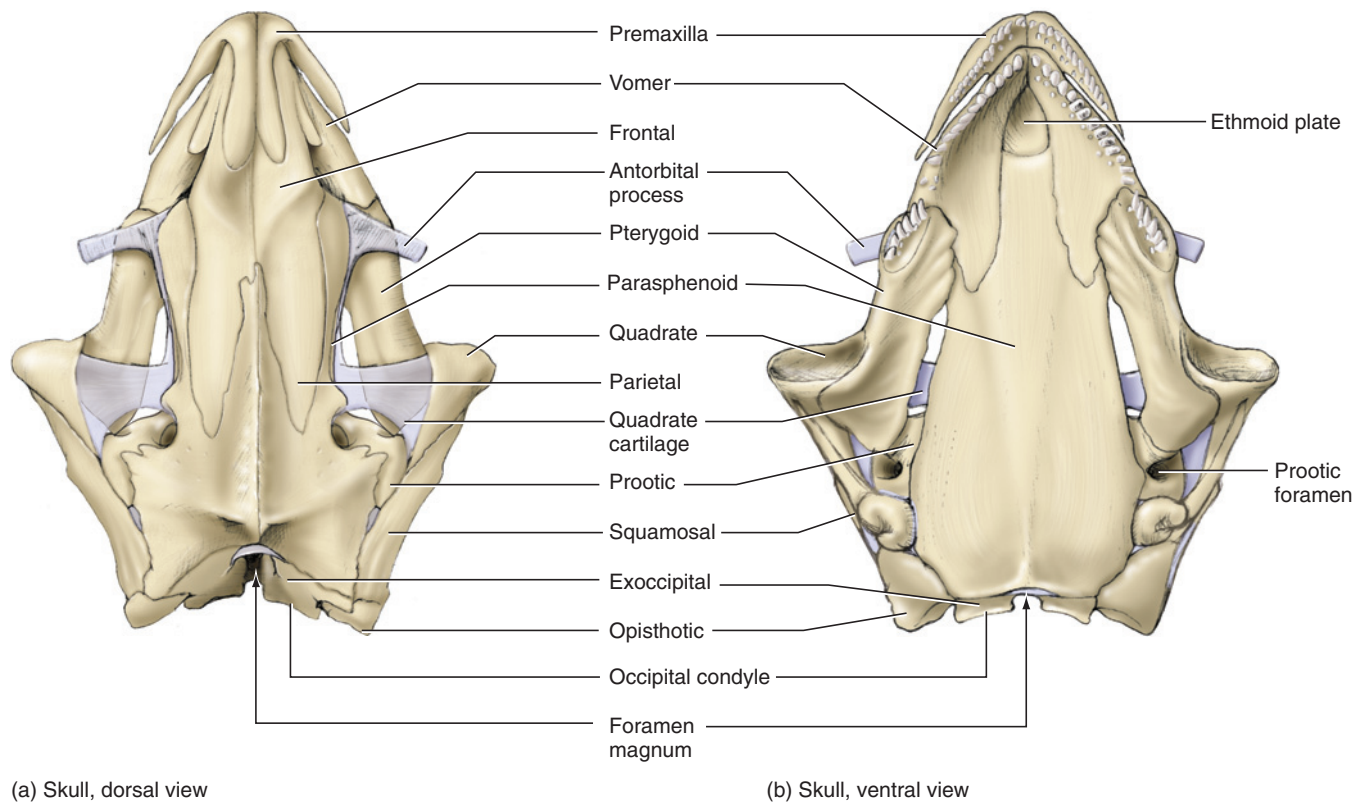
The chondrocranium should be studied in a separate preparation (Figure 5.3), usually set in an acrylic block, even though many of its elements have already been

observed. The posterior half of the chondrocranium consists of the otic capsules, with its cartilaginous portion set between the bony prootic and opisthotic, and the exoccipitals. Left and right otic capsules are connected dorsally by a delicate cartilaginous bridge, the **synotic tectum**. The **basal plate** forms a similar bridge between left and right exoccipitals. A **parachordal plate** extends anteriorly from each otic capsule. **Trabeculae** are the slender rod-like elements extending anteriorly from the parachordals. The antorbital cartilages (noted above) project laterally from each trabecula. Beyond the antorbital cartilages the trabeculae converge to form the ethmoid plate (noted above) and then send a pair of **trabecular horns** anteriorly between the nasal capsules, which are extremely delicate and usually not preserved.

Just anterior and laterally to each otic capsule, many preparations include the bony and cartilaginous components of the quadrate. These have already been observed, but remember that they are part of the palatal complex rather than the chondrocranium. They are in part homologous to the palatoquadrate cartilage, and thus belong to the mandibular arch, which is part of the splanchnocranium.

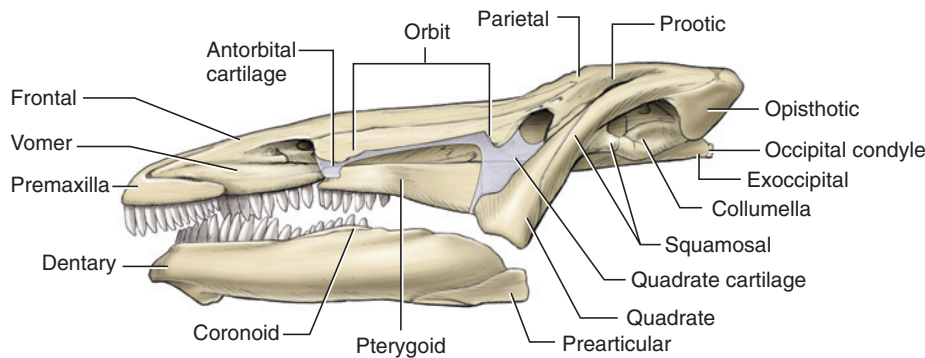
### *Mandible*

In lateral view, most of the mandible is formed by the large **dentary** bone, which bears a long row of marginal teeth (Figures 5.2c, d). Posterior to these teeth is a short tooth row borne by the **splenic** bone. The latter is barely visible in lateral view, but has a wider exposure in medial view. The dentary is also exposed in medial view, forming a small part of the anterior end of the mandible. Medially, however, the mandible is composed primarily by the **angular** bone. The articulation with the upper jaw is formed by **Meckel's cartilage**.

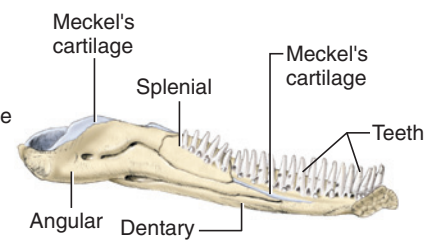


(a) Skull, dorsal view

(b) Skull, ventral view



(c) Skull, left lateral view



(d) Mandible, left medial view

**FIGURE 5.2** Skull and mandible of the mudpuppy: (a) skull in dorsal view; (b) skull in ventral view; (c) skull and mandible in left lateral view; (d) left mandible in medial view.

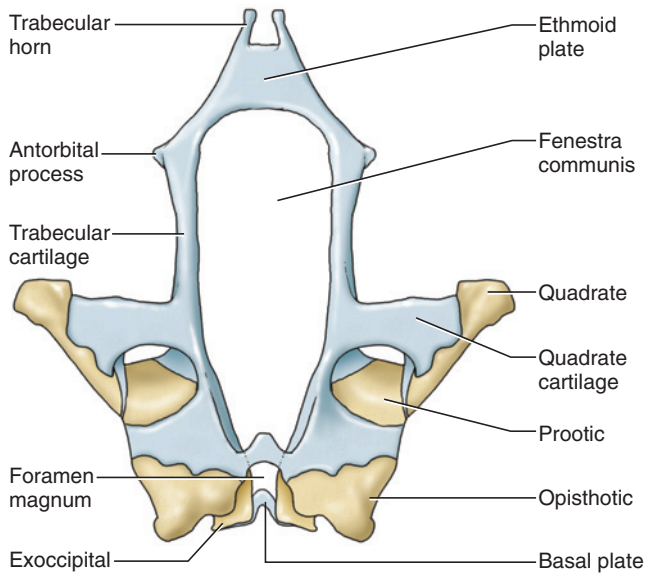
### Hyoid Apparatus

The hyoid apparatus (Figure 5.4) is large and composed of the hyoid arch and parts of the first three branchial arches. The hyoid arch is the largest and most anterior, and supports the tongue. It is composed on each side by the small **hypohyal** and, more laterally, the larger **ceratohyal**. The median **basibranchial 1** extends posteriorly from the hypohyals to the base of the first branchial arch, which is also composed on each side by two large elements, **ceratobranchial 1** and **epibranchial 1**. The more slender **basibranchial 2** extends posteriorly from the left and right ceratobranchial 1. **Ceratobranchial 2** is a tiny, nodular element at the base of **epibranchial 2**. **Epi-**

**branchial 3** lies posterior to **epibranchial 2**. The remaining branchial arches are apparently represented by tiny cartilaginous elements, but these are rarely preserved in prepared specimens.

### KEY TERMS: CRANIAL SKELETON

angular	ceratohyal
antorbital processes	columella
basal plate	dentary
basibranchials	epibranchials
ceratobranchials	ethmoid plate



**FIGURE 5.3** Chondrocranium of the mudpuppy in dorsal view.

exoccipitals	premaxillae
foramen magnum	prootics
frontals	pterygoid
hyoid apparatus	quadrate
hypohyal	quadrate cartilage
mandible	skull
Meckel's cartilage (mandibular cartilage)	splenial
occipital condyle	squamosal
opisthotics	stylus
parachordal plate	synotic tectum
parasphenoid	trabeculae
parietals	trabecular horns
	vomer

## Postcranial Skeleton

### Axial Skeleton

The axial skeleton consists of four types of vertebrae (Figure 5.1). Most anteriorly is the single **cervical vertebra** that articulates with the occipital condyles of the skull and with the first of the long series of **trunk vertebrae** (Figures 5.1 and 5.5). The latter bear **transverse processes**, which extend from the **centrum** and articulate with small, Y-shaped, posterolaterally directed **ribs**. The **neural canal** passes dorsal to the centrum. The **neural arch** forms the roof of the canal and bears a **neural process**. **Prezygapophyses** and **postzygapophyses** are present for articulation with the preceding vertebra and succeeding vertebra, respectively. A single **sacral vertebra** (Figures 5.1 and 5.8) articulates with the pelvic

girdle by way of its ribs. The **caudal vertebrae** (Figure 5.6), each bearing a **hemal arch**, follow the sacral vertebra. Most lack ribs, but bear transverse processes.

### Appendicular Skeleton

The **pectoral girdle** (Figure 5.7) is composed of left and right halves that overlap ventrally but do not fuse. The ossified **scapula** is a short bone that dorsally bears the **suprascapular cartilage**. The **glenoid fossa**, the depression that articulates with the forelimb, is ventral to the scapula. The slender, elongated **procoracoid cartilage** projects anteriorly in front of the glenoid fossa. The **coracoid cartilage** forms the broad, ventral, plate-like part of the girdle.

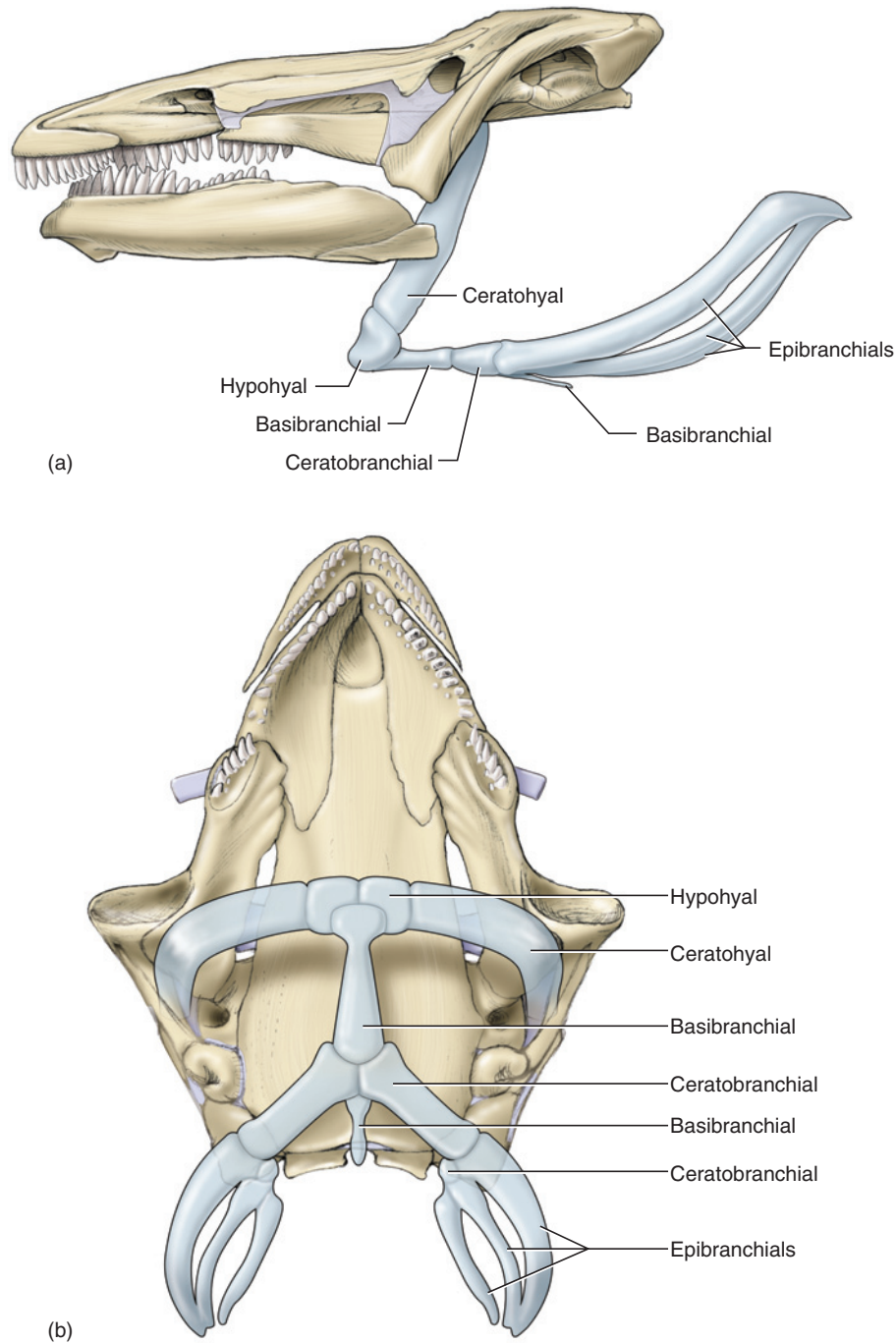
As is typical of tetrapods, the forelimb consists of the brachium, antebrachium, and manus in proximal to distal order. The brachium is supported by the **humerus**. In the antebrachium the **radius** is the anteromedial bone, and the **ulna** is the posterolateral bone. The manus includes six cartilaginous **carpals**, followed distally by four digits. The most proximal segment of each digit is a **metacarpal**, and the more distal elements are **phalanges**.

The **pelvic girdle** (Figure 5.8), like the pectoral, is mainly cartilaginous. The **ilium** is ossified and extends ventrally from its articulation with the rib of the sacral vertebra toward the **acetabulum**, the depression that articulates with the hindlimb. The girdle is formed ventrally by the expansive **puboischialic plate**. Examine the plate in ventral view. The elongated, triangular **pubic cartilage** is the anterior portion. The posterior portion is the **ischial cartilage**, which contains a pair of ossifications termed **ischia**. Note the **obturator foramen** just anterior to each acetabulum.

The hindlimb is also formed of three segments, the thigh, crus, and pes. The **femur** is the single bone of the thigh. The **tibia** and **fibula** lie anteriorly and posteriorly, respectively, in the crus. The pes is formed proximally by six cartilaginous **tarsals** and distally by four ossified digits. The proximal bone of each digit is a **metatarsal**, while the distal elements are **phalanges**.

### KEY TERMS: POSTCRANIAL SKELETON


acetabulum	glenoid fossa
carpals	hemal arch
caudal vertebrae	humerus
centrum (vertebral body)	ilium
cervical vertebra	ischium (pl., ischia)
coracoid cartilage	ischial cartilage
femur	metacarpal
fibula	metatarsal




**FIGURE 5.4** Skull, mandible, and hyoid apparatus of the mudpuppy in (a) left lateral and (b) ventral views.

neural arch (vertebral arch)	pectoral girdle	pubic cartilage	suprascapular cartilage
neural canal (vertebral canal)	pelvic girdle	puboischiadic plate	tarsals
neural process (spinous process)	phalanges	radius	tibia
obturator foramen	postzygapophyses	ribs	transverse processes
	prezygapophyses	sacral vertebra	trunk vertebrae
	procoracoid cartilage	scapula	ulna

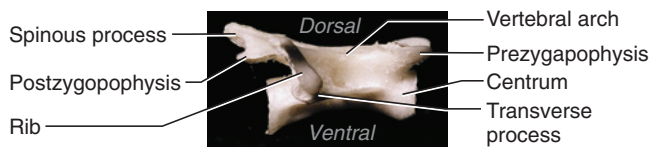




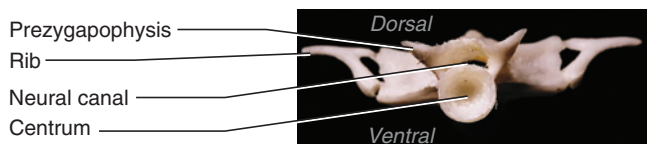
(a) Trunk vertebra dorsal view




(b) Trunk vertebra ventral view



(c) Trunk vertebra right lateral view



(d) Trunk vertebra anterior view

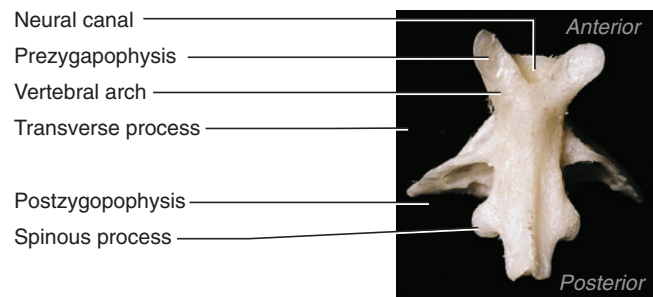


(e) Trunk vertebra posterior view

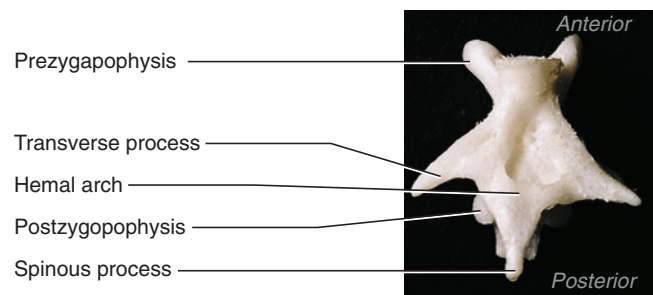
**FIGURE 5.5** Trunk vertebra of the mudpuppy in (a) dorsal, (b) ventral, (c) right lateral, (d) anterior, and (e) posterior views.

## SECTION II—EXTERNAL ANATOMY

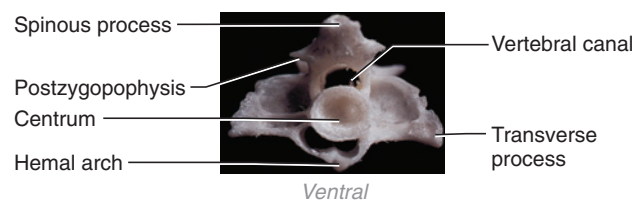
Perhaps the mudpuppy's (Figure 5.9) most striking larval feature is the presence of three pairs of **external gills**, located just posterior to the flattened **head**. Also retained are two pairs of **pharyngeal slits**, one between the first and second gills, the other between the second and third gills. The slits may be probed but will be observed later (Figure 5.10). Note the prominent transverse **gular fold**.



a) Caudal vertebra dorsal view



b) Caudal vertebra ventral view

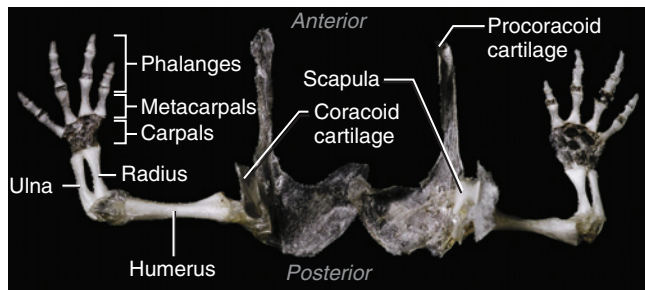


c) Caudal vertebra posterior view

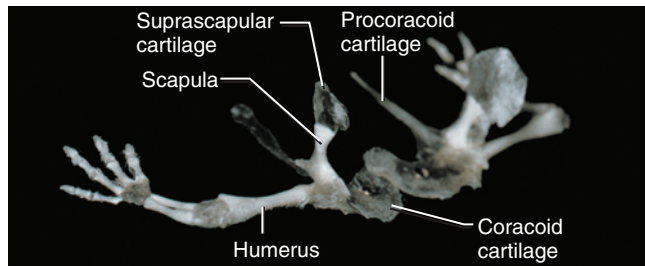
**FIGURE 5.6** Caudal vertebra of the mudpuppy in (a) dorsal, (b) ventral, and (c) posterior views.

The **mouth** is large and bounded by **lips**. The lidless **eyes** are small, as are the widely separated **nares**, which communicate with the oral cavity (see below). A short **neck** is present between the head and the long **trunk**. Posteriorly, the large, flattened **tail** bears a small, marginal **fin**, which, however, lacks the supporting rays present in fishes.

Paired **pectoral** and **pelvic limbs** are small, but bear the three segments typical of terrestrial tetrapods. The **cloaca**, marking the posterior end of the trunk, lies ventrally between the pelvic limbs. In males the cloacal aperture is surrounded by small projections or **papillae**. The region around the cloaca is swollen due to the presence of the **cloacal gland**. Lastly, note the smooth, scaleless skin, which has an important respiratory function. A lateral line system is present as well, but is not obvious.



(a) Pectoral girdle dorsal view



(b) Pectoral girdle left dorsolateral view

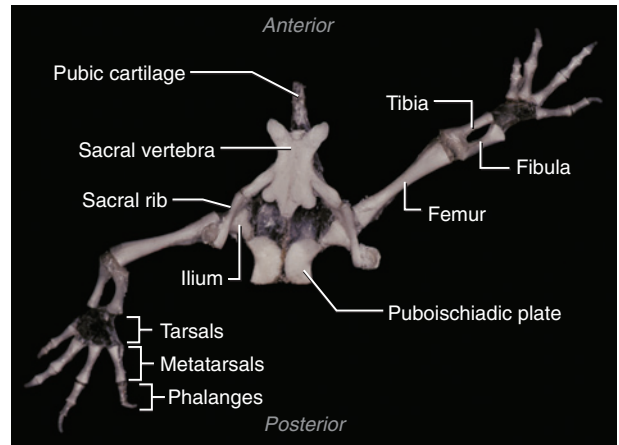
**FIGURE 5.7** Pectoral girdle and forelimbs of the mudpuppy in (a) dorsal and (b) dorsolateral views.

### KEY TERMS: EXTERNAL ANATOMY

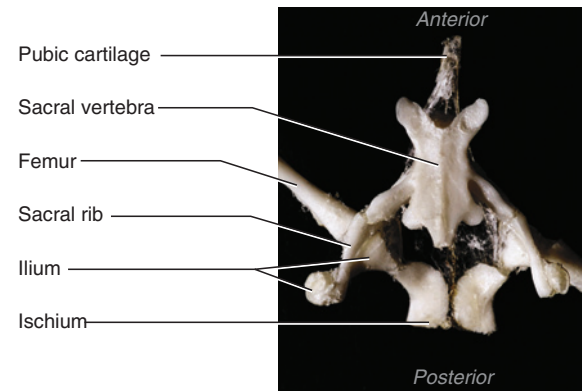
cloaca	nares
cloacal gland	neck
external gills	papillae
eyes	pectoral limbs
fin	pelvic limbs
gular fold	pharyngeal slits
head	tail
lips	trunk
mouth	

## SECTION III—MOUTH, ORAL CAVITY, AND PHARYNX

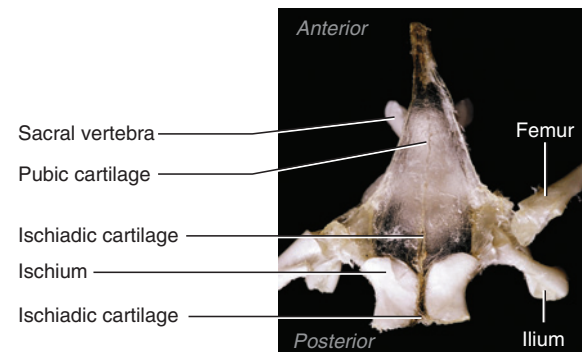
Open the **oral cavity** and **pharynx** by cutting from each corner of the mouth posteriorly through the gills. Swing open the lower jaw, as shown in Figure 5.10, to expose the oral cavity and pharynx. These regions are not distinctly demarcated. Note the teeth, arranged in V-shaped rows in the anterior part of the oral cavity. In the upper jaw, the most anterior row contains **premaxillary teeth**. Just behind these teeth are the **vomerine teeth** medially and the **pterygoid teeth** laterally. An **internal choana**, the internal opening of the nasal passage, may be seen on each side of the roof of



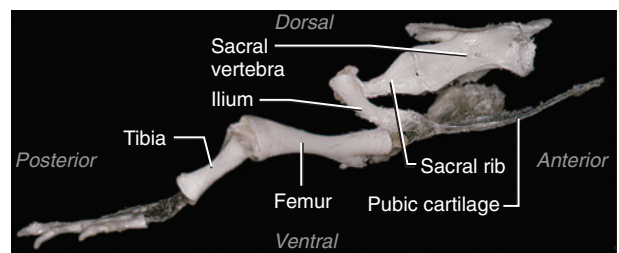
(a) Pelvic girdle dorsal view



(b) Pelvic girdle dorsal view (closeup)

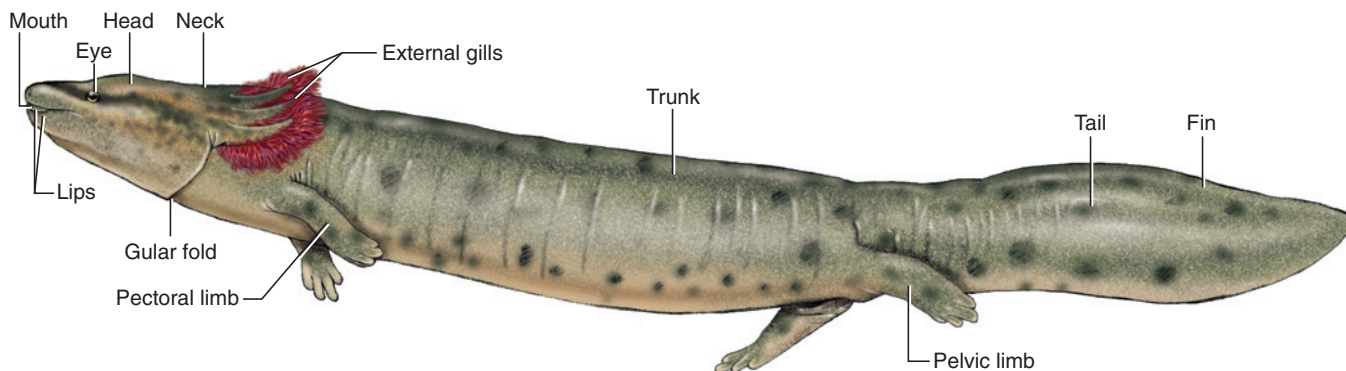


(c) Pelvic girdle ventral view (closeup)

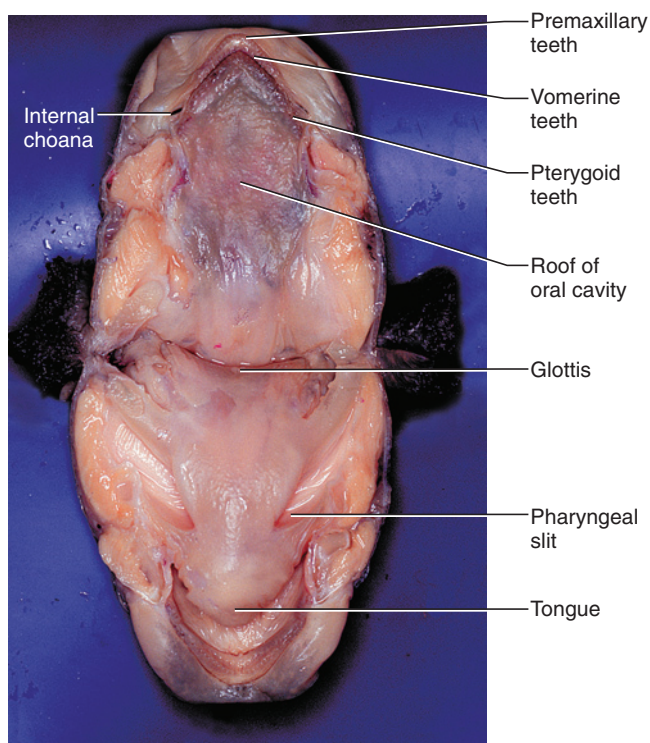


(d) Pelvic girdle right lateral view

**FIGURE 5.8** Pelvic girdle and hind limbs of the mudpuppy in (a) dorsal view, (b) closeup of pelvic girdle in dorsal view, (c) closeup of pelvic girdle in ventral view, and (d) right lateral view.



**FIGURE 5.9** External features of the mudpuppy in left lateral view.



**FIGURE 5.10** Oral cavity and pharynx of the mudpuppy.

the oral cavity, just lateral to the pterygoid teeth. In the lower jaw there is a single row of teeth. Most of them are **dentary teeth**; a few **splenic teeth** lie near the posterior end of the row. The **tongue**, supported by the **hyoid arch**, lies behind these teeth. Identify the sectioned surfaces of the hyoid arch and **mandibular arch**. The entrances of the pharyngeal slits into the pharynx may be noted on each side. Probe to verify that there are two slits. Midventrally on the floor of the pharynx, between the entrances to the slits, is the **glottis**, a small, slit-like opening into the respiratory system.

### KEY TERMS: MOUTH, ORAL CAVITY, AND PHARYNX

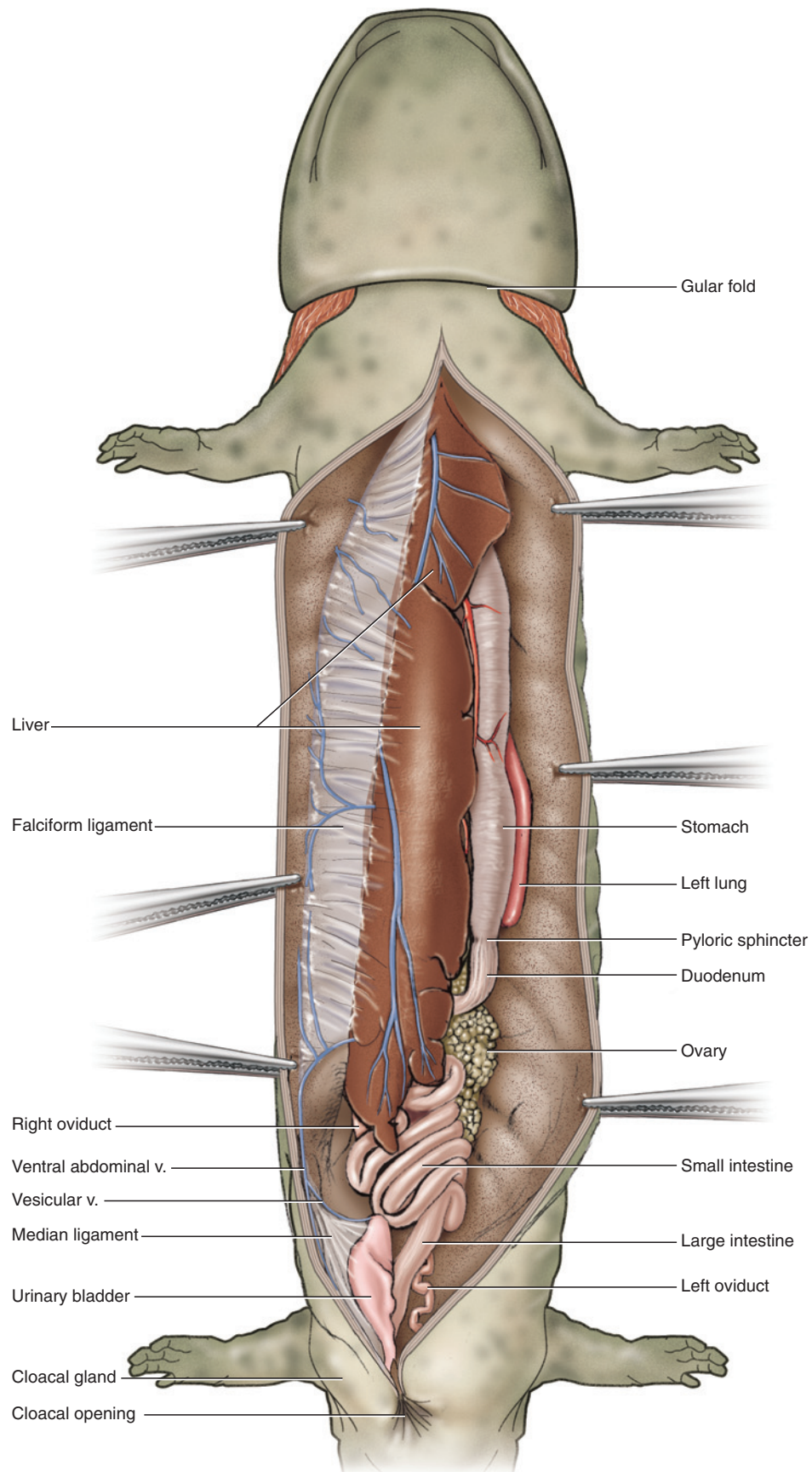
dentary teeth	pharynx
glottis	premaxillary teeth
hyoid arch	pterygoid teeth
internal choana	splenic teeth
mandibular arch	tongue
oral cavity	vomerine teeth

### SECTION IV—PLEUROPERITONEAL CAVITY AND VISCERA

Dissection of the pleuroperitoneal cavity in *Necturus* allows examination of both digestive and urogenital structures. Many vessels will also be noted at this time. Enter the pleuroperitoneal cavity by making a longitudinal incision about 0.5 cm to the left of the midventral line. If the vessels of your specimen have been injected, its abdominal wall will have been cut. If so, continue along this cut to expose the cavity. Cut anteriorly until you reach the level of the posterior margin of the forelimbs, at which point you will have reached the posterior margin of the coracoid cartilage. Cut posteriorly to the posterior margin of the hindlimbs, cutting through the puboischiadic plate.

Gently spread the abdominal wall (Figure 5.11). The large, elongated, dark structure midventrally is the **liver**. Lift the cut edge of the body wall to observe the **falciform ligament** extending between the wall and the ventral surface of the liver. The ligament is much larger than in the other vertebrates considered here. Note the **ventral abdominal vein** passing along the midventral abdominal wall and toward the liver through the free posterior margin of the ligament. Examine the posteroventral part of the cavity to observe the thin-walled





**FIGURE 5.11** Pleuroperitoneal cavity of the mudpuppy in ventral view.



**urinary bladder.** It is supported from the midventral abdominal wall by the **median ligament**. A **vesicular vein** from the bladder passes in the anterior free margin of this ligament to join the ventral abdominal vein.

Carefully cut through the falciform ligament, and make two transverse cuts through the body wall, one on either side, to create four flaps that can be spread apart. (Much of the ventral body wall has been removed in Figures 5.12–5.14, but you need not do so to observe the following structures.) The long, light-colored, tubular **stomach** (Figure 5.11) lies dorsal and slightly to the left of the liver. Lift the stomach to see that it is supported by the **greater omentum**. Spread apart the liver and stomach. The **gastrohepatic ligament** is the small, triangular sheet stretching between their anterior portions (Figure 5.12).

The elongated **spleen** hangs from the posterior left side of the stomach (Figures 5.11 and 5.12). The **gastrosplenic ligament** extends between these organs (Figure 5.12). The stomach ends abruptly at the **pyloric sphincter**, a marked constriction beyond which the digestive tract continues as the long, coiled **small intestine**, followed by the short, straight **large intestine**. The **mesentery** supports the small intestine. Spread the coils of the small intestine to observe it. The **mesorectum** supports the large intestine (Figure 5.12).

The first loop of the small intestine is the **duodenum** (Figures 5.11 and 5.12). The **hepatoduodenal ligament** extends between the duodenum and the dorsal surface of the liver (Figure 5.12). Several organs and vessels lie in this region, but may be difficult to discern. Examine this region in several views as follows, referring to Figures 5.12–5.14. The **pancreas** lies along the duodenum (and partly within the hepatoduodenal ligament). To help identify it, pull the stomach to the left and reflect the liver to the right to expose its dorsal surface (Figure 5.12). The pancreas is irregular, but note that part of it extends anteriorly toward the spleen. The **gastrosplenic vein** lies partly embedded within this lobe and extends toward the spleen.

Observe the long, thin transparent left **lung** lying dorsal to the stomach. The right lung is similar in form. Look between the stomach and the liver. You should discern the right and left lungs, apparently lying side by side. For now, distinguish between them but do not tear through any mesenteries. The liver is supported anterodorsally by the **hepatocavopulmonary ligament**. The **posterior vena cava** is the large vessel passing through the posterior end of this ligament (Figure 5.12). Note the large **hepatic portal vein** embedded in the dorsal part of the liver.

Next, reflect the stomach to the right, so that it lies on the liver's dorsal surface, as shown in Figure 5.13. Note the relationships among the liver, stomach, spleen, and pancreas, as well as their associated mesenteries. Lift the left lung. It is supported by a narrow **pulmonary ligament**, which is connected to the greater omentum.

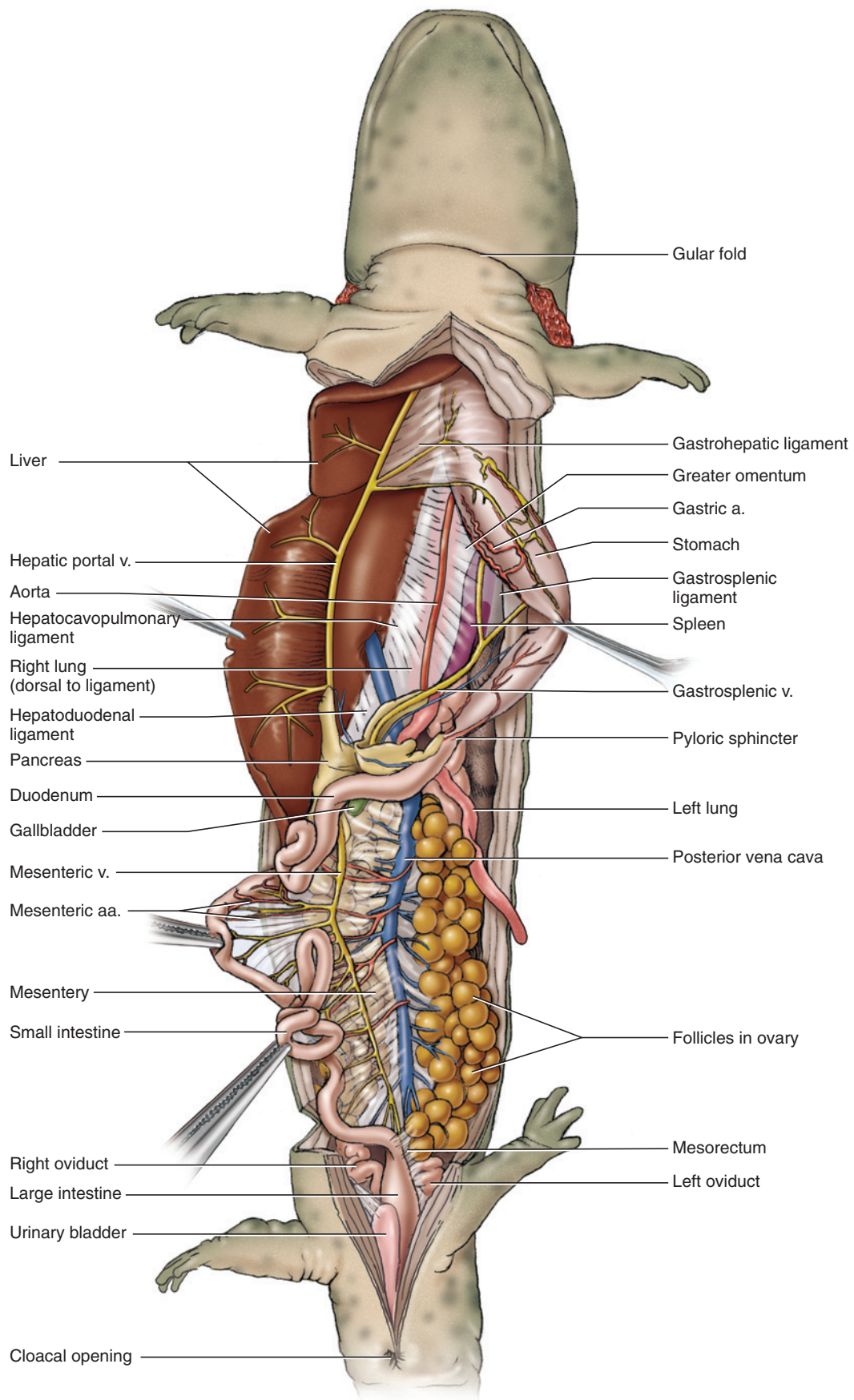
Next, let the viscera fall back in place, and then reflect the liver to the left, as shown in Figure 5.14. Examine the posterodorsal part of the liver for the **gall bladder**, a thin, translucent, greenish sac. Gently lift it and examine the region where it attaches to the liver. The **cystic duct** leaves the gall bladder but is joined by several (and usually fairly narrow) **hepatic ducts** from the liver to form the **common bile duct**, which passes partly through the substance of the pancreas to reach the duodenum. The bile duct is similar to that of the shark and cat, but is much shorter. Note again the positions of the posterior vena cava and gastrosplenic vein. Examine the right lung. Its pulmonary ligament, wider than that of the left lung, is part of the hepatocavopulmonary ligament.

#### KEY TERMS: PLEUROPERITONEAL CAVITY AND VISCERA

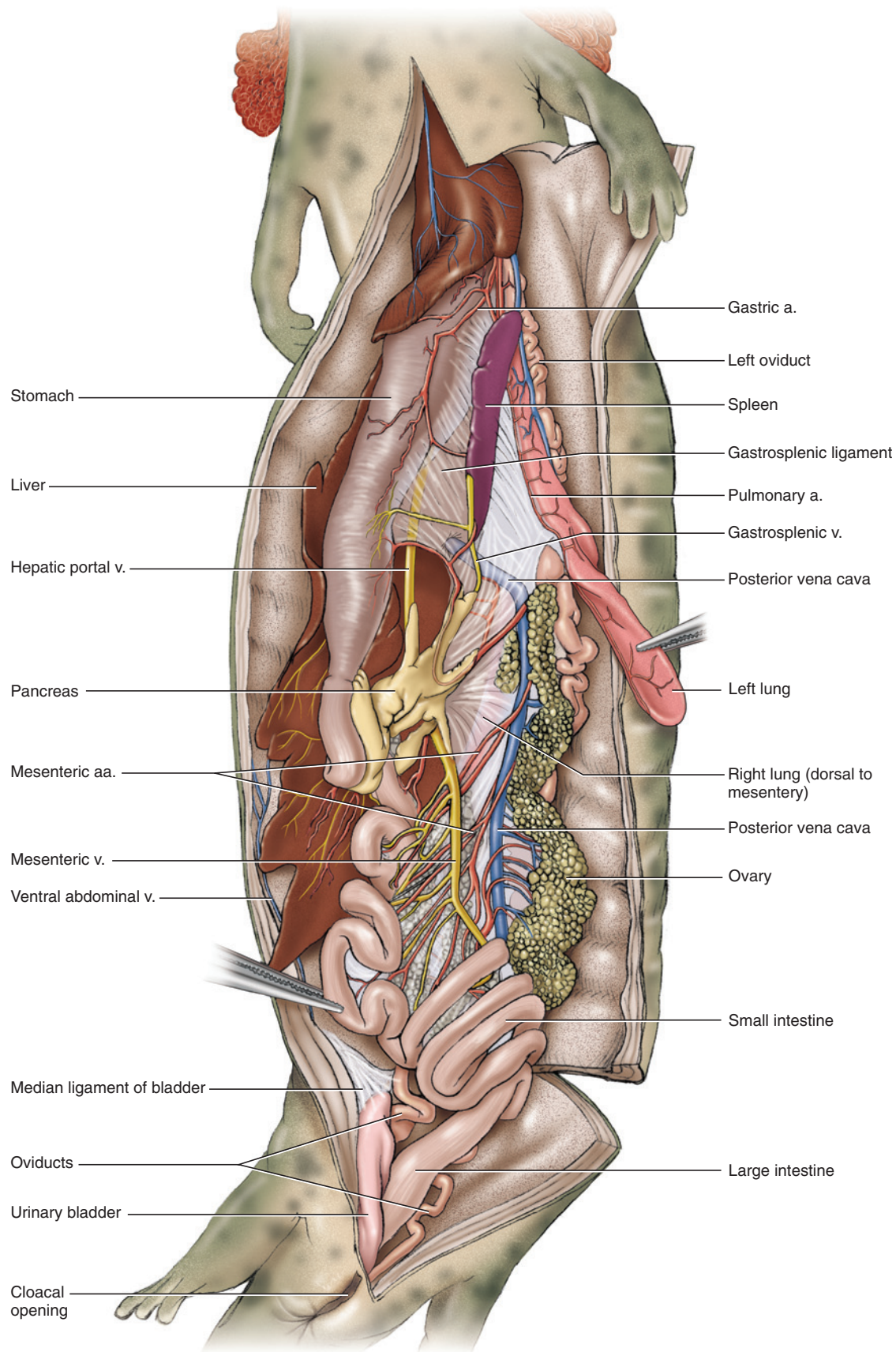
common bile duct	liver
cystic duct	lung
duodenum	median ligament
falciform ligament	mesentery
gall bladder	mesorectum
gastrosplenic vein	pancreas
gastrohepatic ligament	posterior vena cava
gastrosplenic ligament	pulmonary ligament
greater omentum	pyloric sphincter
hepatic ducts	small intestine
hepatic portal vein	spleen
hepatocavopulmonary ligament	stomach
hepatoduodenal ligament	urinary bladder
large intestine	ventral abdominal vein
	vesicular vein

## SECTION V—UROGENITAL SYSTEM

Urinary and reproductive structures should be examined next, but do not injure mesenteries and vessels in doing so. Postpone detailed tracing of the structures until the vessels have been studied. Lift the coils of the small intestine in the posterior part of the peritoneal cavity to locate one of the paired gonads.

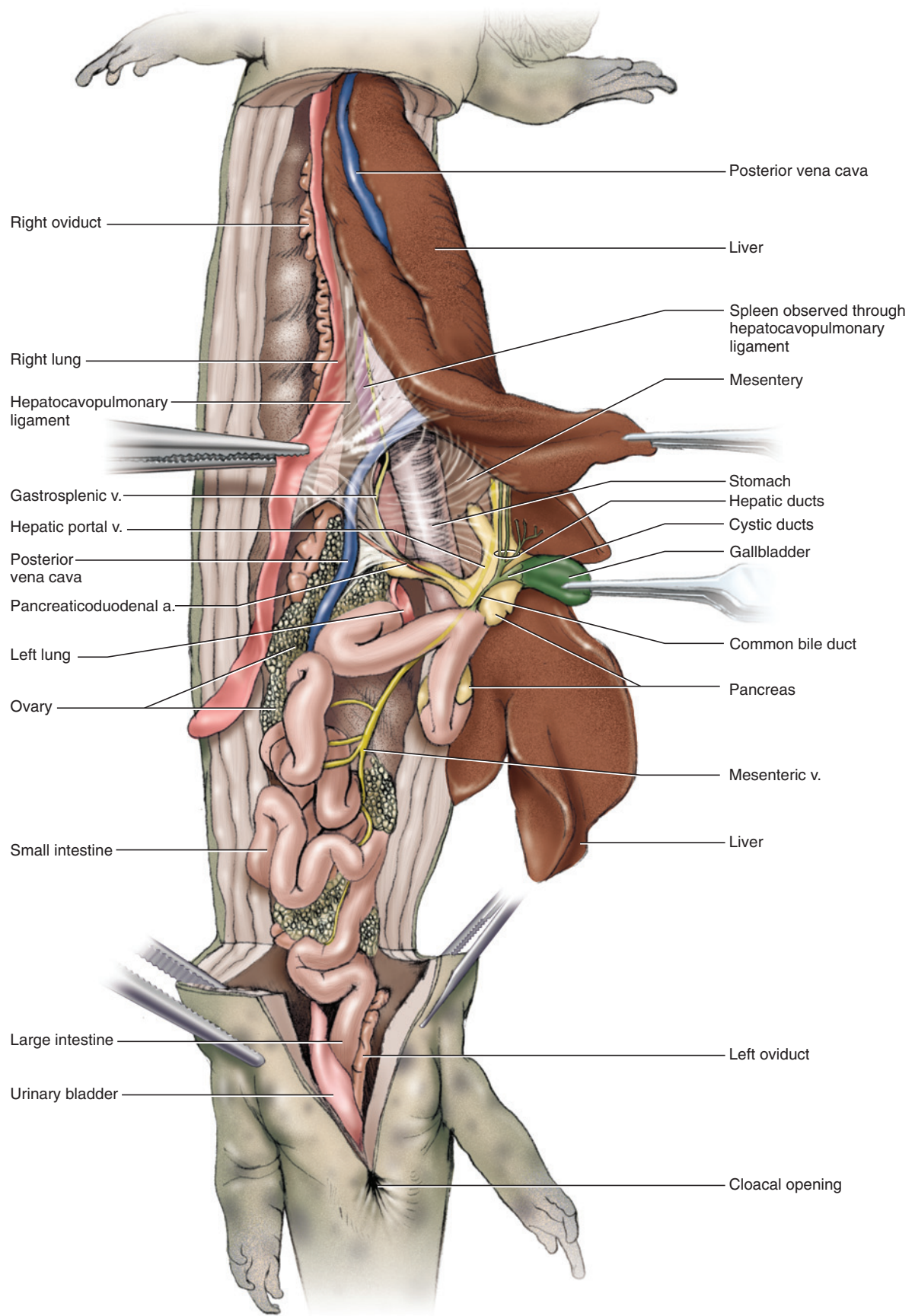


**FIGURE 5.12** Pleuroperitoneal cavity of the mudpuppy in ventral view, with the liver reflected to the right and stomach pulled to the left.



**FIGURE 5.13** Pleuroperitoneal cavity of the mudpuppy in ventral view, with the liver and stomach reflected to the right.





**FIGURE 5.14** Pleuroperitoneal cavity of the mudpuppy in ventral view, with the posterior end of the liver reflected to the left.



## Male Urogenital System

In males the **testis** is an elongated organ posteriorly in the pleuroperitoneal cavity lying ventral to the **kidney** (Figure 5.15). It is supported by the **mesorchium**. The kidney, longer than the testis, is considerably wider posteriorly than anteriorly. Its narrow anterior part is genital in function, while the wider posterior portion is urinary.

The **archinephric duct** is a longitudinal tube that runs along the lateral margin of the kidney. The portion along the genital part of the kidney is coiled, but its more posterior part, lying along the urinary portion of the kidney, is straight. Numerous small collecting tubules may be observed leading to the duct from the kidney. Trace the duct posteriorly to its entrance into the cloaca. In males the duct carries sperm from the testis, as well as urine from the urinary portion of the kidney. Sperm reaches the duct by way of ductules efferentes, which lead into the genital portion of the kidney and thence to the archinephric duct. The vestigial **oviduct** is a dark thread-like structure along the lateral edge of the archinephric duct. It has no connection with the latter and continues anteriorly on its own. The margins of the cloaca bear numerous **cloacal papillae**. Skin the region on one side of the cloaca to expose the **cloacal gland**, which consists of numerous tiny tubules and is involved in clumping sperm to form spermatophores.

## Female Urogenital System

In females the elongated **ovary**, supported by the **mesovarium**, may be quite large (Figure 5.16). The presence of numerous eggs within follicles gives the ovary a lobulated or granular appearance, in contrast to the more regular surface of the testes. The follicles and eggs vary in size depending on their stage of maturity, being quite large in some specimens (Figure 5.12) and smaller in others (Figures 5.14 and 5.16). The archinephric duct lies along the lateral margin of the kidney but is straight and narrower than in the male. In the female it carries only urine from the kidney. Follow it posteriorly to its entrance into the cloaca.

The **oviduct**, supported by the **mesotubarium**, is the long, prominent, and convoluted tube lying between the ovary and kidney and extending nearly the length of the peritoneal cavity. At its anterior end is the open, funnel-shaped **ostium**, into which the eggs pass after they have been released into the coelom by the ovary. Follow the oviduct posteriorly to its entrance into the cloaca. Cloacal glands and papillae are absent in the female.

## KEY TERMS: UROGENITAL SYSTEM

archinephric duct	mesovarium
cloacal gland	ostium
cloacal papillae	ovary
kidney	oviduct
mesorchium	testis
mesotubarium	

## SECTION VI—CARDIOVASCULAR SYSTEM

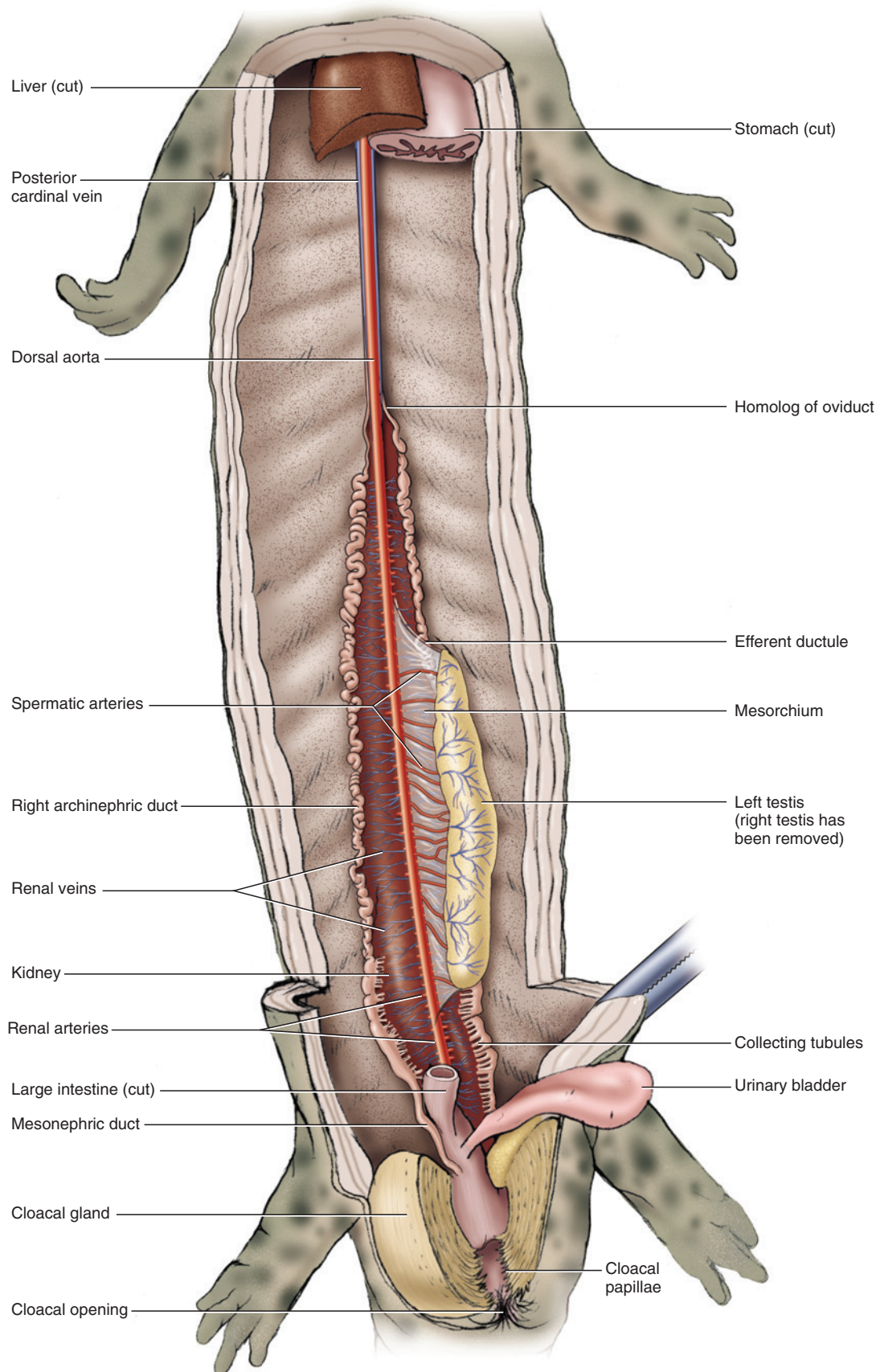
### Heart

The **pericardial cavity** lies just anterior to the liver. It is enclosed by the pericardial sac and contains the **heart** (Figure 5.17). Continue the midventral incision of the abdominal wall anteriorly, cutting through the coracoid cartilage, to expose the pericardial cavity. In doing so you will also cut through the **transverse septum**, the partition separating the pericardial and pleuroperitoneal cavities. Do not injure the posterior vena cava, which passes through the septum to reach the pericardial cavity. Carefully remove the musculature ventral to the cavity. The cavity is lined by **parietal pericardium**, while the heart itself is covered by **visceral pericardium**.

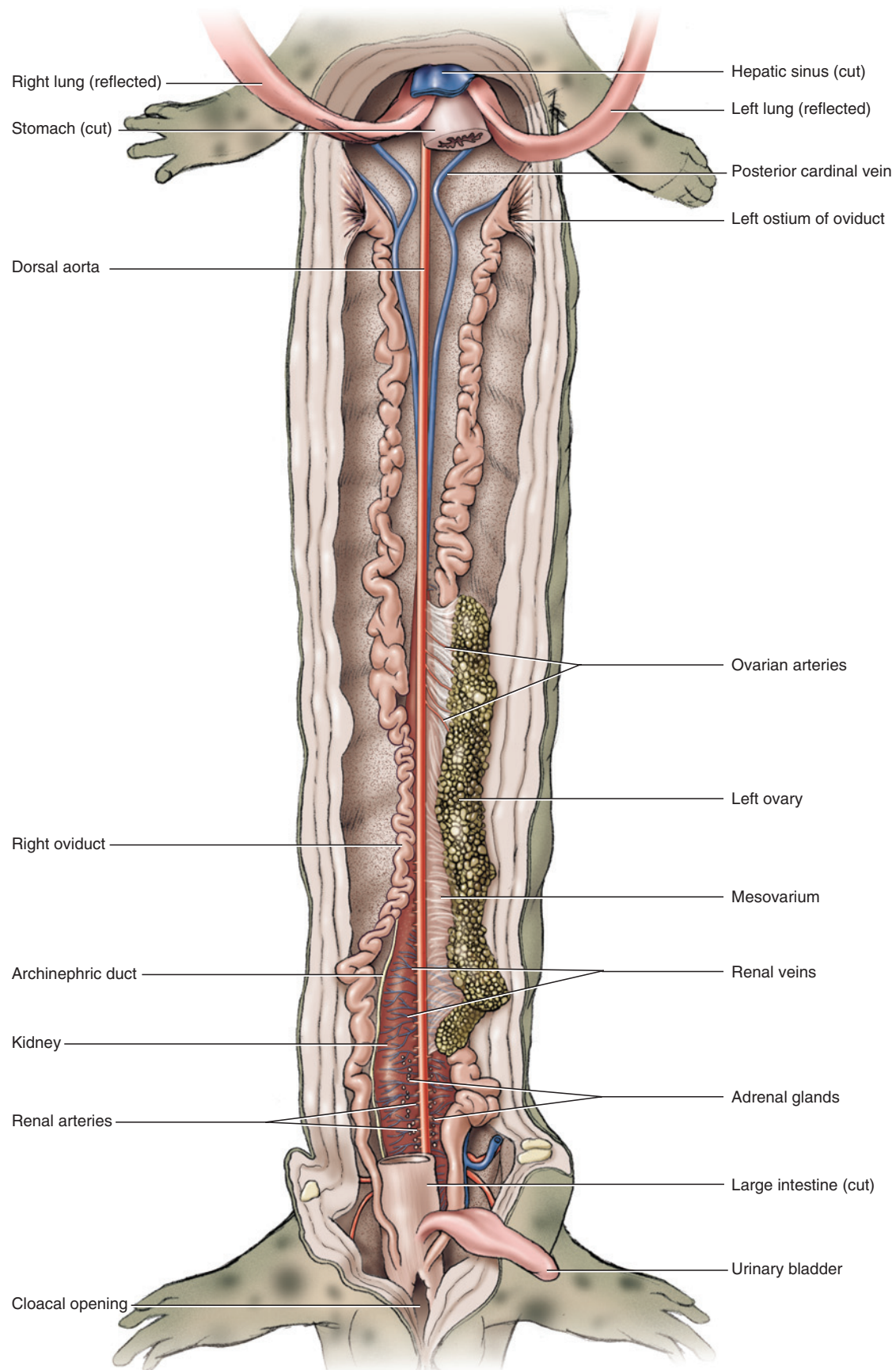
The largest and most conspicuous part of the heart is the **ventricle**, which occupies the posteroventral part of the pericardial cavity (Figure 5.18). Lift the posterior end of the ventricle to observe the **sinus venosus** (Figure 5.19). The atrium lies anterodorsal to the ventricle and is partially divided into **left** and **right atria**. The **conus arteriosus** is the narrow tube extending anteriorly between the atria from the right side of the ventricle. It continues anteriorly as the wider **bulbus arteriosus**.

### Venous System

Trace the posterior vena cava as it passes from the liver through the transverse septum. On entering the pericardial cavity, it subdivides into left and right **hepatic sinuses**, large vessels that extend anterolaterally into the sinus venosus (Figures 5.18 and 5.20). Probe just anterolateral to the entrance of the hepatic sinus on one side to observe the **common cardinal vein**, which enters the posterolateral end of the sinus venosus. The common cardinal vein mainly receives vessels that drain the head and forelimbs, such as the **jugular** and **lingual veins** as well as the **subclavian vein**, which is formed by the union of the **brachial** and **cutaneous veins**. It also

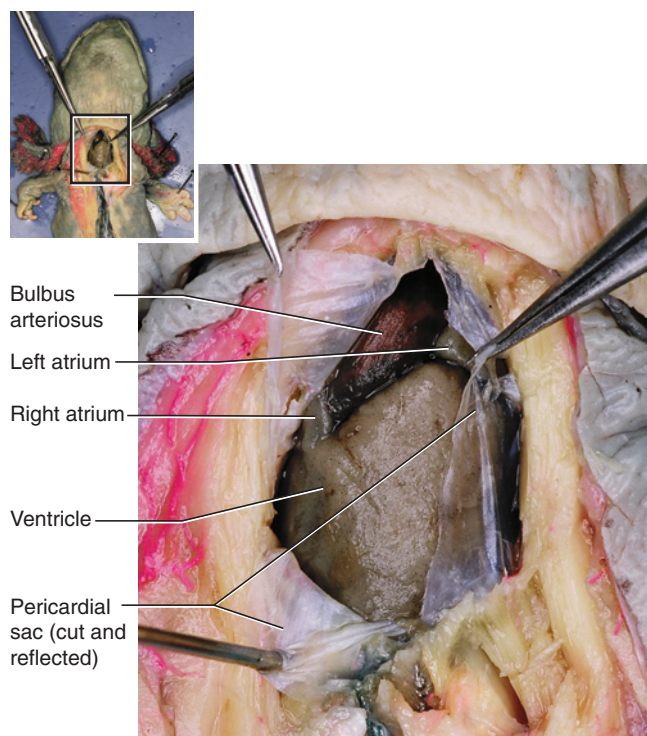


**FIGURE 5.15** Pleuroperitoneal cavity of the male mudpuppy in ventral view, showing the urogenital system. Much of the viscera has been removed.



**FIGURE 5.16** Pleuroperitoneal cavity of the female mudpuppy in ventral view, showing the urogenital system. Much of the viscera has been removed.





**FIGURE 5.17** Pericardial cavity of the mudpuppy in ventral view, opened to reveal the heart.

receives the **lateral vein**, which extends along the lateral side of the trunk, and the **posterior cardinal vein** (Figures 5.18 and 5.20).

Various veins within the peritoneal cavity have already been identified. The posterior vena cava was identified first as it passed to the liver through the hepatocavopulmonary ligament and then through the transverse septum. Reidentify this vein. Follow it as it passes through the liver, from which it receives several **hepatic veins**. Posteriorly, it passes middorsally in the pleuroperitoneal cavity, extending between the kidneys (Figure 5.20). It receives numerous **effluent renal veins** from the kidneys, as well as **testicular** or **ovarian veins** from the gonads (see also Figure 5.20).

A **renal portal vein** extends longitudinally along the dorsolateral margin of each kidney. Follow it posteriorly. At about the level of the hind limbs, each renal portal vein receives a **common iliac vein**. Posterior to the kidneys, the left and right renal portal veins form by the bifurcation of the median **caudal vein** from the tail. Anterior to the kidneys, the renal portal veins become the **posterior cardinal veins**. In this region the posterior cardinals anastomose with the posterior vena cava via the converging **subcardinal veins**; anteriorly, they drain into the common cardinal sinus.

The **ventral abdominal vein** was observed passing through the free posterior margin of the falciform ligament (Figure 5.11). Return to this vessel. As you will see presently, its anterior end joins the **hepatic portal vein**. For now, follow the ventral abdominal vein posteriorly along the midventral abdominal wall. As noted above, it receives the **vesicular vein** from the urinary bladder. The ventral abdominal vein is formed, farther posteriorly, by the union of left and right **pelvic veins**. Follow one of the pelvic veins posterolaterally. At the level of the hind limbs, it receives the **femoral vein**. At this point, note that the common iliac vein, observed above as it entered the renal portal vein, joins the pelvic and femoral veins. The iliac is thus a short vein running between the renal portal vein and the union of the pelvic and femoral veins.

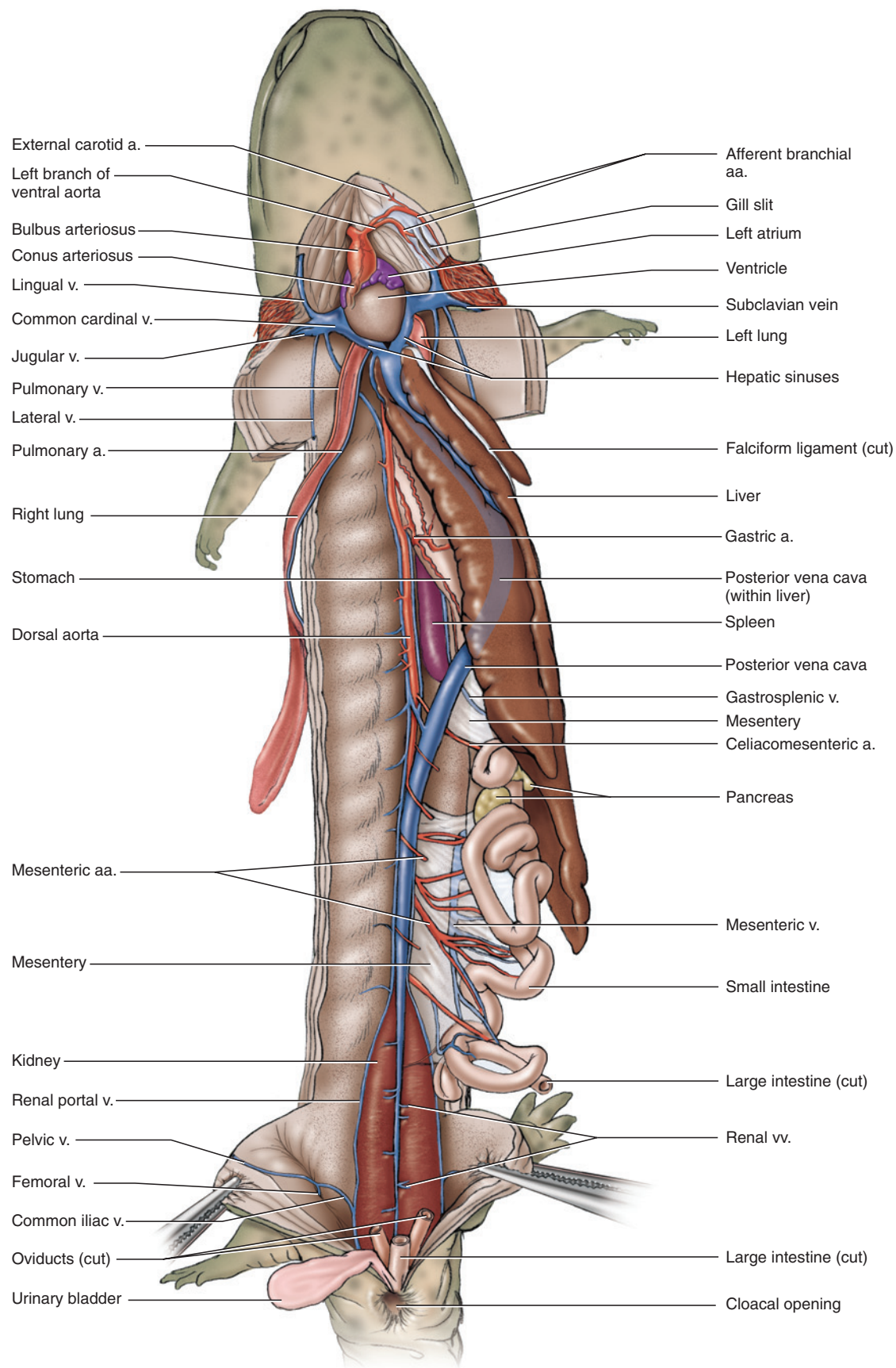
Observe the mesentery by spreading the coils of the small intestine. The **mesenteric vein** runs within the mesentery (Figure 5.18). Follow it as it passes anteriorly toward the pancreas. Next, locate the **gastrosplenic vein**, identified above as extending between the pancreas and spleen. The union of these veins, within the pancreas, forms the **hepatic portal vein**, which runs along the dorsal surface of the liver before entering this organ (Figure 5.20). The ventral abdominal vein joins the hepatic portal vein a short distance anterior to the union of the mesenteric and gastrosplenic veins.

## Arterial System

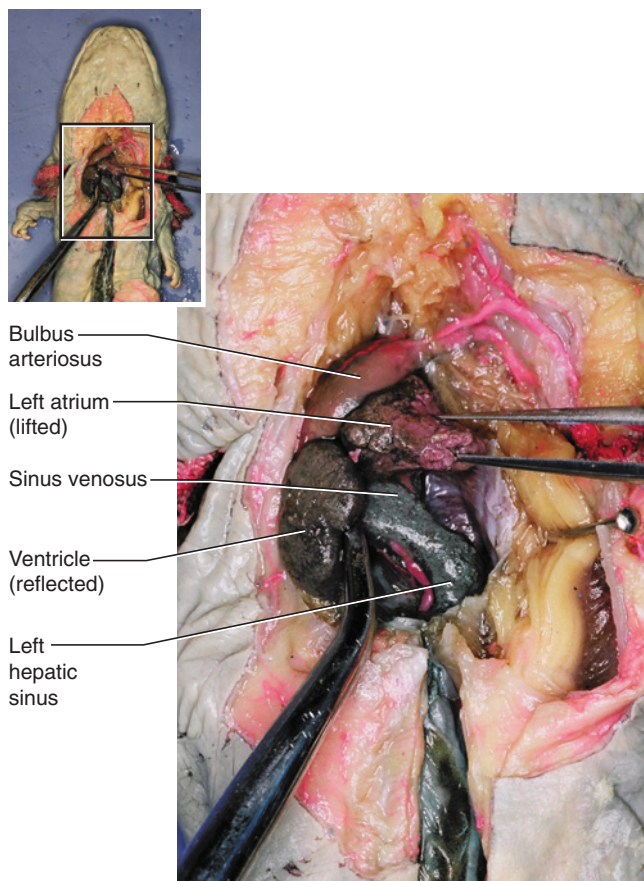
Return to the bulbus arteriosus. As it leaves the front of the pericardial cavity, it bifurcates into left and right arteries (Figure 5.21). Each of these arches laterally and subdivides into two branches. They are probably not injected, but usually have remnants of blood so that they can, with diligence, be followed. The most anterior branch is the **first afferent branchial artery**, which follows the first branchial arch and enters the first external gill. The second branch bifurcates into the **second** and **third afferent branchial arteries**. Follow them, respectively, into the second and third external gills. The **external carotid artery**, which should be injected, is a narrow vessel running anteromedially along the anterior margin of the first afferent branchial artery.

Remove the lining on the roof of the oral cavity and pharynx. Medial to the external gills are the left and right **radices** (sing., **radix**) of the **dorsal aorta** (Figure 5.22). Each radix arches toward the dorsal midline and joins its fellow to form the dorsal aorta, which continues middorsally along the trunk and tail. Follow the radix laterally. Its first branch is the **vertebral artery**, which passes anteriorly and almost immediately enters the musculature. Further laterally, a short





**FIGURE 5.18** Pleuroperitoneal cavity of the mudpuppy in ventral view, revealing heart and vessels. Liver is pulled to the left.



**FIGURE 5.19** Pericardial cavity of the mudpuppy in ventral view, exposing the heart. The ventricle and atrium are lifted and moved aside to reveal the sinus venosus.

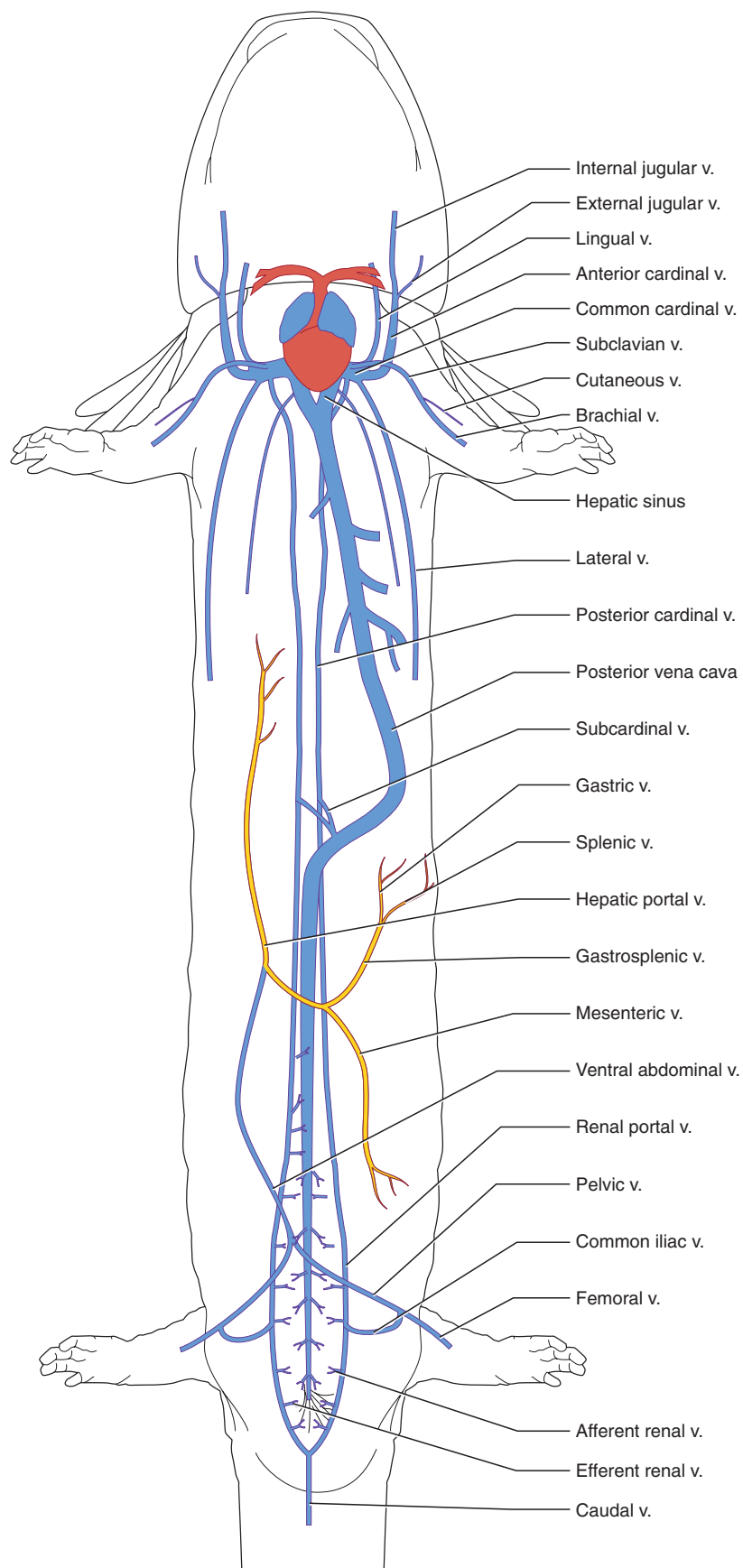
trunk, the **carotid duct**, enters the anterior surface of the radix. The duct connects to the following two arteries. The **first efferent branchial artery** extends medially from the first external gill. The **internal carotid artery** extends anteromedially from the trunk, and helps supply the facial region and brain. The **external carotid artery**, observed in connection with the afferent branchial arteries, helps supply the floor of the mouth and pharynx. It arises from the first efferent branchial artery just after the latter emerges from the gill. Return to the radix and continue to follow it laterally. The **pulmonary artery** arises from its posterior surface and passes to the lung. Beyond the pulmonary artery, the **second and third efferent branchial arteries**, which emerge from the second and third gills, respectively, unite to form the radix.

As in the other vertebrates so far studied, the dorsal aorta supplies the structures of the trunk by paired and unpaired branches. Its most anterior paired vessels are

the **subclavian arteries**. Each subclavian extends almost directly laterally, giving off several small arteries before continuing into the forelimb as the **brachial artery**. The next few posterior arteries are single median arteries that mainly supply the viscera (Figure 5.23). The most anterior of these, the **gastric artery**, arises near the anterior end of the stomach and passes to this organ. The larger **celiacomesenteric artery** arises near the posterior end of the stomach and soon subdivides into various branches that primarily supply the spleen, stomach, duodenum, and liver. The dorsal aorta then gives off several unpaired **mesenteric arteries** that pass through the mesentery and supply the intestines. In addition, the aorta gives off paired **testicular or ovarian arteries** to the testes or ovaries that pass through the mesorchium or mesovarium, respectively, and paired **renal arteries** that pass into the kidneys. Dorsal to the posterior part of the kidneys, large, paired **iliac arteries** extend laterally. Each branches into three vessels, an anterior **epigastric artery** (onto the body wall), a lateral **femoral artery** (into the hind limb), and a posterior **hypogastric artery** (to the cloaca and urinary bladder). The small, paired **cloacal arteries** are the last branches of the aorta, which then continues into the tail as the **caudal artery**.

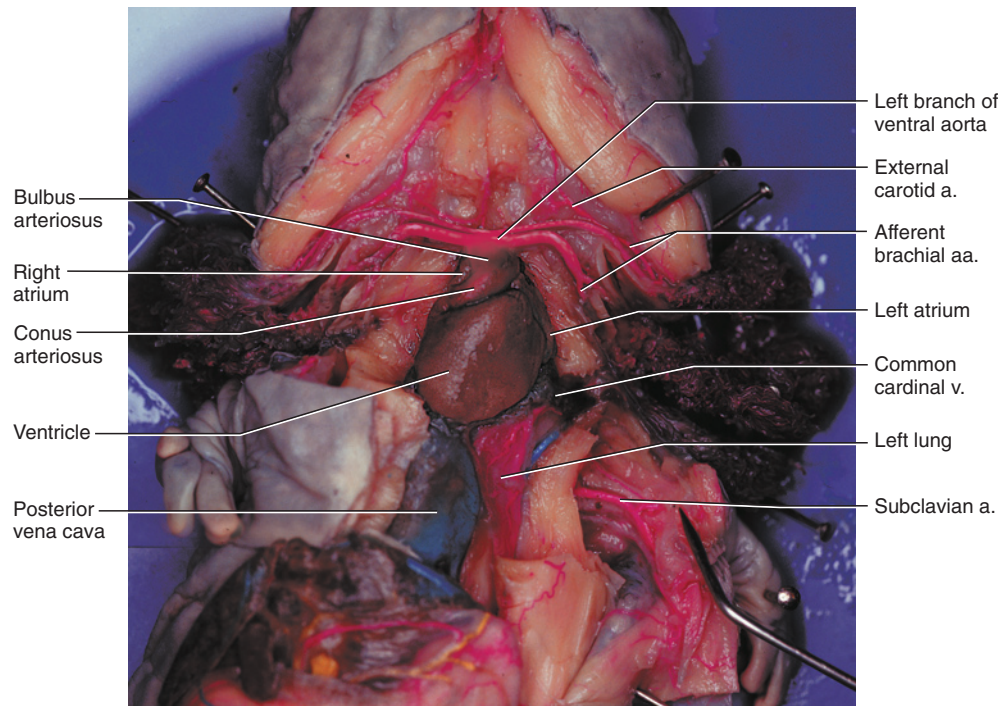
### KEY TERMS: CARDIOVASCULAR SYSTEM

afferent branchial arteries	femoral vein
brachial artery	gastric artery
brachial vein	gastrosplenic vein
bulbus arteriosus	heart
carotid duct	hepatic portal vein
caudal artery	hepatic sinuses
caudal vein	hepatic veins
celiacomesenteric artery	hypogastric artery
cloacal arteries	iliac arteries
common cardinal vein	internal carotid artery
common iliac vein	jugular vein
conus arteriosus	lateral vein
cutaneous vein	left atrium
dorsal aorta	lingual vein
efferent branchial arteries	mesenteric arteries
efferent renal veins	mesenteric vein
epigastric artery	ovarian arteries
external carotid artery	ovarian vein
femoral artery	parietal pericardium
	pelvic veins
	<i>Continues</i>

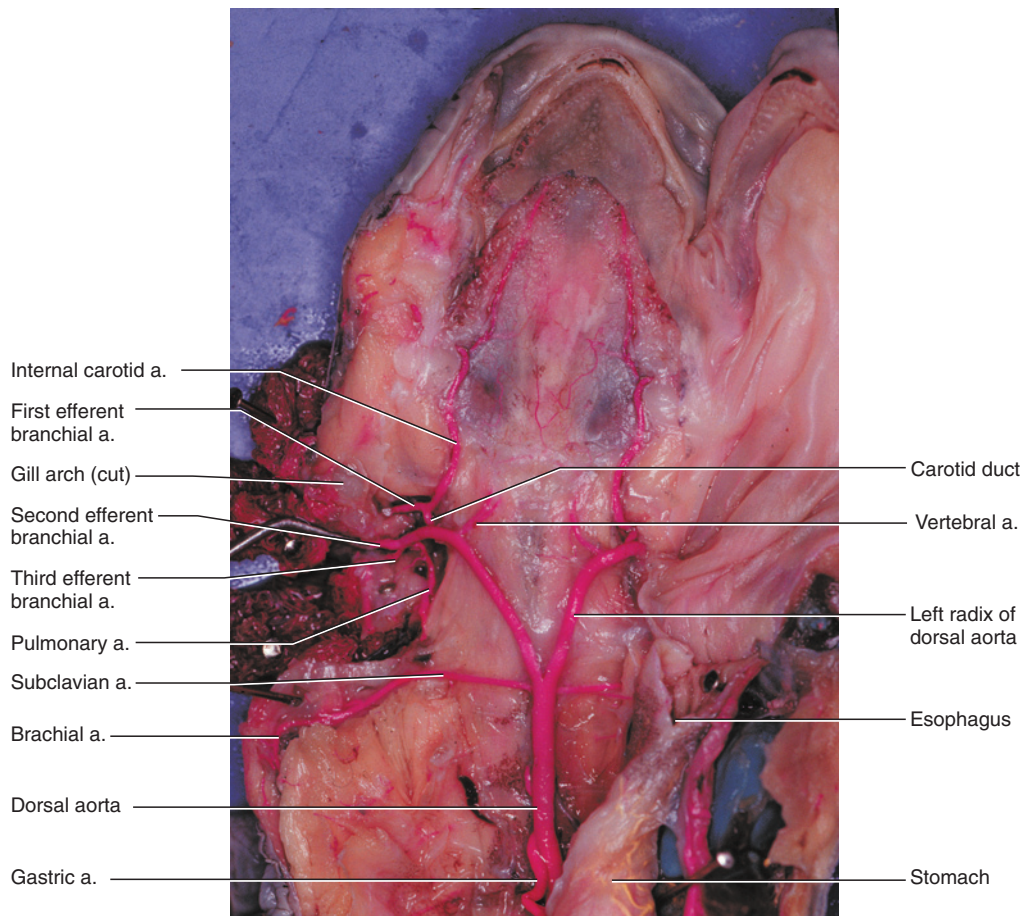


**FIGURE 5.20** Schematic illustration showing the pattern of the venous system in the mudpuppy superimposed on a ventral view of the body outline.



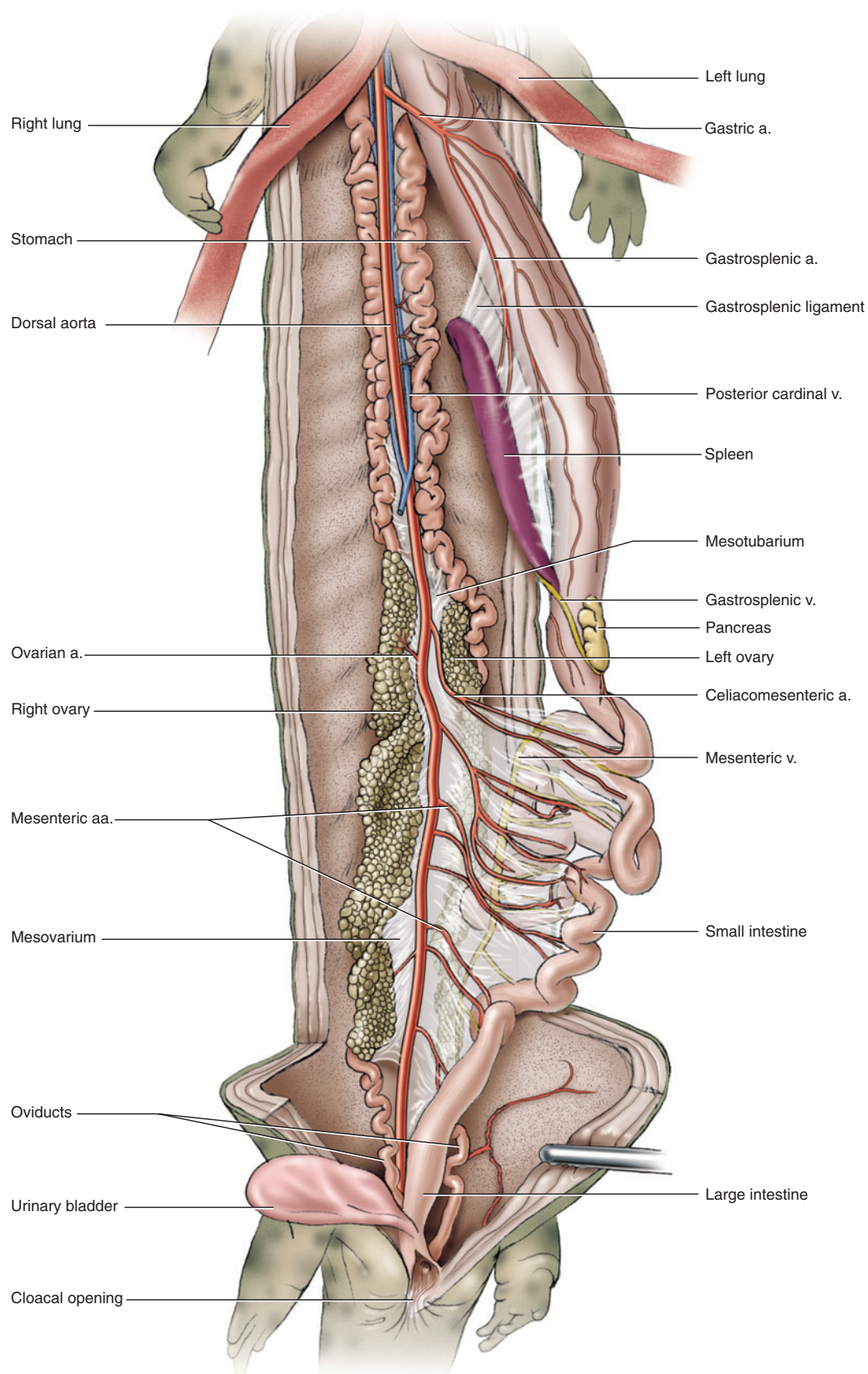


**FIGURE 5.21** Ventral view of the heart and ventral aorta in the mudpuppy.



**FIGURE 5.22** Ventral view of the dorsal aorta and its branches in the mudpuppy. The right side of the mouth has been cut and the lower jaw swung open.





**FIGURE 5.23** Pleuroperitoneal cavity of the mudpuppy in ventral view, showing the pattern of the arterial system posterior to the heart.

pericardial cavity  
posterior cardinal vein  
pulmonary artery  
radices (sing., radix)  
renal arteries

renal portal vein  
right atrium  
sinus venosus  
subcardinal veins  
subclavian artery

subclavian vein  
testicular artery  
testicular vein  
transverse septum  
ventral abdominal vein

ventricle  
vertebral artery  
vesicular vein  
visceral pericardium

This page intentionally left blank

# CHAPTER 6

## THE FROG

### INTRODUCTION

The North American bullfrog, *Rana catesbeiana*, is a member of the Anura, which together with the Caudata (salamanders and newts) and the Gymnophiona (caecilians or apodans) form the Lissamphibia, the only living group of amphibians. Frogs have a long fossil history, with the Early Triassic *Triadobatrachus massinoti* recognized as the earliest frog. This primitive frog is included with the Anura in the Salienta (although some authorities consider the Salienta and Anura as equivalent). As with lissamphibians generally, anurans tend to have permeable, scaleless skin, kept moist by numerous mucous glands, that allows for considerable cutaneous respiration. Frogs have highly specialized locomotory features that make them instantly recognizable. Most obvious perhaps are that the body is rigid, short, and wide, the hind limbs are long and, familiarly though not exclusively, used for jumping, and the tail is absent. It is to the last feature that the group owes its name: Anuran is derived from the ancient Greek words meaning “without” (*an*) and “tail” (*oura*).

These specializations, among others, provide ample proof of the risks involved in viewing living vertebrates as primitive or somehow intermediate between other vertebrate grades. They (and the other lissamphibians) are in fact highly derived tetrapods. Anurans are the most successful lissamphibians, including more than 4,000 species, living on all continents except Antarctica. They have diversified into numerous and markedly different ecological types, even within families.

Anurans generally have an aquatic tadpole or larval stage and undergo metamorphosis to produce the radically different adult form, but different reproductive strategies have evolved. Some, such as some members of the Pipidae, a group of specialized aquatic frogs, produce eggs that develop directly into juvenile frogs, whereas other pipids have aquatic larvae. Some species of *Nectophrynoides* (Bufonidae, the true toads) are viviparous, and in *Gastrotheca* (Hylidae) the juvenile frogs develop directly in pouches in the female's skin. In the species *Rhinoderma darwini* (Rhinodermatidae) the

tadpoles complete their development in the vocal sacs of the male.

Long hind limbs used for jumping is the stereotyped frog locomotory behavior. Again, considerable specialization exists among anurans in this regard. For example, pipids are specialized aquatic frogs with webbed feet used for propulsion through water. Several clades (e.g., Centrolenidae, Hylidae, Rhacophoridae) include arboreal frogs, which can move by quadrupedal walking or climbing as well as by leaping. The Hemisotidae include burrowing frogs that dig headforemost, a behavior reflected by their heavily ossified skulls. Several terrestrial frogs tend to hop or walk rather than jump, such as the Bufonidae, which tend to have heavy or robust bodies with relatively short legs.

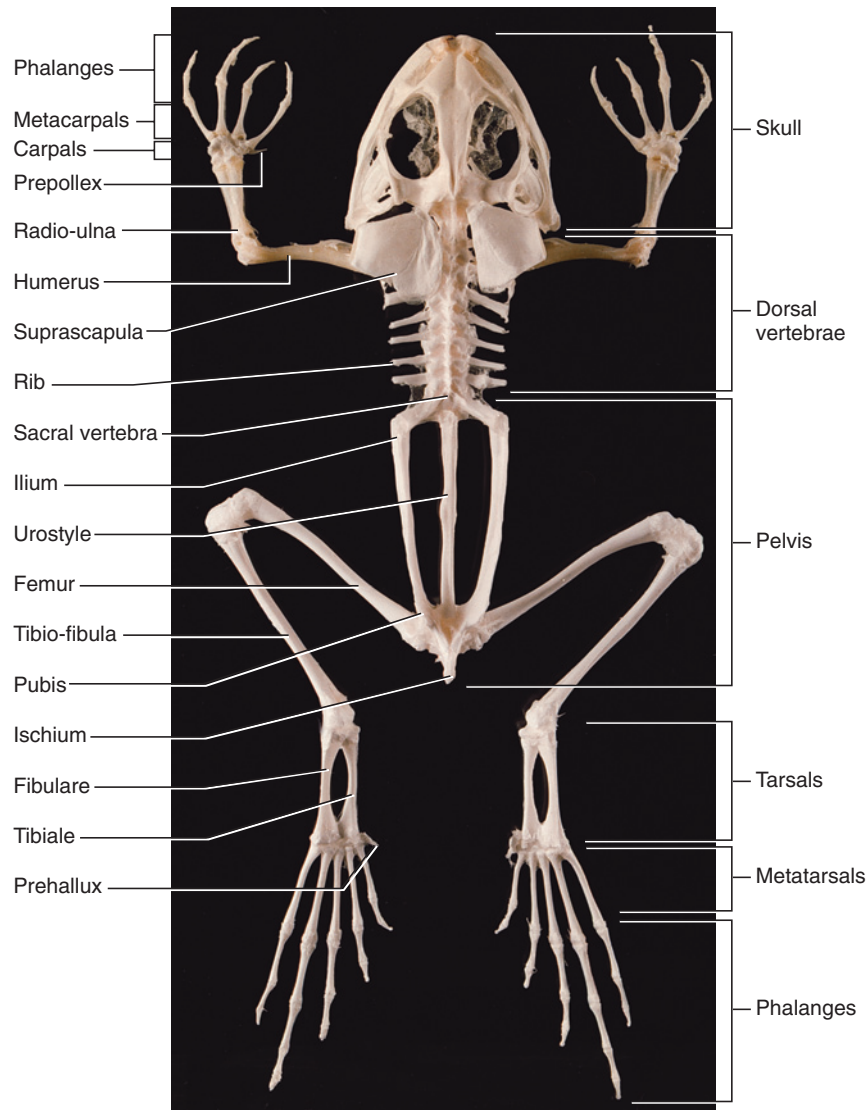
Although frogs are commonly used in vertebrate dissection courses, it is worth remembering that, as vertebrates, they are neither primitive nor typical—they are just readily available. However, their frequent use, particularly for some species, has been a factor in their decline in many areas. *Rana catesbeiana* belongs to the Ranidae, although the systematics of this group are not resolved and it may be paraphyletic. *R. catesbeiana* is a native North American frog with a fairly wide natural distribution and has been introduced in Asia, South America, and parts of Europe. Bullfrogs vary considerably in size, but length tends to be between 10–17 cm, although many will be 20 cm in length. They live in water, so are found near lakes, ponds, and rivers.

### SECTION I—SKELETON

#### Skull, Mandible, and Hyoid Apparatus

The skeleton of anurans demonstrates quite dramatically the misleading assumption that many beginning students have about amphibians—that they are intermediate between fishes and higher tetrapods, and so are simpler versions of reptiles and mammals. One glance at the highly specialized skeleton of a frog should suffice to dispel such views. The skeleton described here is of *Rana catesbeiana*, but its features apply to anurans generally.





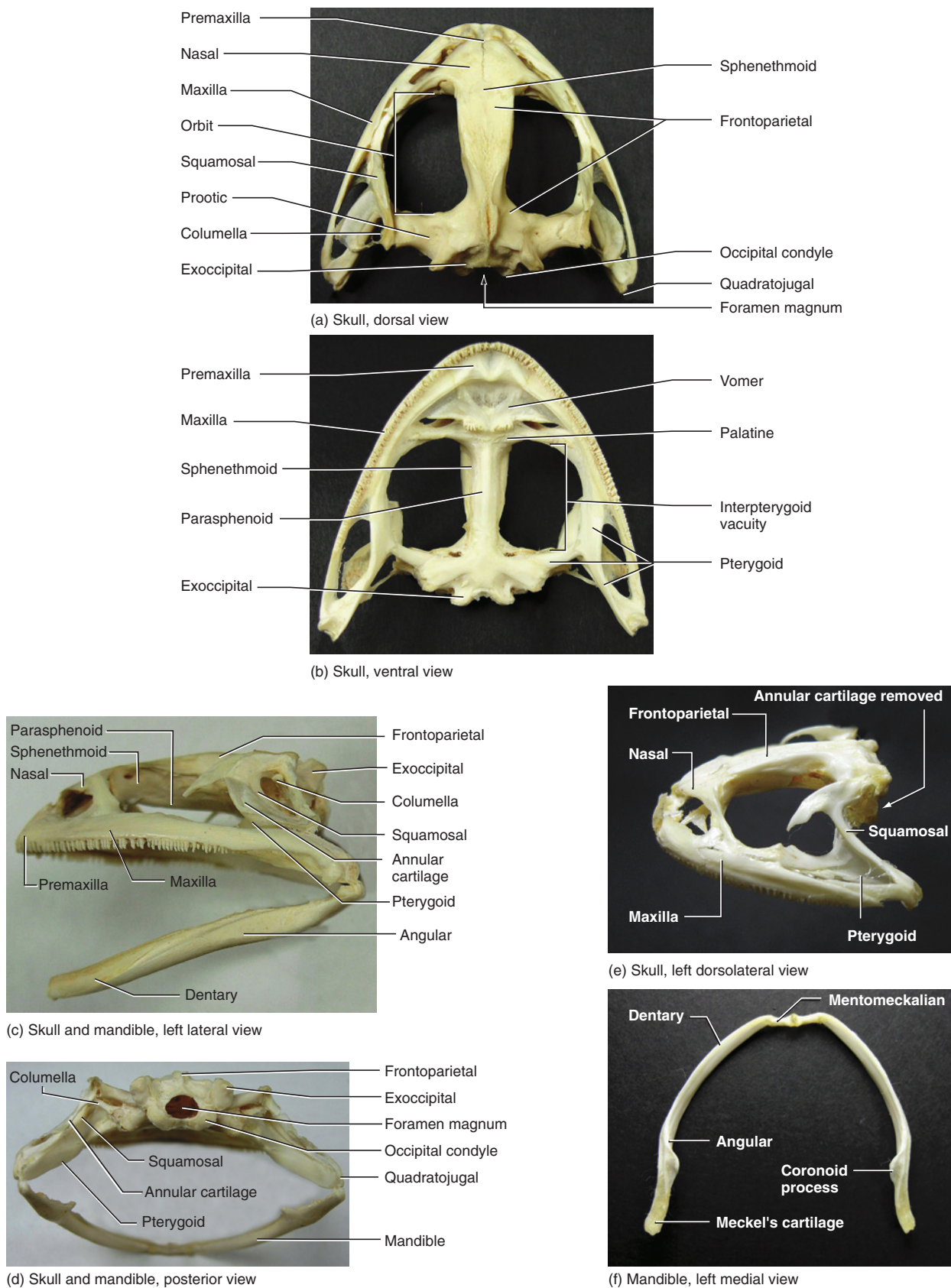
**FIGURE 6.1** Dorsal view of the skeleton of the frog.

Living amphibians generally tend to have specialized and reduced (and in some cases largely cartilaginous) skeletons, and that of frogs is no exception (Figure 6.1). There has indeed been considerable loss of bone and decrease in ossification over basal tetrapods (as well as higher tetrapods), which is clearly evident in the broad, flattened, and fenestrated **skull** (Figures 6.1 and 6.2). Two particularly large openings are the **orbits** dorsally and the **interpterygoid vacuities** ventrally on the palate.

Examine the skull in dorsal view (Figure 6.2a). Its margin is approximately parabolic. On each side, this margin is composed of the small median **premaxilla**, the long **maxilla**, and the shorter **quadratojugal**, in anterior to posterior order. Ventrally, the premaxilla and maxilla bear a single row of small teeth, the **premaxillary** and **maxillary teeth**, respectively (Figures 6.2b–d). The

**vomers** lie anteriorly just behind the premaxillae. They bear vomerine teeth.

The paired **nasals** are broad and flattened medially and contact each other on the dorsal midline (Figures 6.2a, c, d). Each has a narrow process that extends lateroventrally, forming the anterior margin of the large orbits, and contacts an ascending process of the maxilla. The paired **frontoparietals** are elongated, flattened bones that meet along the dorsal midline to form most of the cranial roof. Much of the side and ventral parts of the braincase are formed by the **sphenethmoid**, which is exposed mainly in ventral and lateral views (Figures 6.2b, c). It is essentially tubular, but its anterior part expands laterally. Examine the skull in ventral view to see this anterior part. Here, the **palatines** extend as transverse bars on either side of the sphenethmoid to reach the maxillae. A small portion of the sphenethmoid



**FIGURE 6.2** Skull and mandible of the frog. (a) dorsal and (b) ventral views of the skull; (c) and (d) left lateral and posterior views of the skull and mandible; (e) left dorsolateral view of the skull; (f) dorsal view of the mandible.

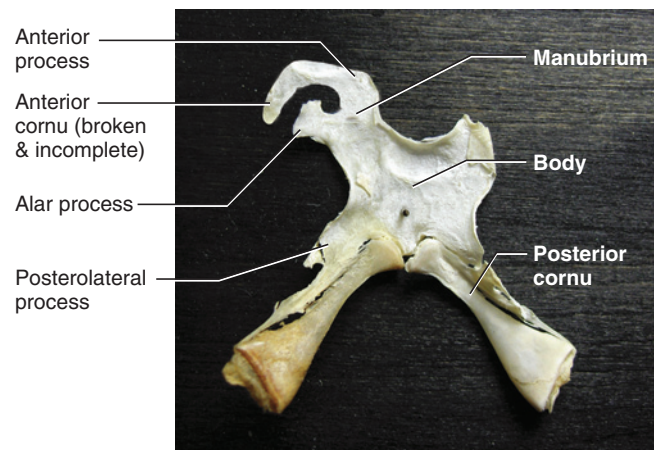
that helps form the roof of the braincase is exposed dorsally, wedged between the nasal and frontoparietal bones.

The **parasphenoid** is approximately cruciate or “t”-shaped (Figure 6.2b). The anteriorly tapering stem of the “t” covers the sphenethmoid ventrally. The top part of the stem projects posteriorly toward the **occipital** bones. Each transverse arm of the “t” extends laterally toward a **pterygoid** bone. The paired occipital bones form the posterior part of the skull (Figure 6.2e). They enclose the **foramen magnum**, the large opening for passage of the spinal cord. Ventrally, each exoccipital bears an **occipital condyle** for articulation with the atlas. The pterygoid is triradiate, or “y”-shaped, with its three arms extending out to contact other skeletal elements (Figure 6.2b). Its anterior arm extends anteriorly and contacts the maxilla and nasal, while its posterior arm extends posteriorly, curving gently laterally, to the angle of the jaws. The medial arm is shortest. It extends toward the **prootic** (see below) and transverse stem of the parasphenoid.

Examine the posterior end of the skull in lateral view and identify the “T”-shaped **squamosal** (Figures 6.2c, d). Its long stem is oriented posteroventrally toward the angle of the jaw. The top of the “T” is curved, with one arm extending anteroventrally, the other posterodorsally. Some prepared specimens provide an unobstructed view of the squamosal (Figure 6.2c), due to the absence of the **annular cartilage** that supports the **tympanic membrane**. Other specimens retain the cartilage, and the distal end of the **columella** (Figure 6.2c; see below) can be seen within the area it circumscribes.

Examine the skull in dorsal view. The irregularly shaped **prootics** contain the inner ear. The prootic extends between the squamosal laterally, and the exoccipital and frontoparietal medially. Anteriorly it helps form the posterior wall of the orbit and contains a large opening, the **trigeminal foramen**, through which the trigeminal nerve (Cranial Nerve V) passes. Posteriorly the prootic and exoccipital form the **foramen ovale**, the opening just beside the occipital condyle, for passage of the glossopharyngeal and vagus nerves (Cranial Nerves IX and X, respectively).

The **mandible** is a slender, parabolic, edentulous structure. Each half of the mandible is composed of a cartilaginous element and two bony elements. The largest element is the **angulare**, which forms most of the demimandible. Its posteromedial surface bears a medially directed flange, the **coronoid process**. The angulare has a long, trough-like groove on its dorsal surface. The groove is occupied by **Meckel’s cartilage**, much of which is often unpreserved in most specimens. However, you should be able to see portions of it, especially at the pos-



**FIGURE 6.3** Hyoid of the frog in dorsal view. The anterior portion of the right side is missing.

terior end of the trough, where Meckel’s cartilage forms the articulation with the upper jaw. The cartilage extends to the anterior end of the demimandible and is ossified as a recognizable element, the **mentomeckalian**. The right and left mentomeckalians are connected by a ligamentous attachment. The **dentary** is a thin flange of bone that covers the anterolateral surface of the demimandible.

The **hyoid apparatus** is mainly a thin, broad cartilaginous plate, or body, on the floor of the oral cavity that supports the tongue and larynx (Figure 6.3). Several processes project from it. The **anterior cornu** initially extends anteriorly, but curves sharply posterodorsally to attach to the skull. In Figure 6.3 only part of the left anterior cornu is preserved. The **posterior cornua** are bony rods extending from the posterior margin. They begin medially but diverge to contact the larynx.

### KEY TERMS: SKULL, MANDIBLE, AND HYOID APPARATUS

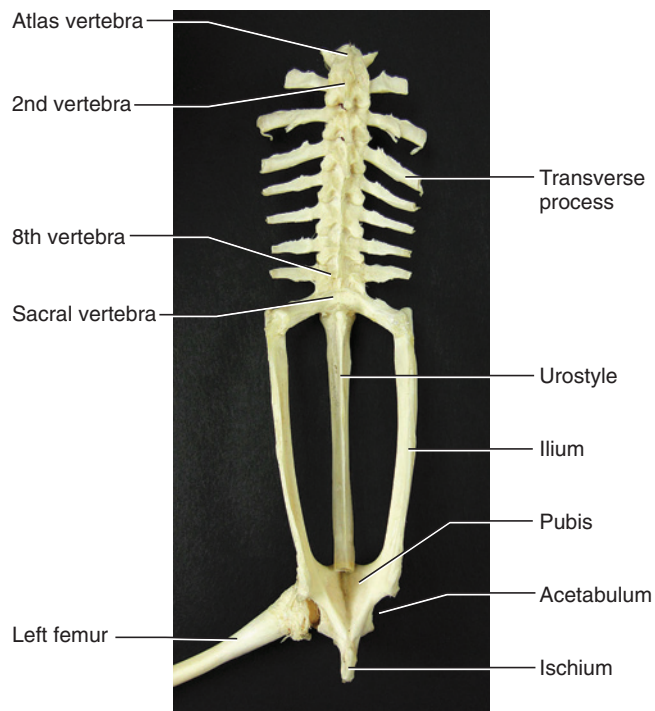
angulare	maxillary teeth
annular cartilage	Meckel’s cartilage
anterior cornu	mentomeckalian
columella	nasals
coronoid process	occipital
dentary	occipital condyle
foramen magnum	orbits
foramen ovale	palatines
frontoparietals	parasphenoid
hyoid apparatus	posterior cornu
interpterygoid vacuities	premaxilla
mandible	premaxillary teeth
maxilla	prootic



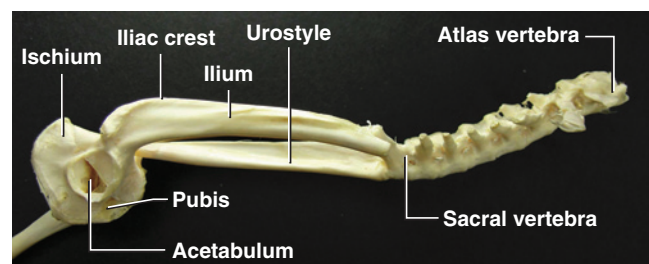
pterygoid	squamosal
quadratojugal	trigeminal foramen
skull	tympanic membrane
sphenethmoid	vomers

## Postcranial Skeleton

The postcranial skeleton also shows evidence of extreme modification, associated mainly with the highly specialized locomotor mechanism characteristic of most anurans. The **vertebral column** is reduced, with only nine free **vertebrae** (Figure 6.4). Most anteriorly in this series is the **atlas**, which articulates with the occipital condyles of the skull. The last free vertebra is a **sacral vertebra**, attaching to the **pelvic girdle** (see below). Extending posteriorly from the sacral vertebra is the



(a) Vertebral column and pelvic girdle, dorsal view

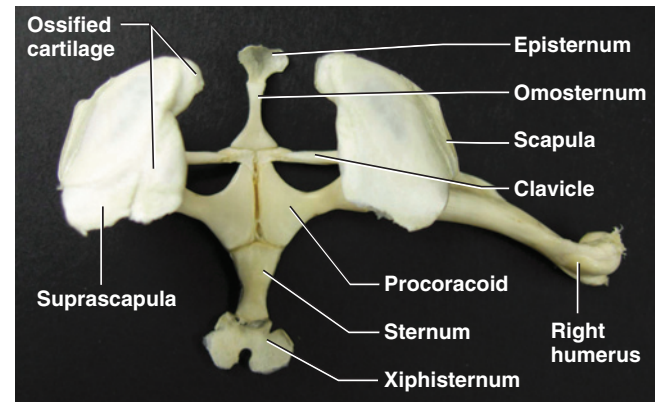


(b) Vertebral column and pelvic girdle, right lateral view

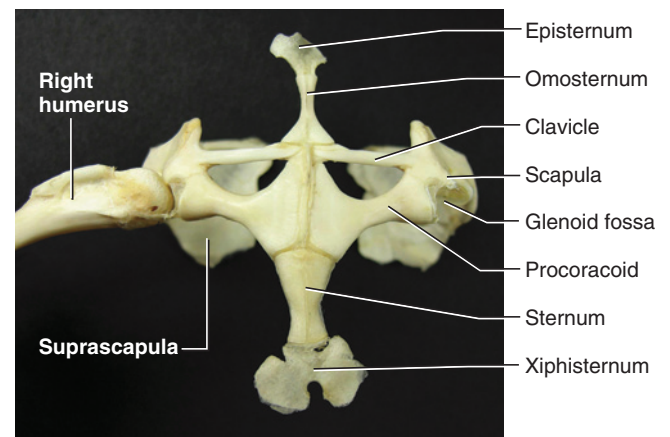
**FIGURE 6.4** Vertebral column and pelvis of the frog in dorsal and right lateral views.

elongated, rod-like **urostyle**, which is formed by the fusion of several vertebrae. The vertebrae have prominent **transverse processes**, but ribs are lacking.

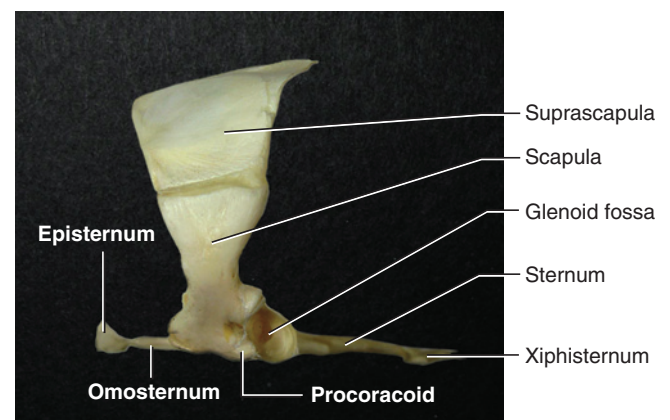
The appendicular skeleton is well developed. The **pectoral girdle**, largely ossified, contains several elements (Figures 6.1 and 6.5). The **scapula** is a nearly vertical



(a) Pectoral girdle, dorsal view



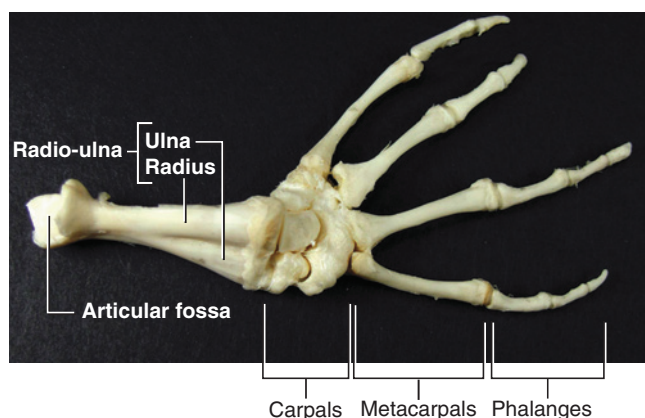
(b) Pectoral girdle, ventral view



(c) Pectoral girdle, left lateral view

**FIGURE 6.5** Pectoral girdle of the frog in (a) dorsal, (b) ventral, and (c) left lateral views.





**FIGURE 6.6** Right antebrachium and manus of the frog in dorsal view.

plate-like structure. Extending dorsomedially from it is the **suprascapula**, which has a prominent and usually calcified cartilaginous portion medially. Ventrally, there are two large paired elements. The more anterior and slender paired **clavicle**, a dermal element, extends almost directly medially from the scapula. The larger, more posterior **procoracoids** form a plate-like base to the girdle. The **glenoid fossa**, for articulation with the **humerus** (see below), is formed mainly by the **scapula** and **procoracoid**. An anterior median element, the **omosternum**, lies anteriorly. The cartilaginous **episternum** extends anteriorly from it. A posterior median element, the **sternum**, articulates with the procoracoids. A cartilaginous **xiphisternum** extends posteriorly from it.

The forelimb includes three segments, the most proximal of which is the **humerus**, extending laterally from the glenoid fossa (Figures 6.1 and 6.5). The next segment includes the **radius** and **ulna**, fused to form a **radio-ulna** (Figures 6.1 and 6.6). The **manus** includes a proximal series of small, nodular **carpals**, followed by four complete **digits**, including **metacarpals II–V** and **phalanges**. The two medial digits each bear two phalanges, while the lateral two bear three phalanges each. A small **prepollex** extends medially from the carpals and may represent a reduced metacarpal.

In the **pelvic girdle**, the **pelvis** is formed on each side by the **ilium**, **ischium**, and **pubis** (Figures 6.1 and 6.4). The slender ilium is an elongated, anteriorly directed element, with a well developed **iliac crest**. The ischium and pubis together outline a semicircle in lateral view, the ischium forming the more posterior portion. The **acetabulum** is a conspicuous depression for articulation with the **femur** (see below). The hind limb consists of the proximal femur, followed by the **tibia** and **fibula**, fused to form the **tibio-fibula**. The **pes** has rather typical **metatarsals** and **phalanges**, but a modification in the

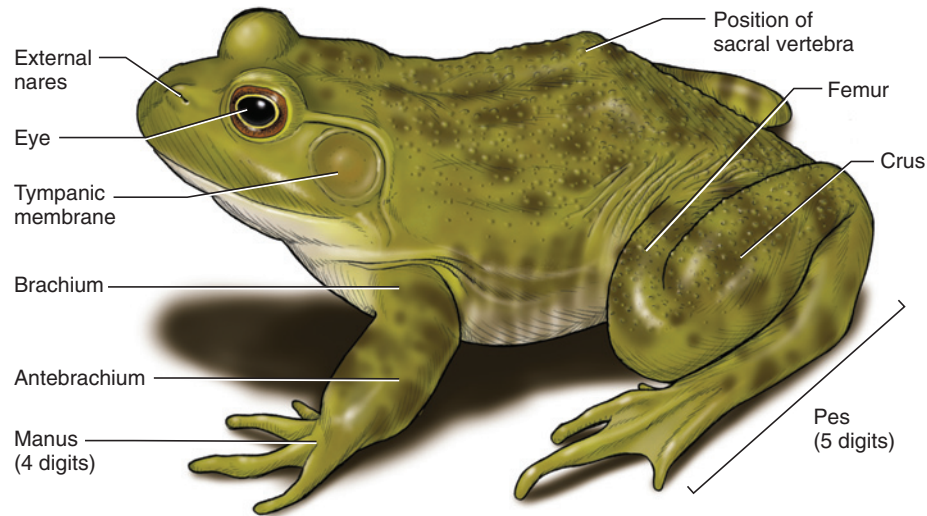
tarsal region produces another functional segment to the hind limb, a feature that is related to the saltatory locomotion of frogs. Here, the two proximal tarsals are elongated to form a medial **tibiale** (= **astragalus**) and lateral **fibulare** (= **calcaneum**) that are partly fused at their ends. The distal tarsals have the more typical nodular form. There are five digits, with the first being the shortest and the fourth longest. Digits I and II each bear two phalanges, III and V three, and IV four. A small **prehallux**, similar to the prepollex, extends medially from the tarsal region.

## KEY TERMS: POSTCRANIAL SKELETON

acetabulum	pes
atlas	phalanges
carpals	prehallux
clavicle	prepollex
digits	procoracoids
episternum	pubis
femur	radio-ulna
fibula	radius
fibulare (= calcaneum)	sacral vertebra
glenoid fossa	scapula
humerus	sternum
iliac crest	suprascapula
ilium	tibia
ischium	tibiale (= astragalus)
manus	tibio-fibula
metacarpals	transverse processes
metatarsals	ulna
omosternum	urostyle
pectoral girdle	vertebrae
pelvic girdle	vertebral column
pelvis	xiphisternum

## SECTION II—EXTERNAL ANATOMY

As with the underlying skeleton, many features of the external anatomy are highly modified in association with the highly specialized saltatory mode of locomotion. The most obvious features are that frogs have very short, wide bodies and very large hind limbs and lack a tail (Figure 6.7). With respect to the shortness of the trunk and relative size of the hind limbs, frogs exhibit the most extreme specializations of any vertebrate. The forelimb, including the **brachium**, **antebrachium**, and **manus**, is typical in form and proportions to that of other tetrapods. In the hind limb, the **femur** and **crus**



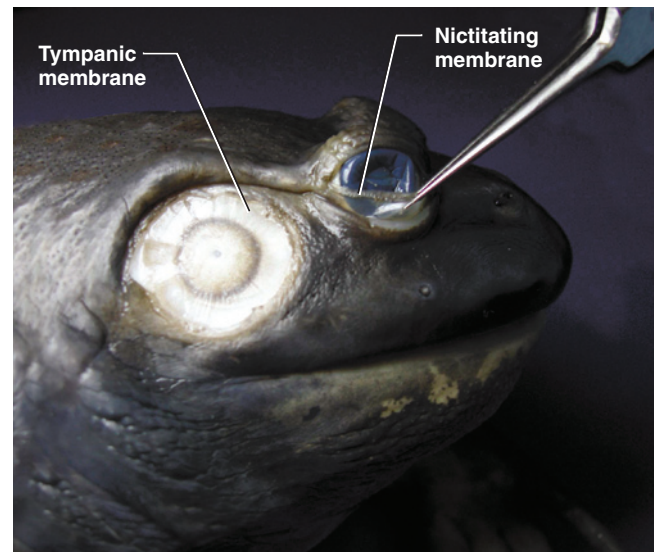
**FIGURE 6.7** External features of the frog.

are also typical, but the **pes** is extremely elongated, a characteristic due to the marked modification of two proximal tarsals (see page 118), which produces an additional functional segment. There are four digits in the manus. The pes has five digits, which are webbed, as in many swimming forms. The thumb hypertrophies in males during the breeding season to help hold the female during amplexus. Claws are absent, as in amphibians generally.


The **skin** is, as in many anurans, thin and highly glandular. These features are associated with the considerable degree of respiration through the skin in most anurans. The mouth is very large, but otherwise normal. The **external nares** are rather small, located anteriorly and close together on the dorsal surface of the snout. The **eyes** are fairly large and project out from the top of the head, but in preserved specimens they are often retracted and covered by the small **eyelids**, which are not independently moveable. A **nictitating membrane** is present (Figure 6.8a).

Posterior to each eye, the conspicuous and circular **tympanic membrane** represents the ear externally (Figure 6.8a). Actually, the membrane itself lies deep to the skin, and may be separated from it. As noted above, the membrane is supported by the annular cartilage (Figure 6.8b). Males are easily distinguished from females by the size of the tympanic membrane. In females it is about the same size as the eye, whereas in males it is much larger than the eye.

The **cloaca** is present posteriorly. However, due to the absence of a tail, it appears to be located somewhat dorsally.



(a) Tympanic membrane and nictitating membrane, right lateral view



(b) Columella with tympanic membrane removed, right lateral view

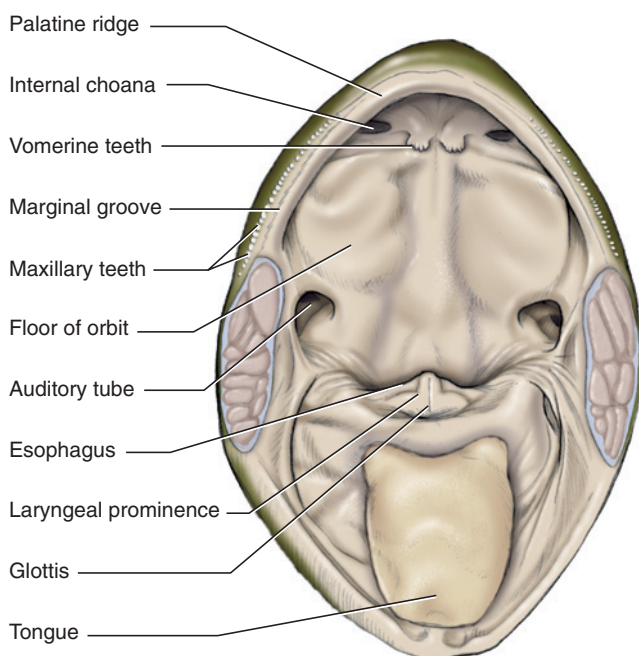
**FIGURE 6.8** Auditory region of the frog in right lateral view.

## KEY TERMS: EXTERNAL ANATOMY

cloaca	nictitating membrane
external nares	pes
eyelids	skin
eyes	tympanic membrane
manus	

## SECTION III—MOUTH, ORAL CAVITY, AND PHARYNX

Open the mouth by cutting through the angle of the jaw on each side, so that you can reveal the **oral cavity** and **pharynx**, as shown in Figure 6.9. Note the large **tongue** on the floor of the oral cavity. The tongue is attached anteriorly and folded back into the oral cavity, so that its distal, bifid end lies posteriorly. The tongue is extended to catch insects by rotating it dorsally around its anterior attachment. A single row of small teeth, often easier to feel than to see, lies around the margin of the upper jaw. As described above, these teeth are mostly **maxillary teeth**. The few **premaxillary teeth** are near the midline. The teeth lie on the lateral side of the **maxillary groove**, which extends around the margin of the upper jaw. The **pterygoid ridge** is medial to the groove. A row of **vomerine teeth** is present on each of the vomers. These teeth lie farther posteriorly near the midline of the roof of the oral cavity.



**FIGURE 6.9** Anterior view of the oral cavity and pharynx of the frog.

A series of openings enter the oral cavity. The **internal choanae** are prominent and lie posterior to the vomerine teeth. The large posterolateral openings are the **auditory tubes**, which lead to the middle ear cavities. The floor of the orbits lies between the internal nares and auditory tubes. Pressure on this area will force the eyeballs up into their open position. Ventrally in the oral cavity, posterior to the tongue, is the slit-like **glottis**, which leads to the **lungs** (see below). It is on a small projection, the **laryngeal prominence**, which is formed by cartilages. Laterally on the floor of the oral cavity, on each side of the anterior end of the glottis, is a small opening in males that lead to a vocal sac. The sacs are used in calling during the mating season, but are difficult to find. The entrance into the **esophagus** is posterior to the glottis. Probe it gently to verify that it does indeed extend posteriorly.

Break the tympanic membrane to expose the middle ear cavity (Figure 6.8b). The **columella** (see above), which has a cartilaginous distal portion, passes through this cavity to the membrane. Probe the cavity to verify that it connects with the oral cavity through the auditory tube.

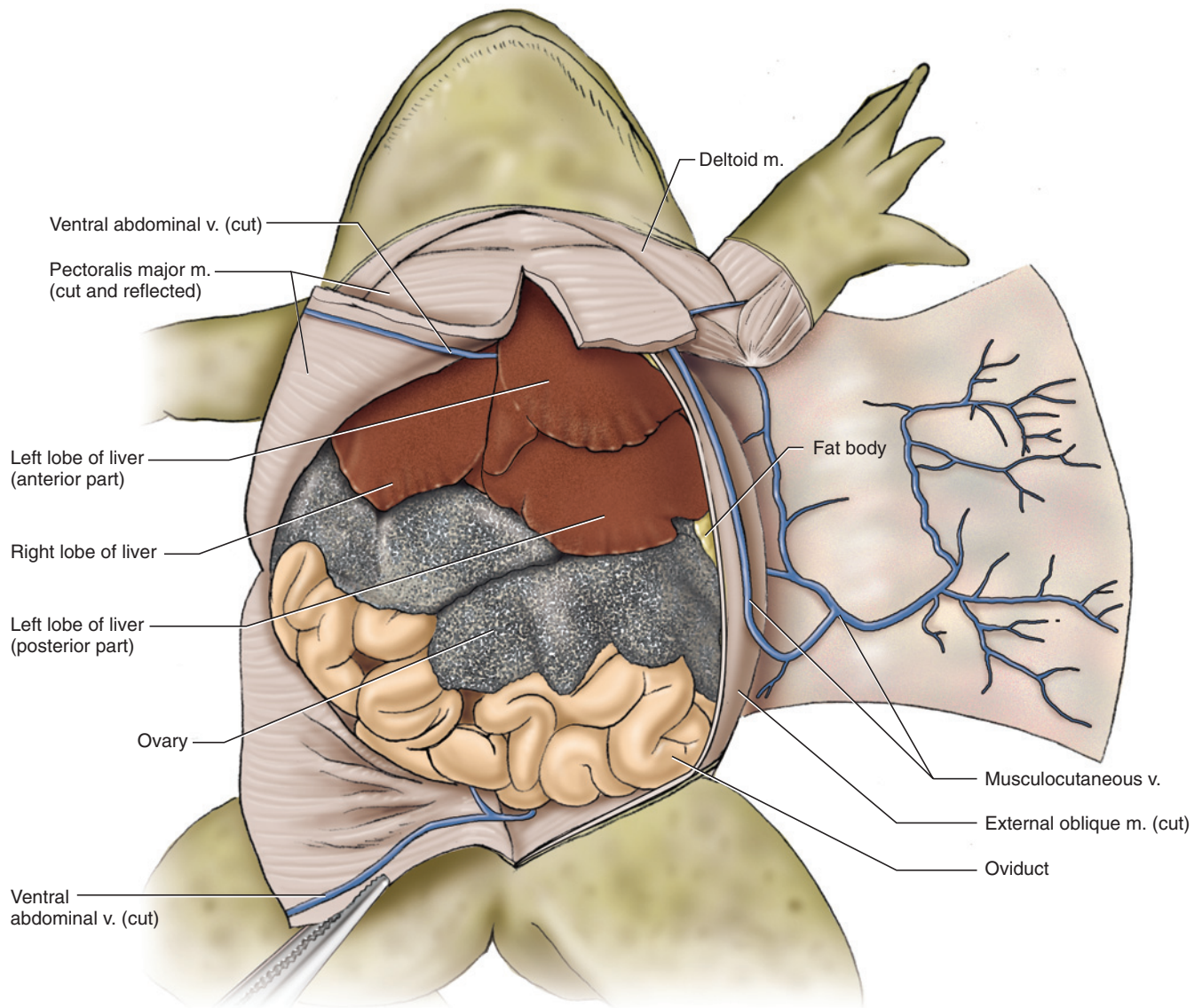
## KEY TERMS: MOUTH, ORAL CAVITY, AND PHARYNX

columella	maxillary groove
esophagus	maxillary teeth
auditory tube (Eustachian tube)	oral cavity
glottis	pharynx
internal choanae	premaxillary teeth
laryngeal prominence	pterygoid ridge
lungs	tongue
	vomerine teeth

## SECTION IV—PLEUROPERITONEAL CAVITY, VISCERA, AND UROGENITAL SYSTEM

Using a scalpel and just to one side of the midventral line, make a small, shallow incision—just large enough to insert a scissor blade—through the skin (and only through the skin), which is very thin. Avoid damaging the underlying musculature. Using scissors, continue the incision anteriorly approximately to the level of the axilla, and posteriorly to approximately midway across the width of the hind limb. From its anterior limit, extend the incision laterally to pass just posterior to the forelimb, and reach nearly to the frog's dorsum. Similarly, from the posterior limit, cut the skin around the margin of the hind limb. Repeat these steps for the skin





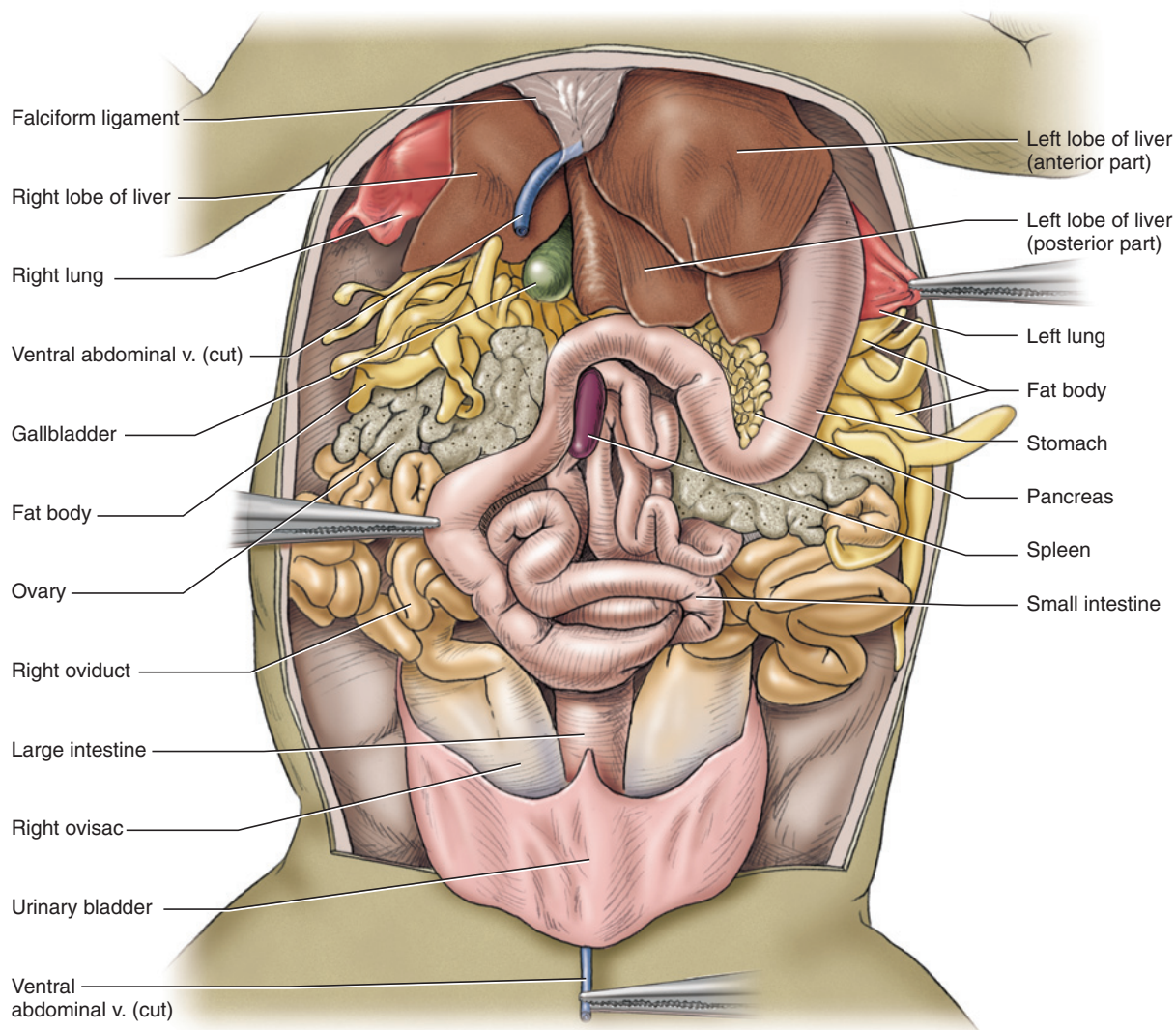
**FIGURE 6.10** Pleuroperitoneal cavity of a female frog in ventral view. The very large ovaries of this individual obscure many of the viscera.

on the other side of the body, finally producing two flaps that can be reflected laterally.

Begin reflecting the skin on one side. It tends to pull away easily but does adhere more strongly in several places. These represent the attachments of lymphatic sacs. Scrape away the connecting tissue, but stay close to the skin in doing so. You will reveal the pectoral and abdominal musculature. Proceed cautiously on the ventrolateral surface, where the **musculocutaneous vein** extends anteroposteriorly. Leave the vein on the musculature; it lies just lateral to the lateral edge of the pectoralis major (Figure 6.10). Anteriorly, it veers medially and passes deep to the pectoralis major. Follow the vein posteriorly as it reflects onto the deep surface of the skin, and note that it is formed by the coalescence of the numerous veins draining the skin.

Examine the abdominal musculature. On the midline, you will note the path of the **ventral abdominal vein**, which actually lies within the abdominal cavity and will be exposed presently. Make two anteroposterior incisions through the musculature. The first will be approximately 0.5 cm to one side of the midventral line, to avoid damaging the ventral abdominal vein. For convenience, make this incision on the same side of the body on which the musculocutaneous vein was exposed. Make the second incision parallel and just medial to that portion of the musculocutaneous vein on the abdominal wall. Then make a transverse cut anteriorly and another posteriorly so that you may remove the rectangular block of musculature. This will expose approximately half of the pleuroperitoneal cavity. For the musculature of the other side, simply cut transversely through the musculature from the middle of the median





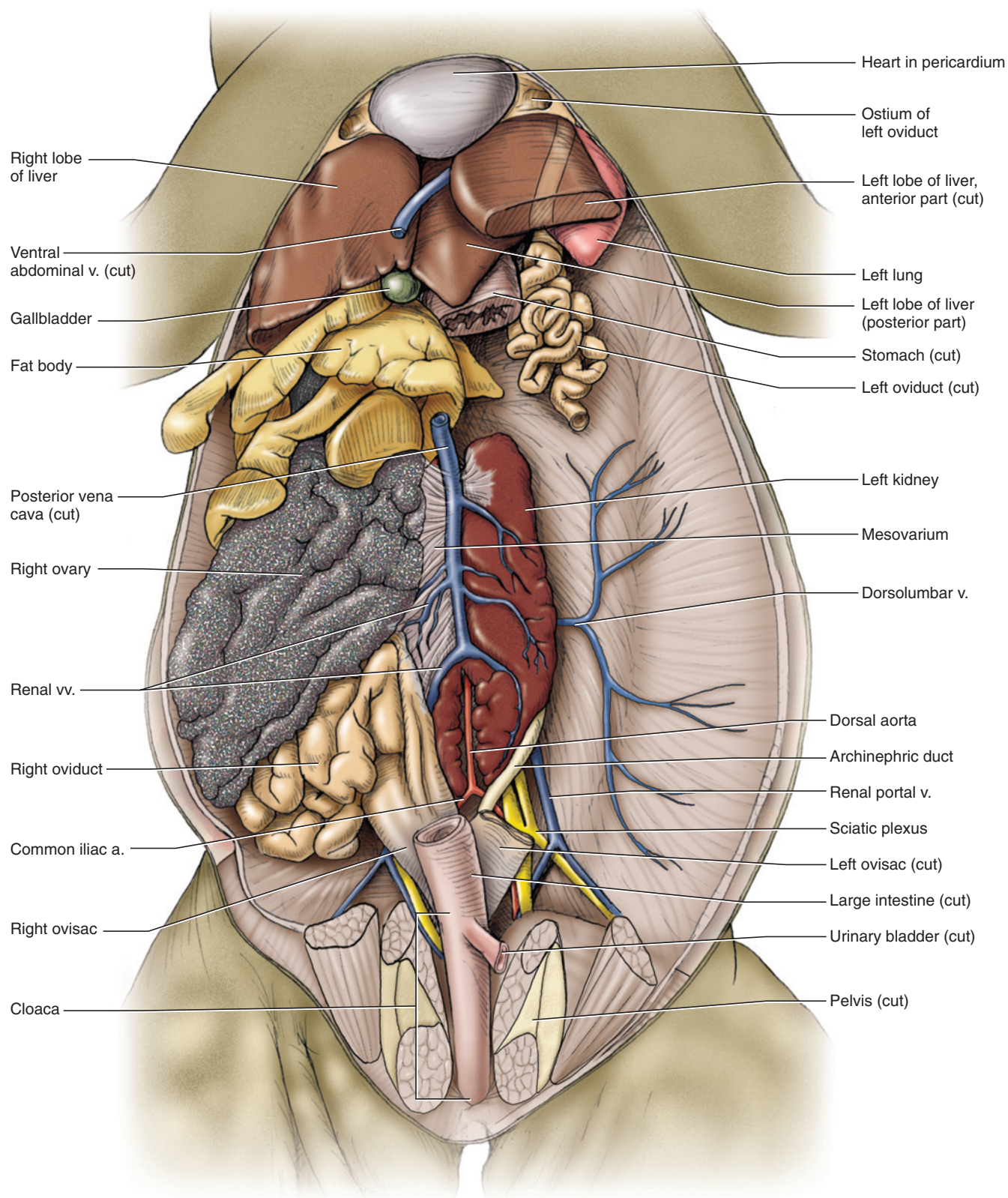
**FIGURE 6.11** Pleuroperitoneal cavity of a female frog in ventral view. The smaller ovaries expose many of the viscera.

anteroposterior incision, and reflect the resulting two flaps.

Follow the ventral abdominal vein as it passes into the cleft between the **right** and **left lateral lobes** of the liver, the large dark mass lying anteriorly in the pleuroperitoneal cavity. The liver is relatively wide and short, conforming to the shape of the body. Its lobes are usually subdivided to varying degrees. The left lobe usually extends further posteriorly due to the development of its posterior lobe, and the right lobe of the liver usually covers a smaller median lobe of the liver. Spread the lateral lobes of the liver to reveal the spherical, sac-like **gall bladder**, which lies just posterior to the passage of the ventral abdominal vein (Figure 6.11). Extending from this vein and the liver to the midventral body wall is the **falciform ligament**. Lift the body wall, and break through the falciform ligament to reveal the **pericardium**, a sac-like structure that contains the heart (see below) nestled

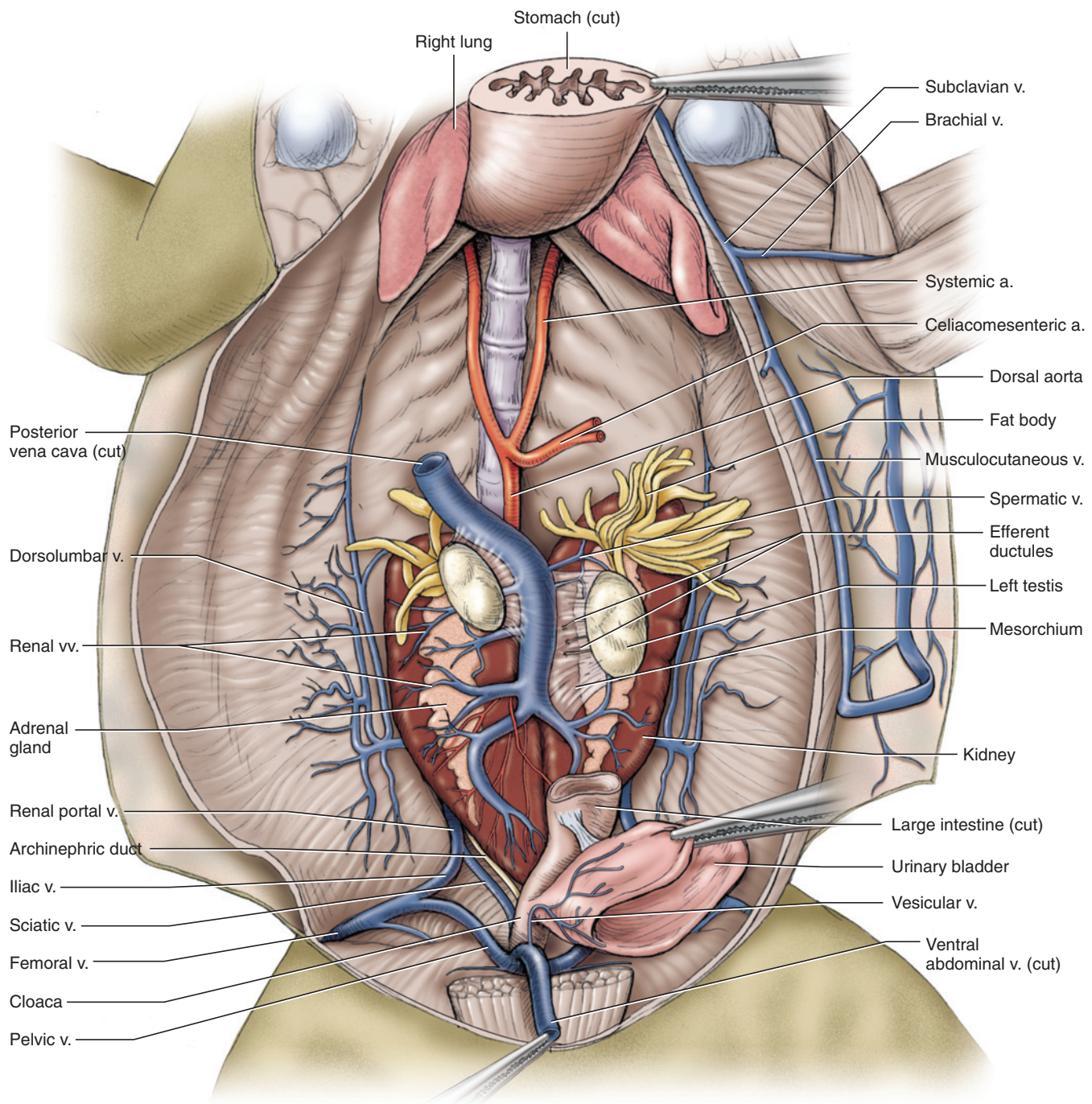
between the anterior ends of the lateral lobes of the liver.

Examine the structures posterior to the liver. In the female the irregularly shaped **ovaries** are generally conspicuous, “speckled” structures containing developing follicles that are usually visible. The ovaries vary in size, depending on stage of the reproductive cycle, and may be massive, occupying a large part of the pleuroperitoneal cavity (compare Figures 6.10–6.12). The small, ovoid **testes** of the male are much less apparent, being confined to their relatively dorsal position, and thus covered by other viscera. They will be described shortly. In both sexes, each gonad is associated with a conspicuous **fat body** (Figures 6.11–6.13), which is subdivided into numerous digitiform lobes that are often pressed up against the sides of the pleuroperitoneal cavity. Stored nutrients in the fat bodies are primarily used to nourish the developing gametes. The size of the fat bodies thus varies greatly with the stage of reproductive



**FIGURE 6.12** Pleuroperitoneal cavity of a female frog in ventral view. Several structures have been removed from the left side to expose the urogenital system.





**FIGURE 6.13** Pleuroperitoneal cavity of the male frog, with many of the viscera removed to expose urogenital system.

cycle. In females, the paired oviducts are large, highly convoluted tubes occupying much of the rest of the ventral part of the pleuroperitoneal cavity. Stretches of the digestive tract (see below) may be exposed among the coils of the oviducts, but these are generally narrower and slightly darker in color. In males large oviducts will not be present, and the coils belong to the digestive tract.

If your specimen is a female with very large or massive ovaries, remove them to provide a better view of the remaining structures, as shown in Figure 6.12. Grasp an ovary, reflect it laterally, and remove it by cutting through its mesentery, the **mesovarium** (Figure 6.12).

Examine the viscera. Find the **stomach**, tucked deep to the lateral side of the left lobe of the liver (Figure 6.11).

It extends posteriorly on the left side of the pleuroperitoneal cavity. Proximally it leads to the short, thick **esophagus**. Lift the proximal end of the stomach to reveal the left **lung**, far anterior in the pleuroperitoneal cavity (Figures 6.11 and 6.13). The right lung may be found dorsal to the right lobe of the liver. The lungs appear as small, contracted sacs in preserved specimens, but they are generally larger in live frogs. Return to the stomach. Distally it narrows and turns abruptly to the right and leads to the **intestine**. The intestine may be subdivided into the narrow, coiled **small intestine** followed by a short, wide **large intestine** that leads to the **cloaca** (Figure 6.12). The **pancreas** lies in the mesentery between the **duodenum**, the first part of the small intestine, and the stomach (Figure 6.11). The **spleen** is a dark, ovoid body lying in the mesentery farther distally and dorsal to the small intestine. Examine the posterior part of the pleuroperitoneal cavity to find the large, thin-walled **urinary bladder**. It empties into the ventral surface of the tube-like cloaca (Figures 6.11 and 6.13).

Examine an oviduct in a female specimen (Figure 6.12). Follow it anteriorly. As it passes anteriorly, it becomes narrower but remains highly coiled, and then, as it passes dorsal to the lung, straightens to reach its opening, the **ostium**, which lies just lateral to the pericardium and faces ventromedially. Ova enter the oviduct through the ostium and then pass posteriorly through the oviduct. At its other end, the oviduct widens and straightens to form the **ovisac**, which may contain masses of eggs. The ovisacs empty into the dorsal surface of the cloaca, just proximal to the level of the entrance of the urinary bladder.

The prominent **kidneys** lie on the dorsal wall of the pleuroperitoneal cavity (Figures 6.12 and 6.13). They are dark, flattened, ovoid structures. The large vessel between them is the **posterior vena cava** (see below). **Adrenal glands** lie along the ventral surface of the kidneys and usually appear as lighter-colored bands. Along the lateral margin of the posterior end of each kidney lies an **archinephric duct**, which leads posteriorly into the dorsal surface of the cloaca, and very near the entrance of the ovisac in the female. The archinephric duct transports only urine in the female, but carries both urine and sperm in the male. The whitish strands that emerge deep to the kidneys are part of the sciatic plexus and give rise to the nerves of the hind limb. To follow the nerves more anteriorly, break through the peritoneum so that a kidney may be lifted from the dorsal body wall.

The ovaries in the female have already been identified. Identify the testes in a male. They lie on the ventral surface of the kidneys, and each is supported by its mesentery, the **mesorchium** (Figure 6.13). The testes are small, smooth, and ovoid structures, their light color in

sharp contrast with that of the kidneys. Sperm pass from the testes through inconspicuous ductuli effentes in the mesorchium, and then enter the kidney to reach the archinephric duct.

### KEY TERMS: PLEUROPERITONEAL CAVITY, VISCERA, AND UROGENITAL SYSTEM

adrenal glands	mesorchium
archinephric duct (Wolffian duct)	mesovarium
cloaca	musculocutaneous vein
duodenum	ostium
esophagus	ovary
falciform ligament	ovisac
fat body	pancreas
gall bladder	pericardium
intestine	posterior vena cava
kidneys	small intestine
large intestine	spleen
liver, right and left lateral lobes	stomach
lung	testis
	urinary bladder
	ventral abdominal vein

## SECTION V—CARDIOVASCULAR SYSTEM

Remove the musculature ventral to the **pericardium** to expose the vessels anterior to the **heart**, as shown in Figure 6.14. Make a longitudinal, midventral slit through the pericardium to open the **pericardial cavity** and expose the heart. Several of the heart's components are plainly visible in ventral view. Its most prominent structure is the single **ventricle**, which lies in the posterior half of the pericardial cavity. Lift the ventricle to see the **sinus venosus** (Figure 6.15). The **right** and **left atria** (sing., **atrium**) are the conspicuous structures anterior to the ventricle (Figure 6.14). Between them, the **bulbus cordis** extends from the ventricle anteriorly and slightly to the left. This anterior part of the heart may be covered by fat and connective tissue. Carefully pick away at and remove it. In an injected specimen the structures are clearly identifiable and easy to expose. In uninjected specimens the vessels are harder to identify and the thin walled atria readily torn, so proceed cautiously.

The bulbus cordis leads into the **truncus arteriosus**, which continues a short distance anteriorly before bifurcating into right and left branches, each of which extends anterolaterally and gives rise to three large



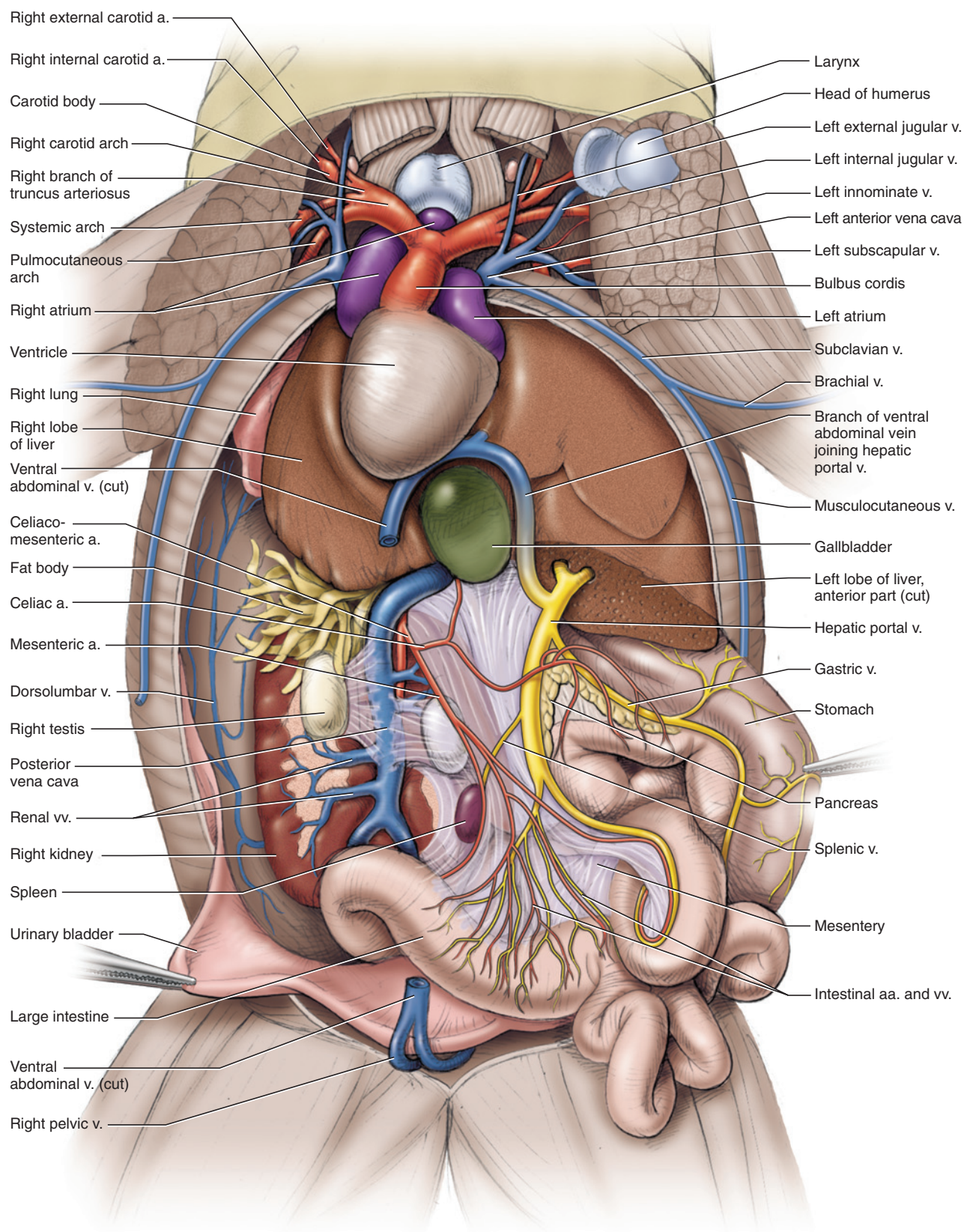
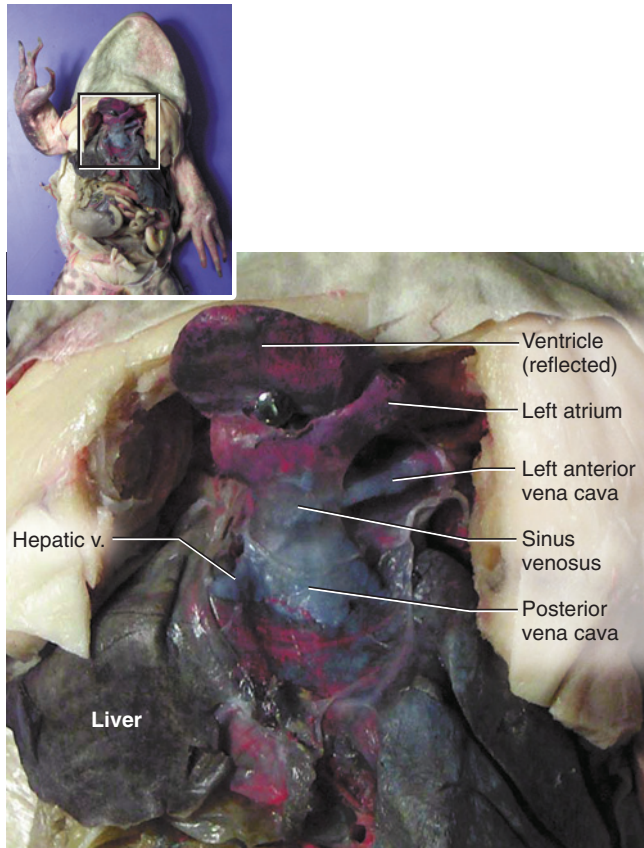


FIGURE 6.14



**FIGURE 6.15** Heart of the frog in ventral view, with the ventricle reflected.

arteries (Figures 6.14 and 6.16). Follow one of the branches, and identify these arteries and their branching patterns. The most anterior branch is the **carotid arch**. It divides into a small branch, the **external carotid artery**, that extends anteriorly to supply the tongue and lower jaw, and a bulbous **carotid body** that continues as the **internal carotid artery** to supply the eye, brain, and upper jaw. The most posterior branch is the **pulmocutaneous arch**. It curves sharply posteriorly, giving off a **cutaneous artery** extending laterally to supply the skin, and then continues to the lung as the **pulmonary artery**. The middle branch is the **systemic arch**. It supplies most of the rest of the body with blood, and so is the largest of the three branches. Initially the systemic arch passes nearly laterally, but it soon arches strongly dorsally. As it passes dorsal to the lung it curves medially and posteriorly, giving off two branches, the **occipitovertebral artery** and the **subclavian artery**, which continues onto the brachium as the **brachial artery** (Figure 6.16). After giving off these two branches, the systemic arch enters the pleuroperitoneal cavity.

Within the cavity each systemic arch passes posteromedially. Just anterior to the level of the kidneys, the right

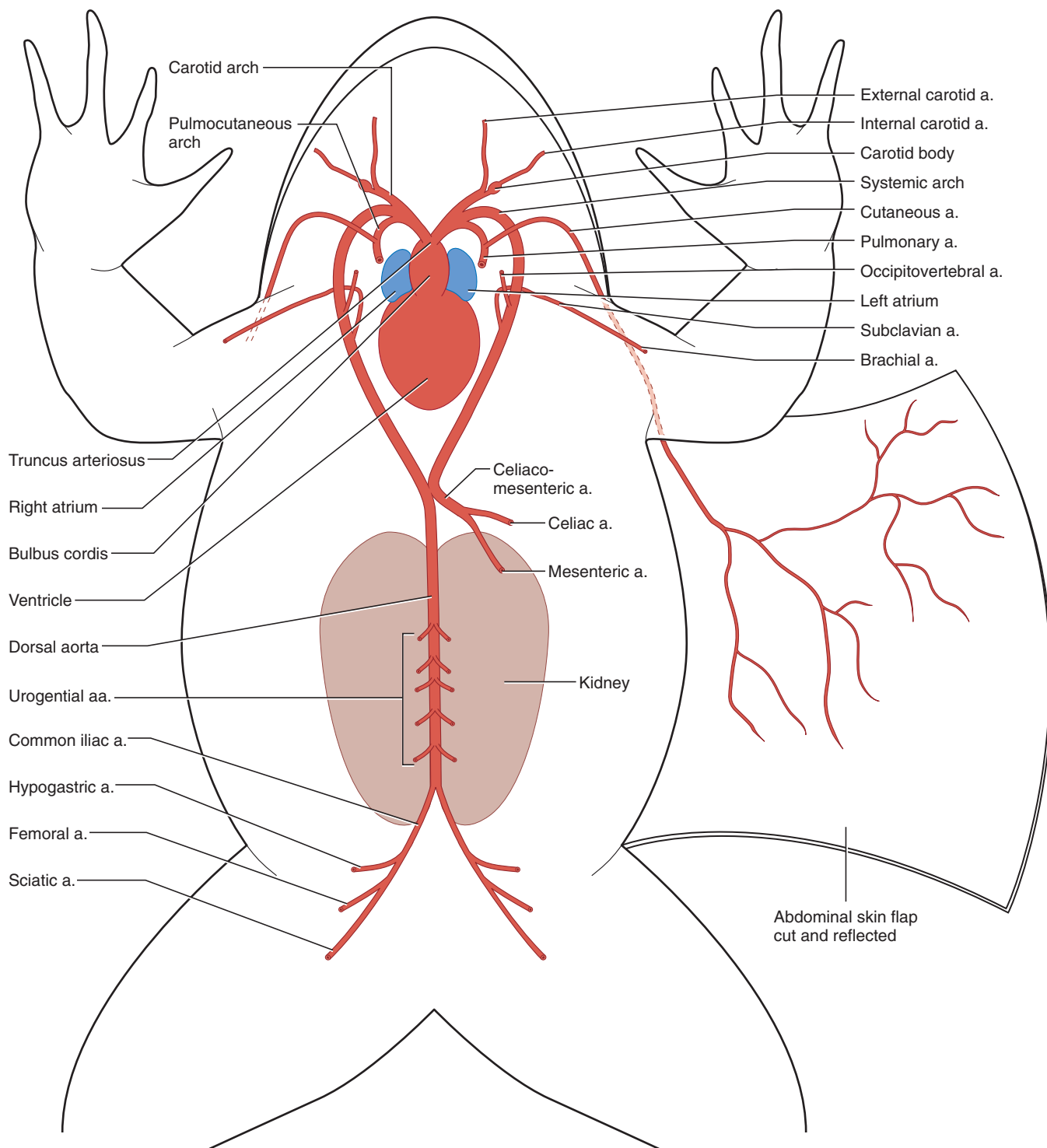
and left systemic arches unite to form the **dorsal aorta**, which continues posteriorly along the middorsal wall of the cavity (Figures 6.13 and 6.16). Immediately after its origin, the dorsal aorta sends off a large branch, the **celiacomesenteric artery**, to the abdominal viscera. This vessel soon bifurcates into the **celiac artery**, which mainly supplies the liver, gall bladder, stomach, and pancreas, and the **mesenteric artery**, which supplies the intestines and spleen.

Between the **kidneys**, several (usually between four and six) smaller, paired vessels, the **urogenital arteries**, extend laterally from the dorsal aorta to supply the kidneys and gonads, as well as fat bodies and urogenital ducts (Figure 6.16). Near the posterior end of the kidneys the dorsal aorta bifurcates into right and left **common iliac arteries** (Figures 6.12 and 6.16). In this region the arteries lie dorsal to the veins, which are also more prominent. Follow one of the common iliac arteries posteriorly. It gives off two smaller branches in quick succession from its lateral surface. These are the **hypogastric artery**, which mainly supplies musculature in this region and the urinary bladder, and the **femoral artery**, which helps supply several muscles and the skin in this region. The common iliac artery then continues into the hind limb as the **sciatic artery** (Figure 6.16). Its many branches supply the leg.

Return to the heart, lift the ventricle, and examine the sinus venosus, which leads into the right atrium (Figure 6.15). Note the large vessels, the **right anterior vena cava** and the **left anterior vena cava**, extending along the lateral edge of the atria and passing into the sinus venosus. The venae cavae collect blood from the head and forelimbs, as well as the skin. Many of the vessels that enter the venae cavae lie dorsal to the arterial vessels and should be injected with blue latex. In a few specimens, however, these will have been infiltrated by the latex of the arteries and will be partly or completely red.

Trace an anterior vena cava. The pattern described here is the general pattern, but there is variation. Indeed, the branching patterns of the right and left venae cavae may vary. The anterior vena cava collects blood from several vessels and empties into the sinus venosus. The main vessels forming the anterior vena cava are the **external jugular**, **innominate**, and **subclavian veins** (Figures 6.14 and 6.17). These three may join together. The external jugular vein extends almost directly anteriorly and drains the tongue and lower jaw. For most of its length it passes nearly parallel and just medial to the external carotid artery. The innominate vein may be quite short or it may extend laterally for a longer distance before receiving its tributaries, the **internal jugular** and **subscapular veins**. The internal jugular, draining the eye, brain, and upper jaw, extends anterolaterally, whereas

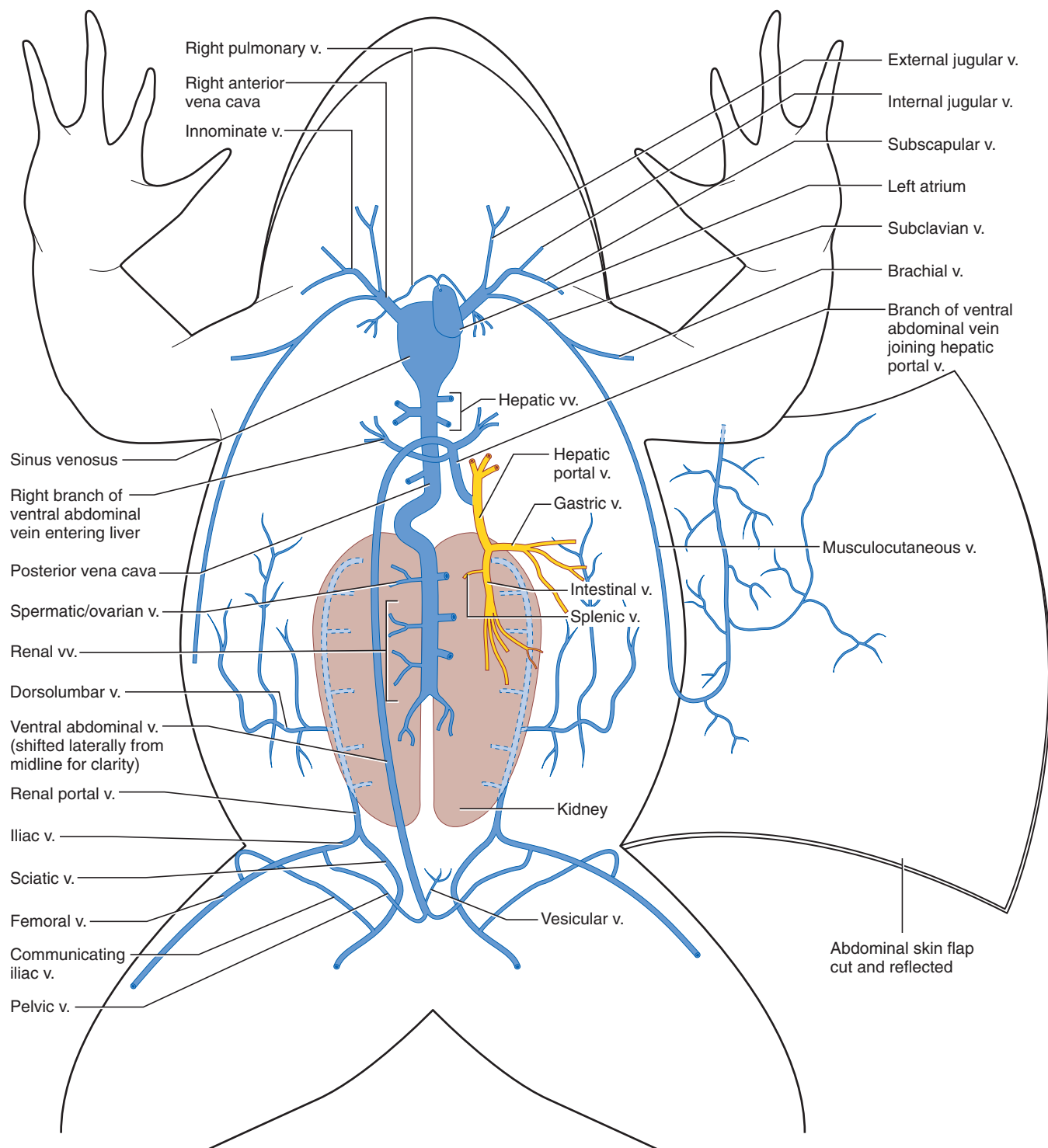




**FIGURE 6.16** Schematic illustration of the arterial system of the frog in ventral view superimposed on the body outline.

the subscapular vein, draining mainly the muscles associated with the pectoral girdle, passes nearly laterally. Finally, the subclavian vein passes posterolaterally, formed by the confluence of the **brachial vein** from the forelimb and the **musculocutaneous vein**, noted earlier, from the pectoral musculature and the deep surface of the skin.

The **pulmonary veins**, returning blood to the heart from the lungs, enter the left atrium (Figure 6.17). The pulmonary vein, one on each side, passes dorsal to the anterior vena cava. Right and left pulmonary veins then unite just anterior to the heart to form a short single vessel that extends posteriorly into the left atrium.



**FIGURE 6.17** Schematic illustration of the venous system of the frog in ventral view superimposed on the body outline. Right atrium, ventricle, and bulbus cordis of heart removed.

Much of the blood posterior to the heart (that from the skin being the main exception) is returned via the large **posterior vena cava**, the large vessel extending between the kidneys (Figures 6.12–6.14). Here it receives several **renal veins** from the kidneys (the fat bodies generally drain into the more anterior renal veins) and **spermatic**

**veins** from the testes or **ovarian veins** from the ovaries. The posterior vena cava extends anteriorly through the liver, receiving from it several **hepatic veins** (Figure 6.17), to reach the posterior end of the sinus venosus. The posterior vena cava also receives blood from much of the hind limbs and dorsal body musculature by way



of the paired **renal portal veins**, which enter the kidneys (Figures 6.12, 6.13, and 6.17). This blood then makes its way through the kidneys to reach the posterior vena cava.

Examine a renal portal vein. It extends mainly along the dorsolateral surface of the kidney. It is formed posteriorly by the union of the **iliac** and **sciatic veins** (Figures 6.13 and 6.17), the latter from the medial side of the thigh. The iliac vein is formed by the **femoral vein**, the large vessel from the lateral side of the thigh, and the **pelvic vein**. A connection between the femoral and sciatic veins, the communicating iliac vein, extends from the femoral, curving dorsally and then medioventrally to meet the sciatic vein (Figure 6.17). The pelvic vein extends ventromedially to join the pelvic vein from the other side of the body. Their union forms the **ventral abdominal vein**, already identified above but which will be described shortly. A small vesicular vein, draining the urinary bladder, enters the ventral abdominal vein just after its origin. The renal portal vein passes anteriorly, sending numerous branches into the kidney. The **dorsolumbar vein**, which drains the dorsal and lateral abdominal walls, consists of numerous branches that collect usually into a single vessel that enters the renal portal vein at about the midlength level of the kidney (Figures 6.12–6.14 and 6.17).

As noted above, the ventral abdominal vein passes anteriorly along the midventral wall of the pleuroperitoneal cavity and extends between the lobes of the liver. It then arches dorsally and then posteriorly. It gives off three branches, two of which enter the right and left lateral lobes of the liver, and the third continuing to join the **hepatic portal vein**, which, as described below, enters the liver (Figures 6.14 and 6.17). Blood from the hind limb may thus return to the heart through the posterior vena cava by several routes. It may pass through the renal portal system or the hepatic veins. In the latter instance it may pass through the branches of the ventral abdominal vein that enter the liver directly or through the hepatic portal vein via that branch of the ventral abdominal vein joining the hepatic portal vein. The hepatic portal vein drains the abdominal viscera. It is formed mainly by the two following vessels: the **gastric vein**, which collects several vessels and drains the

stomach and part of the esophagus, and the **intestinal vein**, formed by vessels that drain most of the small intestine and large intestine (Figures 6.14 and 6.17). The hepatic portal then receives a branch from the ventral abdominal vein before entering the liver.

## KEY TERMS: CARDIOVASCULAR SYSTEM

brachial artery	mesenteric artery
brachial vein	musculocutaneous vein
bulbus cordis	occipitovertebral artery
carotid arch	ovarian veins
carotid body	pelvic vein
celiac artery	pericardial cavity
celiacomesenteric artery	pericardium
common iliac arteries	posterior vena cava
cutaneous artery	pulmocutaneous arch
dorsal aorta	pulmonary artery
dorsolumbar vein	pulmonary veins
external carotid artery	renal portal veins
external jugular vein	renal veins
femoral artery	right anterior vena cava
femoral vein	right atrium
gastric vein	sciatic artery
heart	sciatic vein
hepatic portal vein	sinus venosus
hepatic veins	spermatic veins
hypogastric artery	subclavian artery
iliac vein	subclavian vein
innominate vein	subscapular vein
internal carotid artery	systemic arch
internal jugular vein	truncus arteriosus
intestinal vein	urogenital arteries
kidneys	ventral abdominal vein
left anterior vena cava	ventricle
left atrium	

# CHAPTER 7

## THE CAT

### INTRODUCTION

The domestic cat, *Felis domestica*, belongs to the Mammalia, a synapsid lineage that has its roots in the Triassic Period. Mammals can be readily diagnosed based on living representatives. Among their more distinguishing features are the presence of an insulating covering of hair, a diaphragm that separates the pleural and abdominopelvic cavities, and mammary glands (to which they owe their name). Such soft tissue features, however, fossilize only under exceptional circumstances, and recognition of the most ancient mammals has been based on other features. Paleontologists have traditionally relied mainly on three skeletal features in determining whether a fossil species had achieved the mammalian condition: (1) the presence of three middle ear ossicles (nonmammalian synapsids have one or, rarely, two); (2) a jaw joint between the squamosal bone of the skull and the dentary of the lower jaw (in nonmammalian synapsids, the jaw joint is between the quadrate and articular bones or, in a few cases, all four of these bones participate); and (3) each half of the lower jaw consisting of a single bone, the dentary (in primitive mammals and nonmammalian synapsids, each half includes more than one bone).

Modifications leading to the typical mammalian condition occurred in several advanced cynodont lineages, and the point at which the “mammalian threshold” was crossed has traditionally been defined by possession of a jaw joint between the squamosal and dentary. It is not clear whether all the other features that are usually considered “mammalian” were acquired simultaneously. Evidence from fossils suggests that they were not. Thus, use of the jaw joint criterion to define the Mammalia is arbitrary—any of several other features could equally well be employed. For this reason, paleontologists have moved away from character-based definitions of the Mammalia (or any higher-level taxon) and have come to rely on ancestry as the criterion for defining a group. Mammalia are now usually restricted to the group that includes the living groups of mammals and their common ancestor, as well as all the extinct descendants of this ancestor. It is true that application of the name Mammalia to this particular group is also arbi-

trary, but this system does not rely on characters and promotes a more stable system of grouping organisms.

There are two major subdivisions of living mammals, the Monotremata and the much more diverse Theria or “higher mammals.” The monotremes are restricted to Australia, New Guinea, and Tasmania and include the duckbill platypus and two species of echidnas. Although they have hair and mammary glands, they retain the general amniote reproductive strategy of laying and incubating eggs. They possess several derived characters, however. For example, adult platypuses lack teeth and the rostrum is covered by a leathery bill or beak.

The Theria is subdivided into the Metatheria (marsupials) and the Eutheria (placental mammals). The metatherians were much more widespread and diverse earlier in their history. Living metatherians, while still fairly diverse, are restricted primarily to Australia and South America, with a fairly recent incursion, the opossum, into North America. Metatherians are also known as marsupials or pouched mammals due to the presence of an abdominal marsupium (pouch) or fold in the female. Typically, the young are born in an immature condition and make their way from the vulva to the marsupium, where they latch on to a nipple and complete their development. This is the reproductive strategy of the more familiar marsupials such as the kangaroo, wallaby, and koala. However, not all marsupials follow this strategy. Some, such as the caenolestids or shrew-opossums, lack a pouch, and others (the bandicoot) even have a placenta similar to that of the placental mammals.

The eutherians are the most diverse and widespread of mammals, present on all continents save Antarctica (with modern humans as the exception, of course). They have undergone several major radiations during their history and are currently among the more dominant or conspicuous elements of most terrestrial and aquatic habitats. The degree of habit and structural modifications are truly remarkable. Eutherians include the relatively generalized shrews, the fossorial moles, and the armored armadillos. Several groups of herbivorous types have evolved, including rodents, the most numer-

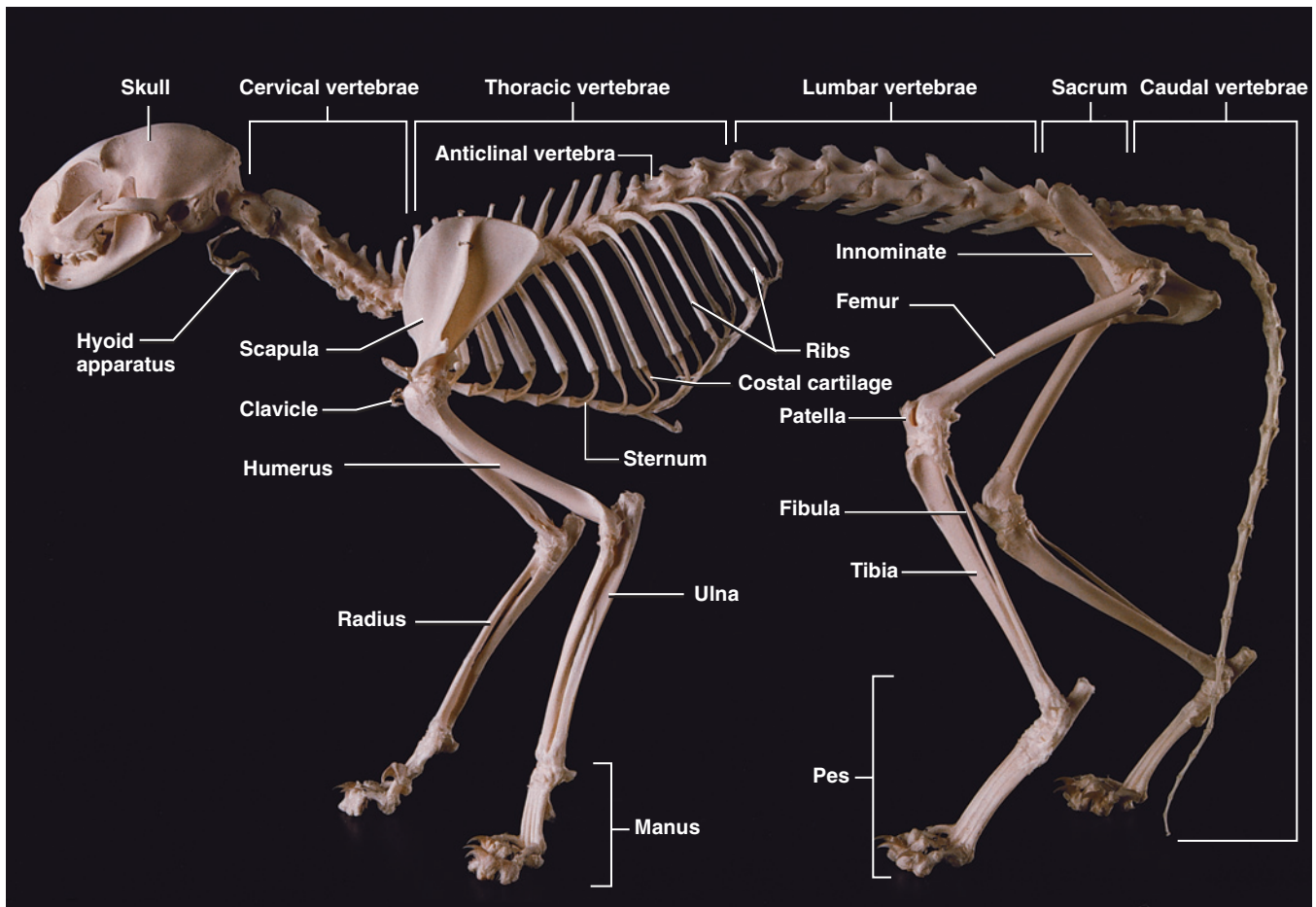


FIGURE 7.1 Skeleton of the cat in left lateral view.

ous of mammals; the bovids, such as the common cattle, as well as bison and sheep; the swift and graceful gazelles; the sleek and powerful equids, such as horses and zebras; and the huge rhinoceroses, hippopotami, and elephants, the largest of living land animals. The chiropterans, or bats, have mastered the skies and are the second most numerous group of mammals, while several groups have invaded the seas. Among the latter are the cetaceans (whales, dolphins, and porpoises) and sirenians (manatees and dugongs), which are completely aquatic, and the pinnipeds (walrus and seals), which live both on land and in the water. The primates, a group that includes humans, are generally arboreal specialists.

Another great group of placental mammals includes the carnivores, to which the cat belongs. Living carnivores include ursids (bears), canids (dogs and their kin), mustelids (weasels and kin), procyonids (raccoons), hyaenids, felids (cats), and viverrids (genets), as well as the pinnipeds mentioned above. The felids include some of the fiercest and largest mammalian predators, such as tigers and lions. The domestic cat is among the smaller members of the group.

## SECTION I—SKELETON

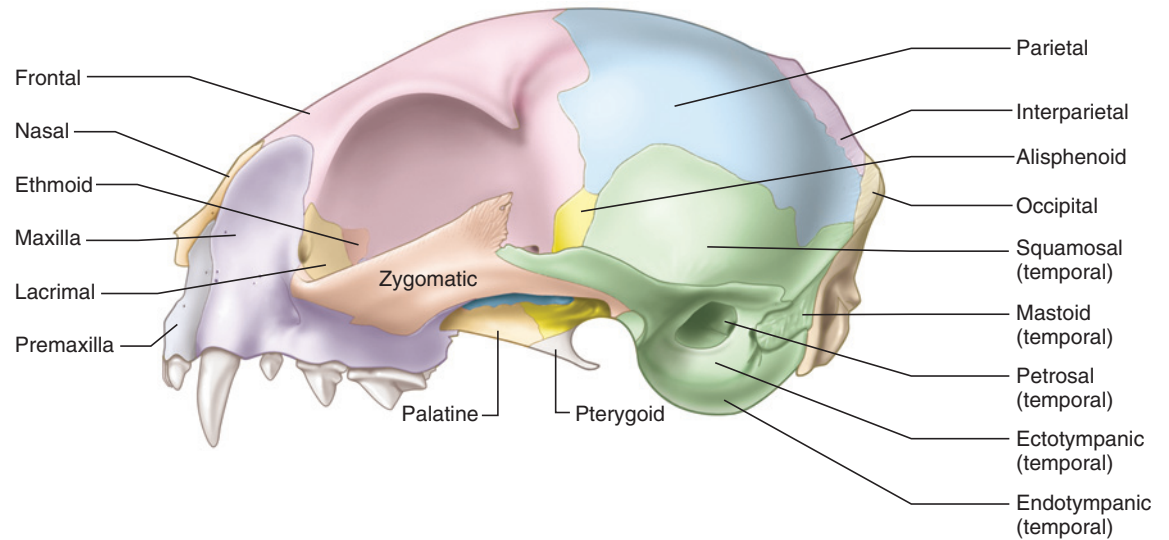
### Cranial Skeleton

#### Skull

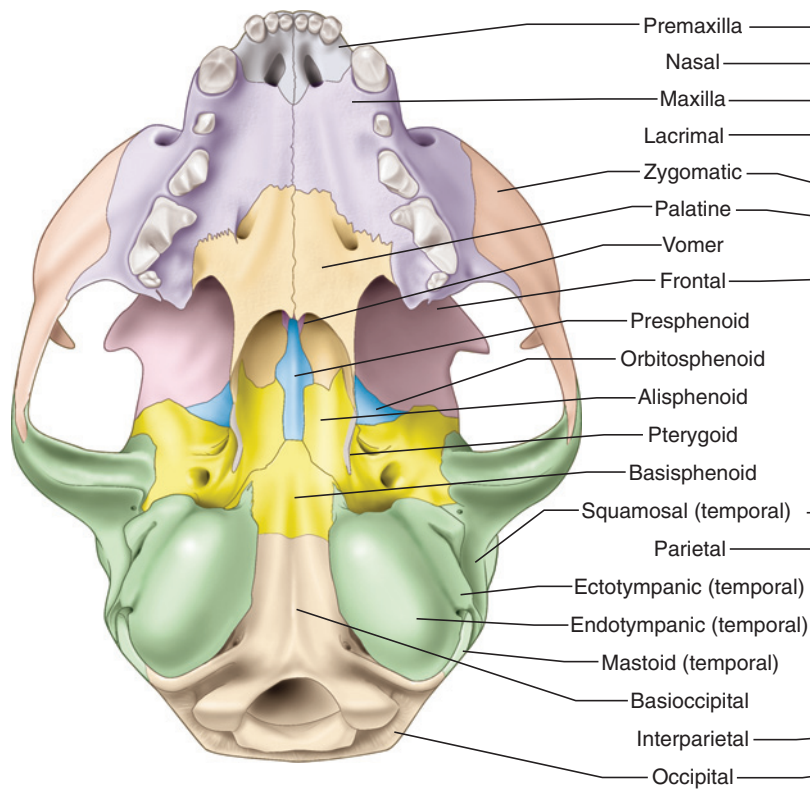
As with other vertebrates, the skull (Figure 7.1) of the cat protects and supports the brain and sense organs and is used in food gathering and processing. It is a single structure formed from various centers of ossification, but may be conveniently divided into a facial or rostral region, including the nose, orbits, and upper jaws, and a cranial region, including the braincase and ear. The lower jaw, while not usually considered part of the skull itself, is included in the following description.

Examine a skull and identify its main features (Figure 7.2a–c). Anteriorly and ventrally, note the marginal series of teeth. Directly above the middle anterior teeth is a large opening, the **nasal aperture**, that leads into the nasal cavity. In life the opening is separated by a cartilaginous septum, so that two **external nares** or nostrils are present. On either side of the skull, dorsal to the posterior teeth, are the large **orbits**, the cavities that

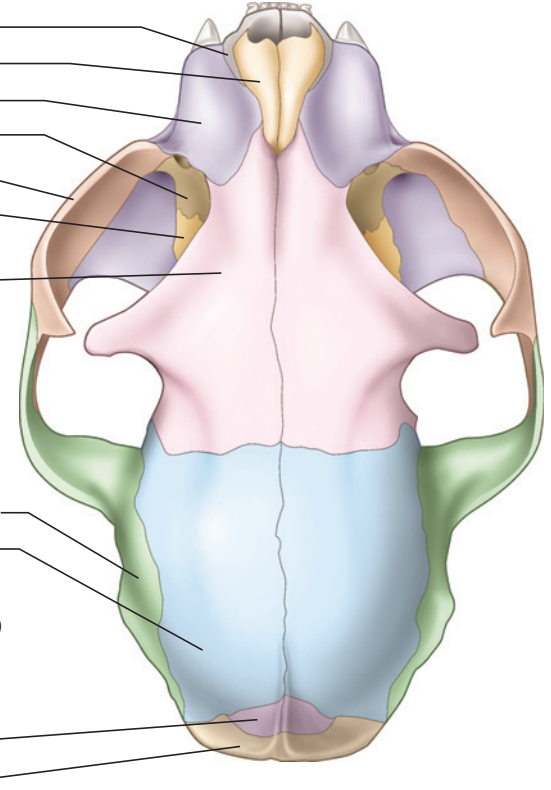
(a) Skull, left lateral view



(b) Skull, ventral view



(c) Skull, dorsal view



**FIGURE 7.2** Skull of the cat in (a) left lateral, (b) ventral, and (c) dorsal views, with bones color-coded.

house the eyeballs. Posterior to each orbit is the expansive cranial wall. This surface is the **temporal fossa**. It protects the brain and serves as the origin for the temporal musculature, which helps to close the jaw. Phylogenetically, the fossa was derived mainly from a depressed region of the skull; thus comes its designation

as a *fossa*, even though in the cat, as in other mammals, it is convex.

The ventral margins of the orbit and fossa are marked by the laterally bowed **zygomatic arch**, which serves mainly for the origin of the masseteric muscular, another



group of jaw-closing muscles. Just posterior to the posterior root of the zygomatic arch is the **external auditory meatus**, the opening and passageway leading to the middle and inner ear. The posterior surface of the skull, the occiput, is pierced ventrally by the large **foramen magnum**, through which the spinal cord passes to the brain.

Examine the skull in ventral view. The flat region between the teeth is the **hard palate**. At its posterior end is the median internal opening of the nasal passage. In life there are two openings, the **choanae**. Further posteriorly lie the paired, oval, and strongly convex **tympanic bullae**. The bulla forms the floor of the middle ear.

Nearly all the bones of the skull are paired. First identify the paired bones along the dorsal midline. Anteriorly, the small, triangular **nasals** form the dorsal margin of the external nares. Posterior to the nasals are the large **frontals**. These extensive bones contribute to the dorsal and lateral surfaces of the skull. Laterally they form most of the orbital walls. Note the **postorbital process** that projects ventrally from each frontal to demarcate the posterior margin of the orbit. Further posteriorly are the **parietals**. These large bones form most of the dorsal and lateral parts of the cranium. The small, **interparietal** bone is wedged between the posterior ends of the parietals. Usually in older individuals the interparietal fuses to the surrounding bones. The **temporal lines** are faint ridges that mark the boundary of muscular attachment on the temporal fossa. These lines curve postero-medially from the postorbital processes of the frontal. They continue posteriorly on the parietals, converging toward the **sagittal crest**, which lies mainly on the interparietal. The crest may be high and sharp or represented only by a rugose ridge.

The **occipital bone** forms the occiput, the skull's posterior surface, and contributes to the **basicranium** (i.e., the base of the cranium). Its most notable features are the **foramen magnum** (Table 7.1 describes the functions of skull foramina) and the **occipital condyles**, which articulate with the first vertebra and support the head on the neck. The occipital is formed from four separate bones. They fuse early in ontogeny, but it is convenient to recognize them separately for the following discussion. The dorsal part of the occipital is the supraoccipital, which forms the dorsal margin of the foramen magnum. The supraoccipital bears the external occipital crest, a median ridge that extends ventrally from the dorsal margin of the occipital. The paired exoccipitals form the lateral parts of the occiput. Each exoccipital carries an occipital condyle and extends laterally to contact the mastoid part of the **temporal** as well as ventrally over the posterior part of the tympanic bulla. The ventral end of the projection forms a blunt **jugular process**. The ventral margin of the foramen magnum is completed by

the **basioccipital**, which also contributes to the **basicranium** as it extends anteriorly between the tympanic bullae.

Return to the front of the skull (see Figures 7.3 and 7.4). The lateral and ventral margins of the nasal aperture are formed by the **premaxillae**. Each is a fairly small bone, with a long, narrow vertical portion and a short ventral portion, into which are implanted the front teeth, or the upper **incisors**. There are three incisors in each premaxilla. Ventrally the premaxillae form the anterior part of the hard palate. Here, each premaxilla has medial and lateral branches separated by the **palatine fissure**.

The **maxillae** are larger bones that hold the rest of the teeth and, in ventral view, form most of the hard palate. The large, curved canine is the first tooth in the maxilla. The following three teeth are **premolars**. Phylogenetically, they represent premolars 2–4 (P2–P4). Cats lost P1 during their evolution and a gap, the **diastema**, is present between the canine and the small, peglike P2. P3 is a larger, triangular tooth that is followed by the very long, bladelike P4. Note the small, final tooth (molar 1 or M1) set transversely and covered in lateral view by the posterior end of P4. The blade-like P4 is the main meat-shearing tooth, and is referred to as the **caninassial** (Figure 7.5). It meets the blade-like m1, the caninassial of the lower jaw.

In lateral view, each maxilla makes a large contribution to the snout or **rostrum**, where it contacts the premaxilla, nasal, and frontal bones. It also contributes a small portion to the orbital margin, where it contacts the small, delicate **lacrimal bone**, which makes a small contribution to the anterior orbital wall. The conspicuous opening of the **lacrimal canal** lies at the anterior margin of the orbit. Finally, the maxilla passes ventral to the **zygomatic bone** and participates in the anterior root of the zygomatic arch. Note that the maxilla contributes a shelf that forms the anterior floor of the orbit. The **infraorbital canal** is the large passage, entirely within the maxilla, at the anterior end of the zygomatic arch.

The **palatine bones** complete the hard palate posteriorly. Ventrally each palatine is a horizontal plate of bone, and the internal opening of the nasal cavity lies posterior to these plates at the midline. The ventral opening of the small **palatine canal** lies very near the suture between palatine and maxilla, approximately medial to the anterior part of P3. Posteriorly each palatine forms a thin, vertical plate of bone. This portion helps to form the **pterygoid blades** or flanges, as well as the ventral part of the orbital wall (Figure 7.3). The region between the pterygoid blades forms the bony part of the tube-like nasopharynx (see page 182). The orbital portion of the

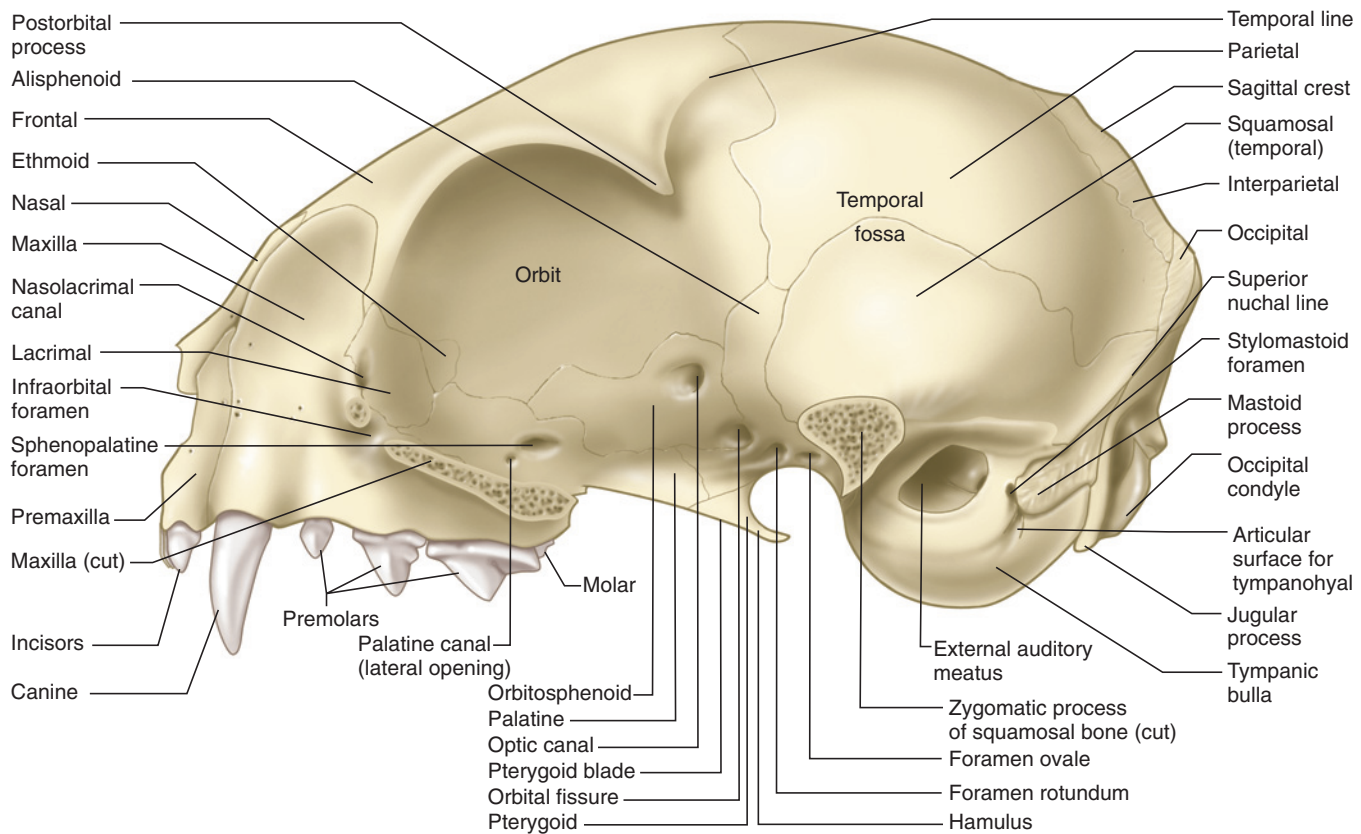
TABLE 7.1

Name	Location	Main Structures Transmitted
Cribriform foramina	cribriform plate of ethmoid	subdivisions of olfactory nerve (CN I)
Optic canal	orbitosphenoid	optic nerve (CN II) and ophthalmic artery
Orbital fissure	between orbitosphenoid and alisphenoid	oculomotor nerve (CN III), trochlear nerve (CN IV), abducens nerve (CN VI), ophthalmic division of trigeminal nerve (CN V <sub>1</sub> ), branch of maxillary division of trigeminal nerve (CN V <sub>2</sub> )
Foramen rotundum	alisphenoid	maxillary division of trigeminal nerve (CN V <sub>2</sub> )
Foramen ovale	alisphenoid	mandibular division of trigeminal nerve (CN V <sub>3</sub> )
Internal acoustic meatus	petrosal	facial (CN VII) and vestibulocochlear (CN VIII)
Jugular foramen	dorsally between petrosal and basioccipital; ventrally between entotympanic (tympanic bulla) and basioccipital	glossopharyngeal nerve (CN IX), vagus nerve (CN X), spinal accessory nerve (CN XI), internal jugular vein; also, hypoglossal nerve (CN XII) after it emerges from the hypoglossal canal
Hypoglossal canal	exoccipital	hypoglossal nerve (CN XII)
Ethmoid foramen	between frontal and orbitosphenoid	branch of ophthalmic division of trigeminal nerve (CN V <sub>1</sub> )
Infraorbital canal	maxilla	infraorbital branch, maxillary division of trigeminal nerve (CN V <sub>2</sub> ), infraorbital artery
Palatine fissure	between premaxilla and maxilla	nasopalatine branch, maxillary division of trigeminal nerve (CN V <sub>2</sub> ), nasal artery
Palatine canal		
lateral opening	palatine (orbital portion)	greater palatine branch, maxillary division of trigeminal nerve (CN V <sub>2</sub> )
ventral opening	palatine (palatine portion), near suture with maxilla	
Foramen magnum	between supraoccipital, basioccipital, and exoccipitals	spinal cord, hypoglossal nerve (CN XII), basilar artery
Stylomastoid foramen	temporal, between mastoid and ectotympanic	facial nerve (CN VII)
Lacrimal canal	lacrimal	lacrimal duct
External auditory meatus	ectotympanic	passageway for outer ear
Sphenopalatine foramen	palatine (orbital portion)	sphenopalatine branch, maxillary division of trigeminal nerve (CN V <sub>2</sub> ), sphenopalatine artery
Oval window	petrosal	receives foot plate of stapes
Round window	petrosal	covered in life by secondary tympanic membrane, which accommodates vibrations of fluid in inner ear
Auditory tube, opening	between tympanic bulla (endotympanic) and basisphenoid	auditory tube emerges from inner ear, from which it passes to nasopharynx
Condylod canal	exoccipital	vein
Mental foramina (anterior openings of mandibular canal)	anteriorly on lateral surface of dentary	dentary branch of mandibular division of trigeminal nerve (CN V <sub>3</sub> ); blood vessels
Mandibular foramen (posterior opening of mandibular canal)	posteriorly on medial surface of dentary	dentary branch of mandibular division of trigeminal nerve (CN V <sub>3</sub> ); blood vessels

palatine (Figure 7.3) has two openings. The larger is the **sphenopalatine foramen**; the smaller is the lateral opening of the palatine canal.

In ventral view, locate the posterior end of the palatine bones (Figure 7.4). They contact a complex, composite element, usually termed the **sphenoid**, consisting of various ossifications. The main part, or body, is the **basisphenoid**. The pterygoid processes of the basisphenoid are the portions that contact the palatine and form the posterior end of the pterygoid blades. The narrow, hook-like posterior projection at the end of each pterygoid blade is the **hamulus**, to which a palatal muscle is attached. The main part of the basisphenoid contributes

to the basicranium. It lies ventrally between the anterior parts of the tympanic bullae. The lateral, wing-like portion of the sphenoid is the **alisphenoid**. It is exposed on the lateral surface of the skull, and will be discussed shortly. Return to the ventral surface and locate the **presphenoid**, the elongated, narrow, median bone lying between the pterygoid blades. The presphenoid also has lateral extensions, the **orbitosphenoids**, that are exposed in the ventral orbital walls. The connection between the presphenoid and orbitosphenoid is concealed by the palatine. The orbitosphenoid contacts the palatine, frontal, and alisphenoid bones. A tiny **ethmoid foramen** (see Table 7.1) lies along the suture between the orbitosphenoid and frontal, but it may be difficult to see.



**FIGURE 7.3** Skull of the cat in left lateral view, with zygomatic arch removed.

A series of four openings into the cranial cavity lies just dorsal to the pterygoid blades, on the lateral surface of the skull (Figure 7.4). Locate these foramina. The two anterior foramina are approximately twice as large as the two posterior foramina. The most anterior foramen is the **optic canal**, and it lies entirely within the orbitosphenoid. The second is the **orbital fissure**. Its margin is formed by the orbitosphenoid and the alisphenoid. The third and fourth foramina, respectively, the **foramen rotundum** and **foramen ovale**, lie entirely within the alisphenoid.

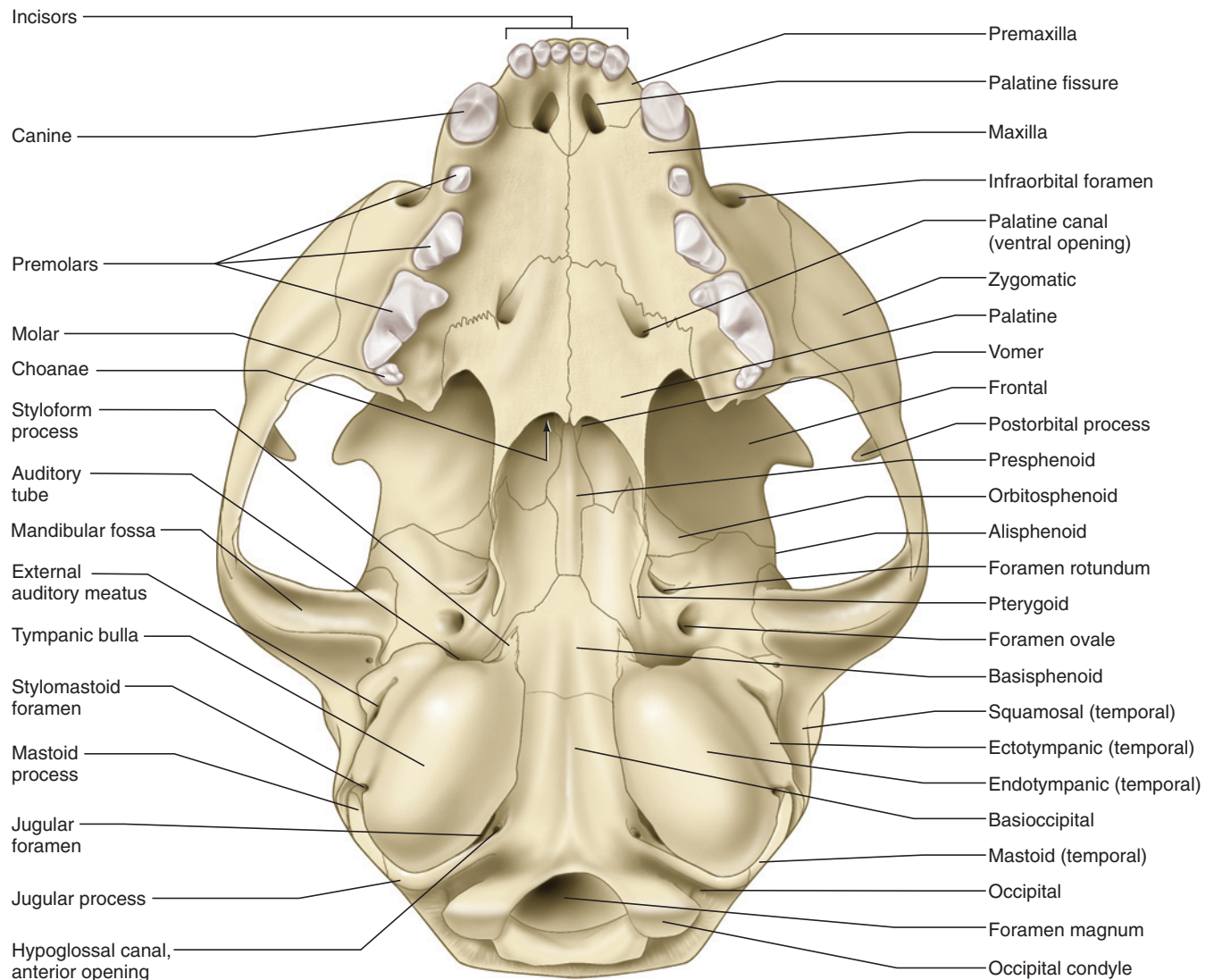
Peer into the internal opening of the nasal cavity. Extending anteriorly from the presphenoid is the **vomer**. Its ventral surface is keeled. The vomer passes anteriorly and contacts the premaxillae and the maxillae. Examine the nasal aperture to view the vomer in anterior view, and note its narrow trough-like form. The vomer contributes to the bony nasal septum, which helps partition the nasal cavity into left and right parts.

The nasal cavity is filled with delicate, scroll-like **turbinate bones** (Figure 7.5). Most of these scrolls are formed from the maxilloturbinate, a paired bone that is connected to the medial wall of each maxilla. The turbinates dorsally in the nasal cavity are formed from the ethmoturbinates, which form the bulk of the

**ethmoid bone**. In some cats a tiny portion of the ethmoid is exposed on the orbital wall, just posterior to the lacrimal. Other parts of the ethmoid are the **mesethmoid** and the **cribriform plate**. The mesethmoid is a median bony plate that, together with the vomer, helps form the bony nasal septum. The cribriform plate is a transverse plate, pierced by many small foramina, that forms the anteroventral wall of the cranial cavity. The cribriform plate can be viewed in a sagittally sectioned skull (Figure 7.5) or one in which the skull roof has been removed.

The **temporal bone** consists of three components that are fused together: the squamous, petrous, and tympanic portions. The **squamosals** are the large, flat bones ventral to the parietals that help complete the lateral wall of the braincase (Figure 7.3). Ventrally the squamosal sends out a projection, the zygomatic process, that extends laterally and then anteriorly to form the posterior part of the zygomatic arch. On the ventral surface of the lateral part of the zygomatic process is the **mandibular fossa** (Figure 7.4), a smooth, transverse groove that articulates with the lower jaw in forming the temporomandibular joint.

The petrous portion of the temporal includes the **petrosal** and **mastoid bones**. The petrosal contains the inner



**FIGURE 7.4** Skull of the cat in ventral view.

ear and may be seen through the external auditory meatus; its medial part should be viewed in a sagittally sectioned skull (Figure 7.5). The tiny bones or ossicles of the middle ear are the **malleus**, **incus**, and **stapes**. The middle ear is essentially between the external auditory meatus and the petrosal and is covered ventrally by the tympanic bulla. The middle ear bones sometimes remain in place. The malleus is the slender, elongated bone lying across the inner end of the external auditory meatus. The other two are more difficult to distinguish, but the stapes lies medially and fits into the **oval window** of the petrosal.

When the middle ear bones are absent, the two lateral foramina of the petrosal can be identified by peering into the external auditory meatus. Move the skull so that you have an anterolateral view into the middle ear. The foramina lie posteriorly on the petrosal. The more ventral one is the **round window** and opens posteriorly.

The oval window, mentioned above, lies dorsal to the round window and opens laterally.

The mastoid bone is the only part of the petrous portion that is exposed externally. It overlaps the posterolateral surface of the tympanic bulla. Its ventral portion forms the **mastoid process**. (It is tiny in the cat, but you can feel it protruding just behind your ear.) The small **stylomastoid foramen** opens just anterior to the mastoid process (Figures 7.3 and 7.4). The mastoid bone continues dorsally on the occiput as a short wedge between the squamosal and occipital bones. The hyoid apparatus articulates with the tympanic bulla just ventral to the mastoid process (Figure 7.3).

The tympanic portion of the temporal includes the rounded, oval tympanic bulla, which is formed from two ossifications. The **ectotympanic** mainly forms the ring of bone surrounding the external auditory



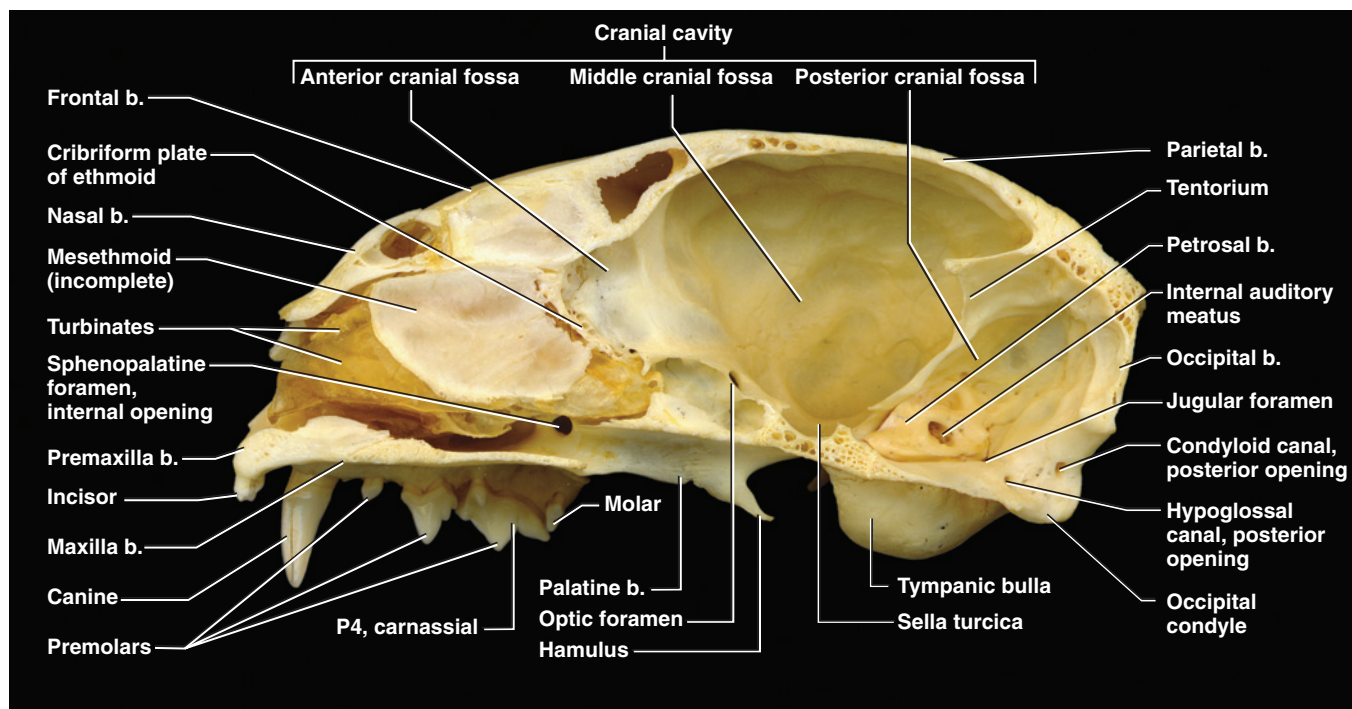


FIGURE 7.5 Right side of the skull of the cat shown in sagittal section.

meatus, but contributes to the bulla ventrolaterally. The rest of the bulla is formed by the **endotympanic**. Anteromedially the bulla sends a pointed wedge, the **styloform process**, onto the base of the skull. Lateral to the process is the large opening for the **auditory tube** (Figure 7.4).

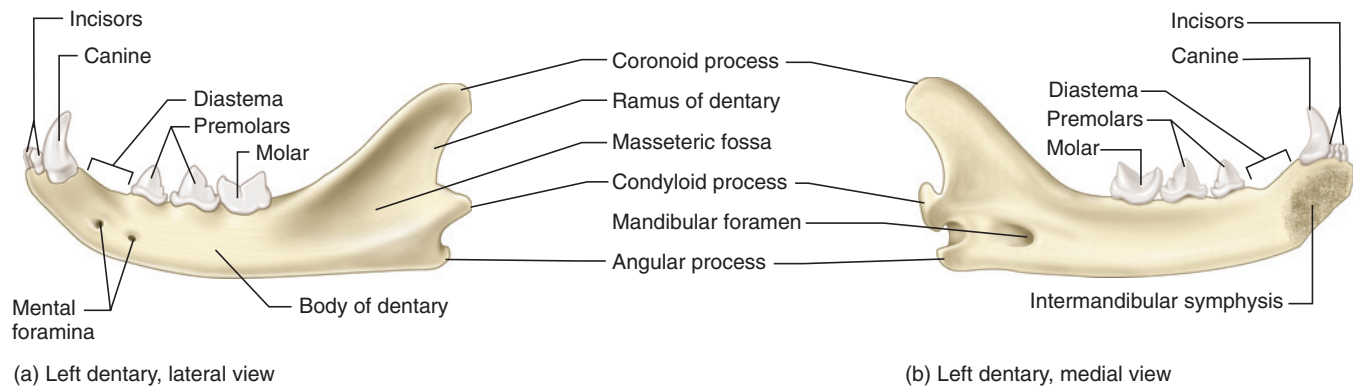
Note the large **jugular foramen** in the base of the skull at the posteromedial margin of the tympanic bulla. It passes between the bulla, the basioccipital (medially), and the exoccipital (posteriorly). A second, much smaller opening lies on the posterior wall (i.e., the exoccipital) of the larger passage. This is the anterior opening of the **hypoglossal canal**. Identify the posterior opening by examining the medial wall of an occipital condyle (i.e., look into the foramen magnum) or a sagittal section (Figure 7.5). Pass a bristle through the hypoglossal canal to determine its course. Posterior and dorsal to the posterior opening of the hypoglossal canal is the posterior opening of the **condylar canal**.

The **zygomatic bone**, contacting the maxilla anteriorly and the zygomatic process of the squamosal posteriorly, forms most of the zygomatic arch. It forms the ventral margin of the orbit, and it sends up a postorbital process that closely approaches the postorbital process of the frontal. Ventrally and laterally the zygomatic bears a crescentic, slightly concave region for origin of masseteric musculature.

Examine a sagittal section of the skull (Figure 7.5). The posterior half of the skull contains the large **cranial cavity** for the brain. The cavity is subdivided into a small **anterior cranial fossa** that receives the olfactory bulbs of the brain (see Figure 7.40), a **middle cranial fossa**, the largest subdivision, which mainly houses the cerebrum, and a **posterior cranial fossa**. The last two fossae are separated by a partial bony septum, the **tentorium**. A depression, the **sella turcica** (shaped like a traditional Turkish saddle in humans, but not in the cat), of the basisphenoid bone on the floor of the middle cranial fossa houses the hypophysis (see Figure 7.40). Note the petrosal, which houses the inner ear. The large opening is the **internal acoustic meatus** for passage of the facial (CN VII) and vestibulocochlear (CN VIII) nerves (see Section VII).

### Mandible

The **mandible** or lower jaw is formed on each side by a single bone, the **dentary** (Figure 7.6). Left and right dentaries articulate anteriorly at the **mandibular symphysis**. The horizontal part of the dentary, in which the teeth are implanted, is the **body**. Note the presence, normally, of three incisors, followed by a canine, which is separated from the three cheek teeth by a diastema. The cheek teeth include p3, p4, and the elongated, blade-like m1. The m1 is the carnassial of the lower jaw; hence the carnassial pair is P4/m1. Typically, two **mental foramina** (see below and Table 7.1 for function) are



**FIGURE 7.6** Dentary of the cat in (a) lateral and (b) medial views.

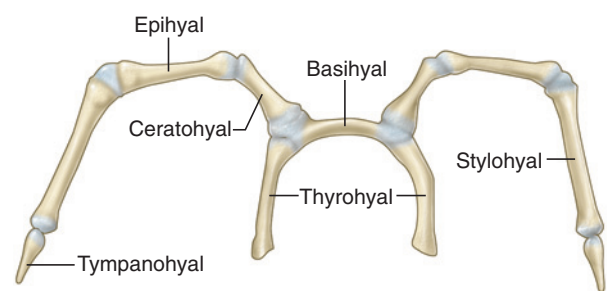
present anteriorly on the lateral surface of the body (Figure 7.6a).

The part posterior to the body is the **ascending ramus**, which has three processes. The **coronoid process** is the largest, extending dorsally. The temporal muscle inserts mainly on its dorsolateral and medial surfaces. The **masseteric fossa**, the large, triangular depression on the lateral surface of the coronoid process, serves as part of the insertion area for the masseteric musculature. The transversely expanded **condyloid process**, forming the lower half of the temporomandibular joint, bears a semicylindrical facet for articulation with the mandibular fossa on the temporal bone. Manipulate the mandible on the skull, and note how the form of the joint permits mainly up and down (or orthal) movements of the jaw and restricts lateral motion. Identify the roughened area on the anteromedial surface of the condyloid process. It is the insertion site for the medial pterygoid muscle. The **angular process** is the projection of the posteroventral part of the dentary. Its medial surface serves as the insertion site for the lateral pterygoid muscle and its lateral surface for part of the masseteric musculature.

A large **mandibular foramen** lies anterior and slightly dorsal to the angular process and the medial surface of the ramus (Figure 7.6b). This foramen is the posterior opening of the mandibular canal, which extends anteriorly through the body for the passage of the blood vessels and the mandibular division of the trigeminal nerve. The mental foramina are the main anterior openings of the canal.

### Hyoid Apparatus

The hyoid apparatus (Figures 7.1 and 7.7) is composed of several small bones, the phylogenetic remnants of some of the gill arches in fishes. It sits in the throat at the base of the tongue and supports the tongue and laryngeal muscles. It is composed of a median bar, the



**FIGURE 7.7** Hyoid apparatus of the cat.

**basihyoid** or body, which is oriented transversely at the anterior end of the larynx. There are two pairs of horns or cornua that extend from the basihyal. The **lesser cornua** are the longer, anterior pair, whereas the **greater cornua** are the smaller, posterior pair. Each lesser cornu consists of a chain of four ossicles that curves anteriorly and dorsally to attach to the skull. These elements are the **ceratohyoid**, **epihyoid**, **stylohyoid**, and **tympanohyoid**, which has a ligamentous attachment to the temporal bone of the skull. The greater cornu is formed on each side by the **thyrohyoid**, which articulates with thyroid cartilage of the larynx. The discrepancy between the size and names of the cornua derives from their condition in humans, in which the greater cornua are indeed larger, as the lesser horn is represented only by the ceratohyoid.

### KEY TERMS: CRANIAL SKELETON

alisphenoid  
angular process  
anterior cranial fossa  
ascending ramus of dentary  
auditory tube (Eustachian tube)

basicranium  
basioccipital  
basihyoid  
basisphenoid  
body, of dentary  
carnassial

ceratohyoid  
 choanae  
 condyloid canal  
 condyloid process  
 coronoid process  
 cranial cavity  
 cribriform plate  
 dentary  
 diastema  
 ectotympanic  
 endotympanic  
 epihyoid  
 ethmoid bone  
 ethmoid foramen  
 external auditory meatus  
 external nares  
 foramen magnum  
 foramen ovale  
 foramen rotundum  
 frontal  
 greater cornua  
 hamulus  
 hard palate  
 hypoglossal canal  
 incisors  
 incus  
 infraorbital canal  
 (antorbital canal)  
 internal acoustic meatus  
 interparietal  
 jugular foramen  
 jugular process  
 lacrimal bone  
 lacrimal canal  
 lesser cornua  
 malleus  
 mandible  
 mandibular foramen  
 mandibular fossa  
 mandibular symphysis  
 masseteric fossa  
 mastoid bone

mastoid process  
 maxilla (pl., maxillae)  
 mental foramina  
 mesethmoid  
 middle cranial fossa  
 nasal  
 nasal aperture  
 occipital bone  
 occipital condyles  
 optic canal  
 orbital fissure  
 orbitosphenoid  
 orbits  
 oval window (vestibular window; fenestra vestibuli)  
 palatine bone  
 palatine canal  
 palatine fissure  
 parietals  
 petrosal (periotic)  
 posterior cranial fossa  
 postorbital process  
 premaxillae  
 premolars  
 presphenoid  
 pterygoid blades  
 rostrum  
 round window (fenestra cochlea)  
 sagittal crest  
 sella turcica  
 sphenoid  
 sphenopalatine foramen  
 squamosal  
 stapes  
 styloform process  
 stylohyoid  
 stylomastoid foramen  
 temporal bone  
 temporal fossa  
 temporal lines  
 tentorium

thyrohyoid  
 turbinate bones  
 tympanic bullae  
 tympanohyoid

vomer  
 zygomatic arch  
 zygomatic bone (malar, jugal)

## Postcranial Skeleton

### Vertebral Column

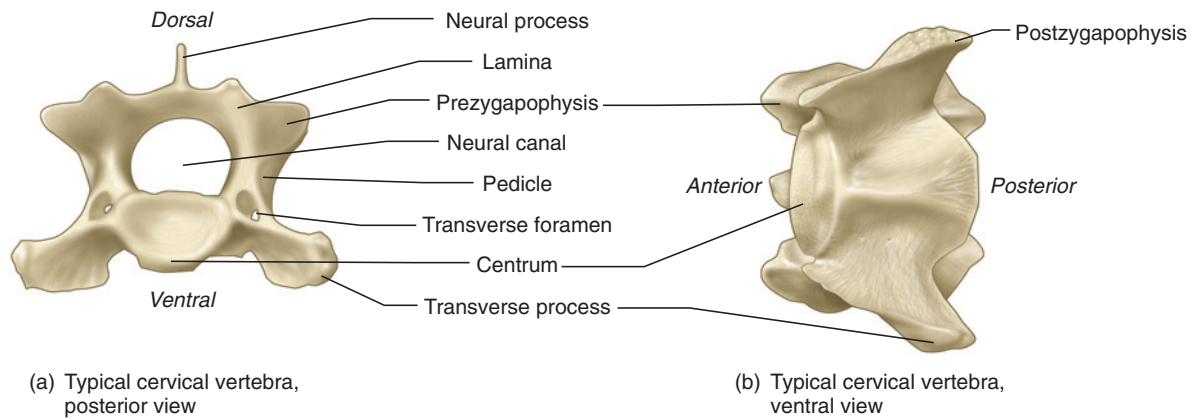
The **vertebral column** is composed of a series of movable bones, or **vertebrae**. The column is an important structure in support and locomotion and has evolved in mammals into five distinct regions. Examine a mounted skeleton to identify these regions (Figure 7.1). Most anteriorly, in the neck, are the **cervical vertebrae**, which are followed by the rib-bearing **thoracic vertebrae** in the trunk. Next are the **lumbar vertebrae**, lying dorsal to the abdomen and between the thoracics and **sacral vertebrae**. The latter are fused into a solid unit and articulate with the pelvis. Lastly, the **caudal vertebrae** support the tail. An opening, the **intervertebral foramen**, is present on each side between adjacent vertebrae for the passage of a spinal nerve.

Each vertebra generally possesses several parts. For the following, examine a typical cervical vertebra (Figure 7.8). The **centra** (sing., **centrum**) or vertebral bodies, oval or kidney-shaped in section, form the main support of the vertebral column. The **neural canal**, through which the spinal cord passes, lies dorsal to the centrum. The neural canal is enclosed laterally and dorsally by the **neural arch**. The arch is composed on each side by a **pedicle**, an oblique plate forming the side of the arch, and a **lamina**, a horizontal plate forming the top of the arch. A **neural process** projects dorsally from the neural arch. A **transverse process** projects laterally on either side from near the junction of the centrum with a pedicle. Near the junction between the pedicle and lamina, each vertebra has anterior and posterior projections for articulation with other vertebrae. The anterior projection, the **prezygapophysis**, bears a facet that faces dorsally or dorsomedially. The facet of the posterior process or the **postzygapophysis** faces ventrally or ventromedially. Thus, a prezygapophysis slips under the postzygapophysis of the preceding vertebrae.

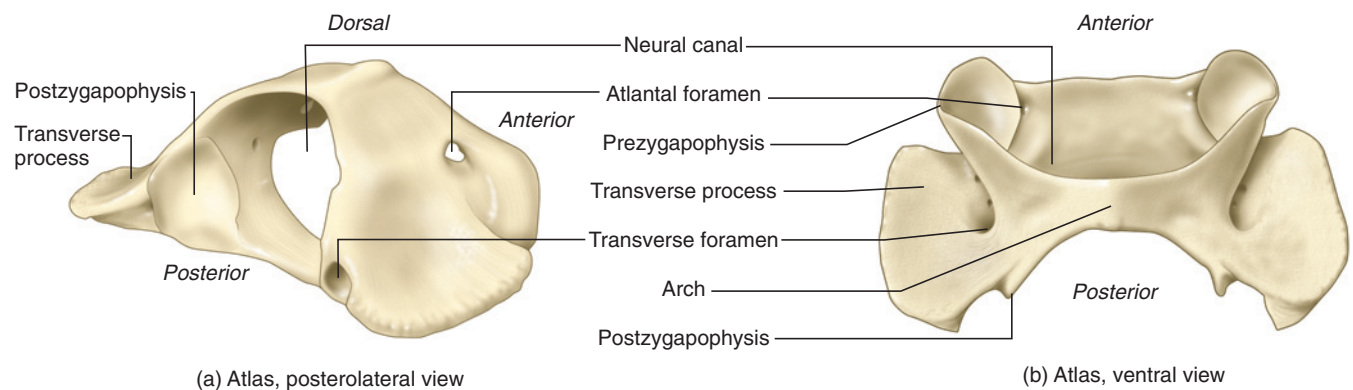
These features are common to most vertebrae, though they may vary in size and proportion among vertebral types. Some vertebrae may also have additional processes. Examine a set of disarticulated vertebrae and distinguish the main types, as described below.

### Cervical Vertebrae

The cat has seven cervical vertebrae, as do most mammals. The first two are specialized and markedly different from the remaining five, due to their function in support and movement of the head. The first vertebra is



**FIGURE 7.8** Cervical vertebra of the cat.



**FIGURE 7.9** Atlas of the cat in posterolateral and ventral views.

the **atlas** (Figure 7.9), after the mythological giant Atlas, who was charged with supporting the world on his shoulders. The atlas is easily recognizable. It is ring-like and lacks a neural process. Ventrally, the centrum is replaced by a narrow strut, and the neural arch is the more prominent component. The transverse processes are broad, wing-like structures. The prezygapophyses bear strongly curved articular surfaces for the occipital condyles. The joints between the occipital condyles and atlas permit mainly up and down or nodding movements of the head on the neck. The postzygapophyses bear nearly flattened surfaces for articulation with the second cervical vertebra, the **axis**. These joints allow mainly rotational movements of the head. The paired **atlantal foramina** pierce the vertebral arch transversely just dorsal to the prezygapophyses. Vessels (such as the craniodorsal artery, a branch of the vertebral artery) and the first cervical nerve pass through the foramen. The **transverse foramina**, despite their name, do not run transversely but anteroposteriorly through the base of the transverse process. The transverse foramen, through which the vertebral artery passes, is characteristic of the cervical vertebrae, except for the last, in which it is usually absent.

The axis is also distinctive (Figure 7.10). It has a large and anteroposteriorly elongated neural process that hangs over the atlas. Also, it has a **dens**, a process that projects anteriorly between the prezygapophyses and articulates with the atlas. This articulation participates in shaking movements of the head. Note the slender, posteriorly projecting transverse processes. The remaining cervical vertebrae are more typical vertebrae (Figure 7.8). Each possesses a relatively slender neural process that increases in height from the third cervical, in which the process is very strongly reduced, to the seventh cervical.

### Thoracic Vertebrae

The cat usually has 13 thoracic vertebrae. These are distinguishable by the presence of additional facets for articulation with ribs and very short transverse processes. The **capitulum** of a **rib** (see below) sits between and articulates with two successive centra, for which most thoracic vertebrae possess **costal demifacets** (Figure 7.11). These are anteriorly and posteriorly paired facets, so that a vertebra typically has four demifacets. The demifacets of successive vertebrae form (on each side) a complete or “full” articular surface for the



capitulum of a rib. Thoracics also have a **costal facet** on the ventral surface of each transverse process for articulation with the **tuberculum** of the corresponding rib.

The thoracic series undergoes various changes as it proceeds posteriorly. For example, the first thoracic has paired costal facets anteriorly and paired demifacets posteriorly. The last few thoracics, usually the 11th

through 13th, only have paired costal facets on the centrum (i.e., no demifacets). Also, the 11th thoracic has markedly reduced transverse processes, while the 12th and 13th lack transverse processes (reflecting the absence of a tuberculum on the last few ribs). The last few thoracic vertebrae have a slender **accessory process** (see Figure 7.12) that extends posteriorly from the pedicle, just lateral to each postzygapophysis. The accessory processes reinforce the articulation between the pre- and postzygapophyses.

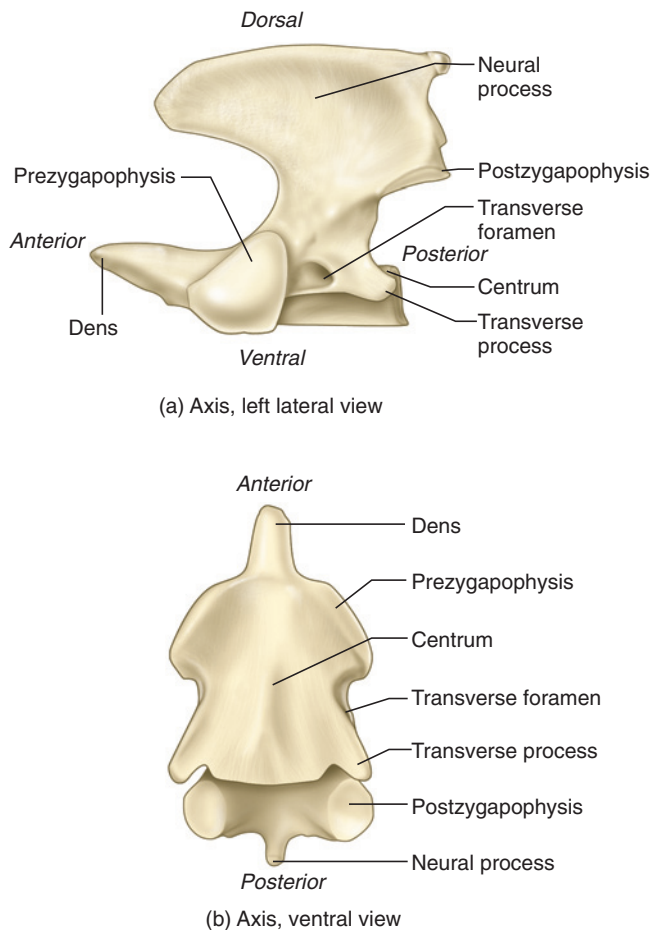
Finally, note the change in the neural process throughout the thoracic series. Anteriorly, the process is high and inclines posteriorly. The height of the process tends to decrease posteriorly while inclination tends to increase until, depending on the individual, the 10th or 11th thoracic vertebra, at which point the process is markedly reduced and points anteriorly. This vertebra is known as the **anticlinal vertebra** (Figure 7.1), denoting the change in inclination. The neural process of the remaining thoracics (as well as the lumbar vertebrae) also incline anteriorly and increase in height. The change inclination of the neural processes allows the cat to extend and flex its back, especially during running.

### Lumbar Vertebrae

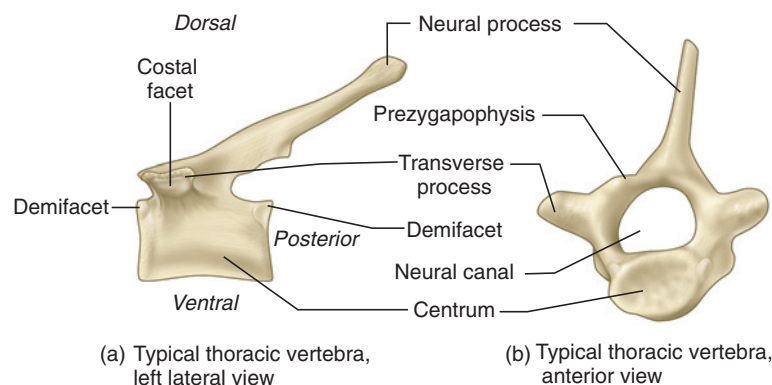
The cat typically has seven lumbar vertebrae. They are characterized by their large size, which increases posteriorly through the lumbar series, and **pleurapophyses**, elongated, blade-like processes that sweep anteroven- trally (Figure 7.12). A pleurapophysis represents a fusion of a transverse process and an embryonic rib. The prezy- gapophyses are extended dorsally beyond the articular surfaces into **mammillary processes** for attachment of epaxial muscles. Finally, note that accessory processes are present on all but the last two lumbar vertebrae.

### Sacral Vertebrae

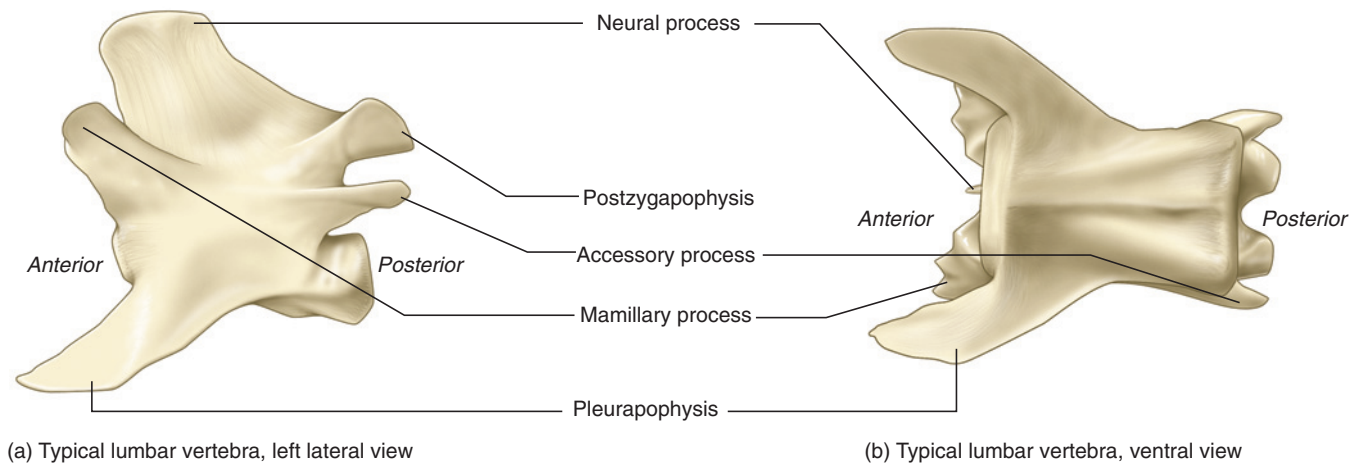
The cat has three sacral vertebrae that are fused together to form a single structure, the sacrum, which links the



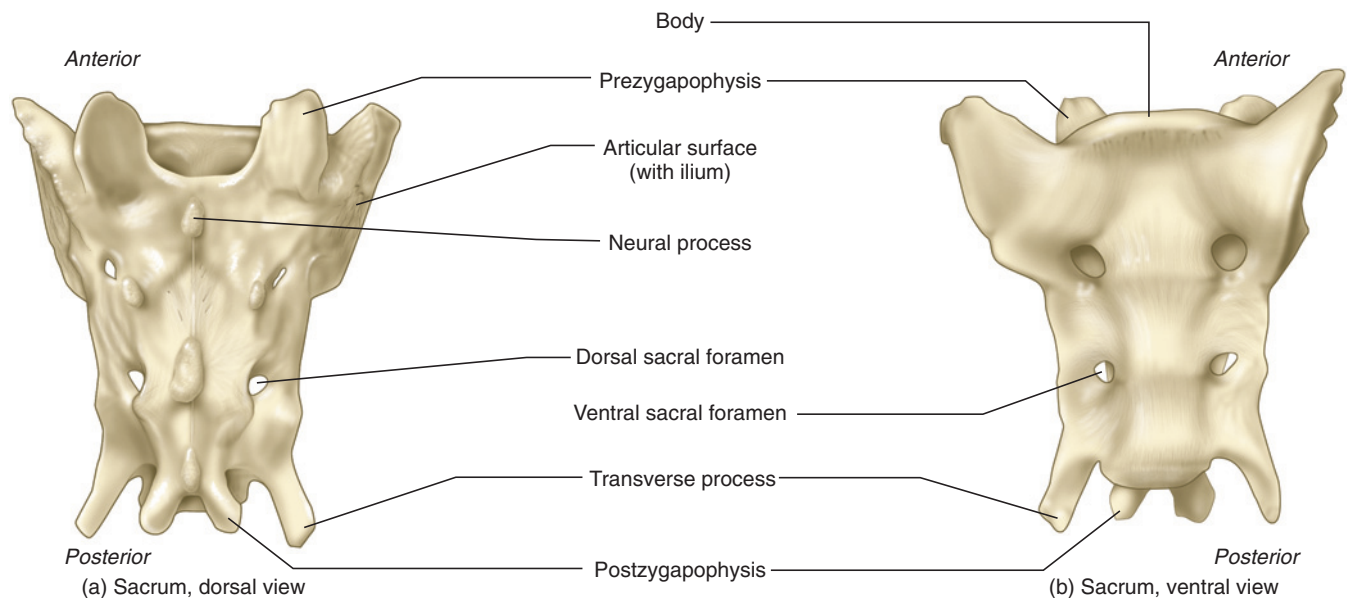
**FIGURE 7.10** Axis of the cat in left lateral and ventral views.



**FIGURE 7.11** Thoracic vertebra of the cat in left lateral and anterior views.



**FIGURE 7.12** Lumbar vertebra of the cat in left lateral and ventral views.

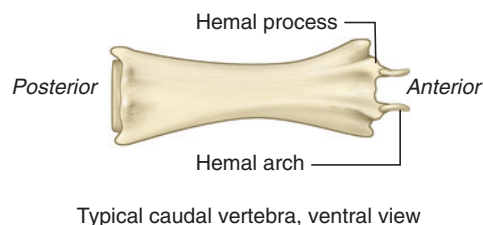


**FIGURE 7.13** Sacrum of the cat in dorsal and ventral views.

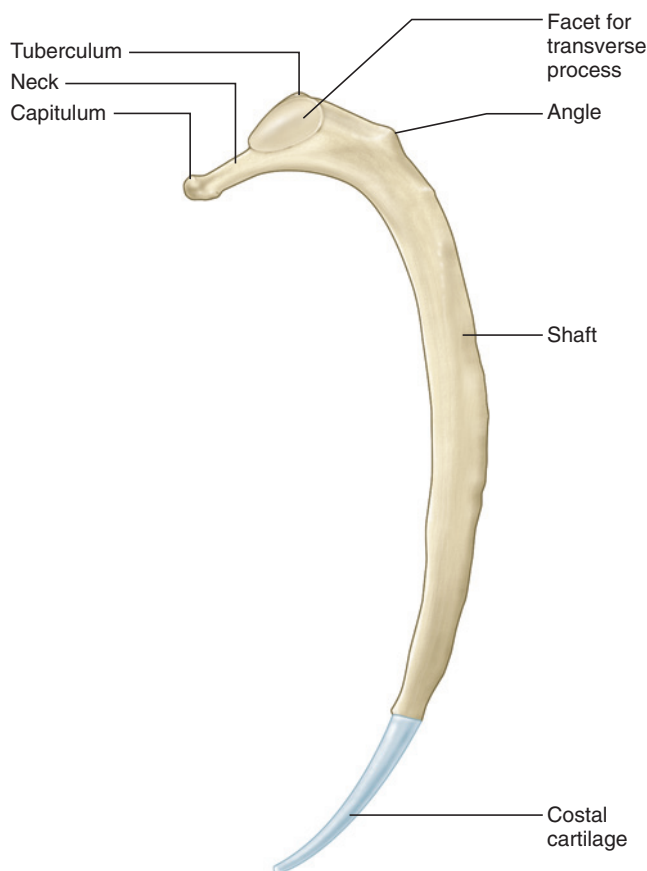
spine to the pelvic girdle (Figure 7.13). Anteriorly the sacrum has on either side a broad, rugose, and nearly circular surface for articulation with the innominate bones of the pelvis. The sacral vertebrae decrease in size posteriorly. Even though they are fused together, many of the structures can be recognized. Identify the three neural processes, and note the areas of fusion at the pre- and postzygapophyses. The pleurapophyses of the sacra are expanded anteriorly and posteriorly and fuse with each other to enclose two pairs of **sacral foramina** on the dorsal and ventral surfaces of the sacrum for the passage of dorsal branches of spinal nerves. The pleurapophysis of the first sacral forms most of the articular surface for the pelvis.

## Caudal Vertebrae

Cats typically possess from 21 to 23 caudal vertebrae, which are the smallest of the vertebrae (Figure 7.14). The caudals tend to become progressively smaller and less complex posteriorly. The anterior caudals have zygapophyses and neural and transverse processes, but the more posterior vertebrae are elongated, cylindrical structures consisting almost entirely of the centrum. Beginning with the third or fourth caudal vertebra, you might note the presence of **hemal arches**, small V-shaped bones, lying at the anterior end of the ventral surface of the vertebra. Successive hemal arches enclose the hemal canal, through which caudal blood vessels pass. Each



**FIGURE 7.14** Caudal vertebra of the cat in ventral view.



**FIGURE 7.15** Rib of the cat.

hemal arch articulates with a pair of small tubercles, the **hemal processes**, on the centrum. The small, delicate arches are usually lost during preparation, but their position can be determined by identifying the hemal processes.

### Ribs

The **ribs** form a strong but partly flexible cage that protects vital organs (e.g., heart and lungs) and participates in inspiration and expiration. Each rib articulates dorsally with the vertebral column and ventrally with a **costal cartilage**.

The 13 pairs of ribs (Figure 7.15) may be subdivided into three types: **vertebrosternal**, **vertebrochondral**, and

**vertebral**, based on the attachment of their costal cartilages onto the **sternum** or breast bone (see Figure 7.16). The first nine ribs are **vertebrosternal** (or “true” ribs), meaning that the costal cartilages attach directly to the sternum. The next three are **vertebrochondral** (or “false” ribs) because their costal cartilages attach to the costal cartilage of another rib; that is, they do not attach directly to the sternum. The last rib is a **vertebral rib** because its short cartilage does not gain access to the sternum. It is thus also known as a **floating rib**.

Ribs differ in length but are generally similar in being curved, slender, rod-like bones. The **capitulum** or head bears surfaces for articulation with the demifacets of the thoracic vertebrae. This is followed by a short, constricted **neck** and then by the **tuberculum**, which has a facet for articulation with the costal facet on the transverse process of a thoracic rib. A tuberculum is absent in the final two or three ribs. The **shaft** of the rib curves distally, and bears a well-defined **angle** beyond the tuberculum. A costal cartilage is attached to the distal surface of each rib.

### Sternum

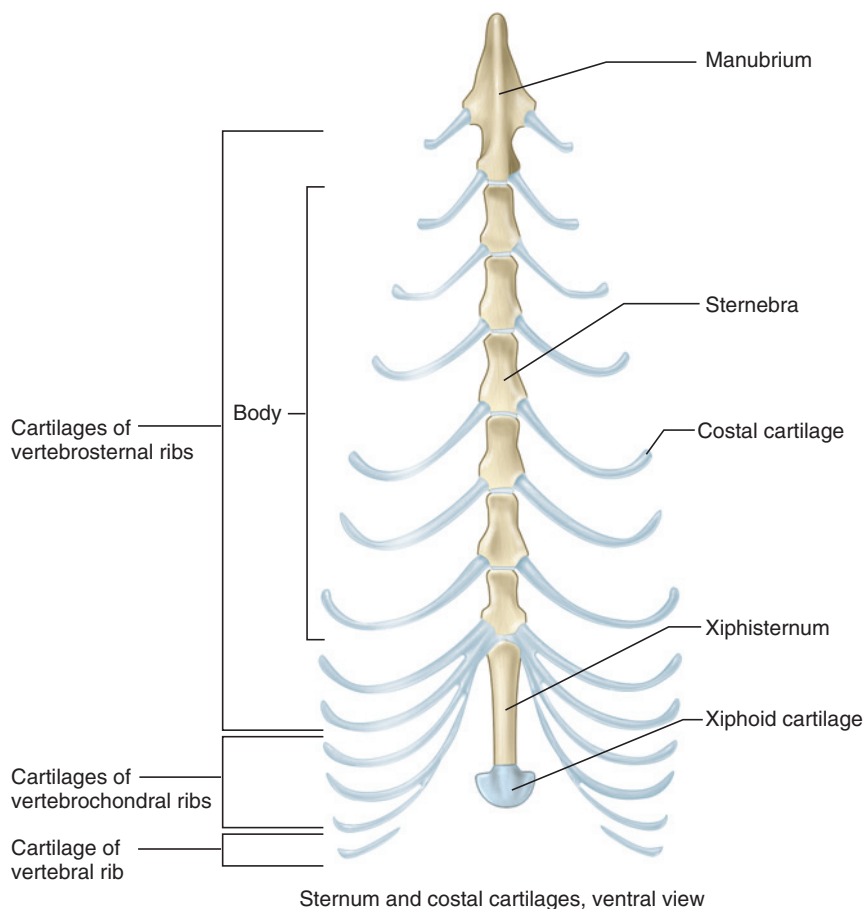
The sternum (Figure 7.16) consists of eight **sternebrae** arranged anteroposteriorly midventrally on the thorax. The most anterior of the series is the spear tip-shaped **manubrium**. In some individuals the manubrium appears to be formed by the fusion of two elements. The next six sternebrae, constituting the **body** of the sternum, tend to be elongated, spindle-shaped elements. Finally, there is the elongated and tapering **xiphisternum**. The **xiphoid cartilage** attaches to its posterior end. The costal cartilages of the **vertebrosternal** ribs attach directly to the sternum. Typically, the pattern is that a costal cartilage attaches between adjacent sternebrae.

### Forelimb

#### Scapula

The **scapula** or shoulder blade (Figures 17a, b) is a flat, triangular bone. Its medial surface is nearly flat, whereas its lateral surface has a prominent **scapular spine**. Examine a mounted skeleton, and note that the apex of the scapula is directed ventrally. Identify the scapula's **anterior**, **dorsal**, and **posterior borders**. The **glenoid fossa** is the smooth, concave surface at the apex for articulation with the humerus. The delicate **coracoid process** projects medially from the anterior margin of the glenoid fossa and is the site of origin for the coracobrachialis muscle.

The medial surface bears the **subscapular fossa**. It is relatively flat, with a few prominent scar ridges indicating tendinous muscular insertions. Note the prominent ridge near the posterior border that demarcates a



**FIGURE 7.16** Sternum and costal cartilages of the cat in ventral view.

narrow, slightly concave surface for muscular attachment. On the lateral surface, the scapular spine rises prominently and separates the **supraspinous fossa** anteriorly from the **infraspinous fossa** posteriorly, both of which are fairly smooth surfaces. Ventrally the spine ends in the acromion process. Just dorsal to the **acromion process** is the posteriorly projecting **metacromion process**.

### Clavicle

The **clavicle** is a small, slender, slightly curved bone suspended in the musculature associated with the forelimb (Figures 7.1 and 7.17c). It lies just anterior to the proximal end of the **humerus** (see below). As such, the clavicle of the cat does not articulate with other skeletal elements.

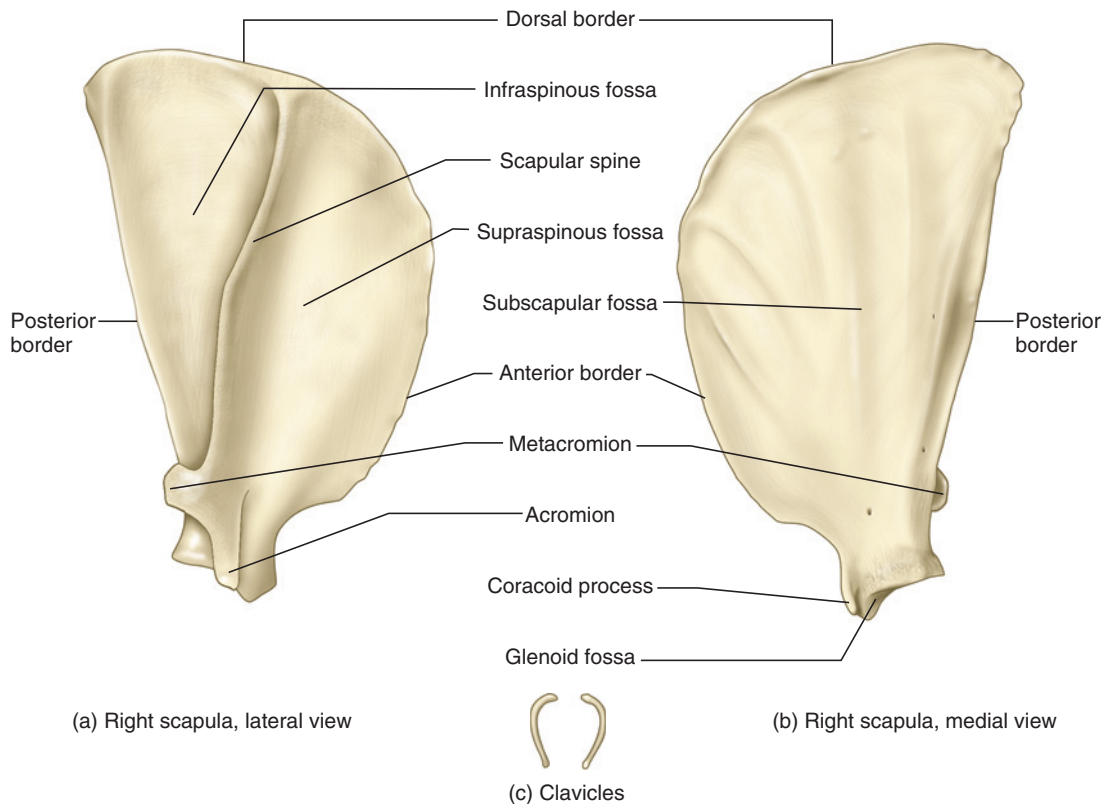
### Humerus

The **humerus** (Figure 7.18) is the bone of the brachium, or proximal part of the forelimb. It articulates proximally with the glenoid fossa of the scapula and distally with the radius and ulna. The **head** is the large, smooth, and rounded surface that articulates with the glenoid fossa of the scapula. It is best seen in proximal and

posterior views. Lateral to the head is the **greater tuberosity**, whereas the **lesser tuberosity** lies medially. Anteriorly between the tuberosities is the deep **bicipital groove**, along which passes the tendon of the biceps brachii muscle. The **pectoral ridge** extends distally from the greater tuberosity on the anterior surface of the humeral shaft. The less prominent **deltoid ridge** extends distally and obliquely from the posterior part of the greater tuberosity. This ridge converges toward and meets the pectoral ridge about midway along the shaft.

Distally, there is a smooth, spool-shaped surface, the **condyle**, which is actually composed of two articular surfaces. The smaller, lateral surface, the **capitulum**, articulates with the **radius** (see below), while the larger, medial surface, the **trochlea**, articulates with the **ulna** (see below). The **coronoid** and **radial fossae** are shallow depressions that lie just proximal to the trochlea and capitulum, respectively, on the anterior surface of the shaft. On the posterior surface, just proximal to the condyle, is the deep **olecranon fossa** that receives the olecranon of the ulna. The **medial** and **lateral epicondyles** are the rugose prominences that lie on either





**FIGURE 7.17** Right scapula of the cat in (a) right lateral and (b) medial views; and (c) clavicles of the cat.

side of the trochlea. The **supracondyloid foramen** is the oval passage lying proximal to the trochlea.

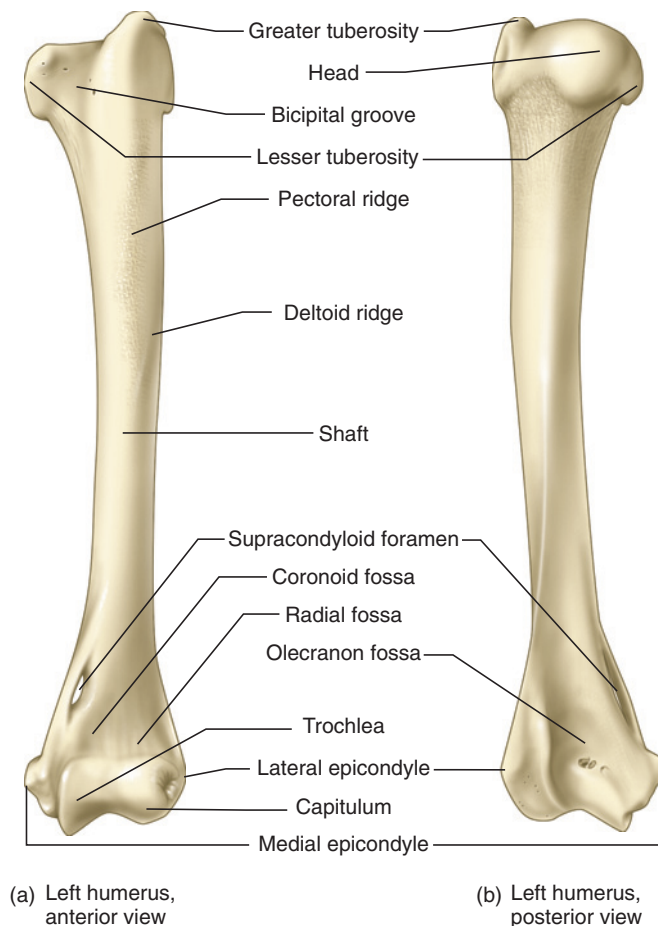
## Ulna

The **ulna** (Figure 7.19) is the longer of the two bones in the forearm, or **antebrachium**. It has a prominent proximal portion, but its shaft tapers distally. Proximally the ulna articulates with the humerus and the radius. Distally it contacts the carpus or wrist. The **trochlear notch** is the deep semicircular surface for articulation with the trochlea of the humerus. The **olecranon** is the squared process extending proximal to the trochlear notch. It is the site of insertion of the tendon of the triceps brachii muscle. The **coronoid process** extends anteriorly from the distal base of the trochlear notch. The **radial notch**, for articulation with the head of the radius, is a curved surface that lies medially along the base of the trochlear notch. The anterior part of the radial notch forms the lateral surface of the coronoid process. The roughened **interosseus crest** lies on the central portion of the medial surface of the ulnar shaft. A sheet of connective tissue extends between the ulnar interosseus crest and the radial interosseus crest (see below) and helps stabilize the antebrachium. The ulna tapers distally and ends in the **styloid process**, which articulates with the lateral part of the carpus.

## Radius

The **radius** (Figure 7.19) is the second bone of the antebrachium. In contrast to the ulna, the radius is more slender proximally and widens distally. As the radius articulates with the lateral part of the humerus and the medial part of the carpus, it crosses over the ulna when a cat assumes a normal standing position (i.e., the manus is *pronated*, meaning the palm faces the ground; the opposite position, with the palm directed up, is termed *supinated*). Proximally the radius consists of the head, which bears an oval, concave **fovea** that articulates with the capitulum of the humerus. The shape of the head allows the radius to rotate on the capitulum. Immediately distal to the fovea, the head bears a smooth, narrow strip, the **articular circumference**, that articulates with the radial notch of the ulna. The **neck** of the radius is a short segment between the head and the **bicipital tuberosity**, onto which the tendon for the biceps brachii muscle inserts. The roughened **interosseus crest** lies distally from the tuberosity on the medial edge of the shaft.

The distal end of the radius has a small articular surface for the ulna medially that allows the radius to turn on the ulna. The distal surface has a large, concave surface that articulates with the scapholunar bone of the wrist.



**FIGURE 7.18** Left humerus of the cat in anterior and posterior views.

Note the two grooves on the anterior surface for passage of extensor tendons, and the short **styloid process** projecting distally from the medial surface of the radius.

## Manus

The manus (Figure 7.20) includes three portions: the **carpus** (wrist), **metacarpus**, and **phalanges** in proximal to distal order. The cat has five **digits** (fingers), each of which is formed by a **metacarpal** and phalanges. The carpus consists of seven small, irregularly shaped bones set in two rows. In medial to lateral order, the proximal row consists of the **scapholunar** and **cuneiform**, with the **pisiform** projecting from the ventral surface of the cuneiform (and thus not visible in Figure 7.20); the distal row consists of the **trapezium**, **trapezoid**, **magnum**, and **unciform**. These bones articulate distally with the **metacarpals**. Note how the bones of the carpus and the metacarpals are arranged in an interlocking pattern that restricts motion.

The metacarpals are included in the palm of the manus. Of the five metacarpals, metacarpal 1 is the most medial and shortest, being less than half the length of metacarpals 2–5. Each metacarpal consists of a base

proximally, a shaft, and a head distally. Digit 1 has only a proximal phalanx, followed by the ungual phalanx, which bears a large claw. Digits 2–5 each have three segments, the proximal, intermediate, and ungual phalanges; the latter also bear large claws.

## Hind Limb

### Pelvis

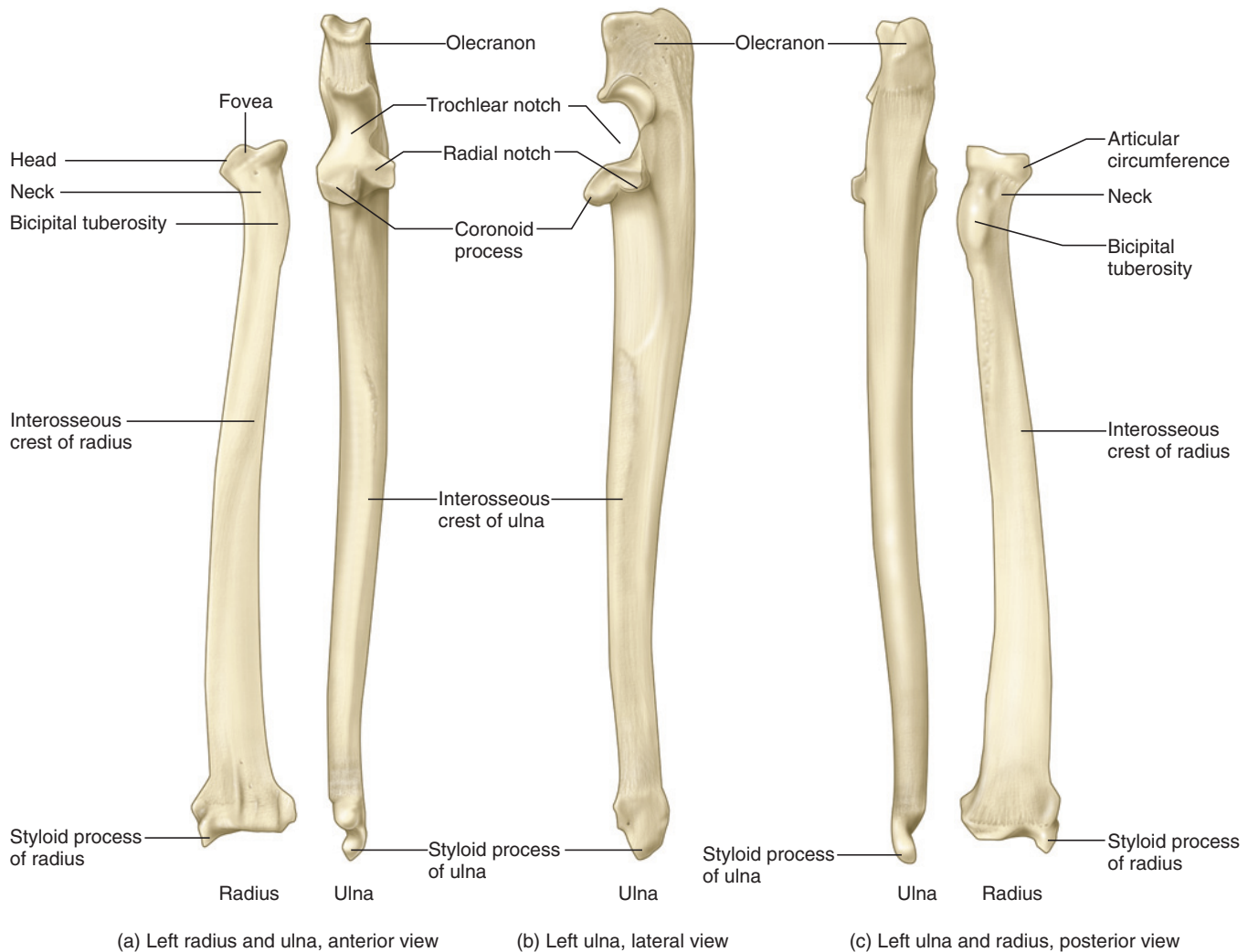
The pelvis or hip consists of paired **innominate bones** (Figure 7.21) that articulate with each other ventrally at the **pelvic symphysis** and with the sacrum dorsally. Examine a mounted specimen, and note the position and orientation of the innominate. Each innominate is composed largely from three bones, the **ilium**, **ischium**, and **pubis**, although a fourth center of ossification, the **acetabular bone**, makes a small contribution. These bones are firmly fused together in the adult. Examine an innominate bone in lateral view and note the large ventral opening, the **obturator foramen**. Locate the **acetabulum**, the deep socket that receives the head of the femur (see below).

The ilium consists of a **body**, near the acetabulum, and an anterodorsally projecting **wing**. The **iliac crest** is the roughened, anterodorsal edge of the ilium. The rugose articular surface for the sacrum lies on the medial surface of the wing. The ischium extends posteriorly from the acetabulum and has an expanded termination, the **ischial tuberosity**. The pubis and the rest of the ischium are oriented ventromedially. Both bones contribute to the medial margin of the obturator foramen. Also, the ischium and pubis of each side of the body meet to form, respectively, the **ischial** and **pubic symphyses**, which together form the pelvic symphysis. The acetabular bone forms the thin, medial part of the acetabulum.

### Femur

The **femur** (Figure 7.22) is the bone of the proximal part of the hind limb, or thigh. The **head** of the femur is a hemispherical surface that fits into the acetabulum of the innominate. The head is supported by the **neck**, which projects obliquely from the proximal end of the femur. Lateral to the head is the roughened, proximally projecting **greater trochanter**, which serves for attachments of hip musculature. The deep depression posteriorly between the trochanter and head is the **trochanteric fossa**. On the posterior surface of the shaft, just distal to the head, is the **lesser trochanter**. The intertrochanteric line connects the two trochanters, but is especially defined along the posterior edge of the greater trochanter. The most prominent muscular insertion site on the diaphysis is the **linea aspera**, the roughened ridge that extends diagonally along the posterior surface of the femur.

The femur expands distally into the prominent and posteriorly projecting **lateral** and **medial condyles**. Each



**FIGURE 7.19** Bones of the left antebrachium of the cat; (a) radius and ulna in anterior view, (b) ulna in lateral view, and (c) ulna and radius in posterior view.

condyle bears a smooth, semicircular surface for articulation with the tibia. The **intercondyloid fossa** is the depression posteriorly between the condyles. The rugose areas for muscular attachment proximal to the condyles are the **lateral** and **medial epicondyles**. The **patellar trochlea**, for articulation with the patella, lies anteriorly between the condyles. It is a smooth, shallow trough, oriented proximodistally.

### Patella

The **patella** (Figure 7.22), or kneecap, is a small, tear-shaped sesamoid bone, with its apex directed distally. Its anterior surface is roughened. Posteriorly it bears a smooth, shallowly concave surface for articulation with the femur.

### Tibia

The **tibia** (Figure 7.23) is the larger and medial bone of the crus, or middle segment of the hindlimb. Its proxi-

mal surface bears **lateral** and **medial condyles** that articulate with the femur. Just distal to the lateral condyle, on the lateral surface and facing distally, is the small, nearly oval facet for the head of the **fibula** (see below). On the posterior surface of the tibia, between the condyles, is the **popliteal notch**. A small muscle, the popliteus, lies in the notch and is a flexor of the knee joint. The **tibial tuberosity**, for insertion of the patellar ligament, lies anteriorly. The **tibial crest** continues distally from the tuberosity along the shaft.

The distal end of the tibia has two articular surfaces. The large surface on the distal surface, the **cochlea tibiae**, is for the astragalus, the tarsal bone with which the pes articulates with the hindlimb. Note how this facet consists of two sulci separated by a median ridge. This structure restricts motion at the ankle almost entirely to a fore and aft direction, producing flexion and extension. If available, manipulate the tibia and pes to observe this. The small, nearly triangular **fibular**

**facet**, for articulation with the fibula, faces posterolaterally and is contiguous with the lateral part of the cochlea tibiae. The **medial malleolus** is the distal extension of the tibia's medial surface. It forms the medial protrusion of the ankle.

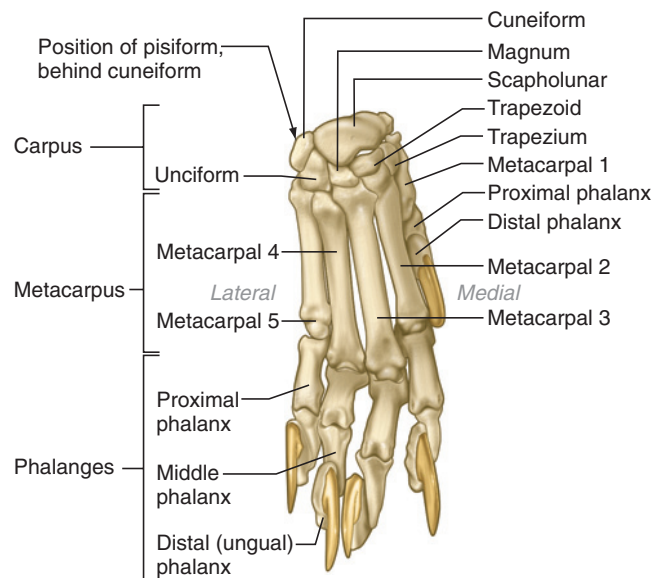
## Fibula

The fibula (Figure 7.23) is the slender, lateral, and shorter bone of the crus. The **head** is irregular and expanded. It bears a proximal facet for articulation with

the tibia. The slender shaft widens distally. There are two distal facets, both toward the anterior half of the medial surface. The more proximal facet is for the distal articulation with the tibia. The distal facet articulates with the lateral part of the trochlea of the astragalus. The **lateral malleolus** projects distally from the posterolateral end of the fibula.

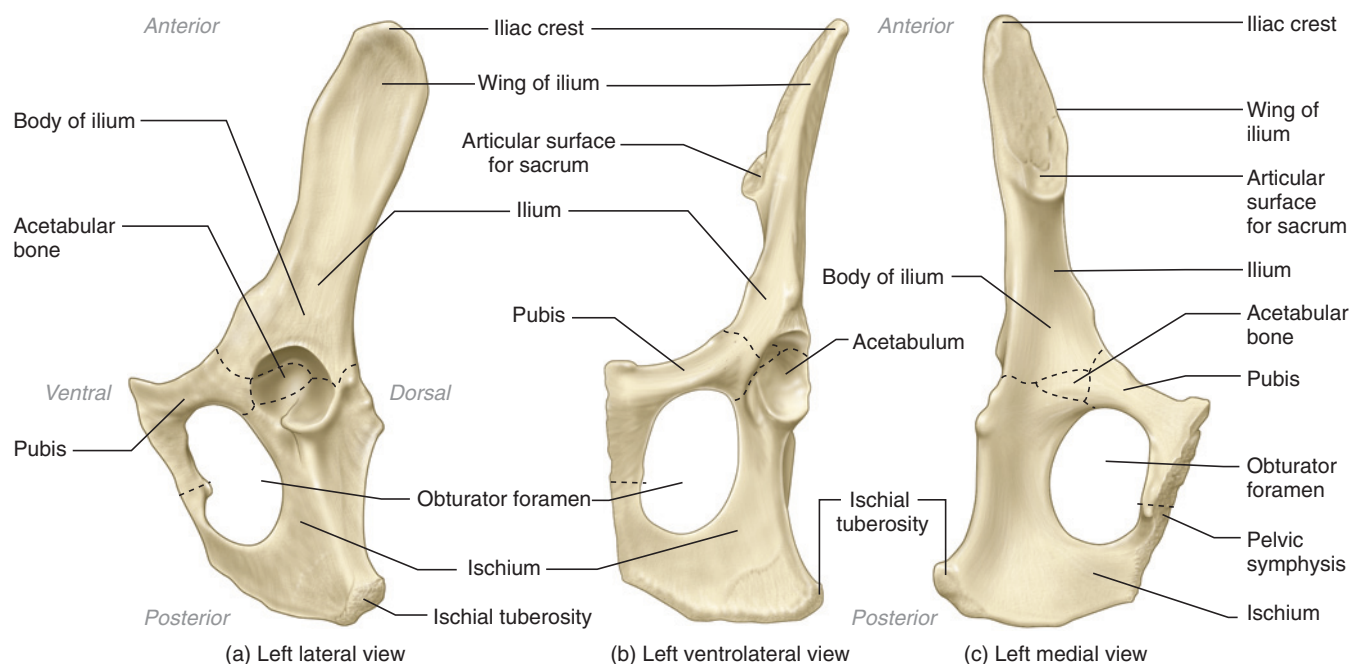
## Pes

The pes (Figure 7.24) consists of **tarsals**, **metatarsals**, and **phalanges**. There are seven tarsals, but the two most proximal bones, the **astragalus** and **calcaneum**, are much larger than the others. The astragalus is the medial bone. It articulates proximally with the tibia and fibula. Note the form of the surface, or **trochlea tali**, for articulation with the tibia. The trochlea consists of medial and lateral keeled surfaces separated by a sulcus. The astragalus articulates ventrally with the calcaneum, which lies laterally. It is about twice as long as the astragalus and projects posteriorly as the heel. Distally the astragalus articulates with the **navicular**, while the calcaneum articulates with the **cuboid**. The navicular articulates distally with the **lateral**, **intermediate**, and **medial cuneiform** bones, and laterally with the cuboid. Note how the articulations among the tarsals and metatarsals are arranged to produce interlocking joints that tend to restrict movement. For example, the lateral cuneiform articulates with metatarsal III distally, but its medial surface articulates with both the intermediate cuneiform and metatarsal II. There are five metatarsals. The first is strongly reduced to a small nub that articulates with the medial cuneiform. The phalanges for digit 1 have been lost in the cat. The remaining metatarsals are stout,



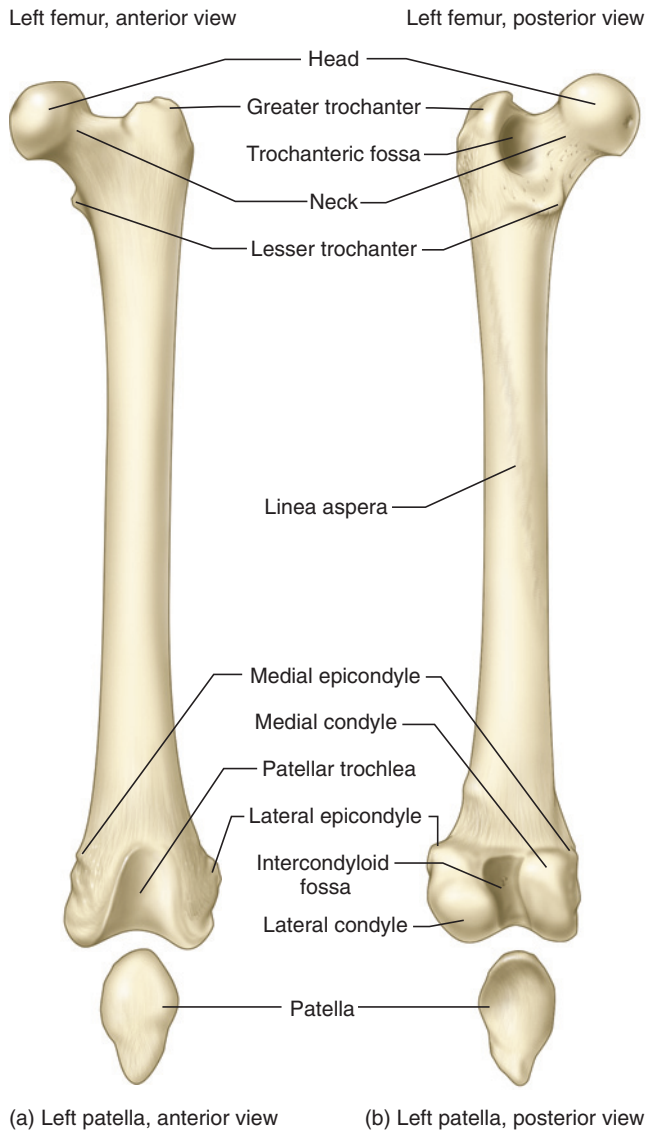
Right manus, dorsal view

**FIGURE 7.20** Right manus of the cat in dorsal view.



**FIGURE 7.21** Left os coxae of the cat in (a) lateral, (b) ventrolateral, and (c) medial views.





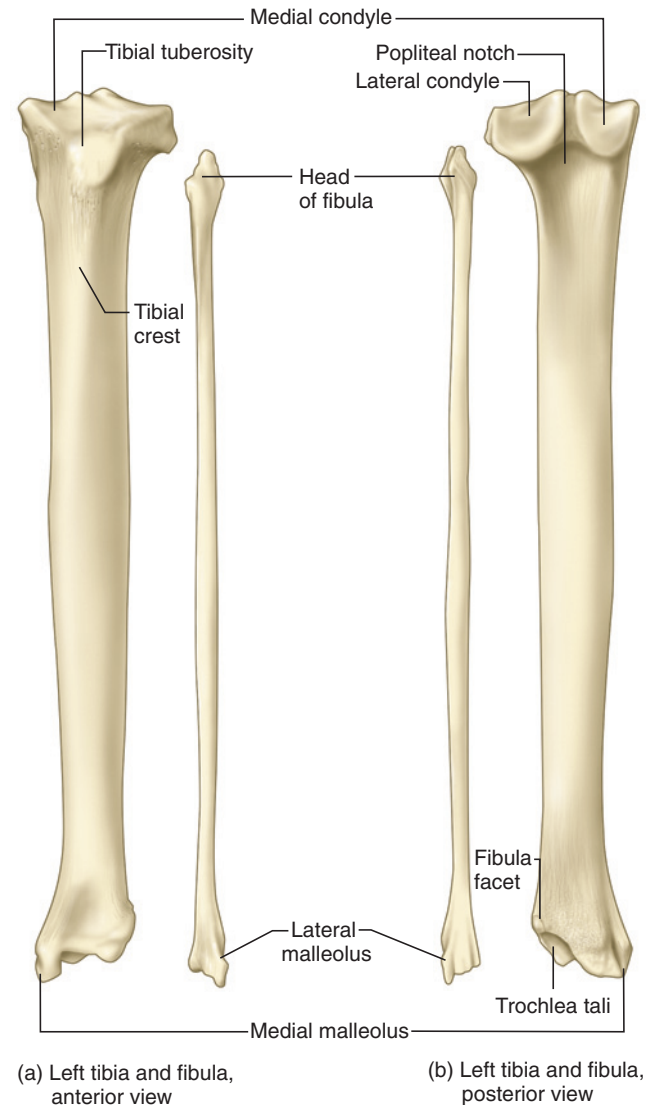
**FIGURE 7.22** Left femur and patella of the cat in (a) anterior and (b) posterior views.

elongated elements and each articulates with a series of three phalanges, the proximal, intermediate, and ungual phalanges.

### KEY TERMS: POSTCRANIAL SKELETON

accessory process  
acetabular bone  
acetabulum  
acromion process  
angle  
antebrachium (forearm)  
anterior, dorsal,  
posterior borders of  
scapula

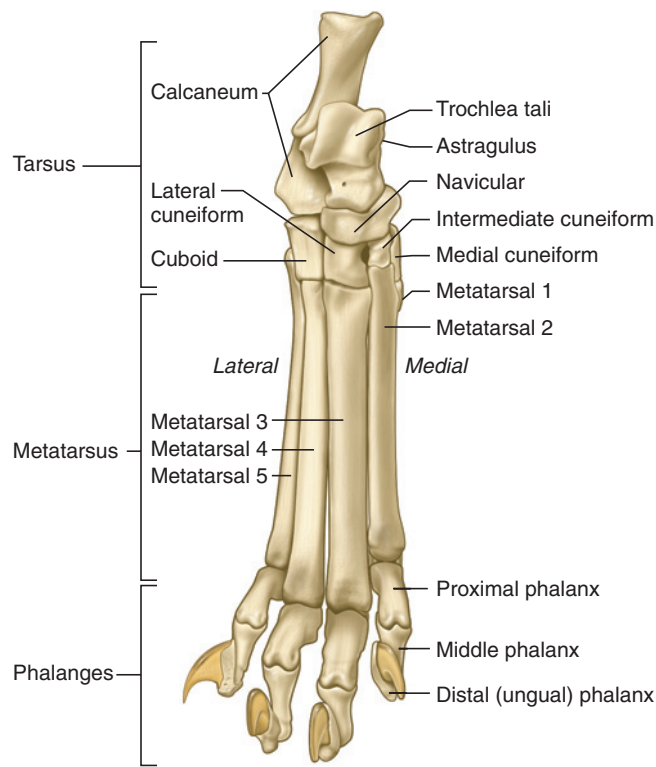
anticlinal vertebra  
articular circumference  
astragalus (talus)  
atlantal foramen  
(plur., foramina;  
intervertebral  
foramen)  
atlas  
axis



**FIGURE 7.23** Left tibia and fibula of the cat in (a) anterior and (b) posterior views.

bicipital groove  
bicipital tuberosity  
body  
calcaneum (calcaneus)  
capitulum (head) of rib  
carpus  
caudal vertebrae  
centra (sing., centrum)  
cervical vertebrae  
clavicle  
cochlea tibiae  
condyle  
coracoid process  
coronoid fossa

coronoid process  
costal cartilage  
costal demifacet  
costal facet  
cuboid  
cuneiform (lateral,  
medial, intermediate)  
deltoid ridge  
dens  
digits  
femur  
fibula  
fibular facet  
fovea



Right pes, dorsal view

**FIGURE 7.24** Right pes of the cat in dorsal view.

glenoid fossa  
greater trochanter  
greater tuberosity  
head of femur  
head of humerus  
head of radius  
hemal arches  
hemal processes  
humerus  
iliac crest  
ilium  
infraspinous fossa  
innominate bones  
intercondyloid fossa  
interosseus crest of radius  
interosseus crest of ulna  
intervertebral foramen  
ischial symphysis  
ischial tuberosity  
ischium

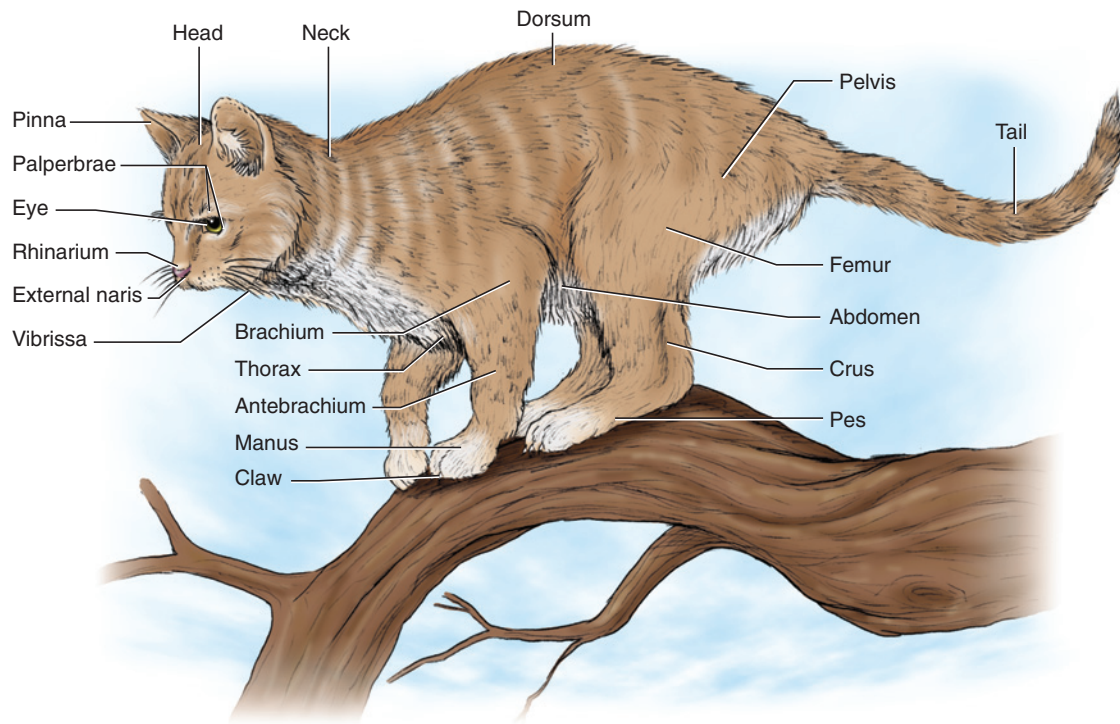
lamina  
lateral condyle  
lateral epicondyles  
lateral malleolus  
lesser trochanter  
lesser tuberosity  
linea aspera  
lumbar vertebrae  
magnum  
mamillary processes  
manubrium  
medial condyles  
medial epicondyle  
medial malleolus  
metacarpals  
metacarpus  
metacromion process  
metatarsals  
navicular  
neck of femur  
neck of radius

neck of rib  
neural arch  
neural canal (vertebral canal)  
neural process (spinous process)  
obturator foramen  
olecranon  
olecranon fossa  
patella  
patellar trochlea  
pectoral ridge  
pedicle  
pelvic symphysis  
phalanges  
pisiform  
pleurapophyses  
popliteal notch  
postzygapophysis  
prezygapophysis  
pubic symphysis  
pubis (pl., pubes)  
radial fossa  
radial notch  
radius  
rib  
sacral foramina  
sacral vertebrae  
scapholunar  
scapula  
scapular spine  
shaft of humerus (diaphysis)  
shaft of femur (diaphysis)

shaft of fibula (diaphysis)  
shaft of rib  
sternebrae  
sternum  
styloid process  
subscapular fossa  
supracondyloid foramen  
supraspinous fossa  
tarsals  
thoracic vertebrae  
tibia  
tibial crest  
tibial tuberosity  
transverse foramina  
transverse process  
trapezium  
trapezoid  
trochanteric fossa  
trochlea  
trochlea tali  
trochlear notch  
tuberculum  
ulna  
unciform  
vertebrae  
vertebral  
vertebral column  
vertebrochondral  
vertebrosternal  
wing  
xiphisternum  
xiphoid cartilage

## SECTION II—EXTERNAL ANATOMY

The body of the cat is covered almost entirely by **hair** (forming a thick coating of fur or pelage), a characteristic feature of mammals. Only the nose, **lips**, and thick pads of the feet are exceptions. The **head** and **trunk** are separated by a distinct **neck**, which allows considerable mobility of the head (Figure 7.25). Dorsally the trunk



**FIGURE 7.25** External features of the cat.

is termed the **dorsum**. Ventrally, it is subdivided into the **thorax** anteriorly and the **abdomen** more posteriorly. The **pelvis** is the region of the trunk associated with the hindlimb, just anterior to the elongated **tail**.

On the head note the **pinnae** (sing., **pinna**), the mainly cartilaginous soft-tissue extension of the external ear. Upper and lower **palpebrae** (sing., **palpebra**) guard the large **eyes**. A third eyelid, the **nictitating membrane**, lies on the medial part of the eye. In life, it can be drawn laterally over the eye. The **nares** (sing., **naris**) are the external openings of the nose and are surrounded by a region of skin termed the **rhinarium**. The **mouth** is surrounded by lips. **Vibrissae** are stiff, tactile hairs or whiskers present mainly around the mouth and snout, but also over the eyes.

Each limb comprises three segments. In proximal to distal order, they are the **brachium**, **antebrachium**, and **manus** in the forelimb, and **femur**, **crus**, and **pes** in the hindlimb. Each digit, except digit 1 of the pes, ends in a retractable **claw**. The walking surface of the forepaws and hindpaws each have epidermal thickenings of the skin termed **tori** (sing., **torus**) that act as pads during locomotion.

The **anus**, the posterior opening of the intestine, lies ventral to the base of the tail. The urinary and reproductive structures lie just anterior to the anus. In the male the **scrotum** is a sac-like projection that contains

the testes. Anterior to it is the **penis**, which is probably retracted and thus not readily apparent. Its tip contains the common opening of the urogenital ducts. In the female the urinary and reproductive tracts open into the **urogenital aperture**.

### KEY TERMS: EXTERNAL ANATOMY

<b>abdomen</b>	<b>nictitating membrane</b>
<b>antebrachium</b> (forearm)	<b>palpebrae</b> (sing., palpebra) (eyelid)
<b>anus</b>	<b>pelvis</b>
<b>brachium</b> (arm)	<b>penis</b>
<b>claw</b>	<b>pes</b>
<b>crus</b> (shank)	<b>pinnae</b> (sing., pinna)
<b>dorsum</b> (back)	<b>rhinarium</b>
<b>eyes</b>	<b>scrotum</b>
<b>femur</b> (thigh)	<b>tail</b>
<b>hair</b>	<b>thorax</b>
<b>head</b>	<b>tori</b> (sing., torus)
<b>lips</b>	<b>trunk</b>
<b>manus</b>	<b>urogenital aperture</b>
<b>mouth</b>	<b>vibrissae</b> (sing., vibrissa) (whisker)
<b>nares</b> (sing., naris) (nostrils)	
<b>neck</b> (cervix)	

## SECTION III—MUSCULAR SYSTEM

### Muscle Terminology

Tables 7.2 to 7.4 list the muscles covered here, including their areas of origin, insertion, and main actions. Muscles may be named according to several criteria. Often a name refers to the muscle's area of origin and area of insertion, usually but not always in this order. For example, the spinodeltoid extends from the spine of the scapula to the deltoid ridge of the humerus; the sternomastoid from the sternum to the mastoid process of the temporal bone of the skull; xiphohumeralis from the xiphoid process of the sternum to the humerus. A name may also refer to the main position of a muscle. For example, the subscapularis essentially occupies all of the subscapular fossa of the scapula; the temporalis the temporal fossa of the skull. In other cases, names are descriptors of shape or form. For example, the deltoid is generally triangular, shaped like the Greek letter delta ( $\Delta$ ). Often, *-ceps* (from the ancient Greek word for "head") appears in a muscle's name in reference to the number of heads that form the muscle—the triceps, for example, is formed by three heads, at least in humans, to which much of the terminology was first applied.

### Connective Tissue and Fiber Direction

Various features and structures are associated with the muscles, but dissection and identification of the muscles requires knowing only the following features. When the skin has been removed, you will note that the muscles are covered by connective tissue. There are various kinds of connective tissue: **epimysium** covers or envelops the surface of individual muscles; **loose connective tissue** lies between structures (such as muscles, nerves, or blood vessels) and helps fill the spaces between them; **fascia** is a very dense, sheet-like connective tissue associated in various ways with muscles; and **tendons** are dense connective tissue that connect muscles (mainly) to skeletal elements. When a tendon is very short, the muscle has a *fleshy attachment*. When it is longer, the muscle has a *tendinous attachment*. In many cases, the tendon is large and sheetlike; such a tendon is an **aponeurosis**, and the attachment is *aponeurotic*.

The visible fibers of a muscle will all tend, in the majority of cases, to have a similar direction. It is very helpful to note fiber direction in distinguishing where one muscle ends and another begins, particularly when muscles overlap one another. This is an important clue in identifying muscles, as well as in knowing where to separate them.

Fiber direction, however, is often obscured by connective tissue, and thus it is essential that you remove the connective tissue until the direction is clearly revealed.

You do not need to clean the whole surface of every muscle. It is sufficient to clear surfaces near where text directions indicate the edges of muscles should be. Most connective tissue can usually be picked away using forceps and a dissecting needle. It is sometimes, but rarely, necessary to use a scalpel in nicking away the connective tissue on the surface of a muscle. Separating muscles can usually be accomplished by using a blunt probe to tear through loose connective tissue. A scalpel should not (unless indicated) be used to cut between muscles. In clearing connective tissue, then, you will be mainly concerned with epimysium or loose connective tissue. You will not cut through aponeuroses or fascia, unless specifically directed to do so.

### KEY TERMS: MUSCULAR SYSTEM

aponeurosis	loose connective
epimysium	tissue
fascia	tendon

### Subdivision of the Musculature

As for the dogfish, the musculature of the cat may be subdivided into formal groups based on phylogenetic derivation. The major muscles can be identified to group based on embryology and innervation. However, the muscles of the cat have undergone considerable modification and are much more complex than in the dogfish. Thus, the musculature from any formal group usually cannot be studied at the same time, because some muscles lie superficially and others more deeply. Also, in many cases muscles have evolved different functions than in their remote predecessors. For example, the trapezius is originally a branchiomeric muscle, but in the cat it functions as an appendicular muscle. For the cat, then, it is more practical to dissect and identify the muscles as they are observed in superficial and deep views. The musculature is organized under informal headings for convenience in dissection. This should help organize your dissection and study of the muscles.

### Skinning the Cat

To examine the muscles and other internal structures, the cat will have to be skinned, but the skin should not be completely removed. It is best to remove the skin from only part of the cat and leave it as a flap that can be wrapped around the cat at the end of each dissection. This helps protect the muscles and other structures and prolongs preservation of your specimen.

Before beginning, read the instructions below with your specimen in front of you, and assess where you will cut through the skin. Determine the course of the incisions according to these instructions and Figure 7.26. Once skinning is completed, you will have a flap of skin still



TABLE 7.2 Muscles of the forelimb

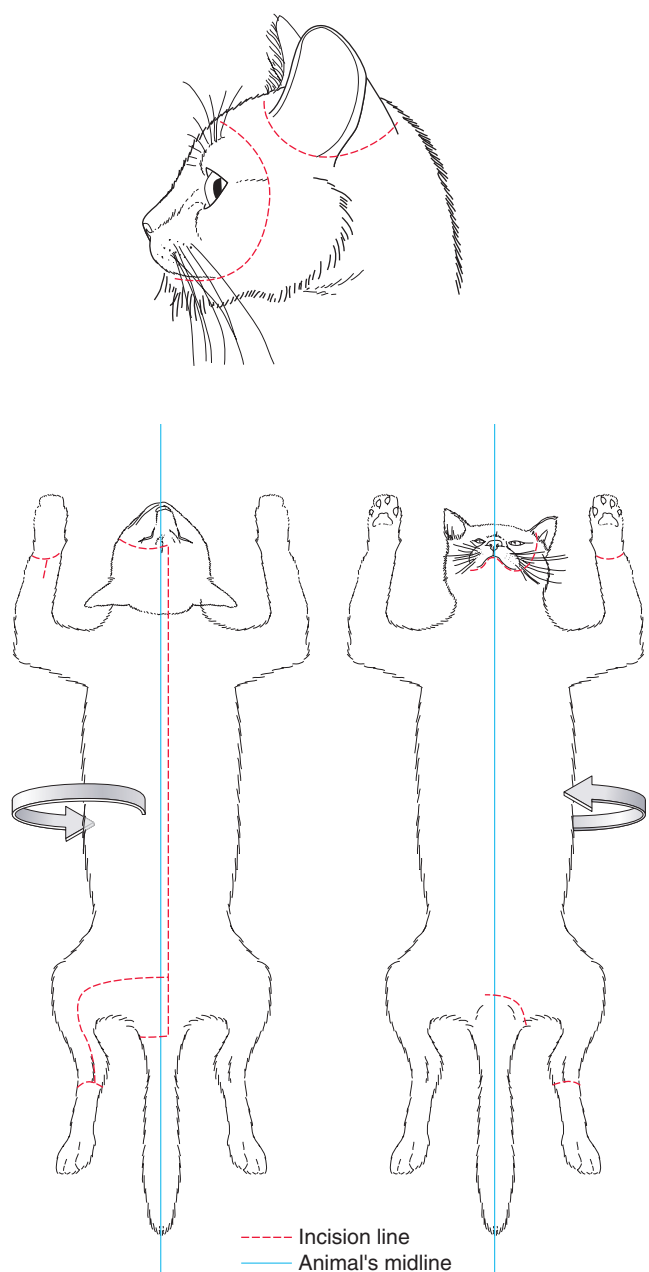
Name	Origin	Insertion	Main Actions
Acromiodeltoid Acromiotrapezius	posterior margin of acromion of scapula middorsal line from neural process of axis to 4th thoracic, by aponeurosis	lateral surface of spinodeltoid muscle metacromion process and anterior half of spine of scapula	flexes and rotates humerus laterally adducts and stabilizes scapulae
Biceps brachii	small tubercle near dorsal margin of glenoid fossa of scapula, by tendon	bicipital tuberosity of radius, by tendon	flexes antebrachium
Brachialis	lateral surface of humerus	lateral surface of ulna, just distal to semilunar notch	flexes antebrachium
Brachioradialis Clavobrachialis	midshaft of humerus clavicle and raphe shared with clavotrapezius	styloid process of radius medial surface of ulna, just distal to semilunar notch	supinates manus flexes antebrachium
Clavotrapezius	medial half of nuchal crest of skull and middorsal line up to neural process of axis	clavicle and raphe shared with clavobrachialis	draws scapula anterodorsally
Cleidomastoid	mastoid process of temporal	clavicle	turns head when clavicle stabilized; draws clavicle anteriorly when head stabilized
Coracobrachialis Epitrochlearis Infraspinatus Latissimus dorsi	coracoid process of scapula surface of latissimus dorsi infraspinous fossa of scapula thoracolumbar fascia	medial surface of proximal end of humerus olecranon process of ulna, by fascia greater tuberosity of humerus medial surface of proximal diaphysis of humerus	adducts humerus extends antebrachium rotates humerus laterally draws humerus posterodorsally
Levator scapulae ventralis	occipital bone and transverse process of atlas	ventrally on metacromion and infraspinous fossa of scapula	draws scapula anteriorly
Pectoantebrachialis	manubrium of sternum	fascia covering proximal surface of antebrachium	adducts humerus
Pectoralis major Pectoralis minor Rhomboides	anterior sternebrae body of sternum posterior cervical and anterior thoracic vertebrae	pectoral ridge of humerus pectoral ridge of humerus posterior part of dorsal border of scapula	adducts humerus adducts humerus draws scapula toward vertebral column
Rhomboides capitis Serratus ventralis cervicis	medial portion of nuchal crest transverse processes of 3rd to 7th cervical vertebrae	anterior part of dorsal border of scapula medial surface of scapula, near dorsal border	rotates and draws scapula anteriorly draws scapula anteroventrally
Serratus ventralis thoracis	lateral surface of first 9 or 10 ribs	medial edge of scapula, near dorsal border	draws scapula ventrally, helps support trunk on forelimb
Spinodeltoid Spinotrapezius	middle third of spine of scapula middorsal line from neural processes of most thoracic vertebrae	deltoid ridge of humerus tuberosity of spine of scapula; fascia of supraspinatus and infraspinatus muscles	flexes and laterally rotates humerus draws scapula posterodorsally
Subscapularis Supraspinatus Teres major	subscapular fossa of scapula suprapinous fossa of scapula dorsal third of posterior border of scapula	lesser tuberosity of humerus greater tuberosity of humerus medial surface of humerus, by tendon in common latissimus dorsi	adducts humerus extends humerus flexes and medially rotates humerus
Teres minor	posterior border of scapula, just distal to glenoid fossa	greater tuberosity of humerus	flexes and laterally rotates humerus
Triceps brachii lateral head long head	deltoid ridge of humerus posterior border of scapula, near glenoid fossa	all 3 heads of the triceps brachii insert on the olecranon process of ulna by a common tendon	all 3 heads of the triceps brachii act to extend antebrachium
medial head Xiphohumeralis	shaft of humerus xiphoid process of sternum	near distal border of bicipital groove of humerus	adducts forelimb

**TABLE 7.3** Muscles of the hind limb

Name	Origin	Insertion	Main Actions
Adductor femoris Adductor longus/adductor femoris longus	pubis and ischium anterior margin of pubis	shaft of femur (linea aspera) shaft of femur (linea aspera)	adducts and extends thigh adducts thigh extensor of thigh—wiscnitzer flexor of thigh—crouch—probably right flexes thigh flexes crus, abducts thigh
Articularis coxae/capsularis Biceps femoris	ilium ischial tuberosity	anterior surface of femur by broad aponeurosis to patella and proximal half of tibia	flexes thigh flexes crus, abducts thigh
Coccygeus/abductor caudae internus Extensor digitorum longus	dorsal margin of ilium and ischium lateral epicondyle of femur	2nd to 5th caudal vertebrae distal phalanges of digits 2 to 5, by tendon that branches into 4 portions	flexes tail extends digits 2 to 5; flexes pes
Flexor digitorum longus	proximal portion of fibula and tibia	joins tendon of flexor hallucis longus to distal phalanges of digits 2 to 5	flexes digits 2 to 5 and extends pes
Flexor hallucis longus	proximal portion of fibula and tibia	joins tendon of flexor digitorum longus to distal phalanges of digits 2 to 5	flexes digits 2 to 5 and extends pes
Gastrocnemius	lateral and medial epicondyles of femur, and patella	by tendon onto proximal end of calcaneum, together with tendon of soleus muscle	extends pes; flexes crus
Gemellus caudalis/inferior	dorsolateral surface of ischium, anterior to ischial tuberosity	tendon of obturatorius internus	abducts thigh
Gemellus cranialis/superior Gluteofemoralis/caudofemoralis/ coccygeofemoralis/gluteobiceps Gluteus superficialis/maximus	dorsal margin of ischium and ilium anterior caudal vertebrae posterior sacral and anterior caudal vertebrae, and gluteal fascia	greater trochanter of femur patella distal part of greater trochanter of femur	abducts and outwardly rotates thigh abducts thigh and extends crus abducts thigh
Gluteus medius	posterior sacral and anterior caudal vertebrae, dorsolateral surface of ilium, and sacral fascia	proximal part of greater trochanter of femur	abducts thigh
Gluteus profundus/minimus Gracilis	ventrolateral surface of ilium pubic and ischial symphyses	lateral part of greater trochanter of femur proximomedial surface of tibia, crural fascia	abducts and outwardly rotates thigh adducts thigh, flexes crus
Iliopsoas	lumbar and posterior thoracic vertebrae, and ilium	lesser trochanter of femur	flexes and rotates thigh
Obturatorius externus Obturatorius internus	ischium and pubis ischium and connective tissue covering obturator foramen	trochanteric fossa of femur trochanteric fossa of femur	flexes thigh abducts thigh
Pectineus	anterior margin of pubis	surface of femur, just distal to lesser trochanter	adducts thigh

**TABLE 7.3** *Continued*

Name	Origin	Insertion	Main Actions
Peroneus brevis/fibularis brevis Peroneus longus	distal half of fibula proximal half of fibula	lateral surface of metatarsal 5 by tendon onto proximal part of metatarsals 2 to 4	extends pes flexes and everts pes
Peroneus tertius/extensor digitorum lateralis Piriformis/pyriformis	lateral surface of fibula posterior sacral and anterior caudal vertebrae	tendon of extensor digitorum longus greater trochanter of femur	extends and abducts 5th digit; flexor of pes— crouch; extends ankle joint—H&W abducts thigh
Plantaris/flexor digitorum superficialis	lateral epicondyle of femur and patella	by tendon extending past proximal end of calcaneum and onto tendon of flexor digitorum brevis	extends pes (and, through flexor digitorum brevis, flexes digits 2 to 5)
Popliteus Quadratus femoris	lateral epicondyle of femur ischial tuberosity	proximal third of medial surface of tibia greater trochanter and lesser trochanter of femur	flexes crus and rotates tibia medially extends and outwardly rotates thigh
Rectus femoris	ventral margin of ilium anterior to acetabulum	lateral surface of patella	extends crus
Sartorius	iliac crest and anteromedial margin of ilium	proximomedial surface of tibia, and patella	adducts thigh, contributes to extension of crus
Semimembranosus	ischial tuberosity and posterior margin of ilium	distomedial surface of femur	extends thigh, flexes crus
Semitendinosus Soleus	ischial tuberosity proximal third of fibula	proximomedial surface of tibia proximal end of calcaneum (with tendon of gastrocnemius)	flexes crus, extends thigh extends pes
Tensor fasciae latae	anteroventral surface of ilium	fascia lata, which merges with proximal part of aponeurosis of biceps femoris (see above)	flexes thigh
Tenuissimus/abductor cruris caudalis	anterior caudal vertebra	crural fascia and tibia, with aponeurosis of biceps femoris	may serve as a tension sensor; effectiveness as extensor of thigh or flexor of crus is probably minimal
Tibialis cranialis/anterior	proximolateral surface of tibia and proximomedial surface of fibula	metatarsal 1	flexes pes
Tibialis caudalis/posterior	proximal end of tibia and fibula	navicular and intermediate cuneiform (tarsals)	extends pes
Vastus intermedius Vastus lateralis	anterior surface of femur greater trochanter and dorsolateral surface of femur	patella (capsule of knee joint) lateral surface of patella	extends crus extends crus
Vastus medialis	shaft of femur	medial surface of patella (and patellar ligament)	extends crus



**FIGURE 7.26** Diagrams showing incision lines to be followed in skinning the cat.

attached ventrally on one side of the chest, abdomen, and groin. For example, if your first longitudinal incision is on the right side of the middorsal line, then you will skin mainly the left side of the body, skinning the left arm and leg, and leaving the skin attached on the right side of the ventral surface of the cat. It does not matter which side of the body you choose to skin. However, avoid skinning a side if it has been damaged or had skin removed to facilitate injection of vessels. For example, in most specimens the skin on one side of the throat will probably have been removed and the musculature damaged when the arteries and veins

were injected. Sometimes, an area in the abdomen will have been skinned and cut to inject the hepatic portal system.

You need not make all the incisions before you begin skinning. Using a new scalpel blade, make a shallow longitudinal incision along the back, about 1 cm to one side of the neural processes of the vertebrae. As you cut, ensure that you have cut only through the skin by reflecting the edge of the flap. Extend the cut from near the base of the tail forward onto the back, neck, and head past the pinnae. At about the level of the eyes, make a sideways incision toward the other side eye (that is, cut back across and past the middorsal line), angling the incision toward the back of the eye. Continue to cut toward the back of the mouth and onto the underside of the lower jaw. Follow around the mandible to the other side. Return to the base of the tail and extend the incision back across the midline, around and under the tail. Continue forward, anterior to and then around the external genitalia. Continue the incision to just past the midventral line. Make an encircling cut around the forelimb, about midway along the antebrachium. Do the same for the hind limb, just past the ankle. Then make another incision, on the lateral surface of the hind limb, between this encircling incision and the longitudinal incision on the back.

Skinning can be accomplished by various techniques. For much of the back, for example, the skin is often readily removed, and a blunt probe, forceps, or your fingers will do the job of tearing through the fibrous connective tissue. In other areas, the skin adheres more strongly, and requires a scalpel. When using a scalpel, hold the blade parallel with the surface of the body and use short strokes; often, simply nicking the connective tissue will suffice, especially if you pull the skin flap away from the body to tense the connective tissue. You will encounter small nerves and blood vessels passing to the skin. Cut through them. As you skin the trunk, you will notice thin and narrow bands of muscles that adhere to the underside of the skin. These bundles represent the cutaneous maximus, one of the cutaneous muscles, a large sheet that covers much of the trunk and is especially prominent ventrally and near the axilla (armpit). This muscle should be removed with the skin, except near the axilla. In this region, it adheres strongly to the shoulder muscles and should be cut.

In a pregnant or lactating female, the **mammary glands** (see page 217) will be large, flattened, glandular masses in the thoracic and abdominal regions, and should be removed with the skin. If your specimen is a male, be careful in skinning the groin region. A large wad of fat, which contains the **spermatic cords** (see page 216) that you will need to see later, lies beneath the skin in this region. Leave the wad of fat intact.



The skin on the neck and throat may be more difficult to remove. Dissect carefully so that you do not injure the vessels in the neck and throat. The skin of the head is very thick and difficult to remove. Use care so that you do not injure the various vessels, nerves, and ducts and the salivary glands that lie just below and beside the pinna. It is not worth trying to skin the pinna; simply cut through it, leaving a stump about 1 cm long. Another cutaneous muscle will be found over much of the head and neck. Remove it with the skin.

In skinning the arm and leg, tear the connective tissue with a probe or forceps to separate the skin and muscles, but try not to tear the skin itself. Proceed from both the trunk down the limb as well as from the encircling cut up the limb. The skin may adhere closely to the muscles. Dissect especially carefully along the anterolateral surface of the brachium. The **cephalic vein** (see Figure 7.27) lies here and should not be removed with the skin.

## Appendicular Musculature

Much of the musculature that you will dissect includes the appendicular muscles, i.e., those associated with the forelimb and hind limb. Thus, if either or both ends of a muscle attach to the scapula (or pelvis) or more distal limb element, it can be considered an appendicular muscle. These muscles will be organized into superficial and deep portions and will be observed with the cat positioned so as to give you lateral and ventral views of its body.

### *Muscles of the Forelimb*

Table 7.2 lists the forelimb musculature and indicates their origin, insertion, and main functions.

#### Superficial Forelimb Muscles: Lateral View (Figure 7.27)

Examine the cat in lateral view. Identify the large, white **lumbodorsal fascia** covering the back in the lumbar region. The fascia is actually composed of two main sheets of tough connective tissue, one above the other. The **latissimus dorsi** is the wide muscle that originates mainly from the lateral margin of the fascia. Its fibers pass anteroventrally and converge toward the axillary region. It pulls the humerus posterodorsally. The muscle emerging from under the latissimus dorsi and extending onto the abdomen is the **external oblique** (see below).

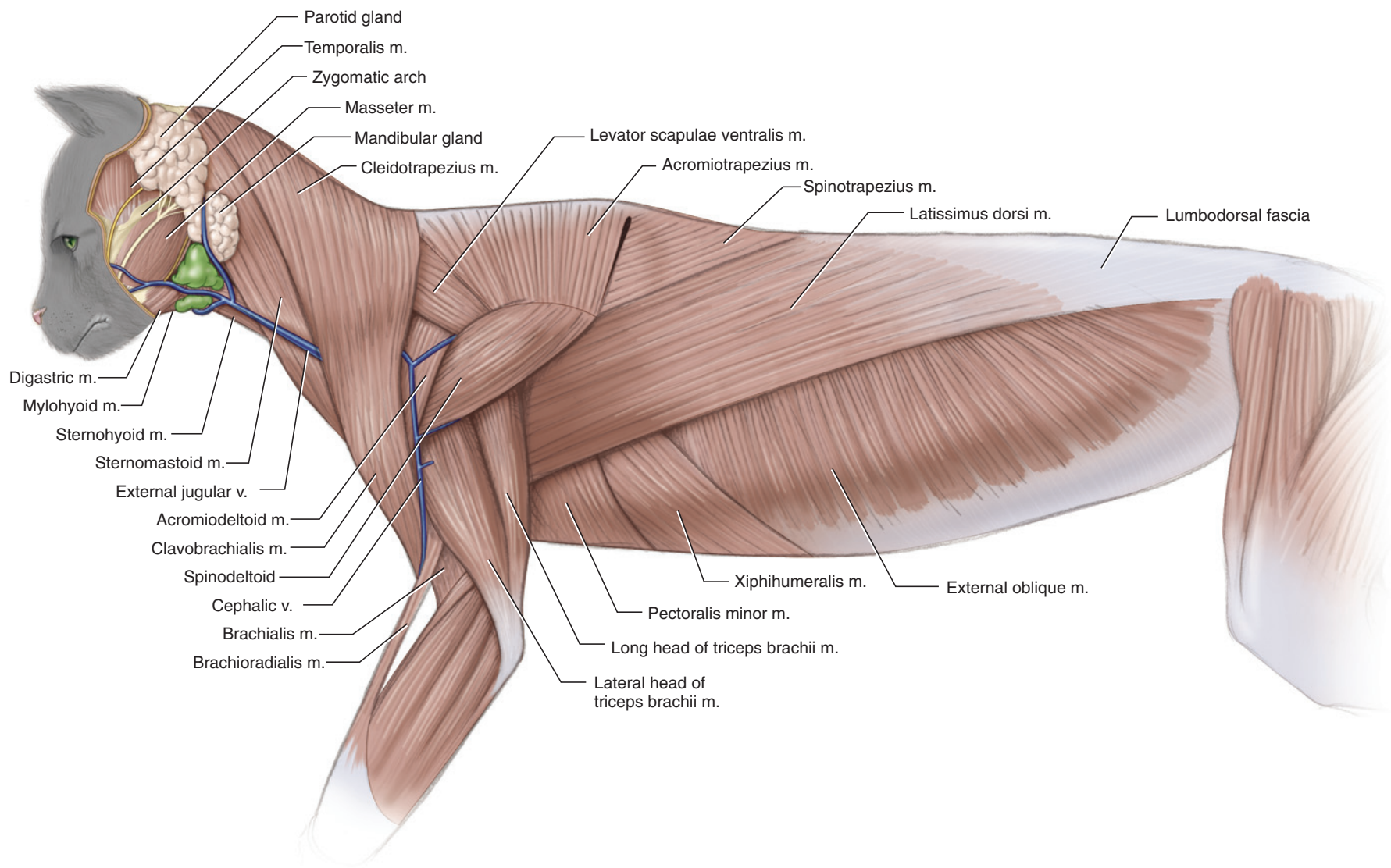
Anterior to the latissimus dorsi are three trapezius muscles. The most posterior is the triangular **spino-trapezius**, which draws the scapula posterodorsally. From their middorsal origin, the fibers of the spino-trapezius pass anteroventrally and converge toward the scapular spine. Next anteriorly is the **acromiotrapezius**. It is wider, but very thin. Its fibers fan out from their

insertion along the scapular spine toward the middorsal line, but do not extend all the way to the middorsal line. Instead, they attach to a thin aponeurosis. The acromiotrapezius can stabilize the scapula or pull it toward the dorsal midline. The most anterior trapezius muscle is the **clavotrapezius**, which covers most of the neck laterally and pulls the scapula anterodorsally. It is a wide muscle that originates from the neck middorsally, extending from just behind the skull to the acromiotrapezius. Its fibers pass almost directly ventrally toward the front of the shoulder. In mammals with a well-developed clavicle, the clavotrapezius inserts on the clavicle. As the clavicle is greatly reduced in the cat, however, the clavotrapezius inserts partly on the clavicle and partly onto another muscle, the **clavobrachialis**, which continues ventrally to insert on the ulna. Actually, a raphe (a narrow band of collagen fibers to which muscle fibers may attach), as well as the clavicle, separates these muscles; as their fibers appear to be continuous across the raphe, they seem to form a single muscle. The clavicle is embedded in the musculature but may be discerned by palpation (see below).

The **sternomastoid** lies anterior to the clavotrapezius. It is not an appendicular muscle, but should be identified at this point. It extends from the mastoid process of the skull (see Section I), just posterior to the ear, along the anterior margin of the clavotrapezius, but then veers medially to insert on the sternum. The sternomastoid will be considered again below. For now, note the **parotid** and **mandibular glands**, also considered in detail later, that lie on its anterior part, and that the muscle is crossed by the large **external jugular vein**.

Examine the musculature of the shoulder and forelimb in lateral view. The **cephalic vein** lies on the anterolateral surface of the brachium. The **spinodeltoid** muscle extends anteroventrally from the scapular spine, arising at the insertion of the acromiotrapezius. Its anterior end passes deep to the triangular **acromiodeltoid**. These muscles are flexors and lateral rotators of the humerus. The narrow **levator scapulae ventralis**, lying dorsal to the acromiodeltoid, extends anterodorsally and then passes deep to the posterior margin of the clavotrapezius. The **long head** of the **triceps brachii** covers the brachium posteriorly, while the **lateral head** of the triceps covers the brachium laterally. Separate the edge of the spinodeltoid from the triceps and note that these heads extend proximally, deep to the spinodeltoid. The **medial head** of the triceps is discussed below. All three heads insert on the olecranon process of the humerus and extend the antebrachium.

Note again the position of the cephalic vein. Distally, it crosses the clavobrachialis, whereas proximally it lies on the acromiodeltoid, and then curves anteriorly, deep to the clavotrapezius. Lift the posterior margin of the



**FIGURE 7.27** Muscles of the cat in lateral view.

clavotrapezius, just anterior to the acromiodeltoid, and cut through the connective tissue, fat, and nerves that you encounter. Continue to separate this muscle and the clavobrachialis from the underlying musculature. As you do so, you will see the posteriorly oriented fibers of the pectoral muscles (see below) inserting on the humerus.

Working dorsally, continue to separate the clavotrapezius, where the levator scapulae ventralis passes deep to its margin. It is fairly easy to free the muscle here, but work carefully anterior to the acromiodeltoid. The clavicle is present in this region, and you should avoid injuring the **cleidomastoid** (Figure 7.28), which attaches on the clavicle. Palpate for the clavicle. Once you identify its position, stop dissecting the clavotrapezius.

### Superficial Forelimb Muscles: Ventral View (Figure 7.28)

The pectoralis muscles, which draw the humerus toward the midventral line, lie superficially on the ventral surface of the thorax. Examine them in ventral view with the brachium held laterally. As a whole, this musculature is a triangular mass extending, on each side, from the ventral midline to the humerus. Carefully pick away at and clear connective tissue covering the muscles on one side to reveal four muscles. Once cleared, they can readily be distinguished by fiber direction. For the most part, the individual muscles are arranged in layers, one atop the other, and tend to adhere strongly to each other. Thus, do not attempt to separate the muscles by cutting them at their margins. Instead, work with a probe and needle to separate the muscles parallel to their surfaces. You do not need to separate each muscle completely; only go far enough to get an idea of the depth and extent of each.

The most superficial muscle is the **pectoantebrachialis**, a thin, narrow, anterior muscle that extends laterally. The **epitrochlearis** (which is not one of the pectorals) is a thin muscle covering the surface of the brachium posterior to the pectoantebrachialis. The epitrochlearis attaches to the olecranon of the ulna and thus extends the antebrachium. The **pectoralis major**, which may be subdivided in two portions, lies dorsal to the latter. The more anterior part extends laterally and is covered almost entirely by the pectoantebrachialis (except for its anteriormost part, which is exposed in ventral view). The posterior part of the pectoralis major runs obliquely, with its fibers passing anterolaterally from the midline.

The **pectoralis minor** is the muscle lying dorsal and posterior to the pectoralis major. The pectoralis minor of the cat is larger than the pectoralis major, but the names are derived from human terminology, in which the pectoralis major is indeed larger. The fibers of the pectoralis

minor run even more obliquely than those of the major as they converge toward the proximal half of the humerus. The fourth muscle is the **xiphohumeralis**, a long, thin, and narrow muscle that lies posterior and dorsal to the pectoralis minor. For the most part, the xiphohumeralis lies along the the pectoralis minor posteriorly and attaches to the xiphisternum and xiphoid cartilage, which give it part of its name.

You have already noted how the fibers of the latissimus dorsi converge toward the axilla. Also note that the latissimus dorsi and the pectoralis minor adhere to one another. Carefully separate these muscles by picking away at the connective tissue that binds them, using a needle and forceps. If necessary, use a scalpel to cut them apart.

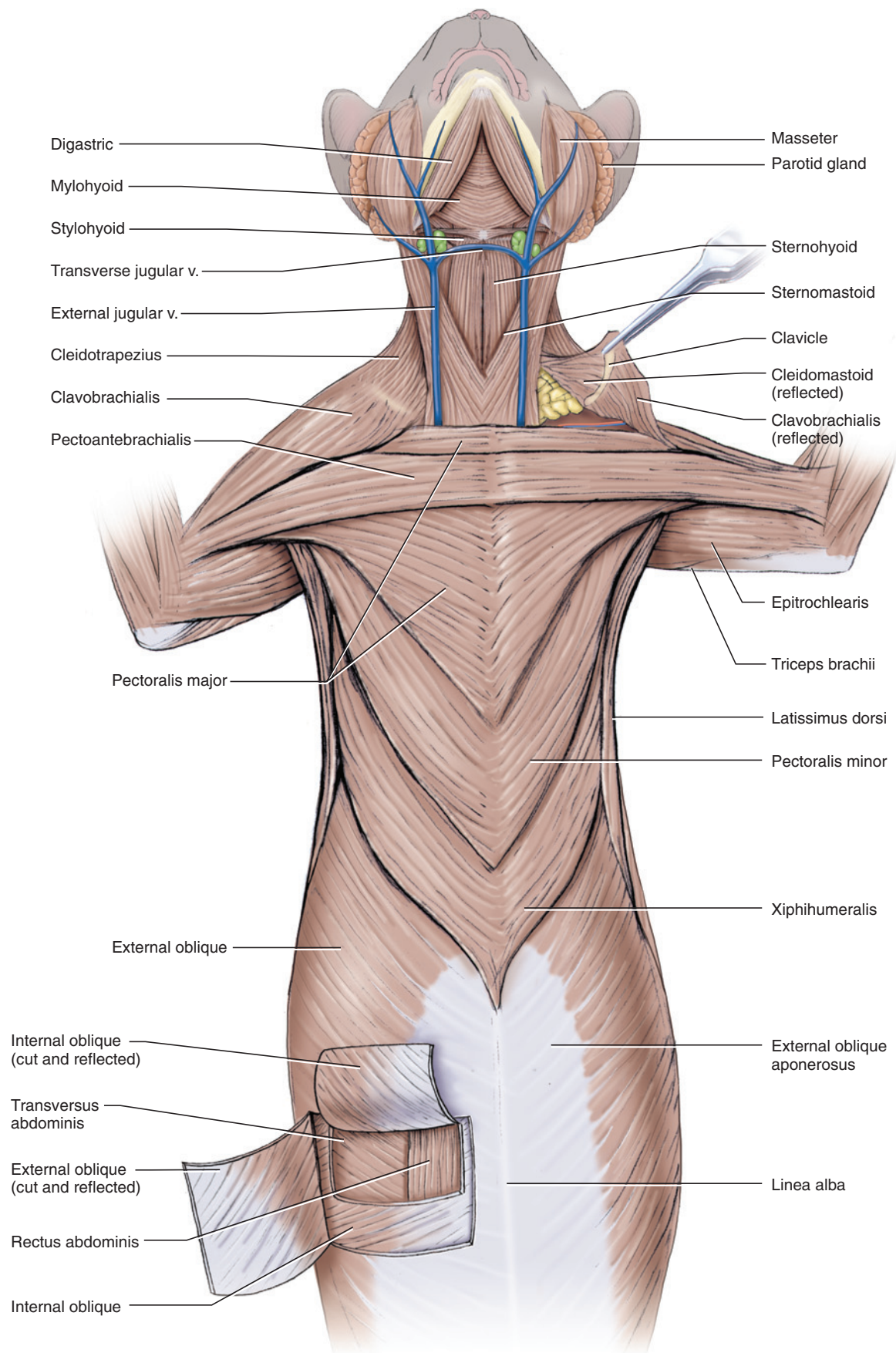
Identify the medial edge of the clavotrapezius along the neck and follow it posteriorly until it abuts against the anterior margin of the pectoral (Figure 7.28). From about this point, the muscle becomes the clavobrachialis, and its margin is bound tightly to the pectoralis major. Beginning medially, separate these muscles. You will soon be able to lift the clavobrachialis and discern the deeper part of the pectoralis, which passes diagonally beneath the clavobrachialis. You should now be able to separate the latter from the pectoralis much more easily.

Return to the medial margin of the clavotrapezius. Lift and separate it from the underlying musculature. You will uncover the cleidomastoid, mentioned above, which passes from the clavicle toward the skull. Probe deep to the sternomastoid to discern its course. Separate as much of the cleidomastoid from the clavotrapezius as possible, but work delicately near the clavicle: These muscles attach to the clavicle in close proximity, and dissection often causes damage. Continue to pick away the fat and tough connective tissue along the medial margin of the clavotrapezius, being careful not to injure the external jugular vein. Also work deep and medial to the cleidomastoid. You should be able to separate and lift the clavotrapezius, clavobrachialis, and cleidomastoid as a unit from the underlying muscles. Clean the connective tissue and fat from the bend of the elbow, being careful not to injure the cephalic vein or the slender **brachioradialis** (Figure 7.27), which supinates the manus, that lies along its anterior edge.

### Deep Forelimb Muscles: Lateral View (Figure 7.29)

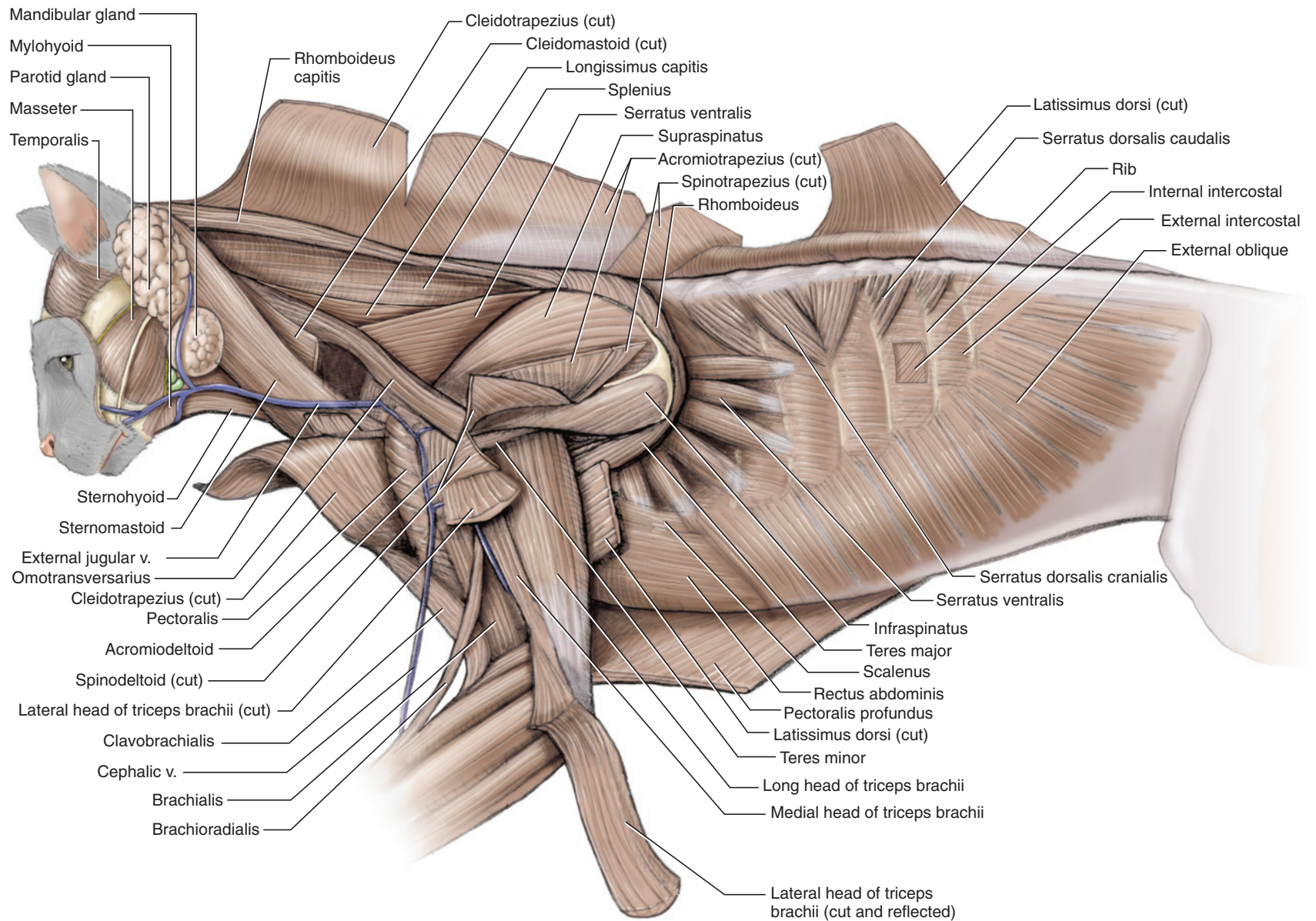
Return to the levator scapulae ventralis. Remove the fat between it and the clavotrapezius, clean away the connective tissue that covers it (i.e., the part deep to the clavotrapezius), and follow it anteriorly as it passes from the scapula toward the skull. Clean away connective tissue deep to the levator and separate it from the underlying muscles. Once you have isolated the levator, you should easily be able to remove fat and connective





**FIGURE 7.28** Muscles of the cat in ventral view.





**FIGURE 7.29** Deeper muscles of the cat in lateral view.

tissue from the anterior margin of the acromiotrapezius and free the muscle from the underlying musculature. Continue posteriorly and separate the spinotrapezius from the underlying muscles. Then cut through the middle of the trapezius muscles, at right angles to the fibers, and reflect their ends.

Examine the anterior part of the latissimus dorsi beneath the spinotrapezius, and then cut the latissimus about 3 cm posterior to the brachium and reflect it. Clean off the connective tissue from the underlying musculature. Examine the muscles on the lateral surface of the scapula. The **supraspinatus** fills the supraspinous fossa, while the **infraspinatus** occupies the infraspinous fossa. These muscles insert on the greater tuberosity of the humerus. The supraspinatus extends the humerus, while the infraspinatus rotates it laterally. The **teres major** arises from the scapula, posteroventral to the infraspinatus. It inserts medially on the humerus, flexing and medially rotating it. Follow the long head of the triceps as it passes deep to the spinodeltoid and infraspinatus and find the **teres minor**, which flexes and laterally rotates the humerus. It lies along the anteroventral margin of the infraspinatus, from which it is initially difficult to distinguish. In Figure 7.29 the spinodeltoid is shown as cut and reflected to expose the teres minor, but it is not necessary to cut the spinodeltoid.

Pull the dorsal border of the scapula laterally and examine the muscles in dorsal view. The fibers of the **rhomboideus** extend anteromedially between the dorsal border of the scapula and the middorsal line. This muscle pulls the scapula toward the vertebral column. The **rhomboideus capitis**, extending separately as a narrow band toward the back of the skull, rotates and pulls the scapula anteriorly. The rhomboideus capitis lies on the surface of the **splenius** (see below), a large, flat muscle covering the neck dorsolaterally. Look ventral to the rhomboideus and note the **serratus ventralis**. It is the large muscle composed from various slips that extend between the scapula and thorax. The slips arise from the ribs and converge to insert on the vertebral border of the scapula. The serratus ventralis will be considered again below.

### Deep Forelimb Muscles: Lateral View with Forelimb Abducted (Figure 7.30)

Earlier, the latissimus dorsi was separated from the pectoralis minor. Now separate the latissimus dorsi from the lateral thoracic wall. You will find considerable fat and connective tissue adhering to the muscle. Remove the fat and connective tissue, but do not injure the blood vessels and nerves in the axilla. At first the shoulder region will not be apparent, but it can be palpated. As you pick away tissue, the scapula and its associated musculature will come into view. When you have

cleaned the musculature associated with the scapula, pull the scapula laterally to see a series of strap-like muscular slips fanning out to the thorax from the scapula. These slips are part of the serratus ventralis.

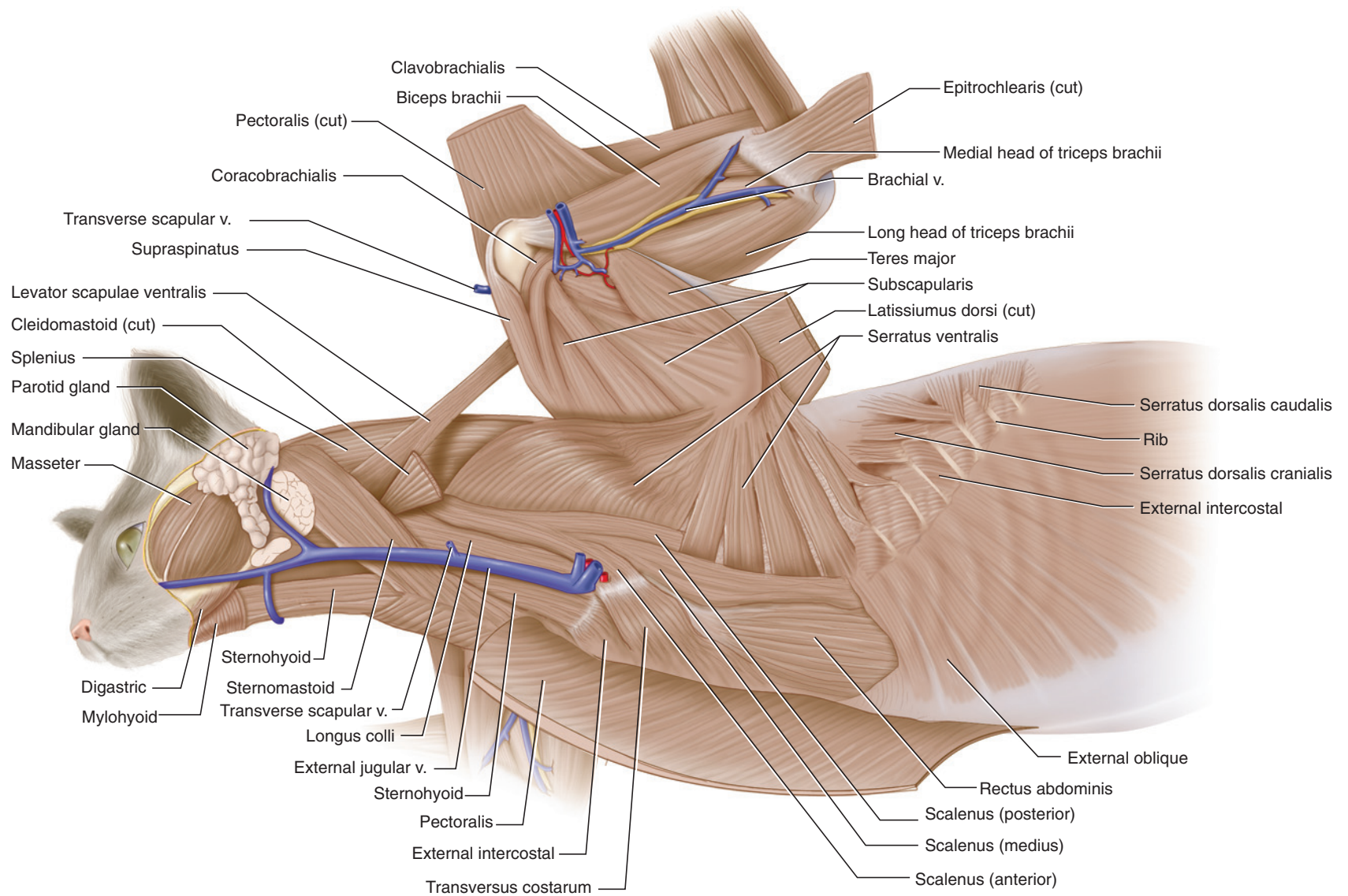
Using scissors and beginning posteriorly, make an anteroposterior cut through the pectoralis muscles about 1 cm to one side of the midline. Work your way first through the xiphihumeralis and pectoralis minor. As you do so, lift the musculature and clean away connective tissue beneath it to ascertain that you are cutting through pectoralis musculature only. As you approach the pectoantebrachialis, lift the musculature and look for vessels and nerves passing out of the thorax and toward the shoulder. They may be embedded in some fat. Do not injure the vessels or nerves. The most apparent vessel is the **axillary vein**, a large vein injected with blue latex. It is accompanied by the axillary artery. These vessels quickly branch into various smaller vessels. The various large nerves are part of the brachial plexus.

Continue cutting through the pectoralis major and then reflect the flaps, removing the connective tissue that binds the xiphihumeralis and pectoralis minor to the thorax, so that you can reflect the pectoral musculature completely away from the thoracic wall. Then delicately clean away connective tissue and fat from around the vessels and nerves. The nerves appear as shiny, whitish strands (some rather large) passing toward the shoulder and brachium. Most lie dorsal to the vessels, but some are anterior to them.

If the musculature has been properly cleaned, it should be easy to follow the external jugular vein posteriorly. At the level of the anterior part of the shoulder, it receives a large tributary, the **transverse scapular vein** (possibly already cut). The external jugular continues posteriorly to join the subclavian as it emerges from the thorax and changes its name to the **axillary**. When you have identified these vessels, which continue onto the forelimb, cut through the vessels as well as nerves, leaving stumps about 1 cm long emerging from the thorax.

Position the brachium as shown in Figure 7.30, and continue cleaning the medial surface of the shoulder as well as the thoracic wall. Also, pick away connective tissue surrounding the vessels as they enter the shoulder musculature. Reidentify the latissimus dorsi, pectoralis muscles, and the serratus ventralis. Note how the fan-like arrangement of the serratus ventralis converges toward the dorsal border of the scapula. Note too that the posterior part of this muscle is clearly subdivided into separate slips, but its anterior fibers are arranged nearly as a continuous sheet.





**FIGURE 7.30** Deeper muscles of the cat in lateral view, with forelimb abducted.

The large muscle covering the medial surface of the scapula is the **subscapularis**. The fibers of its various bundles converge toward the apex of the scapula and insert on the lesser tuberosity of the humerus. It is an adductor of the humerus. The **teres major** initially appears as one of these bundles passing along the posterior border of the scapula. Anteriorly, however, the separation is much clearer: Note how some of the vessels pass between the subscapularis and **teres major**. Carefully observe the muscles that cover the ventromedial region of the scapula. Most of the fibers belong to the subscapularis and converge toward the apex, but the small, strap-like **coracobrachialis**, about 0.5 cm in width, crosses against the direction of the fibers. It also adducts the humerus. In this view, the coracobrachialis lies just posterior to the origin of the **biceps brachii** (see below).

Examine the medial surface of the brachium. Cut through the epitrochlearis and the pectoral musculature (mainly pectoantibrachialis) covering the brachium, and reflect the ends to expose the muscles on the brachium. Clear the connective tissue. A large vessel, the **brachial vein**, which is a continuation of the axillary vein, should be prominently exposed. Dissect carefully near it to reveal the **brachial artery** (continuing from the axillary artery) and several nerves from the brachial plexus. The large muscle anterior to the vessels and nerves is the **biceps brachii**, and the muscle that lies posteriorly is the long head of the **triceps**, which has already been observed in lateral view. Dissect dorsally to the vessels and nerves, and push them aside to expose the **medial head of the triceps**. Follow the **biceps brachii** proximally toward its origin on the scapula and reidentify the coracobrachialis. The **biceps** inserts distally on the radius and is a flexor of the antebrachium.

### KEY TERMS: MUSCLES OF THE FORELIMB

(See Table 7.2 for synonyms)

acromiodeltoid	external jugular vein
acromiotrapezius	external oblique
axillary vein	infraspinatus
biceps brachii	latissimus dorsi
brachial artery	levator scapulae
brachial vein	ventralis
brachioradialis	lumbodorsal fascia
cephalic vein	mandibular gland
clavobrachialis	parotid gland
clavotrapezius	pectoantibrachialis
cleidomastoid	pectoralis major
coracobrachialis	pectoralis minor
epitrochlearis	rhomboideus

rhomboideus capitis	teres major
serratus ventralis	teres minor
spinodeltoid	transverse scapular vein
spinotrapezius	triceps brachii: lateral
splenius	head; long head;
sternomastoid	medial head
subscapularis	xiphohumeralis
supraspinatus	

### Muscles of the Hind Limb

Table 7.3 lists the hind limb musculature and indicates their origin, insertion, and main functions.

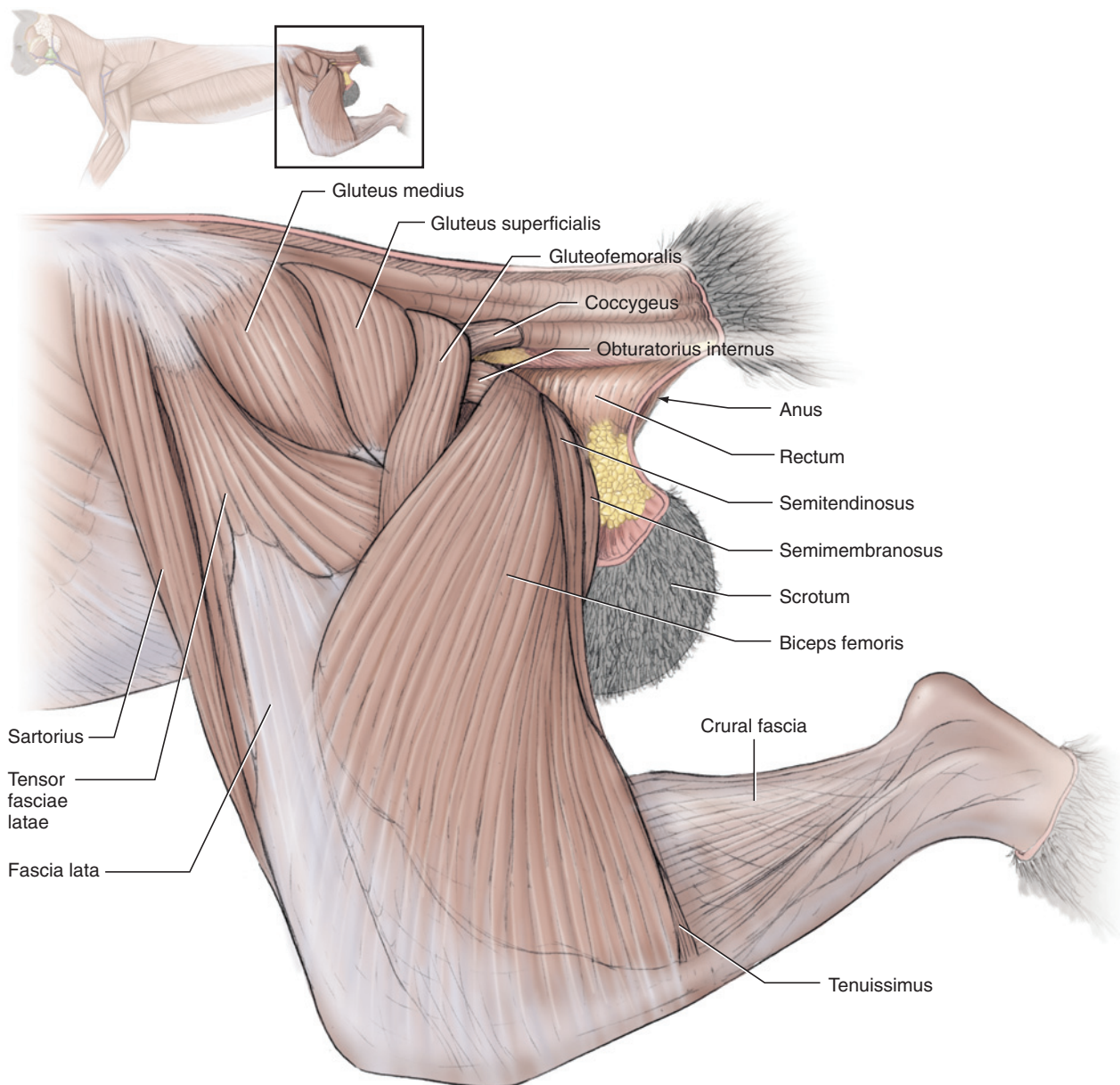
#### Superficial Hind Limb Muscles: Lateral View (Figure 7.31)

The skin of the hind limb has already been removed. Carefully pick away the connective tissue and fat on the lateral surface of the hind limb and the base of the tail, but take care not to injure the fascia that covers the musculature. Considerable fat is present in the popliteal fossa, the depression posterior to the knee joint. Carefully clear this region. You may notice the oval popliteal lymph node, which is embedded within the fat.

Examine the musculature. The most conspicuous muscle of the thigh is the **biceps femoris**. This large muscle covers much of the posterior half of the thigh and is a main adductor and extensor of the thigh. It has a narrow origin dorsally from the ischial tuberosity but widens distally to insert by an aponeurosis on the patella and the proximal portion of the tibia. The posterior portions of two deeper muscles, the **semitendinosus** and **semimembranosus**, are exposed posterior to the dorsal part of the biceps femoris.

Next, identify the **sartorius**, which lies along the anterior edge of the thigh. In lateral view this muscle appears to be elongated and narrow, but its more extensive medial portion will be seen shortly. Posterior to the dorsal portion of the sartorius is the **gluteus medius**, which is covered by fascia. Carefully remove the fascia to uncover the muscle, as shown in Figure 7.31. Posterior to it is the smaller **gluteus superficialis**, followed by the **gluteofemoralis**. The latter is a strap-like muscle that continues distally, deep to the biceps femoris. The gluteal musculature generally functions in abducting the thigh. Extending between the origin of the biceps femoris and the posterior margin of the gluteofemoralis, identify the **obturatorius internus**. Dorsal to it, extending from beneath the posterodorsal margin of the gluteofemoralis to the ventral surface of the tail, is the **coccygeus**.





**FIGURE 7.31** Superficial muscles of the hind limb of the cat in lateral view.

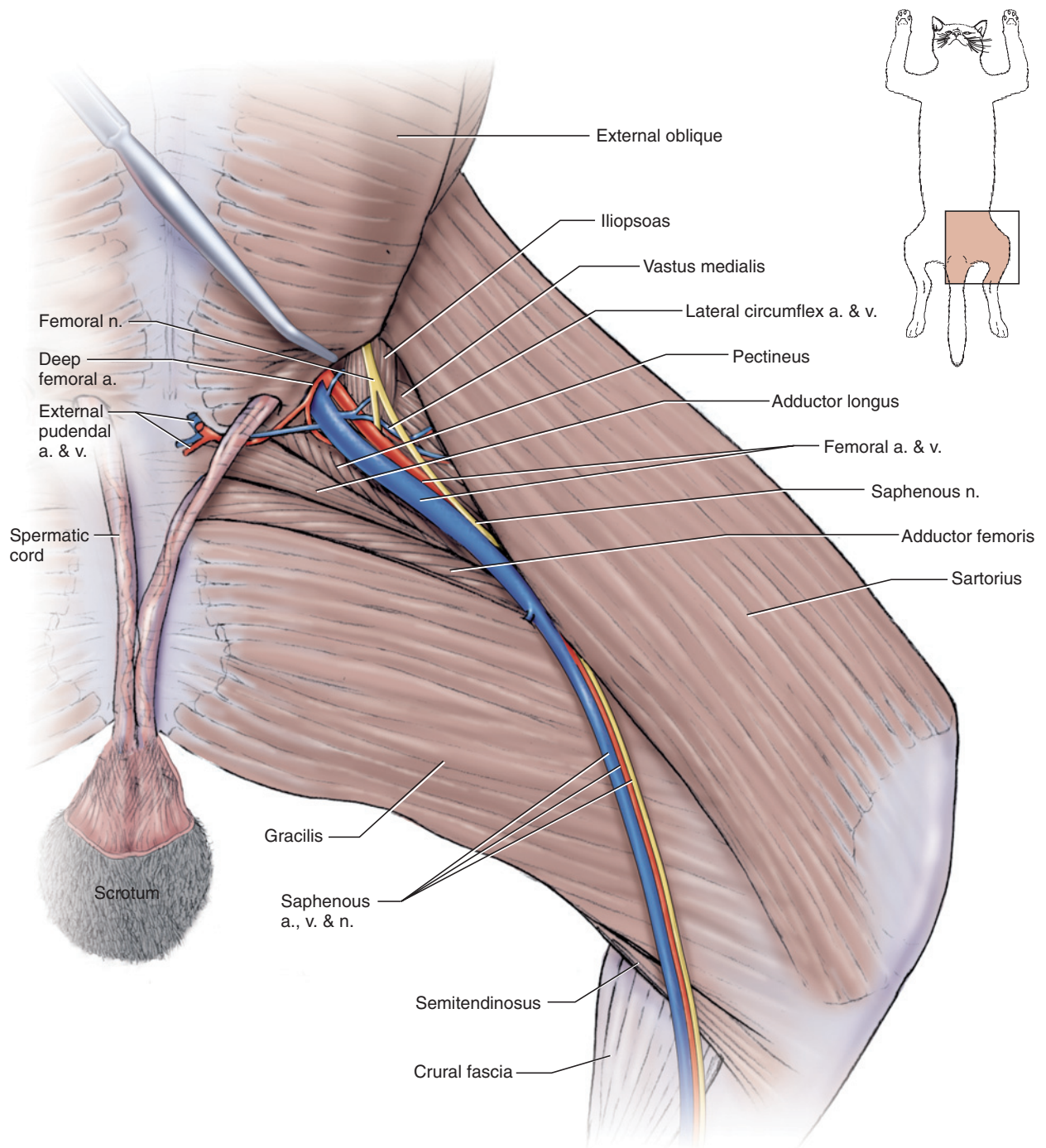
The **tensor fasciae latae**, a flexor of the thigh, is ventral to the gluteal musculature noted above. From its narrow dorsal origin, it fans out distally and inserts on the **fascia lata**, the tough membrane that extends toward the knee joint, anterior to the biceps femoris. The tensor fasciae latae is subdivided into a longer anterior portion and a triangular posterior portion. Trace the anterior portion as it extends deep to the sartorius and onto the anterior surface of the thigh.

The **tenuissimus** is a ribbon-like muscle that lies almost entirely deep to the biceps femoris. It will be exposed presently. Its very distal end, however, is exposed in lateral view along the posterodistal edge of the biceps femoris. Look for this exposed portion. It inserts by a

short tendon that merges with that of the biceps femoris. When you have identified it, lift the posterior edge of the biceps femoris and gently scrape the loose connective tissue adhering to its deep surface to locate the rest of the tenuissimus. It extends dorsally and passes deep to the very dorsal portion of the gluteofemoralis (see Figure 7.33). It may serve as an extensor of the thigh or flexor of the crus, but its composition (a high number of muscle spindles) as well as size suggest that it may function as a tension sensor.

### Superficial Hind Limb Muscles: Medial View (Figure 7.32)

Clear away connective tissue from the medial surface of the thigh, but leave the crural fascia for the time being.



**FIGURE 7.32** Superficial muscles of the hind limb of the cat in medial view.

Avoid damaging vessels and nerves. Note again the wad of fat that lies between the body wall and the proximal surface of the thigh. In males the spermatic cords extend through this wad as they pass from the body wall to the testes. Dissect carefully to avoid injuring the spermatic cords. They are shown as having been dissected out in Figure 7.32, but you do not need to expose them to the same extent.

Once the surface of the thigh has been cleared of connective tissue, the full extent of the sartorius, already observed in lateral view, may be appreciated. It covers the anteromedial surface of the thigh. The large muscle on the posteromedial surface is the **gracilis** muscle, which flexes the crus and adducts the thigh. The distal portion of the semitendinosus is exposed just posterior to the gracilis. Distally the sartorius and gracilis con-

verge and lie side by side, with the former partially covering the latter, as they extend toward the knee. Examine the triangular region formed between their proximal portions and the body wall. The **femoral artery** and **femoral vein** are the conspicuous vessels emerging from within the body cavity and extending distally. The small muscle just anterior (keep in mind that the limb is essentially parasagittal in position) to the very proximal end of these vessels is the **iliopsoas**, which flexes and rotates the thigh. The **femoral nerve** lies anterior to the femoral vessels and passes over the iliopsoas. Probe between the iliopsoas and sartorius to identify the **vastus medialis**, which will be exposed shortly. Posterior to the vessels is the **pectineus**, a small, triangular adductor of the thigh, followed by the larger **adductor longus**, and the much larger **adductor femoris**, much of which lies deep to the gracilis. The last two muscles are also adductors of the thigh (but see also Table 7.3).

Examine the vessels more closely. They will be discussed in more detail later, but it is worth noting the main branching patterns at this time. The femoral artery and vein are the main continuations of the **external iliac artery** and **external iliac vein**, which lie within the body cavity (see pages 204 and 205). The femoral artery and vein are therefore the most conspicuous vessels on the medial surface of the thigh. However, the external iliac vessels branch just as they approach the body wall. The external iliac artery gives rise to the femoral artery and the **deep femoral artery**, and the external iliac vein is formed by the confluence of the femoral vein and the **deep femoral vein**. It is these four vessels that perforate the body wall onto the thigh. As noted, the femoral vessels are easily observed, but the deep femoral vessels may also be identified. Pick away the body musculature adjacent to the femoral artery, working your way toward the abdominal midline. The much smaller deep femoral artery, extending posteromedially, will be exposed. In many individuals, one of its branches is the **external pudendal artery**, which extends medially into the wad of fat in the groin region to supply the external genitalia. The **external pudendal vein** follows the artery. In males the artery and vein pass dorsal to the spermatic cord. Follow the deep femoral artery, after the origin of the external pudendal artery, as it passes into the musculature. The deep femoral vein follows the artery but lies more deeply. Move the artery to expose the vein.

Return to the femoral artery and femoral vein. The **lateral circumflex artery** and the **lateral circumflex vein** branch from these vessels a short distance distally. Note the **saphenous nerve** that accompanies the vessels. More distally, nearer the knee, the **saphenous artery** and **saphenous vein** branch from the femoral vessels and extend distally on the surface of the crural fascia. The saphenous nerve accompanies them.

## Deep Hind Limb Muscles: Lateral View

(Figures 7.33–7.35)

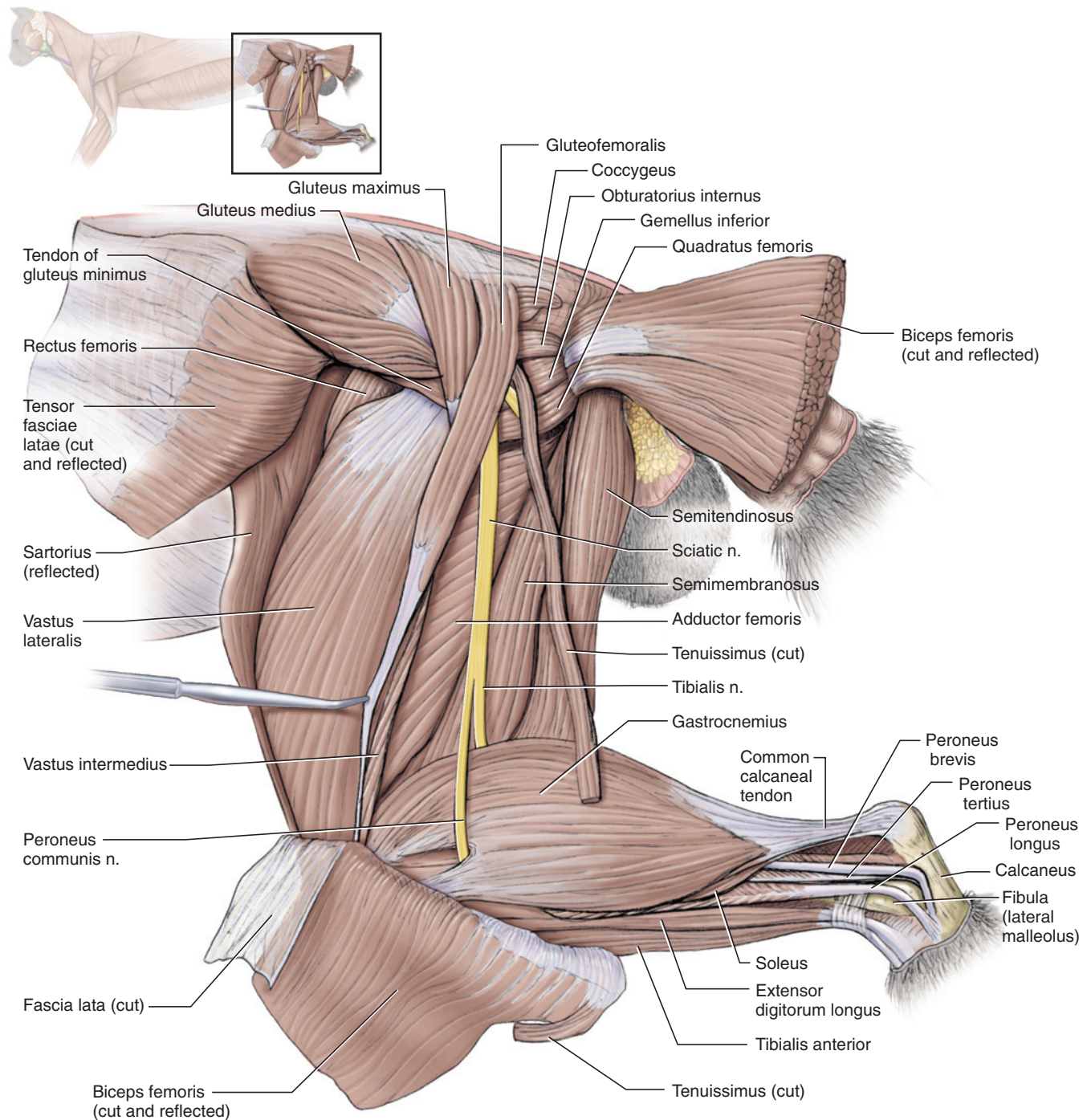
Examine the lateral surface of the thigh. Continue to scrape away the connective tissue and fat from between the deep surface of the biceps femoris (working from both its anterior and posterior margins) and the underlying musculature, and lift the biceps from the musculature. Make an anteroposterior cut through the central part of the biceps femoris and reflect its ends. The exposed surface must be cleared of connective tissue and fat to produce a dissection similar to that presented in Figure 7.33. Although this is tedious, it furnishes an excellent example of how connective tissue and fat are distributed between muscles, both to provide a plane along which muscles may move against each other and to provide protection for structures such as nerves. In clearing the region, preserve the conspicuous **ischiodic nerve** (Figure 7.34) but remove or cut through blood vessels.

The ischiadic nerve extends nearly parallel to the tenuissimus muscle. Note the distal end of the gluteofemoralis. Its fibers insert into a narrow, tapered tendon, which is nearly as long as the fleshy part of the muscle and extends toward the knee joint. The tendon may be distinguished most easily distally, where it lies on the posterior surface of the fascia lata, and appears as a narrow, glistening ribbon. Separate it from the fascia lata.

Reflection of the biceps femoris also exposes two muscles already identified above, the semitendinosus and, anterior to it, the semimembranosus. The **adductor femoris** lies anterior to the latter, deep to the ischiadic nerve. Just anterior to the origin of the biceps femoris and ventral to the obturatorius internus, identify the **gemellus caudalis** and the **quadratus femoris**.

Poke a small opening into the fascia lata, ventral to the level of the tensor fasciae latae. Insert a scissor blade into the opening, bisect the fascia anteroposteriorly, and lift it from the underlying muscle. Cut along the posterior edges of the fascia where it meets the adductor femoris (avoid cutting the tendon of the gluteofemoralis), and then reflect its flaps. The tensor fasciae latae will be reflected with the proximal flap of the fascia lata. The large muscle exposed is the **vastus lateralis**. Clear away connective tissue along the anterodorsal margin of this muscle to expose a portion of the **rectus femoris**. The tendon of the **gluteus profundus** (see below) should also be visible. The **vastus intermedius** has a small, narrow exposure along the posterodistal margin of the vastus lateralis. The vastus lateralis, vastus intermedius, vastus medialis (identified above, but see also below), and rectus femoris form the muscle complex termed the **quadriceps femoris**, which is the main musculature that extends the crus. The **capsularis**



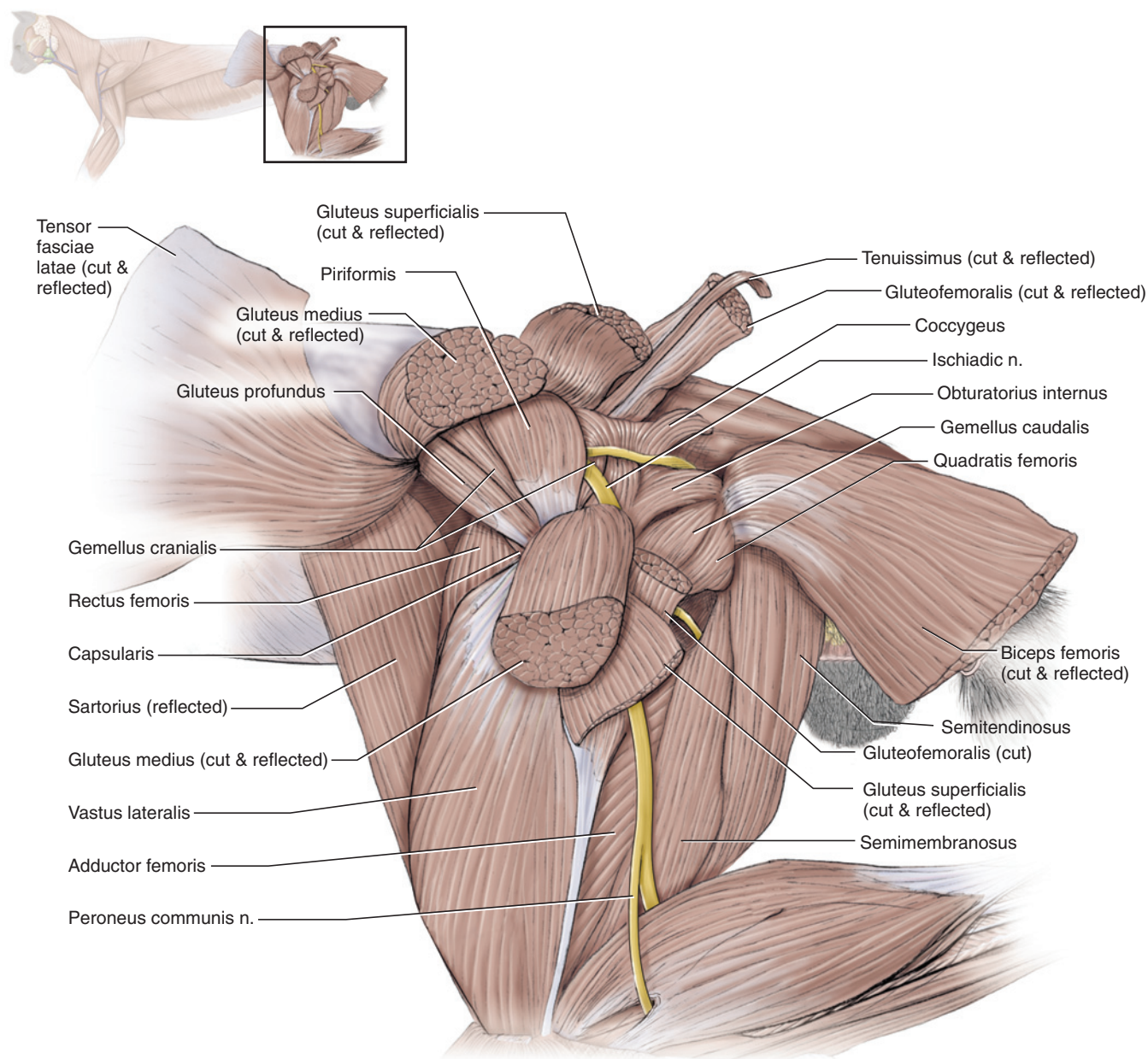


**FIGURE 7.33** Deep muscles of the hind limb of the cat in lateral view.

is a small, narrow muscle just anterior to the hip joint. It extends from the ilium to the anteroproximal surface of the femur. To locate it, probe between the origin of the vastus lateralis and the posteroventral margin of the gluteus profundus (Figure 7.34). Its small size and high proportion of muscle spindles suggest it functions as a tension sensor, although its position indicates a thigh flexor function.

Cut anteroposteriorly through the belly of the gluteofemoralis and reflect it, along with the tenuissimus. Free the gluteus maximus and gluteus medius muscles from underlying musculature. Cut anteroposteriorly through the center of each muscle and reflect them, as shown in Figure 7.34, to expose the underlying muscles. The gluteus minimus (noted above), with its conspicuous insertion tendon, is the more anterior. The





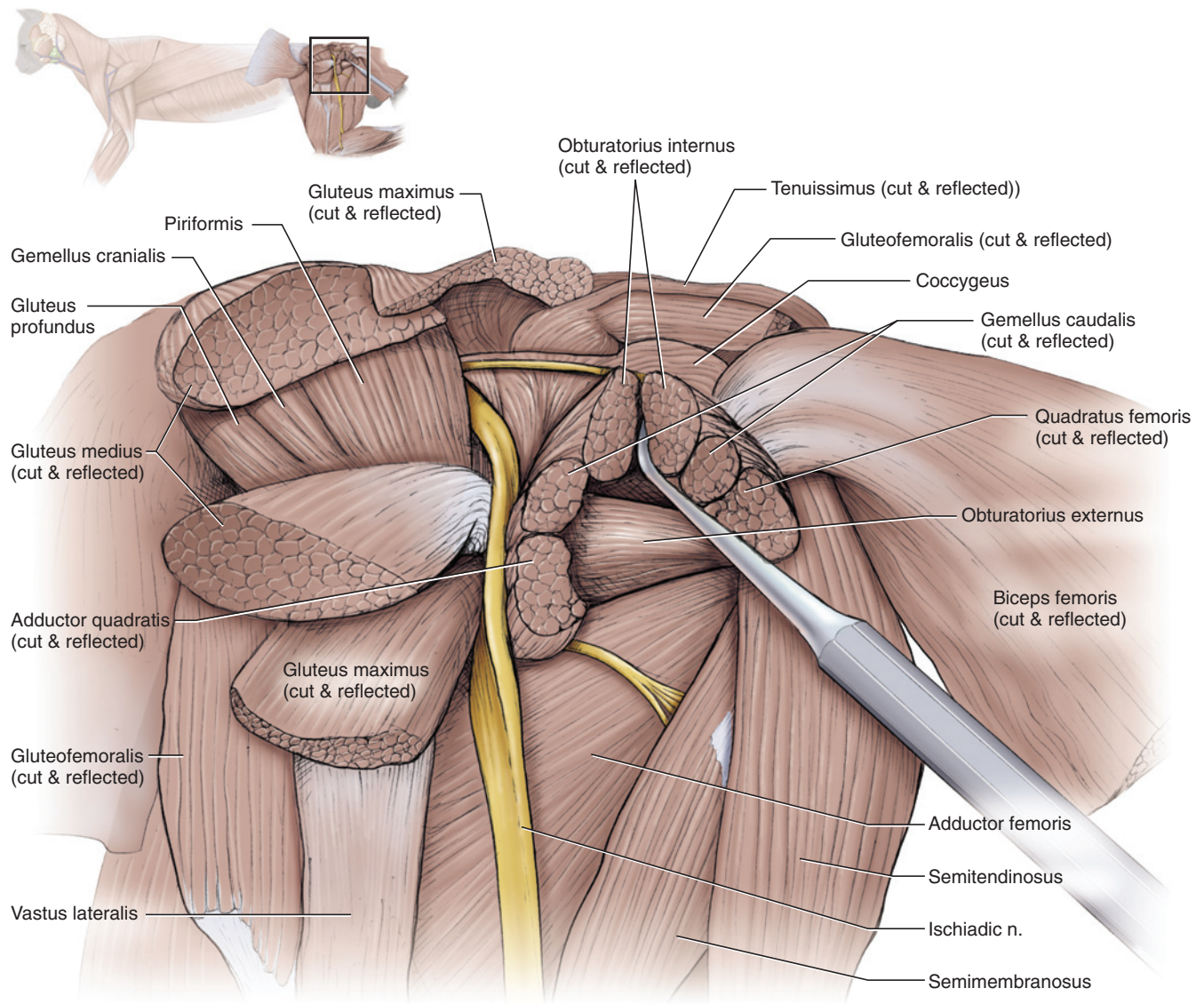
**FIGURE 7.34** Deep muscles of the hind limb of the cat in lateral view.

**piriformis** lies more posteriorly, and largely covers the **gemellus cranialis**, two muscles that act mainly to abduct the thigh.

Reflect the gluteofemoralis anteriorly, as shown in Figure 7.35. Carefully cut dorsoventrally through the middle of the quadratus femoris, but do not injure underlying musculature. Continue cutting dorsally through the gemellus caudalis and obturatorius internus. Reflect the ends of the muscles you have cut through to expose the **obturatorius externus**, which extends anteroposteriorly.

Examine the muscles on the lateral surface of the crus by removing the crural fascia (Figure 7.33). There are

actually several layers of fascia in the region, and they have been separated and partially cut away to produce the dissection in Figure 7.33, which preserves the insertions of the biceps femoris and tenuissimus. The most conspicuous muscle on the crus is the **gastrocnemius**, which lies posteriorly and has lateral and medial heads. Its proximal portion is very thick, but it tapers distally into its tendon, the gastrocnemius tendon. A smaller muscle, the **soleus**, lies mainly deep to the gastrocnemius, but a small portion is exposed anterior to it. It is also thick proximally and tapered distally. The tendons of the gastrocnemius and soleus muscles pass together through a sheath formed by the fascia as the **calcaneal tendon**, which inserts on the proximal end of the calcaneum. As their tendons converge, the soleus and gas-



**FIGURE 7.35** Deep muscles of the hind limb of the cat in lateral view.

trocnemius, which are the main extensors of the pes, are collectively termed the **triceps surae** muscle.

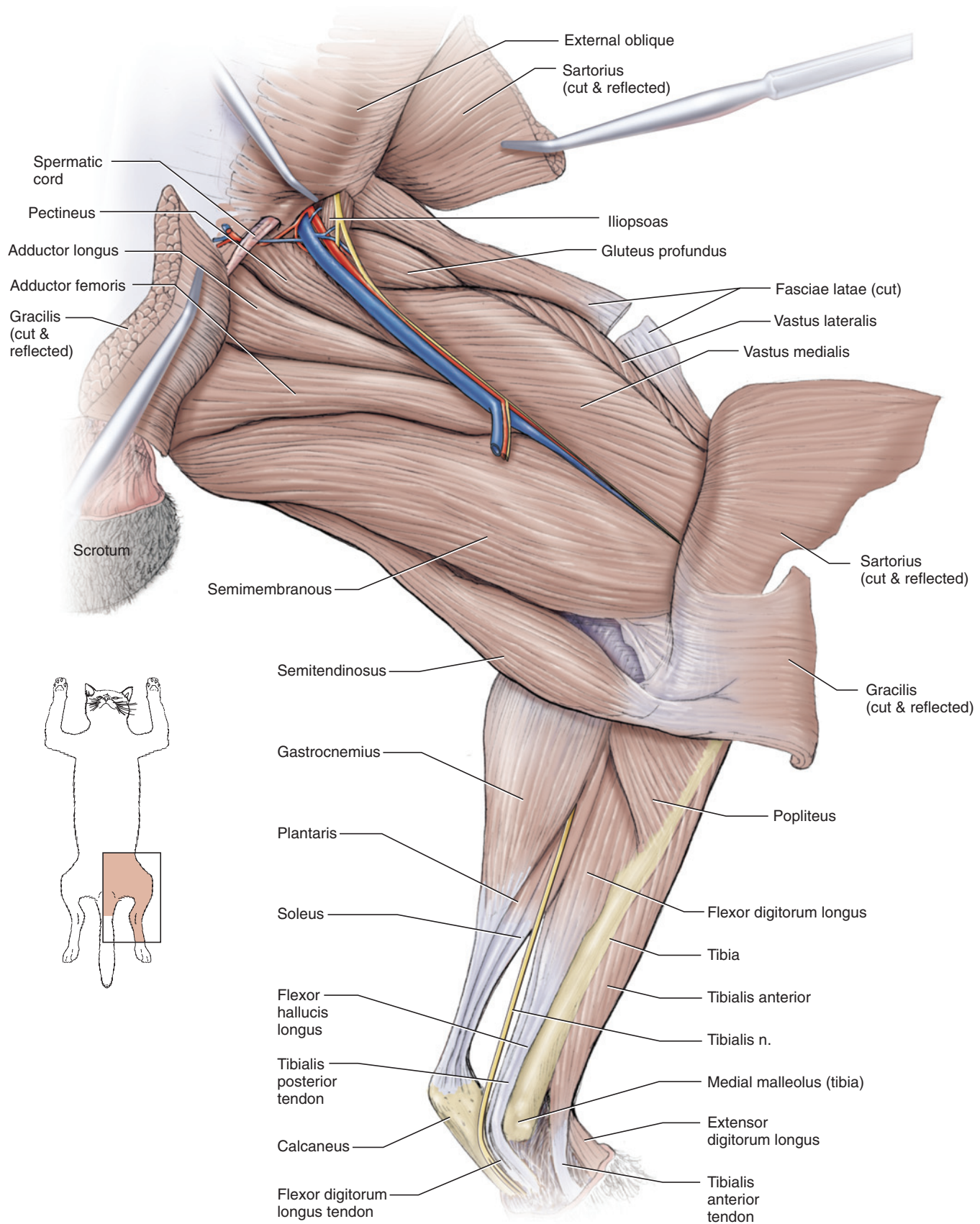
The **tibialis anterior** lies on the anterior surface of the crus. Posterior to it is the slender, elongated **extensor digitorum longus**. Follow the latter distally into its thick tendon on the dorsal surface of the pes. Between the extensor digitorum longus and the soleus is the peroneus musculature. A prominent nerve, the superficial peroneal nerve, lies between the extensor digitorum longus and the peroneus muscles. Three peroneus muscles may be recognized. The **peroneus longus** is an elongated muscle lying posterior to the extensor digitorum longus. Follow it distally as it tapers into its prominent tendon, which passes along a groove on the lateral surface of the lateral malleolus of the fibula (see page 149). The **peroneus tertius** is a smaller muscle posterior to the

peroneus longus. It may be difficult to isolate, but its narrow tendon lies posterior to the tendon of the peroneus longus. The **peroneus brevis** is larger and exposed posterior to the peroneus tertius. Its tendon is much larger and easily identified. The tendons of the peroneus tertius and peroneus brevis extend distally adjacent to each other, and both pass along a groove on the posterior surface of the lateral malleolus. As they pass distally, the tendon of the peroneus brevis obscures that of the peroneus tertius.

### Deep Hind Limb Muscles: Medial View (Figure 7.36)

Return to the medial surface of the hind limb. Lift the sartorius by separating it from underlying musculature. Cut across its central portion and reflect its ends. Do likewise for the gracilis. This will expose much of the





**FIGURE 7.36** Deep muscles of the hind limb of the cat in medial view.

musculature that has already been identified. Anteriorly, identify the vastus medialis. Much of its anterior margin is bordered by the rectus femoris. Recall that the tensor fasciae latae and fascia lata, which was cut earlier (as shown in Figures 7.35 and 7.36), lies on the vastus lateralis. More posteriorly, note the adductor femoris and semimembranosus, both now uncovered. The semitendinosus inserts on the tibia just distal to the insertion of the semimembranosus. The lateral-to-medial orientation of these last two muscles and their contribution to the medial wall of the popliteal fossa is easily appreciated.

Remove the crural fascia from the medial surface of the crus. Clear away connective tissue. The medial head of the gastrocnemius is the conspicuous muscle posteriorly. Probe deep to its anterior margin, where the gastrocnemius begins to taper distally, to locate the soleus, already observed in lateral view, and the **plantaris**, lying between the soleus and gastrocnemius. The tendon of the plantaris extends through the crural sheath with the calcaneal tendon. It continues around the proximal end of the calcaneum onto the plantar surface of the pes, and extends distally onto the digits. Here, the small flexor digitorum brevis muscle surrounds the tendon and contributes to flexion of the digits.

The large tibialis nerve emerges from beneath the musculature. Carefully dissect around the nerve to free it from surrounding structures, and follow it as it extends toward and then around the posterior margin of the medial malleolus of the tibia (see page 149). The medial surface of the tibia is the white strip of bone extending proximodistally near the anterior margin of the crus. On its anterior surface is the tibialis anterior, identified earlier. Follow it distally into its tendon and note that it extends medially across the proximal surface of the pes. Examine the musculature posterior to the tibia. Near the insertion of the semitendinosus, locate the **popliteus**, consisting of a faint, thin band of fibers extending posterodorsally from the tibia. The popliteus, which flexes the crus and rotates the tibia medially, curves laterally and crosses the posterior side of the knee joint to its origin on the lateral epicondyle of the femur. The **flexor digitorum longus** is the larger mass of musculature just posterior to the tibia. Follow it distally. Its tendon is nearly parallel and anterior to the tibialis nerve, and is of similar thickness. The tendon curves around the posterior margin of the medial malleolus onto the medial surface of the pes. Anterior to the tendon of the flexor digitorum longus is the thicker tendon of the **tibialis posterior** muscle. It also curves around the malleolus onto the medial surface of the pes. The fibers of the tibialis posterior lie almost entirely deep to the flexor digitorum longus. You may cut through the latter to expose the tibialis posterior.

## KEY TERMS: MUSCLES OF THE HIND LIMB

<b>adductor femoris</b>	<b>obturatorius externus</b>
<b>adductor longus</b> (adductor femoris longus)	<b>obturatorius internus</b>
<b>biceps femoris</b>	<b>pectineus</b>
<b>calcaneal tendon</b> (Achilles tendon)	<b>peroneus brevis</b> (fibularis brevis)
<b>capsularis</b> (articularis coxae)	<b>peroneus longus</b> (fibularis longus)
<b>coccygeus</b> (abductor caudae internus)	<b>peroneus tertius</b> (extensor digitorum lateralis)
<b>deep femoral artery</b>	<b>piriformis</b> (pyriformis)
<b>deep femoral vein</b>	<b>plantaris</b> (flexor digitorum superficialis)
<b>extensor digitorum longus</b>	<b>popliteus</b>
<b>external iliac artery</b>	<b>quadratus femoris</b>
<b>external iliac vein</b>	<b>quadriceps femoris</b> (= rectus femoris + vastus intermedius + vastus lateralis + vastus medialis)
<b>external pudendal artery</b>	<b>rectus femoris</b>
<b>external pudendal vein</b>	<b>saphenous artery</b>
<b>fascia lata</b>	<b>saphenous nerve</b>
<b>femoral artery</b>	<b>saphenous vein</b>
<b>femoral nerve</b>	<b>sartorius</b>
<b>femoral vein</b>	<b>semimembranosus</b>
<b>flexor digitorum longus</b>	<b>semitendinosus</b>
<b>gastrocnemius</b>	<b>soleus</b>
<b>gemellus caudalis</b> (gemellus inferior)	<b>tensor fasciae latae</b>
<b>gemellus cranialis</b> (gemellus superior)	<b>tenuissimus</b> (abductor cruris caudalis)
<b>gluteofemoralis</b> (caudofemoralis, coccygeofemoralis, gluteobiceps)	<b>tibialis anterior</b> (tibialis cranialis)
<b>gluteus medius</b>	<b>tibialis posterior</b> (tibialis caudalis)
<b>gluteus profundus</b> (gluteus minimus)	<b>triceps surae</b> (= gastrocnemius + soleus)
<b>gluteus superficialis</b> (gluteus maximus)	<b>vastus intermedius</b>
<b>gracilis</b>	<b>vastus lateralis</b>
<b>iliopsoas</b>	<b>vastus medialis</b>
<b>ischadic nerve</b>	
<b>lateral circumflex artery</b>	
<b>lateral circumflex vein</b>	



## Muscles of the Head and Trunk

Table 7.4 lists the head and trunk musculature and indicates their origin, insertion, and main functions.

### Muscles of the Trunk (Figures 7.28–7.30)

The musculature forming the abdominal wall is arranged mainly as three thin, but extensive, muscular sheets or layers (Figure 7.28). The most superficial layer is the **external oblique** (which you noted previously), the middle layer is the **internal oblique**, and the medial layer is the **transversus abdominis**. A fourth muscle, the **rectus abdominis**, also contributes to the abdominal wall. It forms a ventral muscular band running anteroposteriorly between the sternum and pelvis (Figure 7.30). These four muscles act to constrict the abdomen. The rectus can also draw the ribs and sternum posteriorly, flexing the trunk.

The fibers of the external oblique extend posterovertrally. They do not extend all the way to the midventral line but attach by way of an aponeurosis, which covers the deeper musculature of the ventral surface of the abdomen. To see the deeper muscles, cut a small flap in the external oblique, in the central part of the abdomen, as in Figure 7.28. Reflect the muscle and aponeurosis. You can now see the middle layer, the internal oblique. Its fibers extend anteroventrally, nearly at right angles to those of the external oblique. Note, though, that the internal oblique also does not extend to the midventral line, but is continued by an aponeurosis. The muscle lying deep to the aponeuroses is the rectus abdominis, and it will be seen clearly when the internal oblique is cut and reflected. To do so, cut a similar flap in the internal oblique and reflect the muscle and aponeurosis. The muscle exposed is the transversus abdominis, the deepest layer. In this region of the abdomen, the ventral end of the muscle dips deep to the rectus abdominis. Lift the lateral margin of the rectus abdominis. The transversus abdominis is also continued to the midventral line by an aponeurosis. The relative positions of the transversus abdominis and rectus abdominis muscle change more posteriorly. There, the aponeurosis of the former divides so that part of it also covers the rectus abdominis.

Next, examine muscles associated with the thorax. The **scalenus** (Figure 7.30) lies laterally on the thorax, along the ventral parts of the serratus ventralis. Posteriorly, it is subdivided into three narrow bands, with the middle part usually extending farthest posteriorly. Anteriorly, they unite into a single band that passes along the neck. The **transversus costarum** is a small, thin sheet. Its fibers extend anterodorsally from the sternum toward the ventral band of the scalenus, where it inserts on the first rib. The **longus colli** is a long, narrow muscle situated ventral to the cervical vertebrae. It extends anteropos-

teriorly between the anterior part of the scalenus and the external jugular vein. Note also the longitudinal muscle ventral to the posterior part of the external jugular. It is the posterior end of the **sternohyoid muscle**, which will be considered again below.

The thoracic wall is formed mainly by musculature that extends between successive ribs. As in the abdominal region, there are three main muscles. Most superficially are the **external intercostals** (Figure 7.29), followed by the **internal intercostals**, and, most medially, the **transversus thoracis**. Of these, only the internal intercostals extend from middorsally to midventrally. To see the first two muscles, examine the thoracic wall posterior to the serratus ventralis. The muscle fibers extending slightly posteroventrally between successive ribs are external intercostals. Carefully cut perpendicularly through the fibers of one set of external intercostals to expose the internal intercostals, whose fibers run steeply posterodorsally. The external intercostals do not extend all the way to the midventral line, but end at about the level of the lateral margin of the rectus abdominis. Locate the latter muscle and lift its lateral portion away from the thoracic wall. Near the midventral line, note that the internal intercostals are exposed between the ribs. The transversus thoracis is present only near the midventral line, deep to the internal intercostals. Its fibers run almost transversely, with a slight posteroventral inclination. It is best viewed when the thoracic cavity is opened (see Figures 7.45 and 7.51).

### Muscles of the Back and Neck (Figure 7.37)

Two thin muscular sheets, the **serratus dorsalis cranialis** and **serratus dorsalis caudalis**, lie over the back, deep to the latissimus dorsi and rhomboideus (Figure 7.30). The serratus dorsalis muscles are composed of slips extending from the middorsal line to the lateral surfaces of the ribs. The fibers do not extend all the way middorsally, but attach by aponeuroses. The fibers of the serratus dorsalis cranialis extend posteroventrally, and those of the serratus dorsalis caudalis extend anteroventrally.

Next examine the dorsal back or epaxial muscles (Figure 7.37), which lie deep to the musculature so far observed and act mainly to extend the vertebral column. This musculature is extensive, lying between the neural spines and transverse processes and proximal ends of the ribs, from the ilium to the cervical region. It is complex largely because its individual muscles extend between various parts of more posterior vertebrae to more anterior vertebrae, and fusion among its different parts occurs, particularly posteriorly.

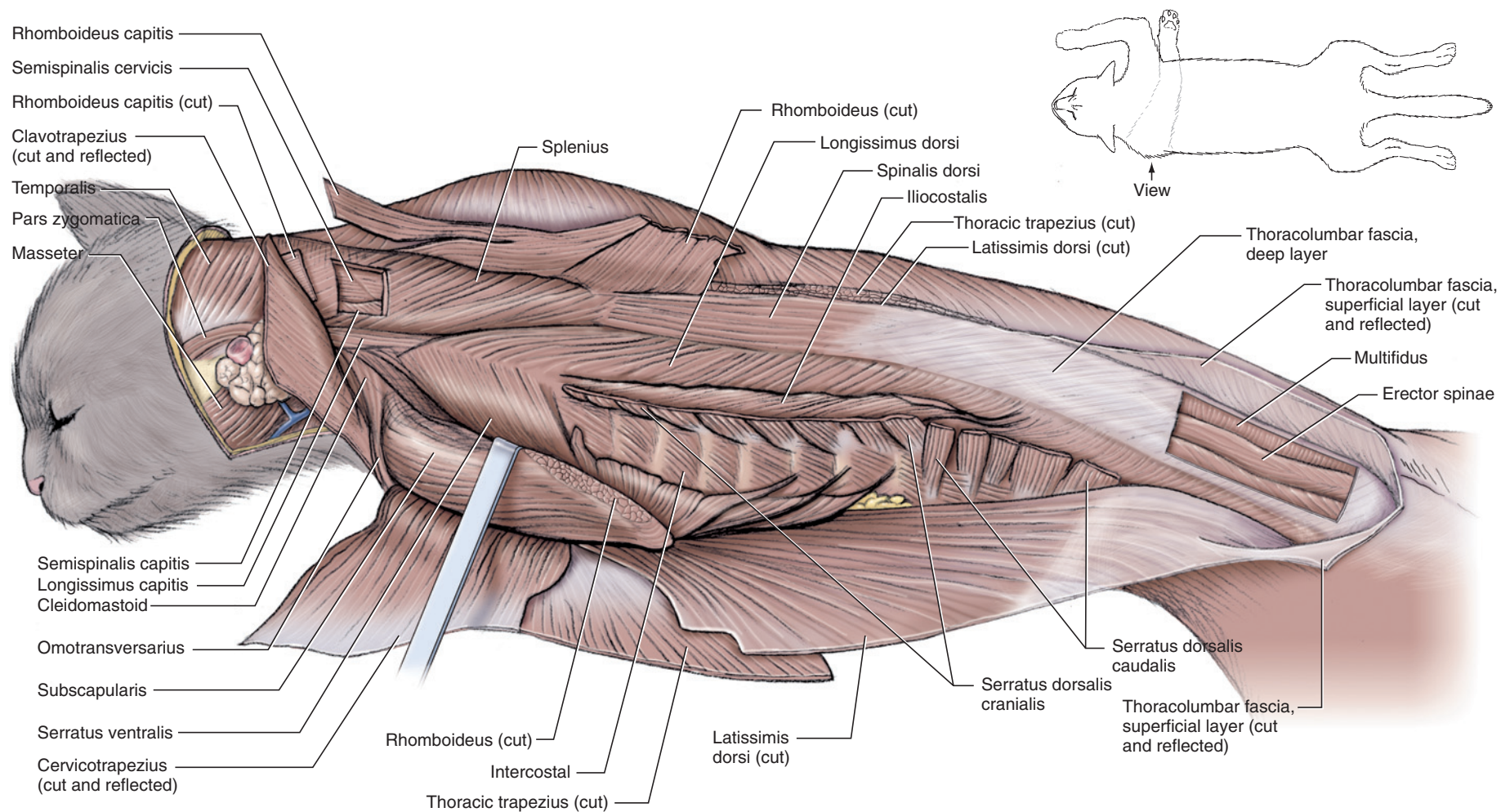
Begin your examination posteriorly with the muscles of the lumbar and posterior thoracic regions. Make a longitudinal cut through the fleshy part of the serratus dorsalis muscles and reflect them. To examine the back

**TABLE 7.4** Muscles of the head and trunk

Name	Origin	Insertion	Main Actions
Digastric	mastoid process of temporal and jugular process of occipital	ventromedial surface of dentary	depresses mandible
External intercostals	posterior margin of a rib	anterior margin of the adjacent posterior rib	protracts ribs, increasing diameter of thorax
External oblique	posterior 9 or 10 ribs and thoracolumbar fascia	mainly on linea alba from sternum to pubis, by aponeurosis	constricts abdomen
Genioglossus	medial surface of dentary	tongue; posterior fibers insert on basihyoid and ceratohyoid	depresses tongue; draws root of tongue anteriorly; curls tip of tongue ventrally
Geniohyoid	ventromedial surface of dentary, just posterior to symphysis	ventral surface of basihyoid	draws hyoid anteriorly
Hyoglossus	lateral part of ventral surface of basihyoid	tongue	depresses and retracts tongue
Iliocostalis	lateral surface of ribs	lateral surface of more anterior ribs	draws ribs together
Internal intercostals	anterior margin of a rib	posterior margin of the adjacent anterior rib	retracts ribs, decreasing diameter of thorax
Internal oblique	thoracolumbar fascia and iliac crest	linea alba, by aponeurosis	constricts abdomen
Lingualis proprius	Intrinsic musculature of tongue consists of several bundles arranged mainly in longitudinal, transverse, and vertical groups. These attach to integument of tongue and insertion fascicles of extrinsic muscles of tongue (e.g., genioglossus, hyoglossus, styloglossus). Tongue musculature responsible for many complex movements, among others those during mastication and deglutition.		
Longissimus capitis	prezygapophyses of 4th–7th cervical vertebrae	mastoid process of temporal	flexes head laterally
Longissimus dorsi	sacral and caudal vertebrae	more anterior lumbar, sacral, and caudal	extends vertebral column
Longus colli	ilium and deep layer of thoracolumbar fascia	more anterior lumbar and thoracic vertebrae	
	ventral surface of first 6 thoracic vertebrae; slips from cervical vertebrae	transverse processes of all cervical vertebrae	flexes neck laterally and ventrally
Masseter	zygomatic arch	ventral part of masseteric fossa of dentary	elevates mandible
Multifidus	various parts of more posterior sacral, lumbar, thoracic, and cervical vertebrae	neural processes of more anterior vertebrae	acting singly: flexes vertebral column laterally; acting with other side multifidus: extends vertebral column
Mylohyoid	medial surface of dentary	midventral raphe; posterior fibers to basihyoid bone	elevates floor of oral cavity; draws hyoid anteriorly
Pterygoideus	pterygoid blade of skull	medial surface of angular region of dentary	elevates mandible
Rectus abdominis	pubis	costal cartilages and sternum	compresses abdomen; draws ribs and sternum posteriorly, flexing the trunk

TABLE 7.4 *Continued*

Name	Origin	Insertion	Main Actions
Scalenus	ribs	transverse processes of all cervical vertebrae	flexes neck; or draws ribs anteriorly
Semispinalis capitis	prezygapophyses of 3rd–7th cervical and 1st–3rd thoracic vertebrae	medial third of nuchal crest	elevates head
Semispinalis cervicis	neural processes of 7th cervical and 1st–3rd thoracic vertebrae, prezygapophyses of 2nd–5th thoracic vertebrae	medial third of nuchal crest	elevates head
Serratus dorsalis caudalis	middorsally from neural processes of lumbar vertebrae	posterior 4 or 5 ribs	draws ribs posteriorly
Serratus dorsalis cranialis	middorsal raphe between axis and 10th thoracic vertebrae, by aponeurosis	lateral surface of first 9 ribs	draws ribs anteriorly
Spinalis dorsi	neural spines of 10th–13th thoracic vertebrae	cervical and more anterior thoracic vertebrae	extends vertebral column
Splenius	anterior middorsal line	nuchal crest	acting singly: flexes head laterally; acting with other side splenius: elevates head
Sternohyoid	1st costal cartilage and manubrium of sternum	basihyoid	draws hyoid posteriorly
Sternomastoid	anterior surface of manubrium of sternum	lateral portion of nuchal crest of skull and mastoid process of temporal	acting singly: flexes neck laterally; acting with other side sternomastoid: depresses snout
Sternothyroid	1st costal cartilage	posterolateral surface of thyroid cartilage of larynx	draws larynx posteriorly
Styloglossus	mastoid process of temporal and stylohyoid	tongue	elevates and retracts tongue
Stylohyoid	lateral surface of stylohyoid	ventral surface of basihyoid	draws basihyoid dorsally
Temporalis	fascia covering muscle, temporal fossa of skull	coronoid process of dentary	elevates mandible
Thyrohyoid	lateral surface of thyroid cartilage of larynx	thyrohyoid	draws hyoid posteriorly and dorsally
Transversus abdominis	costal cartilage of vertebrocostal and vertebral ribs, transverse processes of lumbar vertebrae, ventral margin of ilium	linea alba	constricts abdomen
Transversus costarum	lateral margin of sternum	1st rib and costal cartilage	draws ribs anteriorly
Transversus thoracis	dorsolateral margin of sternum, between attachment of ribs 3–8	costal cartilages near their attachment to ribs	draws ventral portion of ribs posteriorly



**FIGURE 7.37** Dorsal muscles of the neck and back of the cat in dorsolateral view.



musculature here, you must also cut through the lumbo-dorsal fascia, as follows. Poke a hole through the fascia about midway along its length, 0.5 cm to one side of the neural spines. There are two main fascial layers. Separate them by passing a blunt probe between them. Cut through the superficial layer longitudinally, going forward as far as its anterior limit and back to about the level of the anterior part of the hind limb. Continue to remove the connective tissue and fat deep to this fascial layer—note that the latissimus dorsi arises from it laterally.

Clean the surface of the deep layer of fascia to determine its limits. Lateral to the sheet is a longitudinal and relatively narrow muscle bundle, the most lateral portion of the **longissimus dorsi** musculature. You should also be able to faintly see muscle bundles through the fascia. Cut through this deeper fascia, using the same method as with the superficial layer. In this case, dissection is essentially confined to the lumbar region, because you will not be able to go as far anteriorly, as muscle fibers adhere strongly to the deep surface of the fascia. Reflect the fascia to uncover three more longitudinally arranged muscle bundles. The most medial, as well as the narrowest, is the **multifidus**. It is an extensive muscle that is best seen in the lumbar region, lying next to the neural processes. It passes anteriorly deep to other muscles of the back into the cervical region. The two lateral bundles are part of the longissimus dorsi, which is therefore subdivided into three bundles in this region. Its two lateral bundles, separated by the thoracolumbar fascia, are considered to form the lateral division of the longissimus dorsi. The medial bundle is considered the medial division of this muscle.

Further anteriorly, in the thoracic region, the longissimus musculature continues forward as three subdivisions, but these do not correspond entirely to those observed in the lumbar region. To see the more anterior muscles, reflect the anterior part of the latissimus dorsi (along its middorsal origin), as well as the serratus dorsalis. The three subdivisions of the musculature, arranged as longitudinal bundles and derived from the more posterior portion of the longissimus, may now be identified. The **spinalis dorsi** is the most medial, followed by the anterior continuation of the longissimus dorsi, and then, most laterally, by the **iliocostalis**. The spinalis dorsi arises mainly from the deep layer of the thoracolumbar fascia. Follow the longissimus dorsi anteriorly into its cervical extension, the narrow **longissimus capitis**, which lies along the ventral margin of the splenius on the neck. The latter was identified earlier as being deep to the rhomboideus capitis. The splenius and longissimus capitis tend to fuse, but they should be clearly demarcated. Separate these muscles, cut through the middle of the splenius, and reflect its ends. The two

muscles thus exposed are the **semispinalis capitis** and **semispinalis cervicis** (which is actually the anterior portion of the multifidus, noted above), which pass forward from the vertebrae to insert on the skull. The longus colli, passing ventrally along the neck between the anterior part of the scalenus and the external jugular vein, was identified earlier.

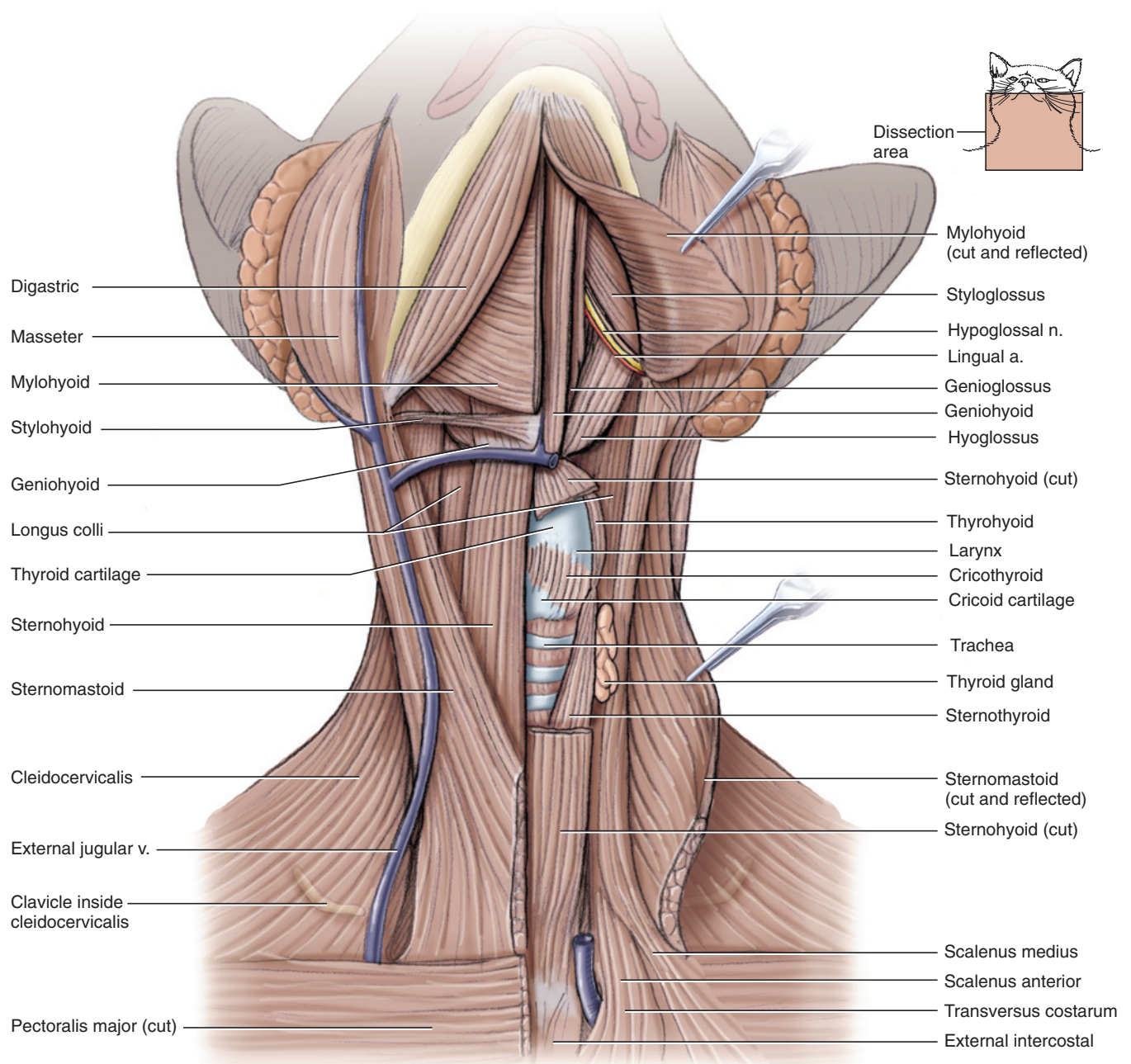
## Muscles of the Throat and Jaw

(Figures 7.28, 7.38, and 7.57)

Examine the muscles associated with the jaws, throat, and tongue, many of which are small, thin, strap-like muscles. It is useful to be familiar with the meaning of the main roots used in names of these muscles (*hyo-* refers to the hyoid, *thyro-* to the thyroid cartilage, *genio-* to the chin, *glossus* to the tongue). Reidentify the sternomastoid, and examine it in ventral view. The sternomastoid from each side passes ventrally and posteriorly from the occiput of the skull. Each follows the anterior border of the clavotrapezius dorsally, but as it nears the throat the sternomastoids veer medially and meet in a V at the base of the throat. The muscles of the throat lie mainly between the V. Gently spread apart the sternomastoids to expose this musculature. Pick away the connective tissue from the surface of the musculature, being careful not to injure the veins passing through the region. Examine the external jugular veins, and note that each receives a medial branch that together form the **transverse jugular vein** near the anterior end of the throat. Extending from this union is a small vessel that passes between the musculature.

The most superficial muscles covering the throat are the **sternohyoid** muscles, whose posterior portions were seen earlier along the neck ventral to the external jugular vein. On the throat, these thin, narrow muscles pass anteroposteriorly next to each other at the midline. Separate them at the midline. Lift one of them from the underlying muscles, cut it, and reflect the ends. You will uncover another set of longitudinal fibers, dorsal and slightly lateral to the sternohyoid. These are parallel to those of the sternohyoid and appear at first glance to constitute a single muscle, but they are two muscles, lying end to end. The posterior and longer muscle is the **sternothyroid**; the more anterior and shorter is the **thyrohyoid** (Figure 7.38). Gently pass a blunt probe beneath them to determine their extent.

Examine the muscles anterior to the transverse jugular vein. This area is roughly triangular, with the sides of the triangle formed by the **digastric muscles**. They lie along the medial edges of the dentary and converge toward the mandibular symphysis. Between the digastrics is the **mylohyoid**, which actually consists of a pair of muscles connected by a raphe at the midline. It is easily recognizable by its transverse and slightly



**FIGURE 7.38** Muscles of the throat of the cat in ventral view.

curving fibers. Extending laterally along the posterior edge of the mylohyoid from the lateral edge of the sternohyoid is the very small and narrow **stylohyoid**. The deeper muscles of the throat and tongue lie beneath the mylohyoid. To view them, cut and reflect the mylohyoid along the midline. The thin, narrow **geniohyoid** muscles (see also Figure 7.40) extend anteroposteriorly next to each other at the midline. These arise from the dentary on either side of the manibular symphysis (the region of the chin in humans; cats do not have a true chin) and insert on the hyoid. The narrow **hyoglossus** muscle arises deep and lateral to the insertion of the

geniohyoid. Its fibers pass anteriorly into the tongue and its surface is crossed by the hypoglossal nerve and lingual artery. The **genioglossus** muscle arises anteriorly, lateral and deep to the origin of the geniohyoid, and passes posterodorsally into the tongue. The **styloglossus** is a long, narrow muscle that passes from the mastoid process of the skull into the tongue. It extends forward parallel to the medial border of the dentary. Push the digastric laterally to help locate the styloglossus. It will cross the anterior part of the hyoglossus. The mass of the tongue is formed mainly by intrinsic fibers, termed the **lingualis proprius**, within the tongue (Figure 7.40).

Examine the head. The larger muscle covering the posterolateral surface of the jaw is the **masseter**, one of the three main jaw-closing muscle groups (Figures 7.27, 7.29, 7.30, and 7.39). The **temporalis**, another jaw-closing muscle, lies on the lateral surface of the cranium and arises from the temporal fossa (see page 133). It is deep to the parotid and mandibular glands, large salivary glands that will be described presently, and covered by a thick fascia. A small slip of the temporalis, the pars zygomatica, curves over the zygomatic arch (Figure 7.37). The third and smallest jaw-closing muscle, the pterygoid, lies medial to the jaw and requires further dissection. It is not considered further.

### KEY TERMS: MUSCLES OF THE HEAD AND TRUNK

digastric	semispinalis capitis
external intercostals	semispinalis cervicis
genioglossus	serratus dorsalis caudalis
geniohyoid	serratus dorsalis cranialis
hyoglossus	spinalis dorsi
iliocostalis	sternohyoid
internal intercostals	sternothyroid
internal oblique	styloglossus
lingualis proprius	stylohyoid
longissimus capitis	temporalis
longissimus dorsi	thyrohyoid
longus colli	transverse jugular vein
masseter	transversus abdominis
multifidus	transversus costarum
mylohyoid	transversus thoracis
rectus abdominis	
scalenus	

## SECTION IV—DIGESTIVE AND RESPIRATORY SYSTEMS

### Salivary Glands

The cat has five pairs of salivary gland, two of which—the **parotid** and **mandibular glands**—are easily observed (Figure 7.39). They have already been noted in connection with the musculature of the throat. The parotid gland, lying almost directly ventral to the ear, is the largest. It is irregular, with obvious lobules and an elongated, tapered ventral portion. The smaller mandibular gland, smoother and nearly oval, lies just posterior to the ventral part of the parotid gland.

Note that three veins come together in this region to form the external jugular vein (Figure 7.39). The most dorsal tributary, the **maxillary vein**, turns dorsally, crosses the

anterior part of the mandibular gland, and then passes deep to the parotid gland. **Lymph nodes** are also present in this region and may be confused with the salivary glands, but lymph nodes are smaller and, as they lack lobules, have a smoother surface. Usually, two are present ventral to the parotid and mandibular glands. Often there seems to be only a single large node that is crossed by the **linguofacial vein**, but careful dissection will reveal two nodes, with the vein passing between them (Figure 7.39).

Examine the ducts of the parotid and mandibular glands. The **parotid duct** is the thick, whitish strand crossing over the middle part of the masseter muscle and extending toward the upper lip. Also crossing the masseter are two branches of the **facial nerve**, the dorsal buccal and ventral buccal branches (Figure 7.39), which are thinner than the duct. One branch lies dorsal and the other ventral to the duct. If you were indelicate in removing the skin, you may have already taken off the duct and nerves.

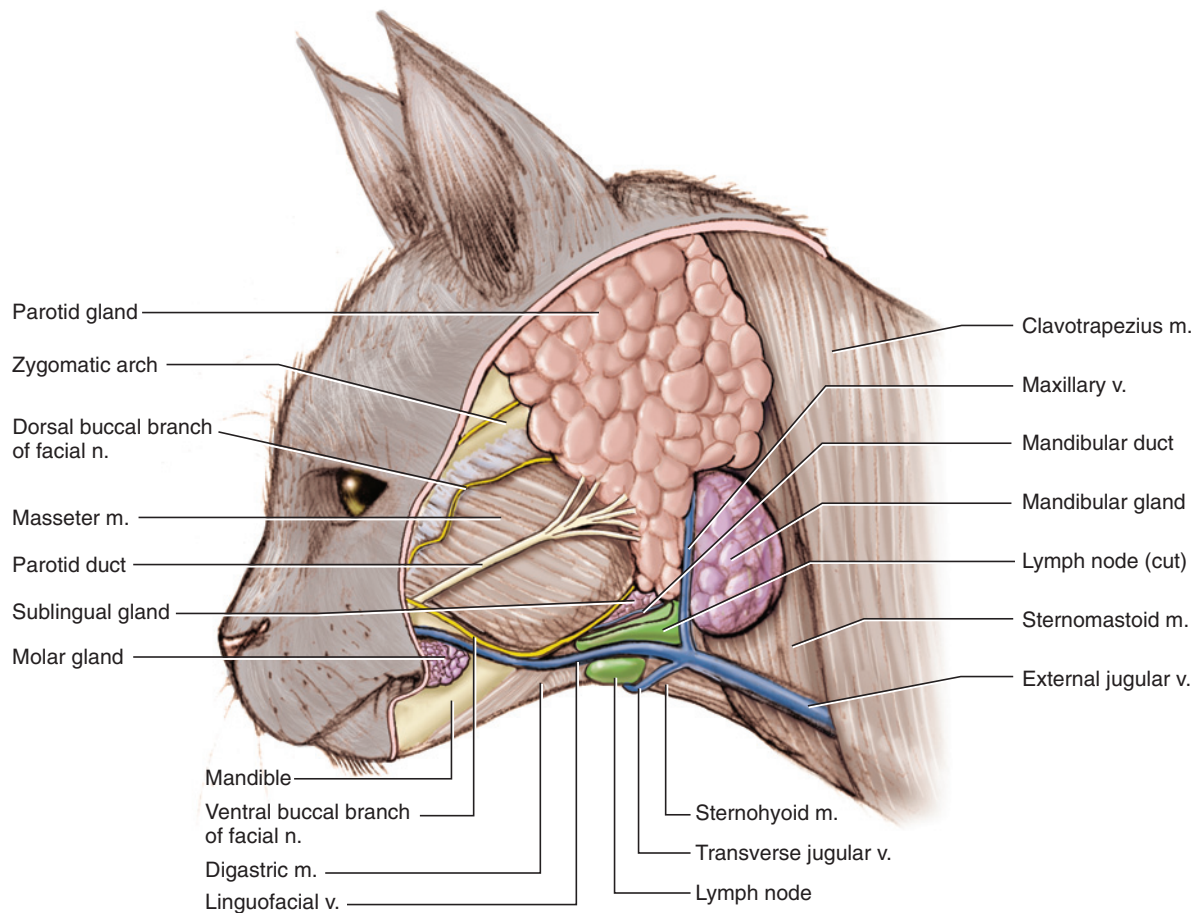
The **mandibular duct** emerges from the anteroventral part of the mandibular gland, just dorsal to the lymph node. Dissect carefully in this region. The duct will appear as a whitish strand, thinner than the parotid duct, that passes ventral to a small glandular mass. This is the long and narrow **sublingual gland** (Figure 7.57). Its posterior end usually abuts against the mandibular gland and may initially be confused as an extension of that gland. Tugging the anterior end of the sublingual gland will reveal that it is more extensive than it at first appears. The duct of the sublingual gland is difficult to discern grossly.

Return to the mandibular duct. Dissect the connective tissue binding it by gently pulling the duct taut with forceps and using a needle; a #11 scalpel blade, worked backwards (i.e., the noncutting edge) also works very well. The proximal part of the duct crosses the surface of the **digastric muscle** as the latter turns dorsally toward the mastoid process of the skull. Continue dissecting anteriorly to reveal the duct and digastric. Note how the duct crosses the dorsal surface of the digastric and then passes medial to it. At this point, approach the digastric from the ventral surface of the jaw. Reflect and separate it from the mylohyoid. You should easily locate the mandibular duct as it passes deep to the edge of the mylohyoid. Reflect the mylohyoid (which was bisected earlier; see page 178 and Figure 7.38) to see the duct continuing anteromedially. The **lingual nerve** crosses the duct anteriorly (Figure 7.57). While studying this region, review the hypoglossal nerve (see also Figure 7.38). It is larger than the mandibular duct and runs almost parallel to it, but further posteroventrally.

### Oral Cavity and Pharynx

Once the salivary glands and their ducts have been examined, the **oral cavity** may be opened. To do this, the





**FIGURE 7.39** Muscles and other structures of the neck and head of the cat in lateral view.

mandible must be spread apart and the tongue pulled ventrally. Begin by separating the jaws, as follows. Locate the position of the symphysis, which lies between the two middle incisor teeth of the mandible. Place the edge of a fresh scalpel blade between the incisors on the anteroventral margin of the mandible and rock it back and forth. The blade will soon pass into the symphysis, separating the dentaries. Do not push hard on the scalpel. A rocking motion with steady, gentle pressure and patience are all that are needed. Place a finger on the dull side of the blade to help guide the scalpel.

When you have passed through the symphysis, use your fingers (but be careful; the cat's teeth are sharp) to spread the dentaries apart. One of them will probably break. Cut through the musculature and other tissues attaching to the medial surface of each dentary as far back as about the level of the lymph nodes. Then pull the **tongue** down through the dentaries to give you a clear view into the oral cavity.

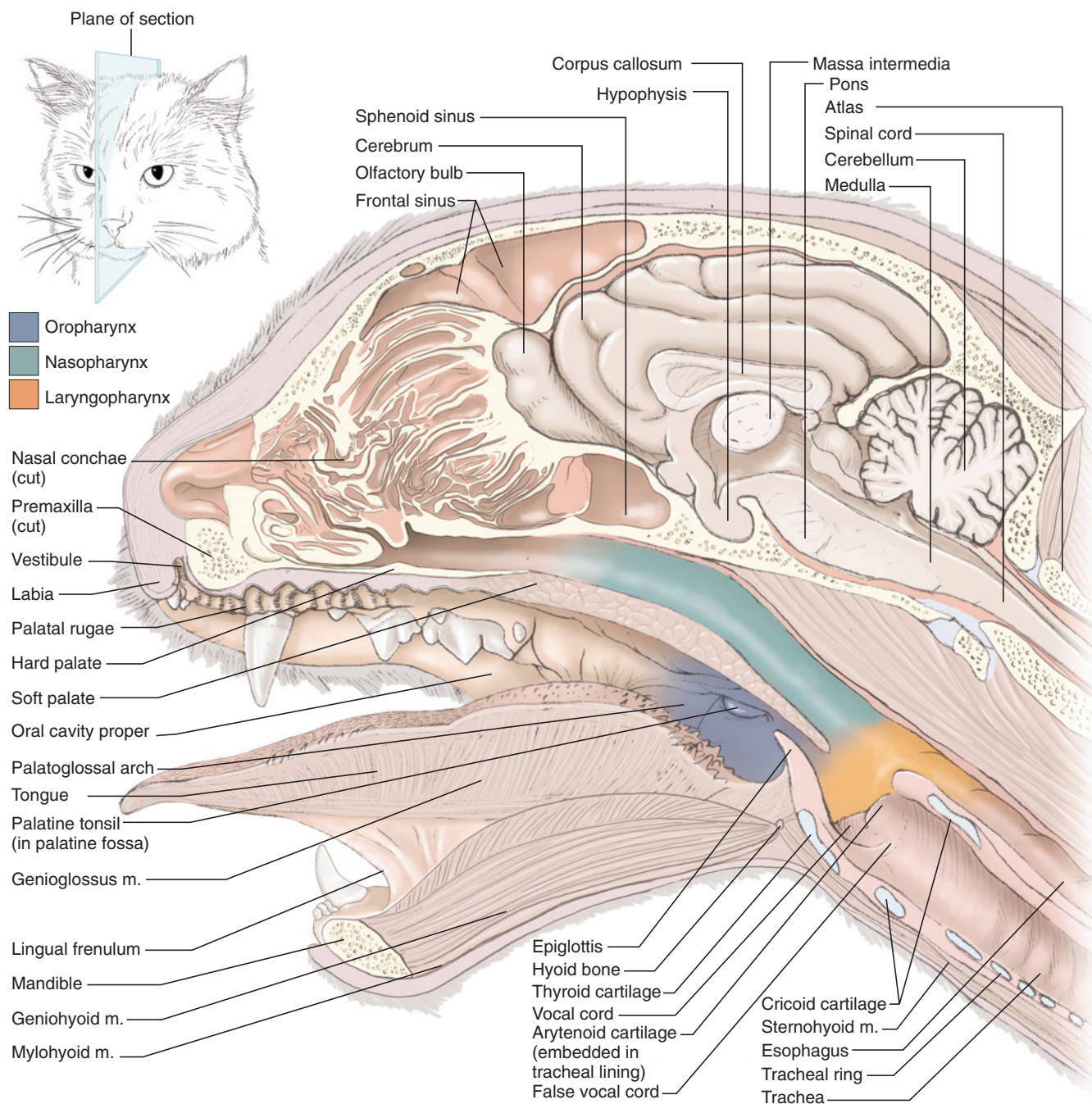
In its broad, everyday sense, the **mouth** includes the structures such as the tongue and the teeth. In a strict sense, however, these structures are part of the oral cavity. The mouth is only the part between the **labia**

(sing., **labium**). The oral cavity is subdivided into the **vestibule**, between the lips and teeth, and the **oral cavity proper**, bounded by the teeth anteriorly and laterally (see Figure 7.40). Posteriorly it extends to just beyond the level of the hard palate. The epithelial covering of the hard palate has roughened transverse ridges, the **palatal rugae**.

The tongue almost completely fills the oral cavity when the mouth is closed. Pull the tongue dorsally and note the **lingual frenulum**, a vertical, median flap attaching the tongue to the cavity floor (see Figure 7.40). The surface of the tongue bears various projections or papillae (Figure 7.41). The **filiform papillae** are most numerous. Interspersed among them are the rounded **fungiform papillae**. The **vallate papillae** are set in the posterodorsal surface of the tongue, and the **foliate papillae** are along the side of the posterior end of the tongue.

The paired **palatine tonsils** are set partially within **tonsillar fossae**. Just anterior to the tonsillar fossae are the **palatoglossal arches**, lateral folds that may be made more prominent by pulling the tongue downward. In the adult these arches mark the end of the oral cavity. Thus, the oral cavity extends somewhat beyond the level of



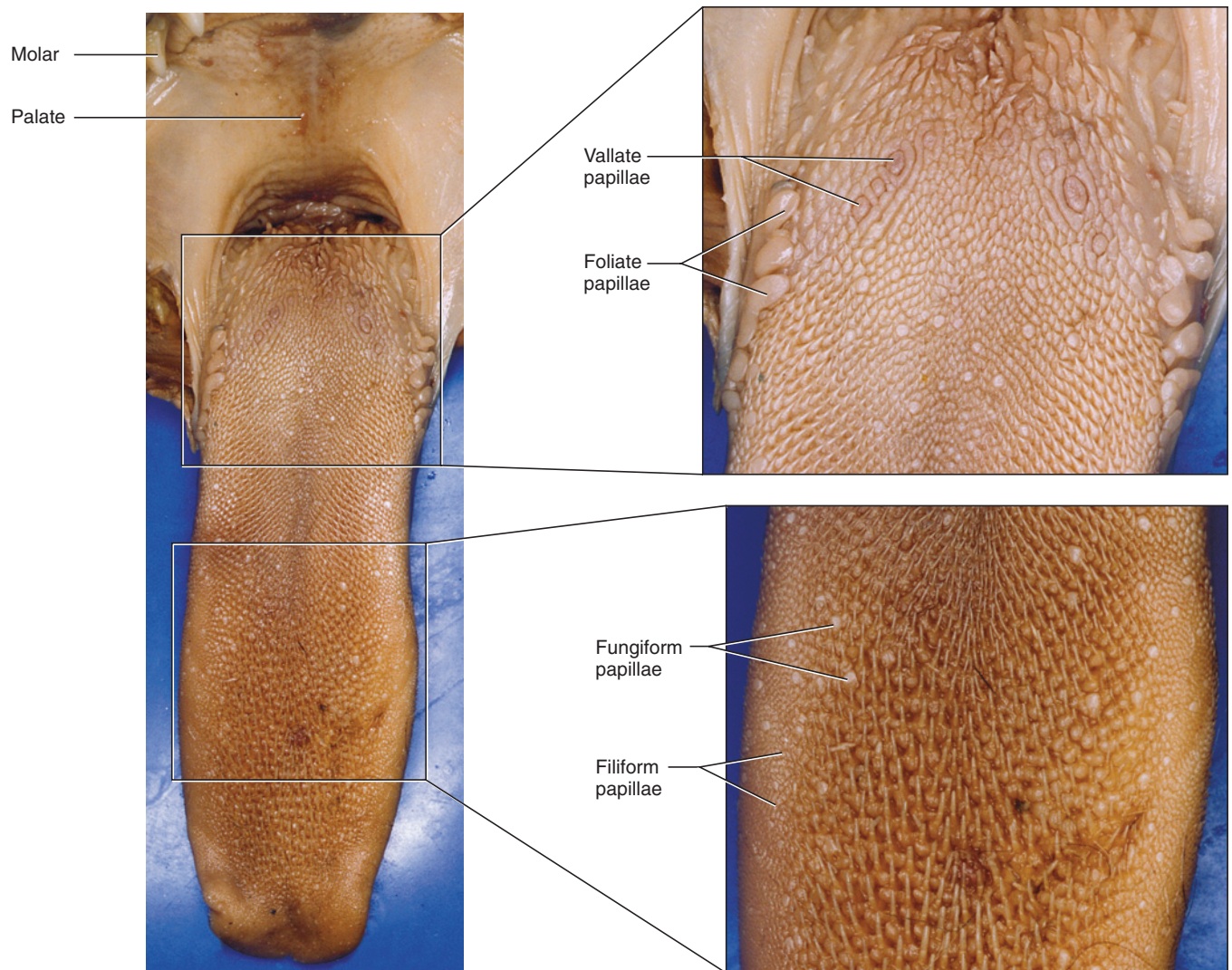


**FIGURE 7.40** Head of the cat in sagittal section.

the hard palate (see Figure 7.40). The bones of the hyoid apparatus that pass to the base of the skull are embedded within the palatoglossal arches, as are small muscles that assist in swallowing. Extend the cuts made to open the oral cavity further posteriorly to the level of the palatoglossal arches, but do not cut through the hyoid apparatus. This provides a better view of the oral cavity and **pharynx**.

The pharynx is the passage common, in part, to both the digestive and respiratory systems. It extends from a line through the posterior edge of the hard palate to a

line through the posterior boundary of the larynx. The anterior part of the pharynx is subdivided into dorsal and ventral portions by the **soft palate**, the fleshy posterior continuation of the hard palate. The region dorsal to the soft palate is the exclusively respiratory **nasopharynx**; that ventral to the soft palate the exclusively digestive **oropharynx** (which therefore lies posterior to the oral cavity). Posterior to the soft palate these become continuous and extend posteriorly to the **laryngopharynx**, which communicates with the larynx posteroventrally and with the esophagus posterodorsally (see Figure 7.40). Make a median slit in the soft palate to



**FIGURE 7.41** Tongue of the cat with blowups showing detail of the taste buds.

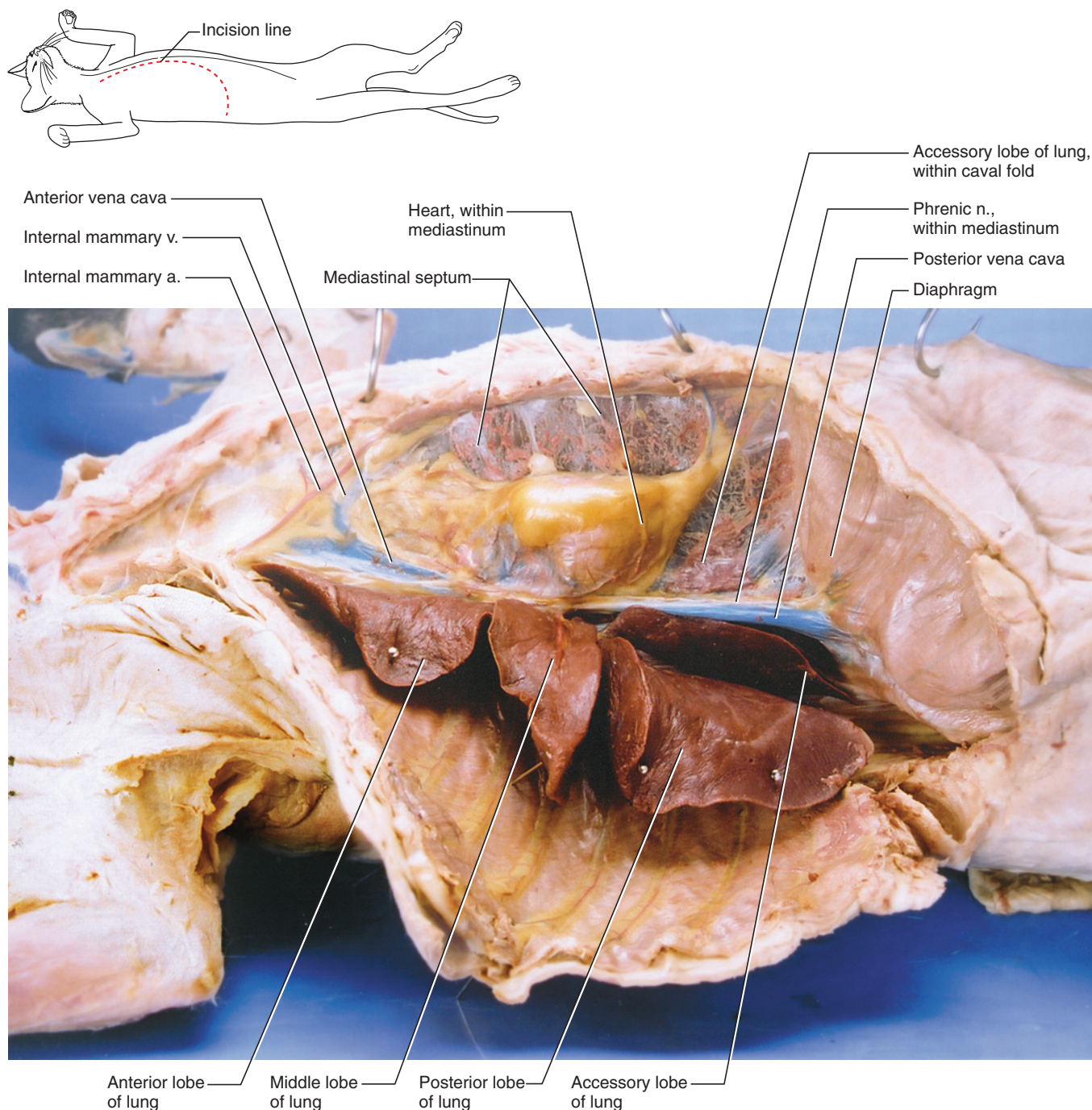
expose the nasopharynx. Anteriorly, it leads to the **internal choanae**. The opening of the **auditory tube** (which leads to the middle ear) lies on the dorsolateral wall of the nasopharynx. However, it is often swollen with fluid and may be difficult to find.

The **esophagus** is the muscular tube of the digestive system that extends from the laryngopharynx to the stomach. The **larynx** is the chamber at the anterior end of the **trachea** or windpipe (see Figure 7.38) and is formed from several cartilages. The opening into the larynx is the **glottis**, which is guarded by the **epiglottis**, the plough-like, cartilaginous structure at the base of the tongue. The epiglottis, which is supported by an **epiglottal cartilage**, is flipped back to cover the glottis during swallowing, so that food passes posteriorly through the laryngopharynx and into the esophagus. Using a bent probe, reflect the epiglottis forward and slide the probe posteriorly. It will pass through the glottis and enter the trachea. Palpate the trachea to verify this.

Cartilages that contribute to the larynx include the **thyroid**, **cricoid**, a pair of **arytenoid cartilages**, and the epiglottal cartilage just mentioned. Examine them by observing the throat region in ventral view. The thyroid is the largest cartilage. It was noted in connection with the thyrohyoid and sternothyroid muscles (see page 178 and Figures 7.38, 7.40, and Figure 7.57). The thyroid is incomplete dorsally. Anteriorly, it contacts the thyrohyal of the hyoid apparatus. The epiglottis rests against the anteroventral part of the thyroid. The cricoid lies slightly distal to the thyroid and forms a complete ring, but is narrower ventrally than dorsally. The **cricothyroid muscle** extends between these cartilages (see Figure 7.38). Separate the larynx from the surrounding tissue and observe its dorsal surface. The arytenoids (see Figure 7.40) are small cartilages that help complete the larynx dorsally, anterior to the cricoid cartilage.

Make a midventral slit through the larynx and spread it open. Two folds of tissue are present on each side of





**FIGURE 7.42** Right pleural cavity of the cat in lateral and slightly ventral view.

the larynx. The **vocal cords** are the more posterior folds, extending between the arytenoid and thyroid cartilages (see Figure 7.40). The glottis lies between them. The **false vocal cords** are an accessory pair of folds, extending between the arytenoid and epiglottic cartilages. They are larger, looser and lie anterior to the vocal cords.

The **tracheal cartilages** are C-shaped, dorsally incomplete cartilaginous elements that keep the trachea open (see Figures 7.38 and 7.40). The esophagus lies dorsal

to the trachea. To examine the rest of the respiratory system, it will be necessary to open the thorax.

The **thorax** is the region that contains the thoracic cavity, the anterior part of the body cavity or coelom. The **thoracic cavity** and **abdominopelvic cavity** (the posterior part of the coelom) are separated by a muscular partition, the **diaphragm** (Figure 7.42). The thoracic cavity is subdivided into three cavities: left and right pleural cavities, each containing a **lung**, and a median

space, the **mediastinum**, which contains most of the other structures that lie in or pass into the thorax (such as the heart, esophagus, trachea, and nearly all the vessels and nerves that pass through this region).

Subdivision of the thoracic cavity is due to the presence of thin epithelial membranes that line the inside wall of the cavity and the structures that lie within it. Enclosed body cavities (i.e., those that do not communicate with the exterior environment) such as the thoracic cavity are lined by serous epithelium, a membrane that produces a watery, lubricating secretion to help reduce friction between structures lined by the membrane. The serosa of the thoracic cavity is termed **pleura**. There are two sheets of pleura, one on the right side and the other on the left. Portions of the pleura are designated based on position. That portion that lines the inside of the cavity is **parietal pleura**, whereas the portion that envelops the lung is **visceral pleura**. As noted, these are actually formed by one continuous sheet. The parietal pleura lines the inside of the cavity, but near the sagittal midline it reflects, so that it then passes to cover the lung. Where the right- and left-side pleura meet near the midline, they form a double layer termed the **mediastinal septum**. The mediastinum is the space or potential space between this double layer. Various structures, as noted above, may occupy this space, but in places the mediastinal septum remains as a double-layered structure.

Open the right side of the thorax first by making a longitudinal cut about 1 cm to the right of the midventral line. Begin posteriorly, at about the midpoint of the xiphohumeralis muscles. This position should be just in front of the diaphragm. You will be cutting through costal cartilages and ribs, as well as musculature, so use a strong pair of scissors. Spread open the thorax and locate the diaphragm. Now cut laterally, following along the anterior surface of the diaphragm. Extend the cut as far dorsally as you can. Spread the thorax further open and nip the dorsal end of each rib, beginning posteriorly. This will allow you to push open the right side of the thorax, exposing the right pleural cavity and lung (Figures 7.42–7.44).

Examine the right pleural cavity. It is really only potentially a cavity, because it is filled in life by the lung. Its walls are lined by parietal pleura, whereas the lung is covered by visceral pleura (Figure 7.44). The parietal pleura is clearly visible on the inside of the thorax, where it covers the musculature (including the diaphragm) and ribs. You cut through it in exposing the thorax. In addition, the parietal pleura forms the medial wall of the pleural cavity. Between the medial walls of the right and left pleural cavities lies the mediastinum. The large bulge within it is the heart. Identify the mediastinal septum, which occurs where the pleurae of the right and left pleural cavities meet at the midline. Lift

the sternum to observe the septum, but do not damage it (Figures 7.42 and 7.43).

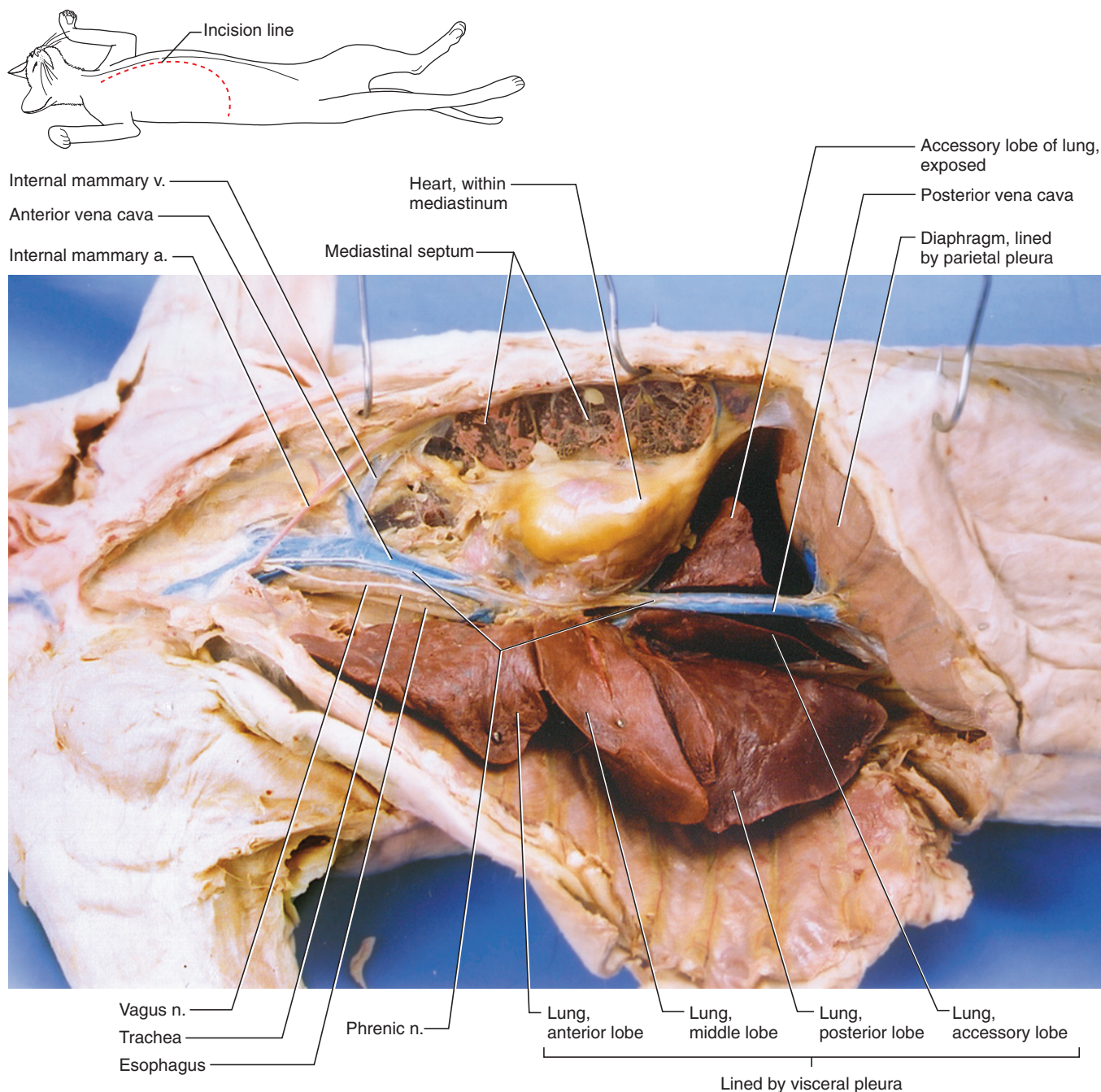
The right lung consists of **anterior, middle, posterior, and accessory lobes**. The accessory lobe passes dorsal and then medial to a large vein, the **posterior vena cava**. This lobe may not be apparent at first because it lies in the **caval fold**, a pocket-like expansion of the mediastinal septum just posterolateral to the heart (Figures 7.42 and 7.43). Dissect the caval fold to expose the accessory lobe and the vena cava (Figure 7.43). The lung is suspended in the pleural cavity by the **pulmonary ligament**, a flat, broad, sheet-like connective tissue. To view it, pull the posterior lobe of the lung ventrally, and examine in lateral view the region dorsal to the lobe (Figure 7.44).

Next, push the lung laterally and look between the lung and mediastinal wall. At about the middle of its medial surface, a fold of pleura will be seen passing from the lung to the mediastinal wall. This fold is part of the pulmonary ligament. Various structures (such as the pulmonary vessels and the bronchus), collectively forming the **root of the lung**, pass through it.

Examine the mediastinal wall just ventral to the root of the lung. You should discern a thin, whitish strand extending anteroposteriorly. This is the **phrenic nerve**, which lies in the mediastinum and passes to the diaphragm (Figure 7.43). Using a needle, expose the phrenic nerve and follow it posteriorly as it passes along the ventral surface of the posterior vena cava. Also follow the nerve anteriorly as it passes along the mediastinum anterior to the heart. Break through into the mediastinum as you do so. Very delicately, clear away fat and connective tissue. The large vessel injected with blue latex is the **anterior vena cava**. Dorsal to it is the trachea; its cartilaginous elements should be easily recognizable. Note the **vagus nerve**, running anteroposteriorly along the lateral surface of the trachea. Dorsal and slightly to the left of the trachea is the esophagus (Figure 7.43). Further posteriorly, the esophagus passes through the diaphragm and into the stomach. The trachea passes posteriorly in the mediastinum and bifurcates near the level of the 6th rib into right and left **primary bronchii**. Postpone their study until the heart has been examined (see Section V). Each bronchus in turn branches into **secondary** and **tertiary bronchii**, which further branch into bronchioles that end in the tiny respiratory structures of the lungs, the alveoli. The bronchioles and alveoli, however, cannot be easily dissected and observed grossly.

Open the left pleural cavity by making a longitudinal cut to the left of the midventral line and by repeating the procedures described above for the right pleural cavity. This method produces a median flap that leaves the sternum intact. Examine the left lung, and identify the anterior, middle, and posterior lobes (Figure 7.45).





**FIGURE 7.43** Deeper dissection of the right pleural cavity of the cat in lateral and slightly ventral view.

The left lung lacks an accessory lobe. Find the left phrenic nerve, just ventral to the root of the lung.

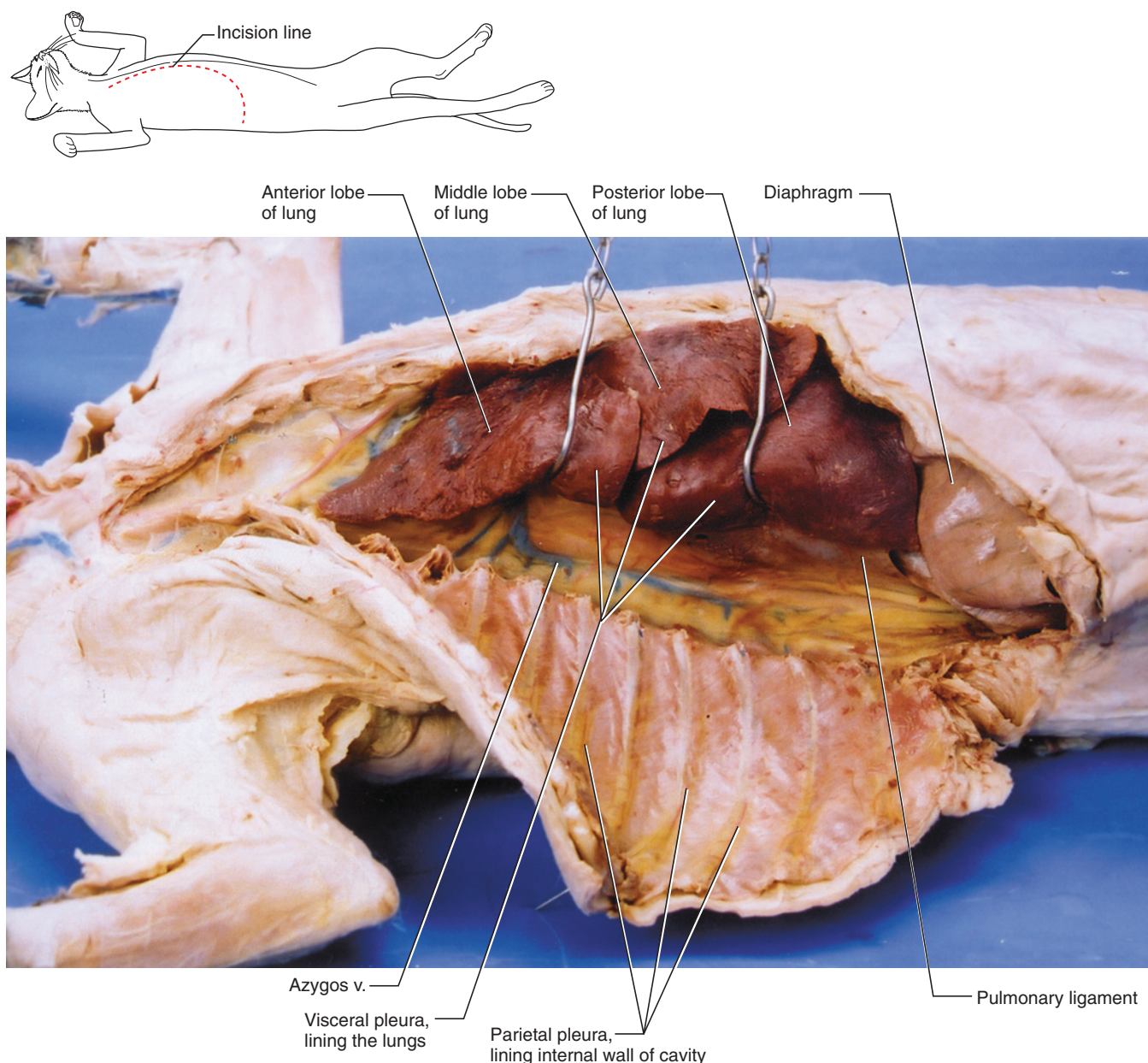
### Pericardial Cavity

Cut the median strip ventrally and break through the pleura ventral to the heart so you can lift the sternum (Figure 7.45). Be careful not to injure the internal mammary vessels passing to the inside of the strip. Peel the pleura away from the heart—there may be a considerable layer of fat deep to the pleura. Carefully clear the fat to reveal that the heart sits in its own space, the **pericardial cavity**, which is enclosed by a tough layer of

**pericardium**. Note the great vessels of the heart anteriorly by cleaning away fat, but do not examine them at this time. Lift the apex of the heart (its posterior end) to better appreciate the extent of the accessory lobe of the right lung. With a pair of scissors, pierce the parietal pericardium and cut it longitudinally to expose the surface of the heart, itself covered by **visceral pericardium** (Figure 7.45).

### Abdominopelvic Cavity

The abdominopelvic cavity forms the rest of the coelom posterior to the diaphragm and contains most of the



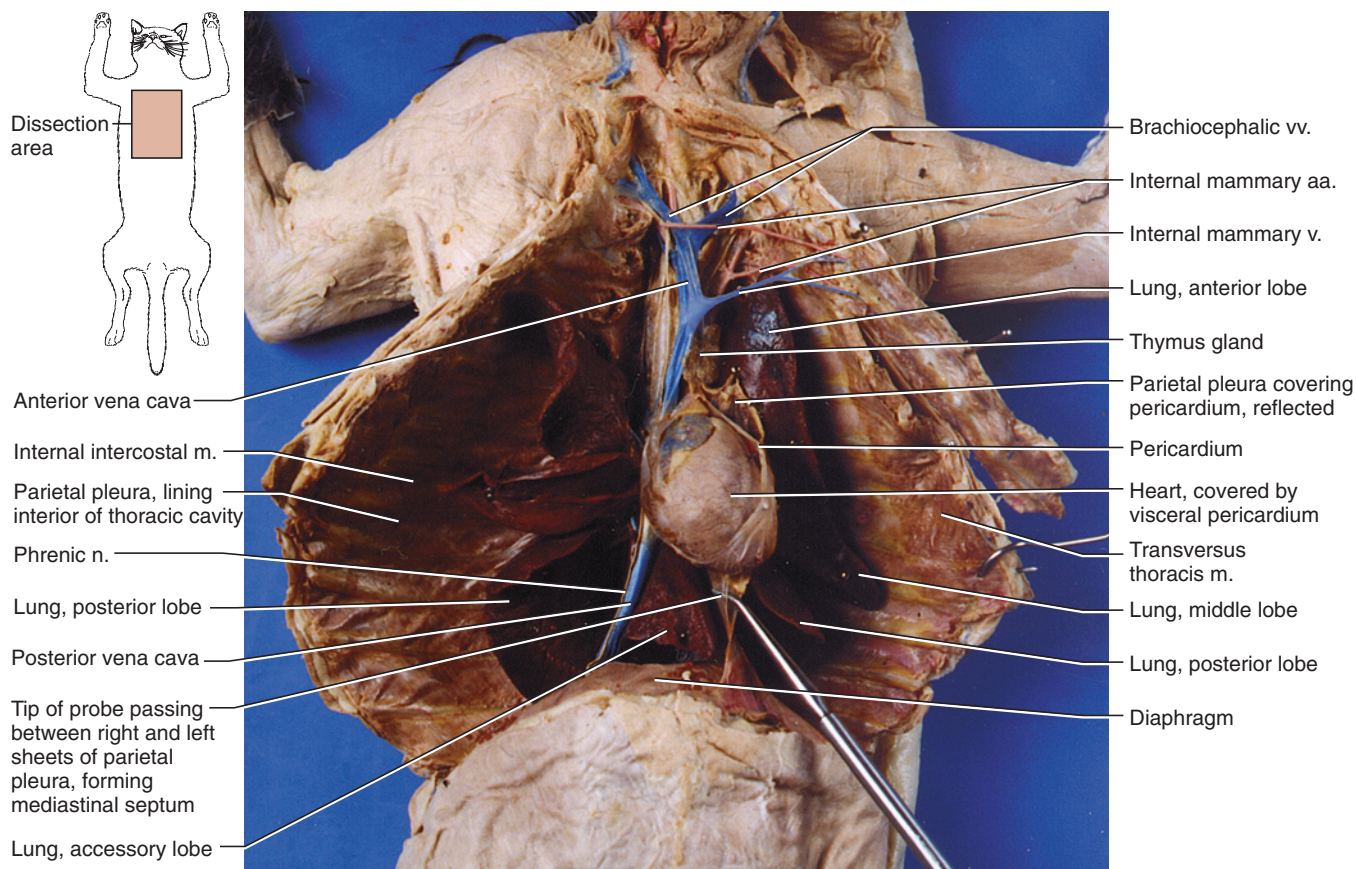
**FIGURE 7.44** Deeper dissection of the right pleural cavity, with right lung lifted from dorsal wall, of the cat in lateral and slightly ventral view.

structures of the digestive and urogenital systems. Open the abdominopelvic cavity by making a longitudinal incision, using scissors, about 1 cm to the right of the midventral line. Then cut laterally along the posterior margin of the diaphragm and spread open the muscular walls of the abdomen (Figure 7.46).

The abdominopelvic cavity and its contained structures are lined with serous epithelium termed **peritoneum**. That portion lining the walls of the cavity is **parietal peritoneum** and that covering structures within the cavity is **visceral peritoneum**. The peritoneum actually represents two separate sheets, each of which encloses separate cavities in the embryo. These cavities are the right coelom

and left coelom, and the embryonic gut lies between them. Near the midsagittal plane, dorsal and ventral to the embryonic gut, the peritoneum of the right and left coela lie adjacent to each other, forming a sheet-like, double layer (similar to the pleurae of the thoracic cavity) of peritoneum that is termed a *mesentery*. Other organs, as they arise and enlarge in the embryo, come to occupy a position between the two layers and demarcate separate sections of mesentery. Subsequently in development, most of the ventral mesentery breaks down, creating a single space from the two originally separate coela. Whereas adults retain only small remnants of the ventral mesentery, nearly all of the dorsal mesentery remains. Mesenteries serve mainly to support structures in the





**FIGURE 7.45** Thoracic cavity of the cat in ventral view.

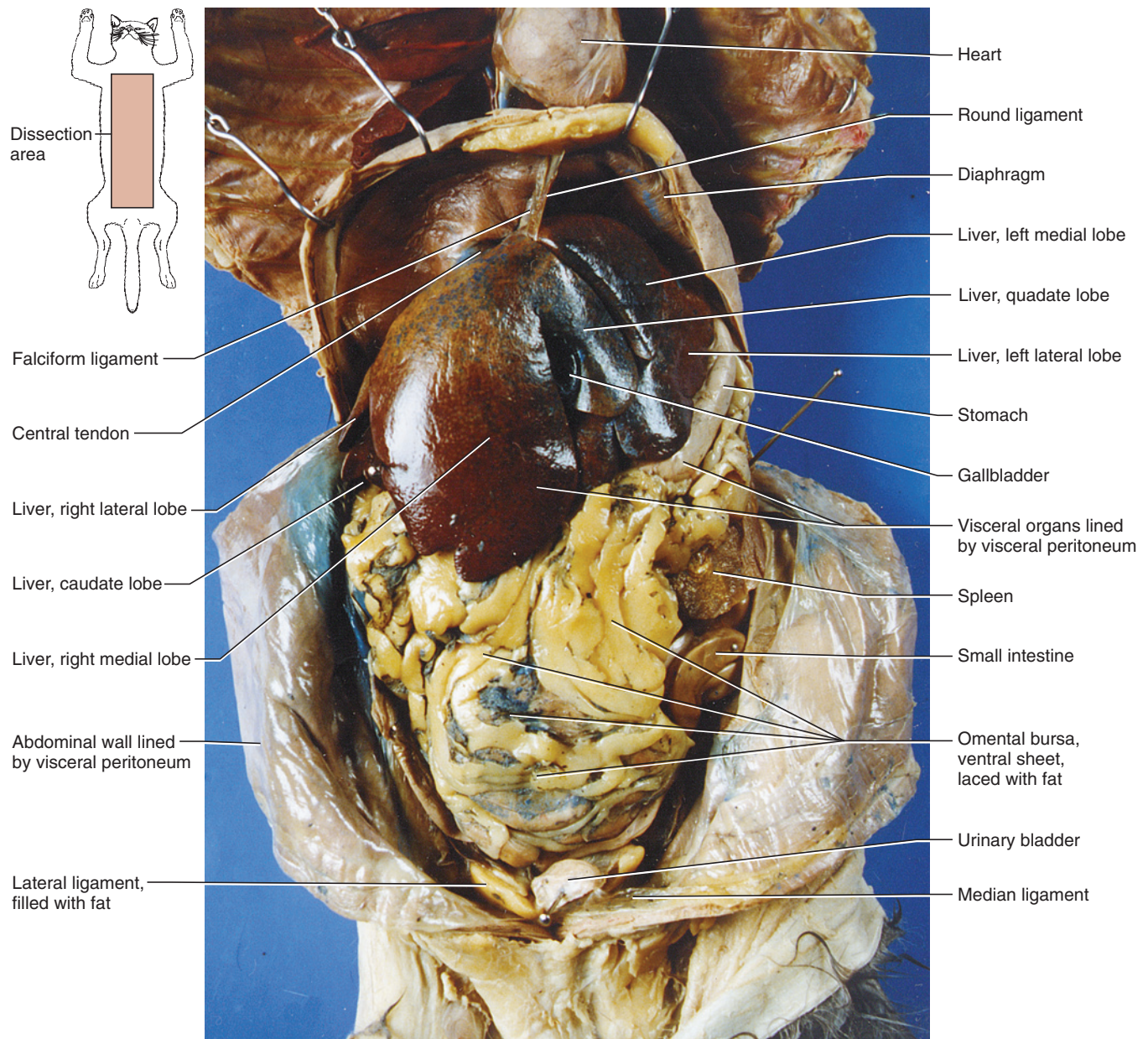
abdominopelvic cavity by anchoring them to the body wall (either directly or by way of other mesenteries) and to provide a channel for the passage of nerves and vessels. Examine an inside wall of the abdominopelvic cavity to observe parietal peritoneum.

Pressed tightly to the posterior surface of the diaphragm is the **liver**. It is covered by visceral peritoneum. Spread apart the liver and diaphragm. This will pull taut the **falciform ligament** (an example of ventral mesentery), which passes from the diaphragm to the liver and separates the liver into left and right halves. In overweight cats the falciform may be hard to distinguish because it is very fatty. The free ventral edge of the falciform ligament may contain a slight expansion, the **round ligament**. The fibers of the diaphragm converge toward its center and insert on the **central tendon**, which may be difficult to discern. To see it, separate the liver and diaphragm and observe the posterior surface of the diaphragm. Run a finger along the anterior surface of the diaphragm, toward its center, to the left of the heart. You should be able to make out your finger through the translucent central tendon. The **coronary ligament** is a very short structure between the diaphragm and liver on either side of the falciform ligament, and binds the liver tightly to the diaphragm and lateral body wall.

As noted above, the falciform ligament separates the liver into right and left halves, each of which is further subdivided (Figures 7.46 and 7.47). The **right medial lobe** is considerably larger than the **left medial lobe**. Between these lobes is the small quadrate lobe. It is separated from the right medial lobe by the greenish, sac-like **gall bladder**. The quadrate and right lateral lobes are connected anterior to the gall bladder, and in some specimens posterior to it as well. The **left lateral lobe** is larger than the **right lateral lobe**, which is partly hidden by the right medial. Lift the right lateral lobe to reveal the **caudate lobe**.

The **stomach** is the large, light-colored, sac-like organ partially exposed posterior to the left lateral lobe of the liver (Figure 7.46). Dorsal to the edge of this lobe, near the midline, find the esophagus passing through the diaphragm and into the stomach. The stomach's long, convex surface is the **greater curvature**; its shorter, concave surface is the **lesser curvature**. Distally, toward the right, the stomach constricts into the **pyloric sphincter**, the muscular, valve-like separation between the stomach and the duodenum. Make a slit in the ventral wall of the stomach and note the folds or **rugae** that line its inner walls. The large dark organ to the left of the stomach is the **spleen**.



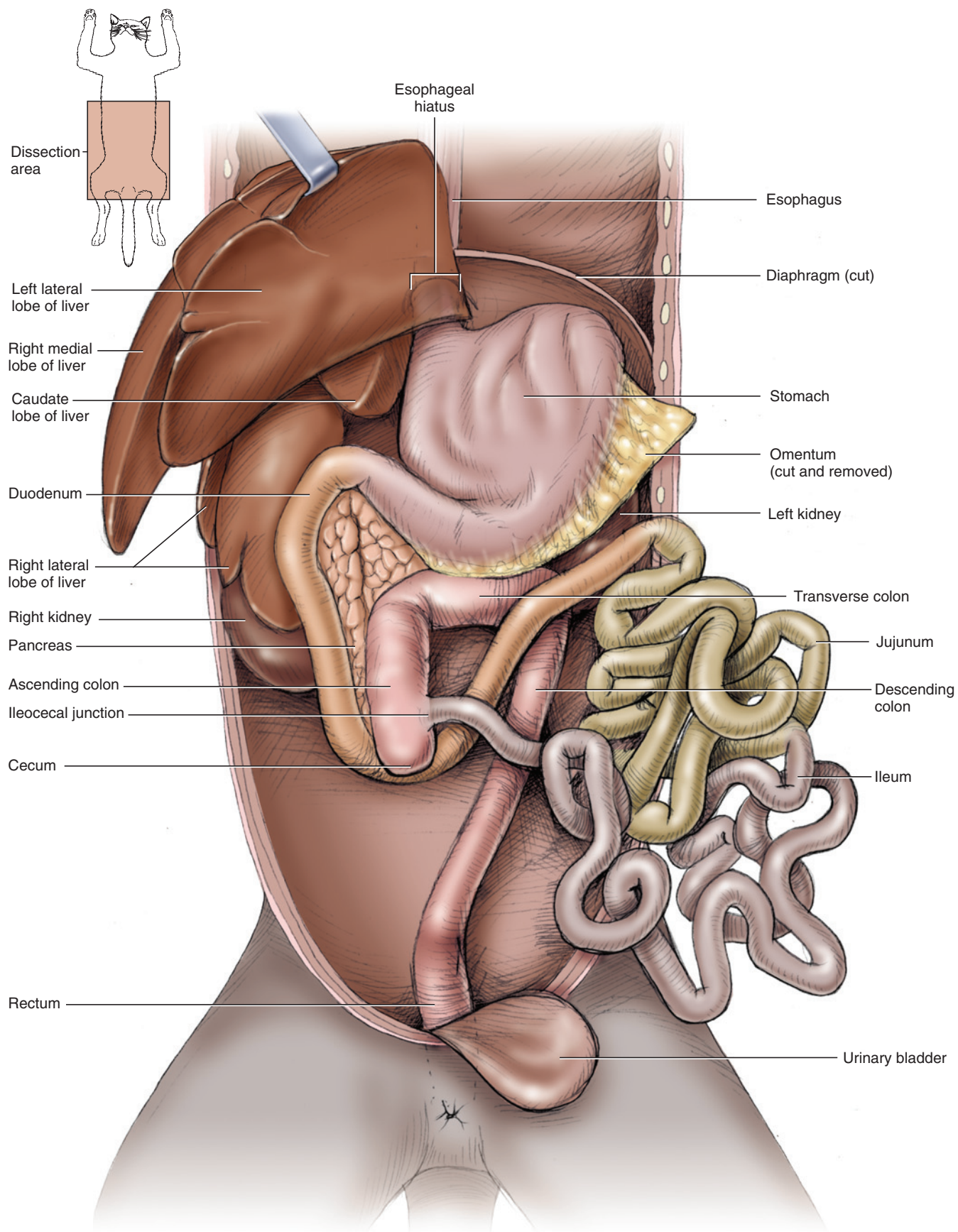


**FIGURE 7.46** Abdominopelvic cavity of the cat in ventral view, with diaphragm reflected.

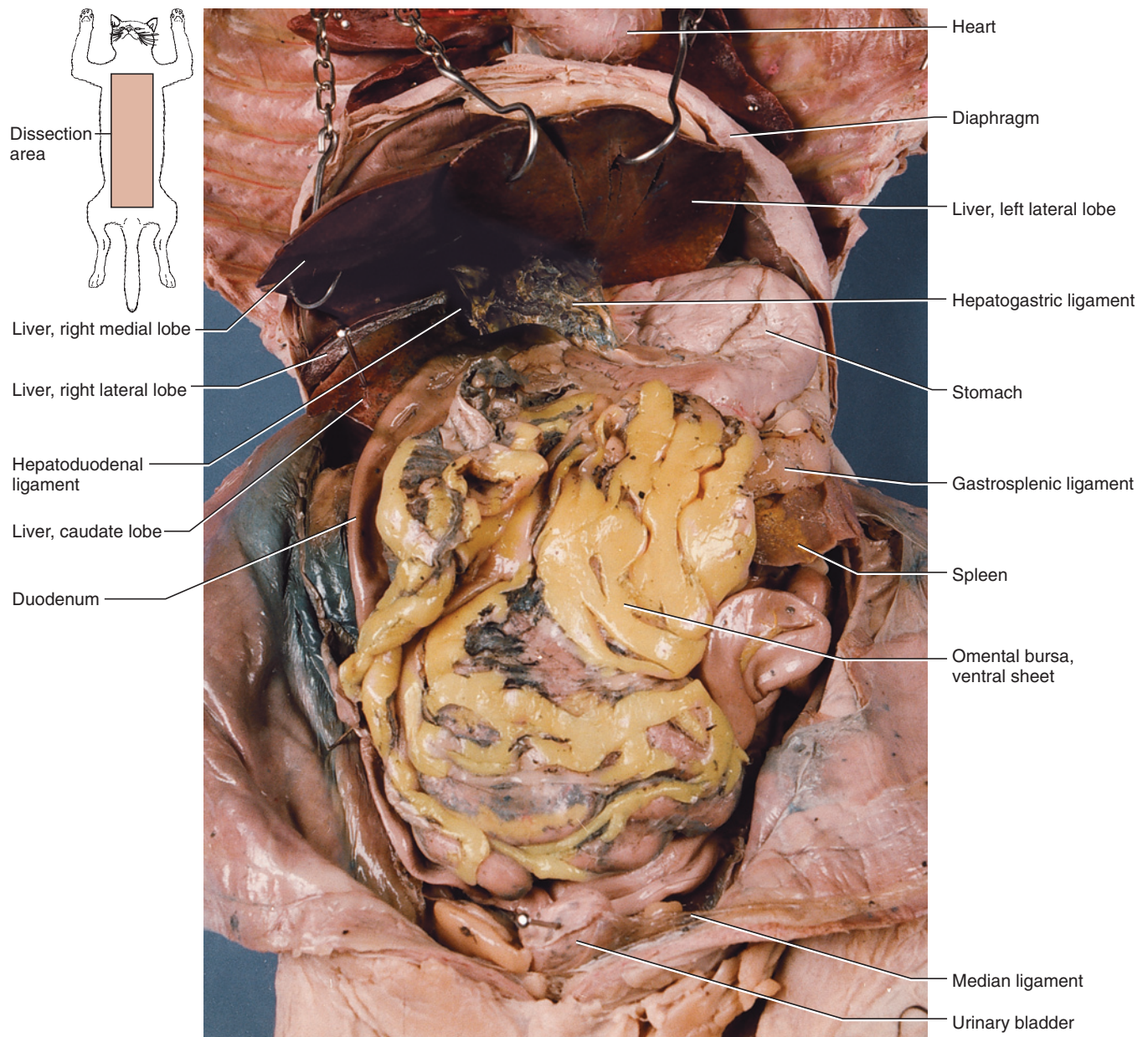
Posterior to the stomach, the abdominal cavity is covered ventrally by the **omental bursa**, a large, double-layered, fat-laced mesentery that covers the **intestines** like an apron (Figure 7.46). The bursa is a sac-like structure formed from the greater omentum, which is part of the dorsal mesentery. Its structure will be discussed shortly. The omental bursa extends posteriorly to the **urinary bladder**, the light-colored, median, sac-like organ lying ventrally. If it is empty, it resembles a collapsed balloon. The mesentery passing from the bladder to the midventral wall, just to the left of the incision made to open the abdominopelvic cavity, is the **median ligament** (Figure 7.46). The bladder is also supported by **lateral ligaments**, one on either side, that are often filled by wads of fat.

Return to the anterior part of the abdominal cavity and spread apart the stomach and liver (Figure 7.48). The mesentery extending from the lesser curvature of the stomach and duodenum to the liver is the **lesser omentum** (another example of ventral mesentery), which is divided into two portions. One part, the **hepatogastric ligament**, passes from the lesser curvature to the liver. The other, passing from the proximal part of the duodenum to the liver, is the **hepatoduodenal ligament**, which appears to head toward the gall bladder. Various structures pass through the lesser omentum, including the **common bile duct** and the **hepatic artery**. These will be considered below.





**FIGURE 7.47** Diagrammatic illustration of the viscera of the cat in ventral view, with liver reflected to show arrangement of intestines.



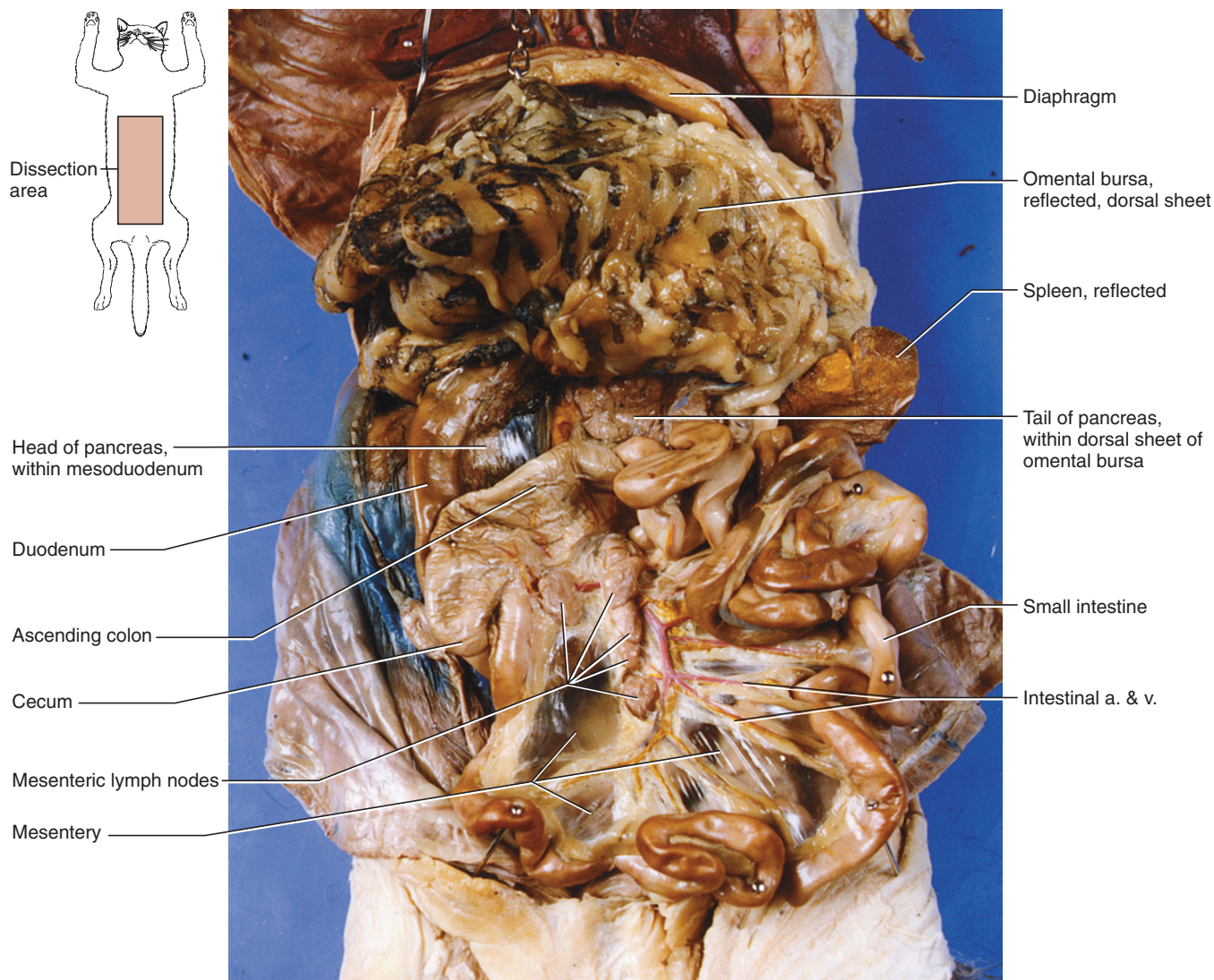
**FIGURE 7.48** Abdominopelvic cavity of the cat in ventral view, with liver reflected.

The remaining mesenteries associated with the digestive system are mainly part of the dorsal mesentery. Similar subdivisions as were noted for the dogfish may be recognized, but they are more complex in the cat. The most conspicuous part is the greater omentum, which, as mentioned above, forms a double-layered, sac-like omental bursa that is draped over the intestines. The greater omentum consists mainly of two sheets. The ventral sheet attaches to the greater curvature of the stomach and extends posteriorly (Figure 7.46). Near the urinary bladder the sheet curves dorsally and extends back toward the stomach as the dorsal sheet. The greater omentum is delicate and should be handled carefully. Slowly lift its posterior end away from the intestines (you will also lift the spleen) to see the dorsal sheet, which

passes dorsal to the stomach (Figure 7.49). Just posterior to the stomach, the dorsal sheet contains glandular material, the **tail of the pancreas**, but do not examine it now. The omental bursa is this sac-like part of the greater omentum. Within it is the potential space, normally closed, known as the **lesser peritoneal cavity**. It communicates with the peritoneal cavity via the **epiploic foramen**, which will be described shortly. Part of the greater omentum, the **gastrosplenic ligament**, stretches between the stomach and the spleen (Figure 7.46).

Return to the pyloric sphincter and trace the digestive tract distally without tearing through any mesenteries. Use Figure 7.47 in locating the structures described. The small intestine fills nearly all the abdominal cavity poste-





**FIGURE 7.49** Abdominopelvic cavity of the cat in ventral view, with omental bursa and spleen reflected.

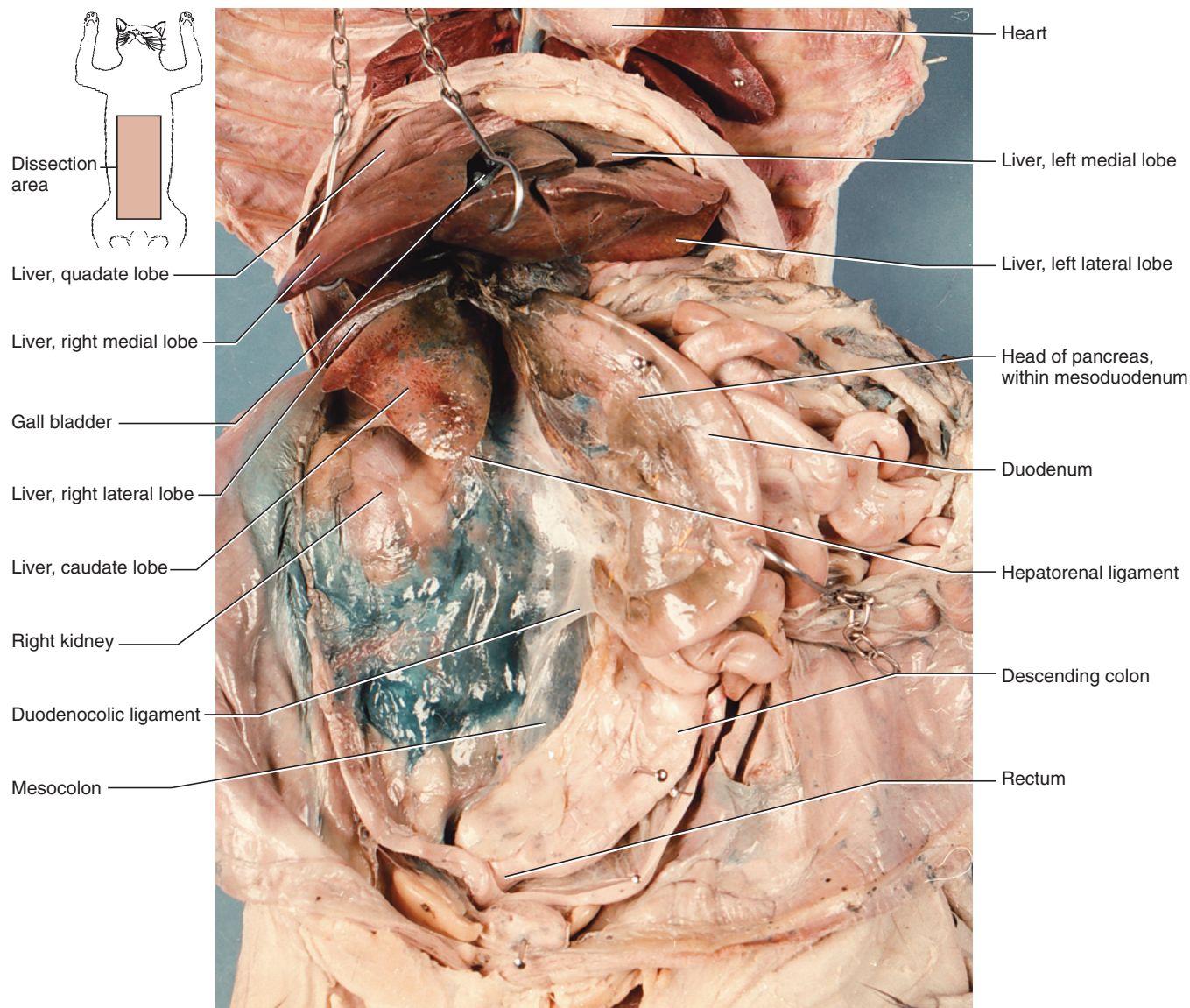
rior to the liver and stomach. It is subdivided into three parts. The **duodenum** is the short distal part, comprising the first loop of the small intestine. The rest of the small intestine is subdivided into the proximal **jejunum** and distal **ileum**. The small intestine is tightly coiled and ends toward the right posterior part of the abdominal cavity, where it passes into the large intestine or **colon**. A very short segment of the colon continues posterior to its union with the small intestine as the blind-ended **cecum**. The main part of the colon includes the **ascending colon**, which extends anteriorly on the right side, the **transverse colon**, which passes from right to the left, and the **descending colon**, which extends posteriorly on the left side. Note that the duodenum loops dorsal to the colon and that the jejunum and the rest of the small intestine pass ventrally to the rest of the colon. This position is due to rotation of the intestine during embryonic development. The colon continues into the **rectum**, which lies in the pelvic canal and leads to the **anus**.

Lift the coils of the small intestine to reveal the descending colon, extending posteriorly, on the left side of the abdominopelvic cavity (Figure 7.50). Pull it gently to see that it is suspended by the **mesocolon**, which has a broad attachment to the middorsal body wall. The rectum is supported by the **mesorectum**.

The duodenum extends posteriorly along the right side of the abdominopelvic cavity and then turns anteromedially. Lift the duodenum to reveal the caudate lobe of the liver. Gently tug the duodenum ventrally and note that it is supported by the **mesoduodenum** (Figure 7.50), within which is the **head of the pancreas**. The **duodenocolic ligament**, a small, triangular mesentery with a free posterior margin, extends between the mesoduodenum and mesocolon.

Examine the caudate lobe of the liver. The large oval swelling posterior to it is the right **kidney**. Lift the pos-





**FIGURE 7.50** Abdominopelvic cavity of the cat in ventral view, with liver, intestines, and pancreas reflected.

terior end of the caudate lobe. The **hepatorenal ligament**, a small triangular mesentery, extends between the posteromedial end of the caudate lobe and the peritoneum covering the kidney (Figure 7.50).

The jejunum and ileum, the distal parts of the small intestine, are supported by the **mesentery** proper (Figure 7.49). The mesentery has only a restricted attachment to the middorsal body wall, but it fans out to support all but the duodenal portion of the small intestine. Gently spread the coils of the intestine to see the mesentery clearly. Note the small **mesenteric lymph nodes** and the vessels within it.

The gall bladder is a sac used for bile storage. The various ducts associated with the gall bladder and liver are greenish, like the gall bladder itself. The ducts pass to the duodenum through the lesser omentum. To view

these structures, carefully dissect the lesser omentum near the caudate lobe of the liver and the gall bladder. Do not injure the vessels that are also present in the lesser omentum. The **cystic duct** (Figure 7.58) is the duct of the gall bladder. It extends a short distance toward the duodenum before it is joined by usually two **hepatic ducts** from the liver. The confluence of the cystic and hepatic ducts forms the **common bile duct**, which continues to the duodenum. Follow the common bile duct to its entrance into the duodenum.

Return to the ventral sheet of the omental bursa and cut across its attachment to the stomach. Examine the dorsal sheet and distinguish the tail of the pancreas (Figure 7.49). Follow the tail toward the right, noting that it is partly tucked behind the stomach and then curves ventrally along the medial side of the duodenum, within the mesoduodenum, as the head of the pancreas.

The pancreas consists of endocrine and exocrine glandular tissue. Of the two, the exocrine portion makes by far the largest part (the endocrine portion consists of small pockets of tissue termed *islets of Langerhans*, which cannot be distinguished grossly). The pancreas has two ducts that carry its exocrine secretion to the duodenum. The main **pancreatic duct** passes, together with the bile duct, to the duodenum. Find it in this region and trace it for a short distance into the head of the pancreas by carefully scraping away pancreatic tissue.

## KEY TERMS: DIGESTIVE AND RESPIRATORY SYSTEMS

abdominopelvic cavity	gall bladder
anterior vena cava	gastrosplenic ligament
anus	glottis
arytenoid cartilages	greater curvature
ascending colon	hepatic artery
auditory tube	hepatic ducts
bronchus: primary, secondary, tertiary (plur., bronchii)	hepatoduodenal ligament
caval fold	hepatogastric ligament
cecum	hepatorenal ligament
central tendon	ileum
colon	internal choanae
common bile duct	intestines
coronary ligament	jejunum
cricoid cartilage	kidney
cricothyroid muscle	labia (sing., labium) (lips)
cystic duct	laryngopharynx
descending colon	larynx
diaphragm	lateral ligaments
diaphragm	lesser curvature
diaphragm	lesser omentum
duodenocolic ligament	lesser peritoneal cavity
duodenum	lingual frenulum
epiglottal cartilage	lingual nerve
epiglottis	linguofacial vein (anterior facial vein)
epiploic foramen	liver: caudate lobe, left lateral lobe, right lateral lobe, right medial lobe, left medial lobe
esophagus	lung: anterior, middle, posterior, accessory lobes
facial nerve	
falciform ligament	
false vocal cords	
filiform papillae	
foliate papillae	
fungiform papillae	

lymph nodes	pharynx
mandibular duct	phrenic nerve
mandibular gland	pleura
maxillary vein (posterior facial vein)	posterior facial vein
median ligament	posterior vena cava
mediastinal septum	pulmonary ligament
mediastinum	pyloric sphincter
mesenteric lymph nodes	rectum
mesentery	root of the lung
mesocolon	round ligament
mesoduodenum	ruga (plur., rugae)
mesorectum	soft palate
mouth	spleen
nasopharynx	stomach
omental bursa	sublingual gland
oral cavity (= oral cavity proper + vestibule)	thoracic cavity
oral cavity proper	thorax
oropharynx	thyroid cartilage
palatal rugae	tongue
palatine tonsils	tonsillar fossae (tonsillar pits)
palatoglossal arches	trachea
pancreas: head, tail	tracheal cartilages
pancreatic duct	transverse colon
parietal peritoneum	urinary bladder
parietal pleura	vagus nerve
parotid duct	vallate papillae
parotid gland	vestibule
pericardial cavity	visceral pericardium
pericardium	visceral peritoneum
peritoneum	visceral pleura
	vocal cords

## SECTION V—CARDIOVASCULAR SYSTEM

### Heart

The **heart** lies within the **pericardial cavity**, which is isolated from the mediastinum by the **pericardium** (see page 186). To complete the study of the heart and its vessels, remove the pericardium carefully, especially near the roots of the lungs and where the great vessels leave the heart (see Figure 7.45). The heart has a flattened, anterior **base** and a pointed, posterior **apex**. Within the heart are the left and right **atria** (sing., **atrium**) anteriorly and the left and right **ventricles** posteriorly. The small arteries and veins on the surface of the heart are the **coronary**

**arteries** (red) and **veins** (blue), which respectively supply and drain the heart (see Figure 7.45).

On the ventral surface of the heart, the separation of the ventricles is marked by the **interventricular groove**, which passes anteriorly on the left to posteriorly on the right and is often filled with fat. A similar interventricular groove is also present on the dorsal surface of the heart. The separation between the atria and ventricles is represented by the **coronary sulcus**, which is also usually filled with fat. The lateral extension of each atrium is the **auricle** (Figures 7.52 and 7.53), which has scalloped margins and is usually darker than the rest of the heart tissue. The great vessels that leave the heart anteriorly pass between the left and right auricles.

Before examining the other structures of the circulatory system, it is useful to review the basic flow of blood. Oxygen-depleted blood from the body returns to the right atrium through the **anterior** and **posterior venae cavae** (sing., **vena cava**). From there, it is pumped to the right ventricle, which pumps it through the pulmonary arteries to the lungs for reoxygenation. From the lungs, oxygenated blood returns to the heart via the pulmonary veins to the left atrium. The blood then enters the left ventricle, which pumps it through the aorta and arteries to the rest of the body. Note that a vessel is defined based on the direction of blood flow within it (toward or away from the heart), not on the type of blood it carries (oxygenated or oxygen-depleted). A *vein* carries blood toward the heart, and an *artery* carries blood away from the heart.

## Vessels

### *Main Vessels Associated with the Heart*

The great vessels leave the base of the heart (Figures 7.45, 7.55). The **pulmonary trunk** leads from the right ventricle. It is located on the middle part of the ventral surface and angled toward the left. The **aorta**, carrying blood from the left ventricle, extends anteriorly just dorsal to the pulmonary trunk and medial to the right auricle. It curves sharply to the left as the **aortic arch**, and then posteriorly, passing dorsal to the root of the left lung, as the **thoracic aorta** (Figure 7.51). Dissect carefully between the aortic arch and pulmonary trunk to find a tough ligamentous band connecting these vessels. This is the **ligamentum arteriosum**, a remnant of the ductus arteriosus, through which blood was shunted in the fetus.

The pulmonary trunk is very short and divides almost immediately into left and right **pulmonary arteries** (injected with blue latex). The left pulmonary artery is clearly discernable as it passes laterally to the left lung. The right pulmonary artery passes under the aortic arch to reach the right lung. Blood from the lungs returns to

the left atrium through left and right **pulmonary veins** (injected with red latex), which are easily seen ventrally on the roots of the lungs (Figure 7.51). Blood from the body returns to the heart via the venae cavae. The **anterior vena cava**, draining the region anterior to the diaphragm, has already been noted during dissection of the mediastinum. The **posterior vena cava** drains the regions posterior to the diaphragm. Lift the right side of the heart and note these vessels entering the right atrium (Figures 7.42, 7.43, and 7.53).

The peripheral distribution, including the main branches and tributaries, of vessels that leave the heart is treated in the following sections. Diagrams that summarize the patterns are provided at the end of this Section in Figures 7.64–7.67.

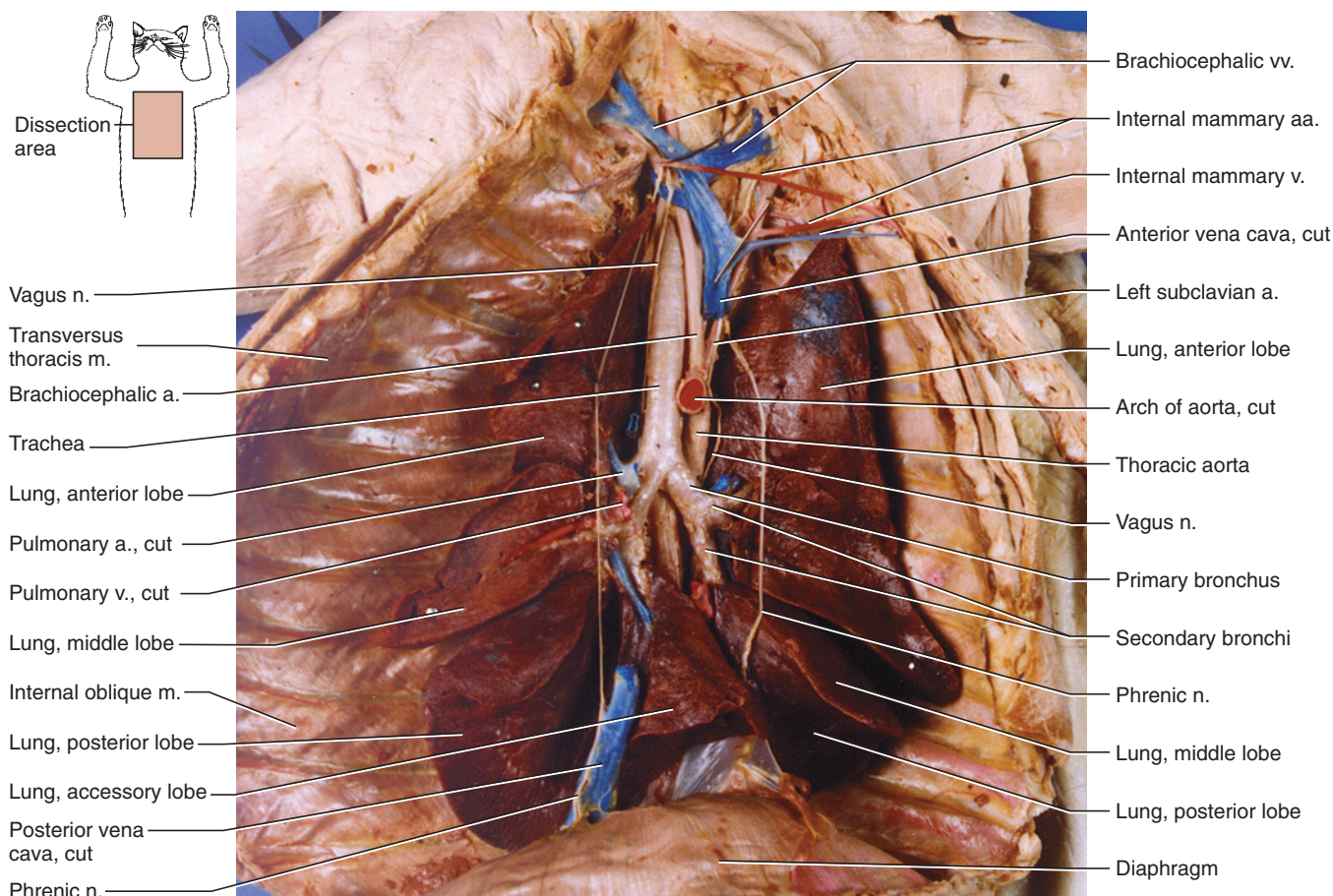
### *Vessels Anterior to the Diaphragm*

The vessels described here are branches of the aortic arch and thoracic aorta and tributaries of the anterior vena cava, which, respectively, mainly supply and drain the regions of the body anterior to the diaphragm. The summit of the aortic arch gives rise to two main vessels (Figures 7.55 and 7.56). The larger, on the right, is the **brachiocephalic artery**; the other is the left **subclavian artery**. The anterior vena cava lies just to the right of the brachiocephalic artery. To trace these vessels anteriorly, remove the connective tissue (including the thymus, which may be rather large in younger specimens) and fat associated with them, but avoid injuring the nerves.

Begin by tracing the main tributaries of the anterior vena cava (Figures 7.53 and 7.54). One or two small branches arise from the anterior vena cava, but its most posterior branch is the **azygos vein** (Figures 7.44, 7.53, and 7.54) from the dorsal surface of the vena cava; lift the heart to observe it. The azygos passes a very short distance dorsally, turns abruptly posteriorly, and then passes dorsal to the root of the right lung along the right side of the body. It mainly drains the intercostal areas posterior to the heart through the **intercostal veins** from both sides of the body. The anterior intercostal areas are drained by the **highest intercostal veins**. That of the right side often enters the anterior part of the azygos, but may enter the vena cava directly, a short distance anterior to the azygos. The left highest intercostal vein typically enters the left side of the vena cava between the second and third ribs. The **intercostal arteries** and **highest intercostal arteries** that supply these areas extend closely in parallel with the veins; their origins are considered below.

The next large branch, the **internal mammary vein**, enters the ventral surface of the anterior vena cava. It is a short trunk formed from the confluence of left and right **internal mammary veins**, which pass along the inner wall of the chest on either side of the sternum





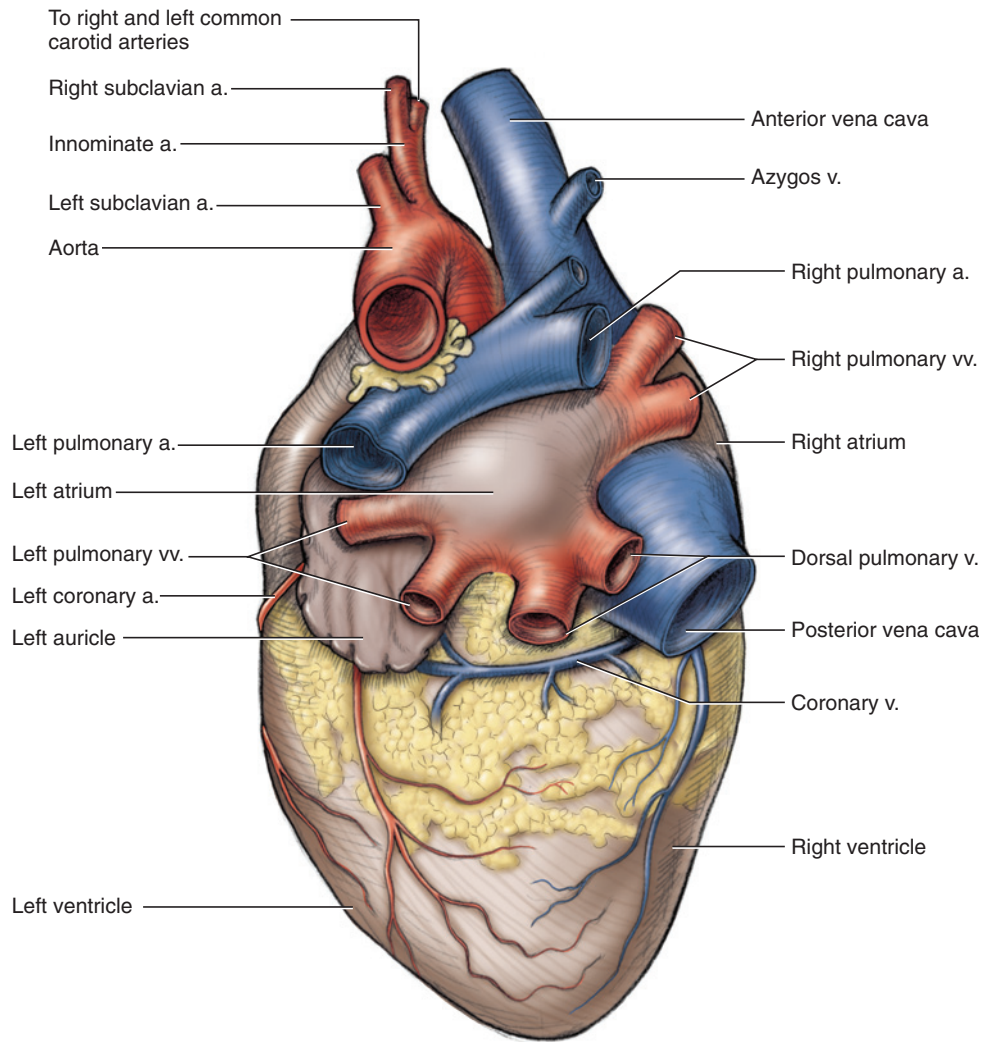
**FIGURE 7.51** Thoracic cavity of the cat in ventral view, showing respiratory system, vessels, and nerves.

(Figure 7.45). The left and right **internal mammary arteries** run, for most of their length, parallel to the veins. A short distance anterior to the internal mammary vein, the anterior vena cava is formed by the confluence of the left and right **brachiocephalic veins**. The tributaries of the brachiocephalic veins are similar but usually not symmetric. The **costocervical + vertebral trunk**, a large vein formed by the confluence of the **costocervical vein** and **vertebral vein**, commonly enters the right brachiocephalic dorsolaterally just before or very near the union of the right and left brachiocephalic veins. On the left side, the costocervical + vertebral trunk usually enters the left brachiocephalic slightly more anteriorly. In either case, the trunk curves dorsally. Follow the trunk to observe its tributaries. The vertebral vein heads almost directly anteriorly, whereas the costocervical heads mainly laterally and then posteriorly. In some specimens the right costocervical and vertebral veins have separate entrances, as is shown in the right side of Figure 7.54.

The brachiocephalic is typically formed by the **subclavian vein** and **bijugular trunk**, large vessels that unite just medial to the first rib. The subclavian passes laterally and helps drain the forelimb. The bijugular trunk

is a very short vessel formed by the large **external jugular vein** and the much smaller **internal jugular vein**. The external jugular passes anteriorly along the lateroventral surface of the neck, whereas the internal jugular vein passes more medially along the neck. The internal jugular primarily drains the palate, pharynx, and inside of the skull, and may not be injected. In some individuals, the internal and external jugular veins unite at about the same level as the subclavian; in others, the internal jugular may even join the brachiocephalic trunk. Thus, you will not necessarily be able to identify vessels based only on branching patterns; it is good practice to follow them distally toward the structures they serve. Do not confuse the internal jugular veins with the very small ventral thyroid vein. Although the latter is usually injected, it is a median unpaired vessel in the throat region. You will find an internal jugular vein lying just lateral to a common carotid artery (see below), whereas the ventral thyroid lies between the right and left common carotid arteries and empties into one of the brachiocephalic veins.

The external jugular helps drain two main areas, the forelimb and the external structures of the head. Drainage of the forelimb is accomplished through its first



**FIGURE 7.52** Heart and vessels of the cat in dorsal view.

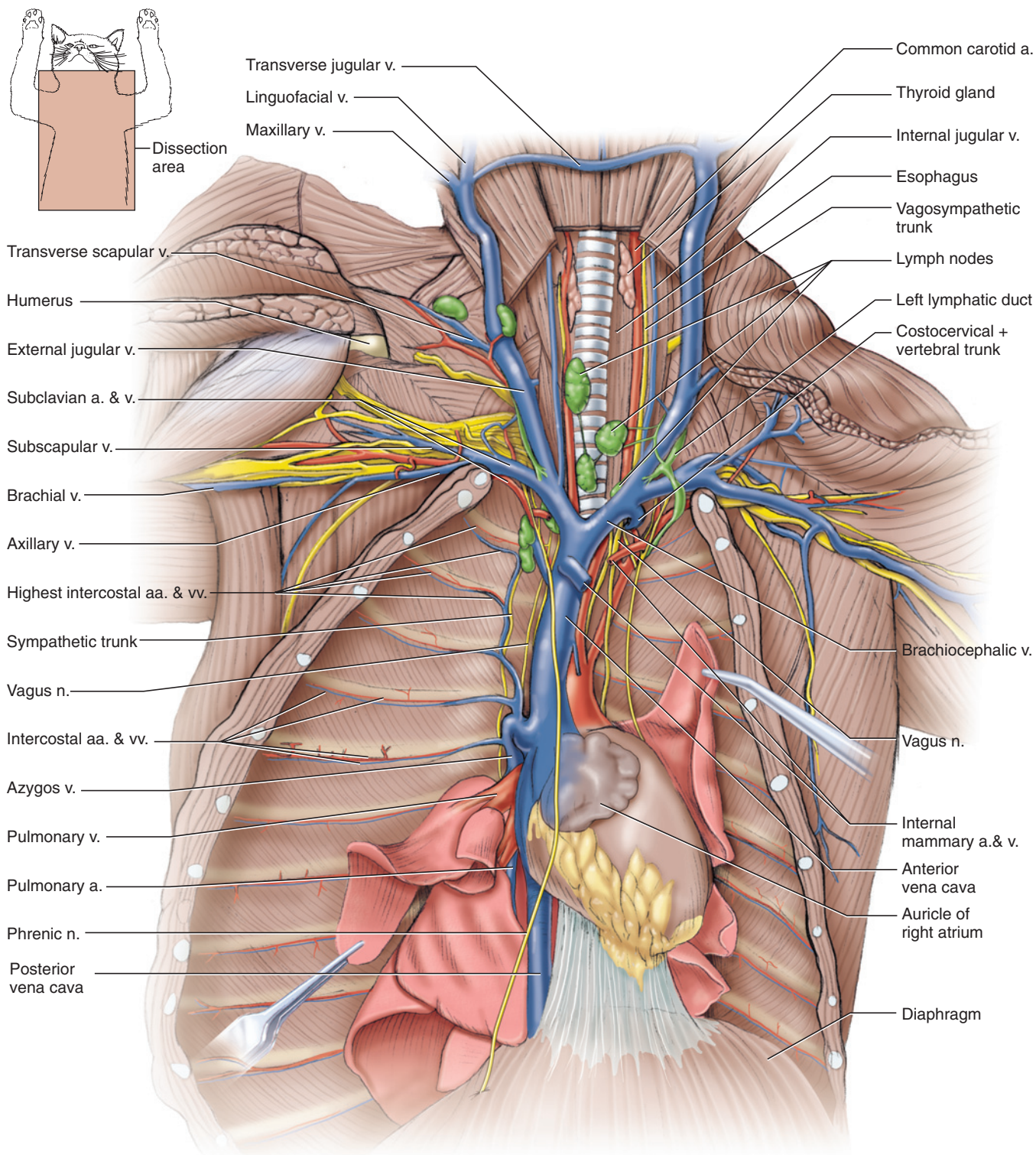
main tributary, the **transverse scapular vein**. As was observed earlier (page 163), this vessel enters the external jugular at about the level of the front of the shoulder. A main tributary of the transverse scapular is the **cephalic vein**, also observed earlier passing along the lateral surface of the forelimb (page 158). Further anteriorly the external jugular has three main tributaries, but their branching patterns vary (Figures 7.39 and 7.54). Often, they converge close together to form the external jugular. The **transverse jugular vein** forms a ventral link between the left and right external jugular veins, and helps drain the neck. The **anterior facial vein** passes anteriorly to the face and lower jaw. The **posterior facial vein** extends anterodorsally, crosses the mandibular gland, and passes deep to the parotid gland (see page 180).

Return to the aortic arch, and reidentify the brachiocephalic and left subclavian arteries (Figures 7.55 and 7.56). Just to the left of the subclavian, two slender **intercostal arteries** usually arise from the arch to help supply the more anterior intercostal regions. Follow

the aorta as it curves posteriorly and dorsally. Lift the left lung to observe the remaining intercostal arteries that arise from the thoracic aorta and are accompanied by the intercostal veins, which were described above. The left subclavian artery eventually supplies the left forearm, but before doing so gives off various substantial branches that supply other structures in the trunk and neck (as does the right subclavian artery). Tracing of these branches is deferred until the branches of the brachiocephalic artery have been studied.

The brachiocephalic artery heads anteriorly, just medial to the anterior vena cava. At about the level of the internal thoracic vein, it gives rise to three branches, the **right subclavian artery**, and the right and left **common carotid arteries**. The subclavian lies most laterally, while the common carotids pass anteriorly on either side of the trachea. The arteries pass deep to the anterior vena cava and brachiocephalic veins. The left common carotid sometimes arises independently, with the right common carotid and right subclavian arising further distally from





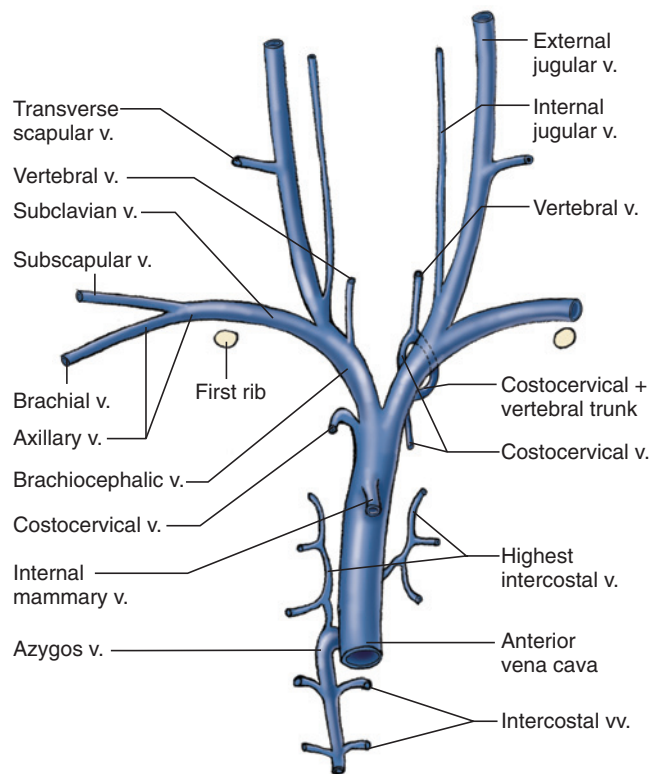
**FIGURE 7.53** Vessels and nerves anterior to the heart of the cat in ventral view.

a very short common trunk. All three arteries, however, may arise very close together.

As the common carotids ascend the neck, they send out various small branches to supply the thyroid gland, muscles, and lymph nodes. Note the nerves present in this region. The **phrenic** and **vagus** nerves were observed

passing through the thorax (Figures 7.42 and 7.43). In the cervical region, the vagus and the anterior extension of the **sympathetic trunk** (Figure 7.53) form the **vagosympathetic trunk**, which is bound together with the common carotid artery and internal jugular vein by a tough connective sheath. The vagus and sympathetic trunk separate near the branching of the brachiocephalic





**FIGURE 7.54** Schematic illustration of the veins anterior to the heart of the cat in ventral view.

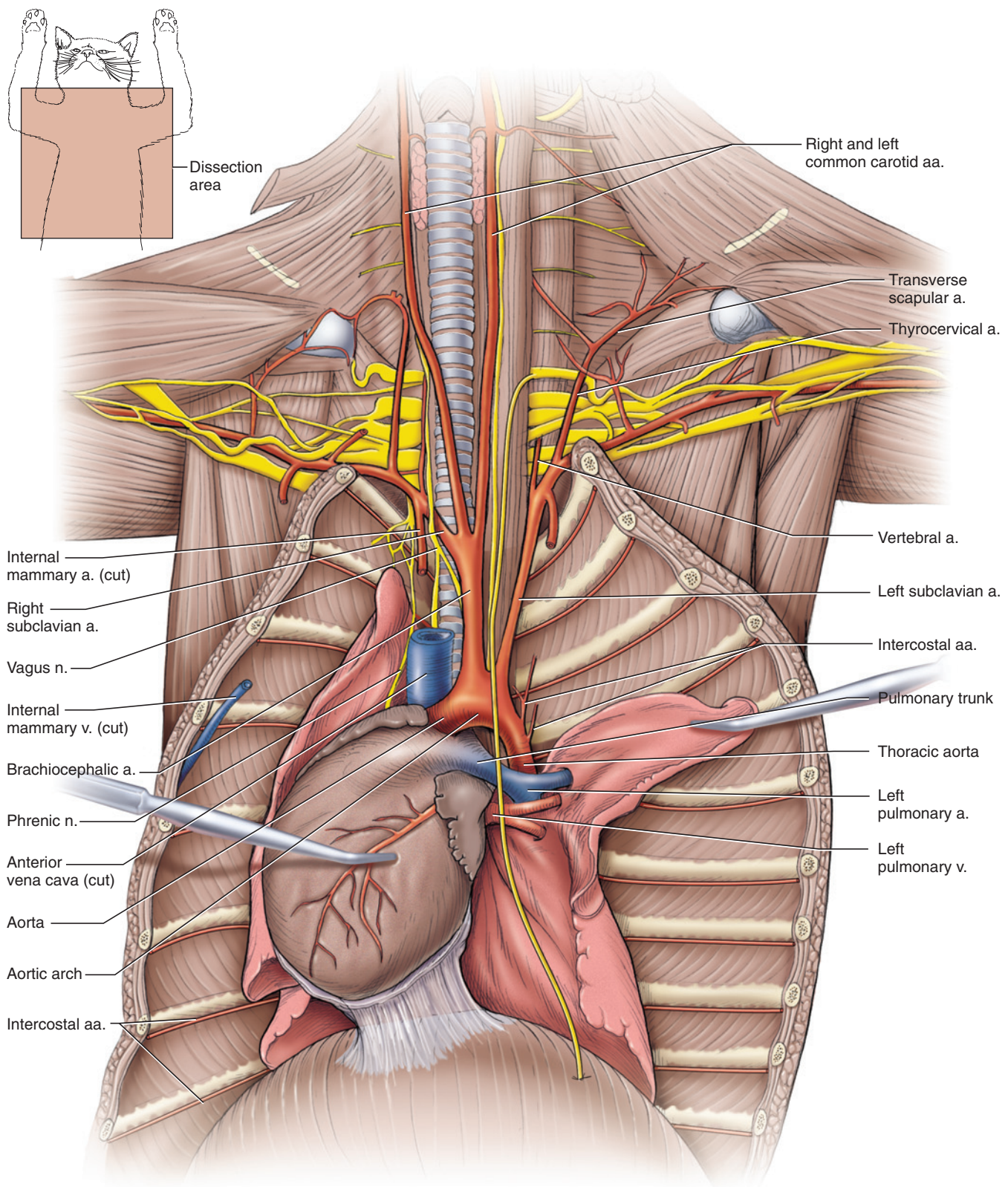
artery. The sympathetic trunk extends anteroposteriorly along the dorsal wall of the thorax, crossing ventral to the intercostal arteries and veins. Carefully dissect it out, and note the series of small ganglia along its course.

Follow one of the common carotids as it approaches the skull, near which it divides. Its main branch is the **external carotid artery**, which is as wide as the common carotid, so the division is not readily apparent (Figure 7.57). Find the branching point as follows. A short distance posterior to the masseter muscle, locate the **hypoglossal nerve**, which was observed earlier (page 179). The nerve crosses the very proximal part of the external carotid artery, so the division of the common carotid occurs just posterior to the nerve. Carefully dissect along the dorsal surface of the common carotid, just posterior to the hypoglossal nerve. In most mammals three small arteries usually arise in very close proximity. These are the internal carotid, **occipital**, and **ascending pharyngeal arteries**; the last two usually arise by a short, common trunk. These arteries can be dissected, but they may be difficult to find because they are small, are closely bound by connective tissue, and in the cat one of the arteries, the internal carotid artery, is largely occluded and represented by a whitish strand, the **internal carotid ligament** (only the proximal portion of the internal carotid artery is occluded. Its distal part, within the skull, remains functional, receiving blood via anastomoses with other arter-

ies, such as the maxillary and ascending pharyngeal.). The arteries and ligament pass anterodorsally, with the ligament being most posterior of the three. Thus, even though they arise almost together with the internal carotid ligament, the occipital and ascending pharyngeal arteries are actually the first branches of the external carotid artery. The ligament extends nearly dorsally, and so is not visible in Figure 7.57. These three small vessels may be observed, but this requires time and delicate dissection. If you cannot find them, use the hypoglossal nerve as a landmark to indicate the beginning of the external carotid.

The distribution of the main superficial vessels on the skull may be examined next. Anterior to the hypoglossal nerve, the external carotid gives rise to the **lingual artery**, which passes anteromedially toward the base of the tongue. The lingual artery is also crossed by the hypoglossal nerve. The external carotid continues as a large vessel and soon gives rise to the **facial artery**, which passes anteriorly along the ventral margin of the masseter muscle and subdivides into various branches to supply the jaws and facial structures. The external carotid continues dorsally, deep to the mandibular gland. Follow it by dissecting between the ventral parts of the mandibular and parotid glands. It gives rise first to the **posterior auricular artery**, a fairly large branch that extends dorsally behind the ear, and then the **superficial temporal artery**, a smaller branch, extending dorsally anterior to the ear. The superficial temporal divides into the **anterior auricular artery** and **transverse facial artery**. After it gives off the superficial temporal, the external carotid continues as the **maxillary artery**, a large vessel that passes into the dorsal part of the masseter muscle to supply orbital and palatal regions.

The regions supplied by the arteries discussed in the preceding paragraph are drained by veins that extend mainly parallel to the arteries but with slightly different branching patterns. Return to the external jugular vein and trace it forwards toward the skull. Three large vessels were noted in connection with the beginning of external jugular on page 180. These branches will now be considered in detail. The external jugular is formed by the confluence of the **maxillary vein** and **linguofacial vein**. The latter extends anteriorly between the two prominent lymph nodes lying ventral to the salivary glands (see page 180). The **transverse jugular vein** enters the very proximal end of the linguofacial vein, although in some individuals the transverse facial, linguofacial, and maxillary veins appear nearly to branch from the same point. Follow the linguofacial anteriorly. It is formed by the union of the **facial vein**, which extends along the ventral margin of the masseter muscle, and the **lingual vein**, which extends ventromedially in draining the mandible, lower lip, and tongue. The maxillary vein extends dorsally deep to the parotid gland. Follow it, dissecting away portions of the gland as necessary, to see the **posterior auricular vein**,



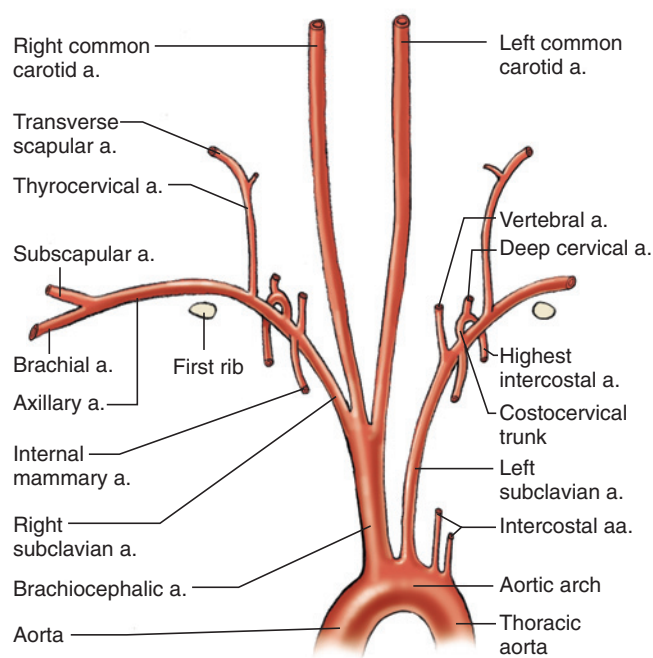
**FIGURE 7.55** Arterial, partial venous system and nerves anterior to the heart of the cat in ventral view.

from behind the ear, entering the maxillary. The latter continues a short distance anterodorsally to receive the **superficial temporal vein** and then continues deep to the posterodorsal margin of the masseter muscle. The superficial temporal receives the **anterior auricular vein** from in

front of the ear and continues anteriorly toward the eye as the **transverse facial vein**.

Finally, consider the branches of the subclavian arteries and veins (Figures 7.53–7.56). These vessels help supply





**FIGURE 7.56** Schematic illustration of the arteries anterior to the heart of the cat in ventral view.

and drain the forelimbs, as well as regions of the neck and thorax. Trace them on the side opposite that on which the forelimb muscles were dissected. For the most part, it is easier to find the arteries and then note the corresponding veins, which run beside them but are not injected.

The subclavian artery and vein pass toward the forelimb laterally, just in front of the first rib. Follow the subclavian artery. Just before it passes out of the thorax, it gives rise to four arteries. Dissect around the artery to find these branches. The **internal mammary artery** arises from the ventral surface of the subclavian artery and extends posteriorly. The left and right internal mammary arteries converge toward the ventral midline, and pass along either side of the sternum in parallel with the internal mammary veins, which was noted earlier (see page 196). If you have trouble locating its origin, follow the artery proximally to the subclavian artery from the midventral strip of the thorax. Note that the internal mammary vein empties into the anterior vena cava and not the subclavian vein. The **costocervical artery** arises from the posterodorsal surface of the subclavian almost opposite to the internal mammary artery. The costocervical is a short trunk that soon branches into two vessels. The **highest intercostal artery** is the smaller branch. It passes back over the medial surface of the first rib onto the anterior part of the thorax. The other, larger branch is the **deep cervical artery**, which extends almost directly dorsally to supply deep neck muscles.

The other two arteries, the **vertebral** and **thyrocervical arteries**, can be exposed by gently pulling the subclavian

posteriorly and carefully dissecting along its anterior surface. The vertebral artery is more medial and passes anteriorly and dorsally. The thyrocervical artery is more lateral. It passes anteriorly deep to the subclavian vein and then for a short distance follows along the dorso-lateral side of the external jugular vein. It gives off a small medial branch toward the thyroid and then passes laterally as the **transverse scapular artery**, in company with the transverse scapular vein, at about the level of the anterior part of the shoulder.

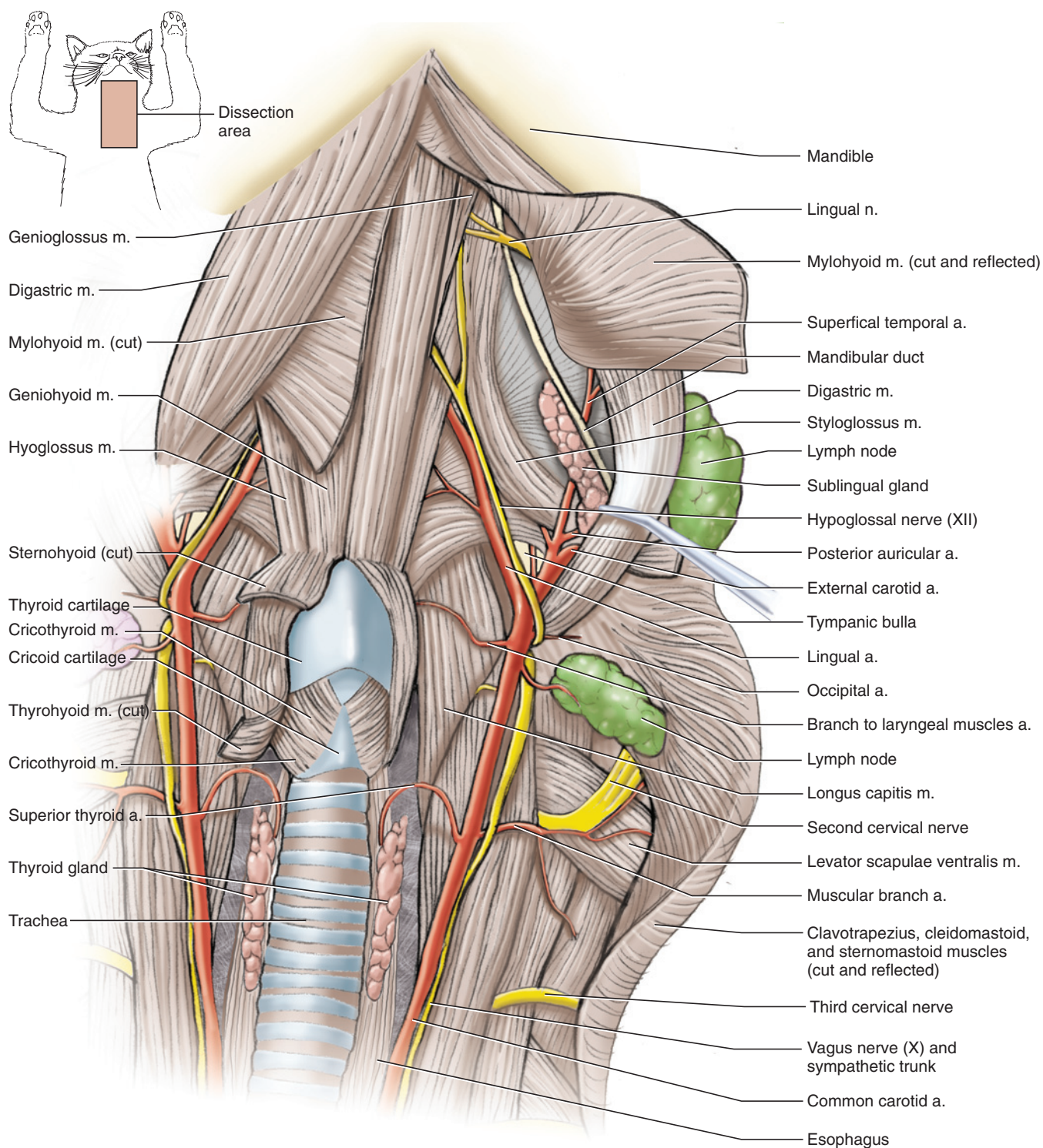
Just anterior to the first rib, the subclavian artery and vein pass from the thorax into the axilla (armpit) as the **axillary artery and vein**. These vessels and their branches extend toward the forelimb in company with the complex of nerves termed the *brachial plexus*, which was examined briefly in Section III, so the vessels require careful dissection. The axillary artery sends out various branches, mainly to surrounding pectoral musculature, before it branches into two large vessels, the **brachial artery**, which continues onto the medial surface of the brachium, and the **subscapular artery**, which extends into the musculature toward the anterior part of the shoulder. The axillary vein receives the **subscapular vein**. Distally it follows the subscapular artery, but it enters the axillary vein more proximally than the origin of the subscapular artery from the axillary artery. The axillary vein continues distally, receiving tributaries from the surrounding musculature, and passes onto the medial surface of the brachium as the **brachial vein**.

### *Vessels Posterior to the Diaphragm*

The vessels considered here mainly supply and drain the musculature and organs in the posterior part of the body. Trace the **posterior vena cava** posteriorly from the heart (Figures 7.42, 7.43, 7.45, 7.46, 7.53, and 7.54). It passes through the diaphragm and enters the liver. It receives several **hepatic veins** from the liver, but does not drain the liver directly. Scrape away some of the liver, just anterior to its quadrate lobe, to expose the veins. The posterior vena cava continues through the liver. It emerges into the abdominopelvic cavity from beneath the caudate lobe of the liver, passes between the left and right kidneys, and continues posteriorly (Figures 7.58 and 7.59). Return to the thoracic aorta and, lifting the left lung, trace it posteriorly (Figure 7.51). It passes through the diaphragm and into the abdominopelvic cavity as the **abdominal aorta**, and extends posteriorly to the left of the posterior vena cava (Figure 7.58).

Push the digestive tract and spleen to the right, so you can view the abdominal aorta from the left side. Immediately on passing through the diaphragm, it gives rise to the **celiac artery** and then the **anterior mesenteric artery**, both large, unpaired vessels that mainly supply the viscera (Figure 7.58). With the viscera pushed to the right, these vessels pass directly laterally toward the

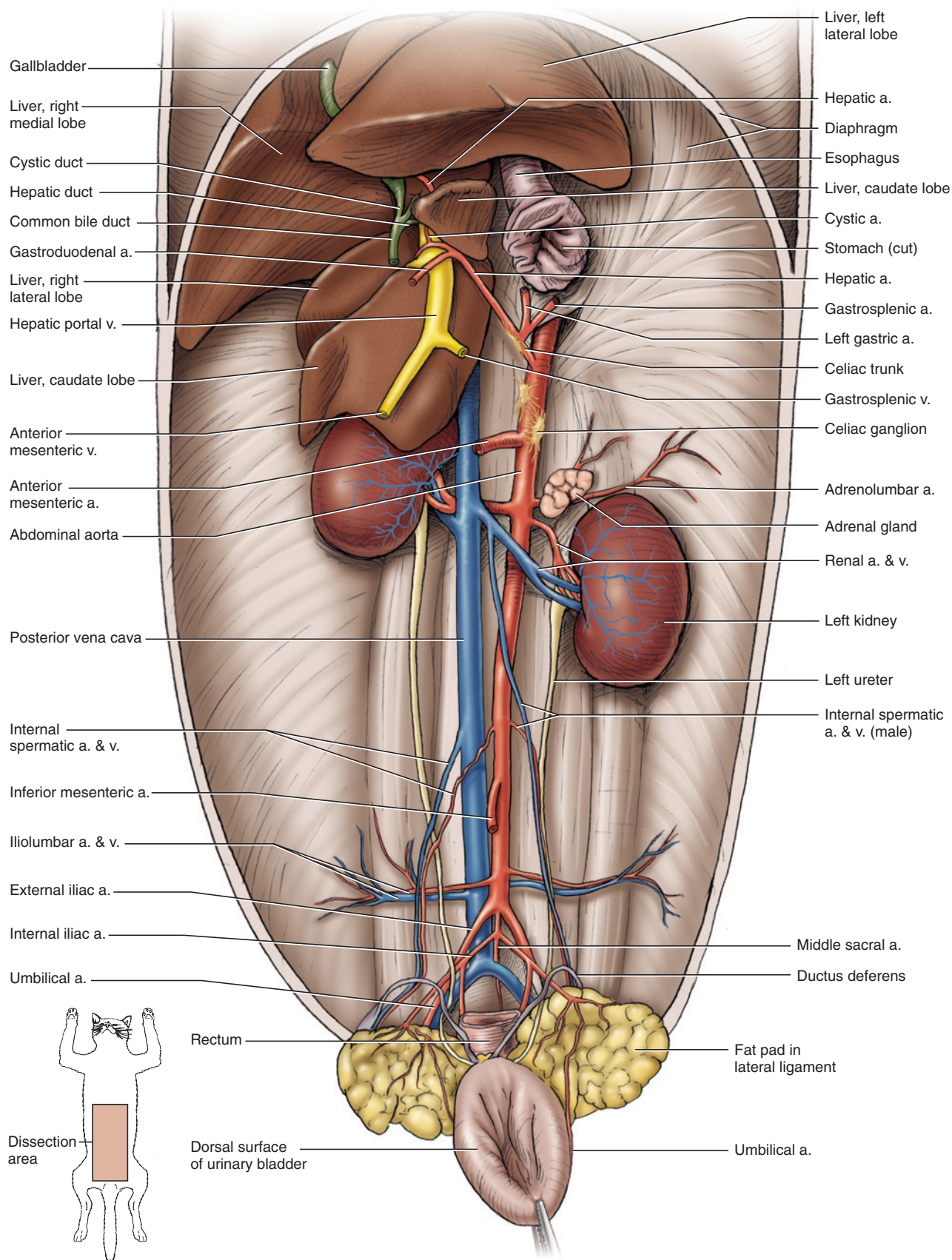




**FIGURE 7.57** Branches of the common carotid artery, and muscles and nerves of the throat of the cat in ventral view.

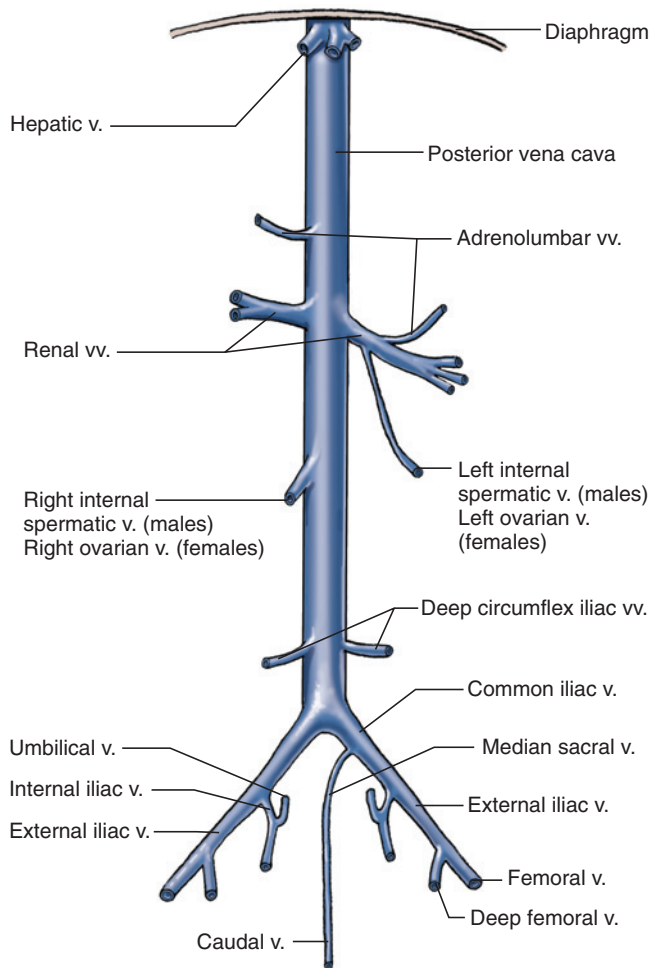
right. They will be traced shortly. The veins that drain these structures are part of the **hepatic portal system** and are also discussed below. Careful dissection will reveal several ganglia along the ventral surface of the aorta between the origins of these arteries. Continue to follow the aorta posteriorly. The next large branches of the aorta are the paired **renal arteries**. Remove the peri-

toneum covering the kidneys, and follow the right and left renal arteries as they pass toward the central part of the medial surface of each kidney. As the right kidney lies slightly anterior to the left kidney, the right renal artery is slightly anterior to the left renal artery. The **renal veins** (Figures 7.58 and 7.59), of which the left is usually larger, follow the renal arteries.



**FIGURE 7.58** Abdominopelvic cavity of the cat showing arteries and veins posterior to the heart, with most of digestive system removed and urinary bladder reflected, in ventral view.

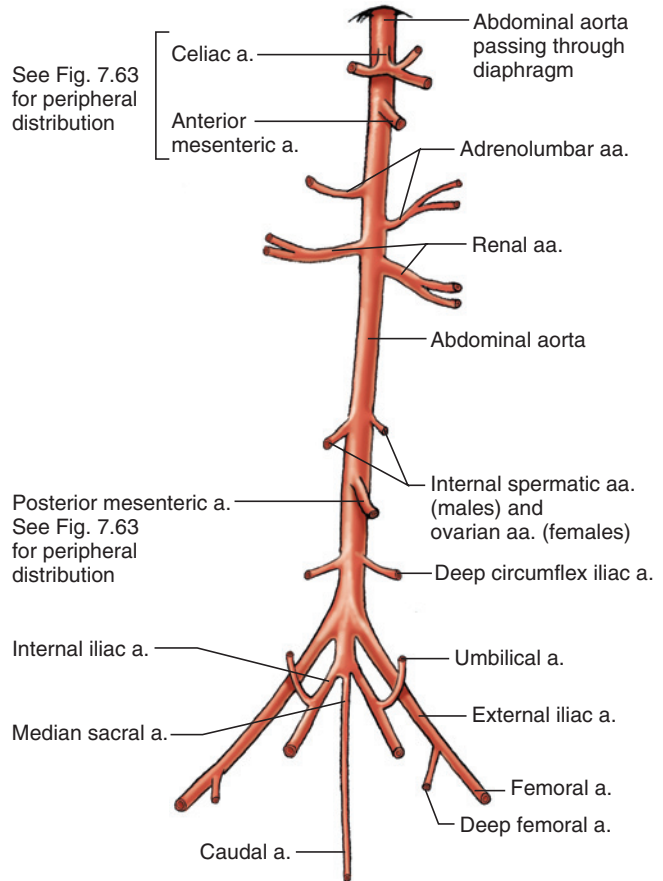




**FIGURE 7.59** Schematic illustration of the veins posterior to the heart of the cat in ventral view.

Between the anterior mesenteric and renal arteries, the aorta usually gives rise to slender and paired **adrenolumbar arteries**, which may also arise from the renal arteries (Figures 7.58 and 7.60). On each side, the adrenolumbar artery supplies and passes the small, nodular **adrenal gland**. The right adrenal gland lies between the anterior end of the kidney and the vena cava, and the left adrenal gland lies between the kidney and the aorta. Remove the fat and tissue from around the glands to expose them. Lifting the kidneys, follow the adrenolumbar arteries. They continue onto the dorsal wall of the abdominal cavity. The **adrenolumbar veins** accompany the arteries. They may empty into the posterior vena cava or the renal veins (Figures 7.58 and 7.59).

Posterior to the renal arteries, the aorta gives rise to paired gonadal arteries, **internal spermatic arteries** in the male and **ovarian arteries** in the female (Figures 7.58, 7.60). In the female they pass almost directly laterally to the ovaries, which lie at the anterior end of each uterine horn, the paired proximal extensions of the uterus (Figure 7.71). In the male, however, the internal spermatic arteries extend posteriorly, through the



**FIGURE 7.60** Schematic illustration of the arteries posterior to the heart of the cat in ventral view.

abdominal wall (by way of the inguinal canal) to the scrotum, which contains the testes (Figures 7.58, 7.70). The right **ovarian** and **internal spermatic veins** closely follow the corresponding arteries to enter the posterior vena cava. On the left side, however, the proximal portions of the artery and vein are further apart because the vein enters the renal vein.

The next aortic branch, the **posterior mesenteric artery**, is an unpaired vessel arising from the ventral surface of the aorta that helps supply the viscera. Its peripheral distribution is discussed below. Almost immediately posterior to the origin of the inferior mesenteric artery, the aorta gives rise to the paired **deep circumflex iliac arteries**. The **deep circumflex iliac veins** closely follow the arteries to enter the posterior vena cava.

Just beyond these vessels, the aorta gives rise to two large branches, the **external iliac arteries**, which extend posterolaterally into each hindlimb. The aorta continues as a narrower vessel for a very short distance before giving off the **internal iliac arteries**, which also extend posterolaterally but are smaller than the external iliacs. Follow the internal iliacs for a short distance to see that they give off branches to the pelvic viscera. Past the origin of the internal iliacs, the aorta continues as the



small **median sacral artery** and then enters the tail as the **caudal artery** (but you will not look for it).

In contrast to the similar branching patterns of most of the paired arteries and veins of the aorta and posterior vena cava, the patterns of the iliac arteries and veins differ. Near the origin of the external iliac arteries, the posterior vena cava begins with the confluence of two large tributaries, the **common iliac veins**. Each common iliac vein, in turn, is formed by the confluence of the **internal** and **external iliac veins**. The **median sacral vein**, which accompanies the median sacral artery, usually joins one of the common iliac veins and continues in the tail as the **caudal vein**.

Return to the external iliac arteries and follow one of them distally. It passes through the abdominal wall and enters the hindlimb as the **femoral artery**. Just before it passes through the body wall, it gives rise from its medial surface to the **deep femoral artery**. The latter gives rise to several branches and then passes deep into the medial side of the thigh (see also Figure 7.32). The internal iliac artery mainly supplies muscular and visceral structures in the pelvic canal. Its first branch, the **umbilical artery**, supplies the urinary bladder. The **femoral vein** and **deep femoral vein** empty into the external iliac vein. The **umbilical vein** usually empties into the internal iliac vein.

### *Vessels Associated with the Viscera*

In this section, the vessels that supply and drain the viscera are examined. The arterial system consists of three vessels, the celiac, anterior mesenteric, and posterior mesenteric arteries, and their branches. Their origin from the aorta have already been identified. The structures supplied by these arteries are drained by tributaries that ultimately form the **hepatic portal vein**, which returns blood to the liver (Figures 7.58, 7.61, and 7.62). The hepatic portal breaks up into capillaries within the liver. These re-collect into several hepatic veins, which then enter the posterior vena cava.

Reflect the viscera to the right, and locate the origins of the celiac and anterior mesenteric arteries as they first arise from the aorta, as it emerges through the diaphragm, and then extend toward the right. The celiac is a short trunk that divides into three branches. Two of these, the **hepatic** and **left gastric arteries**, slant anteriorly toward the right in this view. The third, the **splenic artery**, is the largest and extends almost directly toward the right. You can easily follow the hepatic for about 2 cm in this view, but change perspective to follow it more distally.

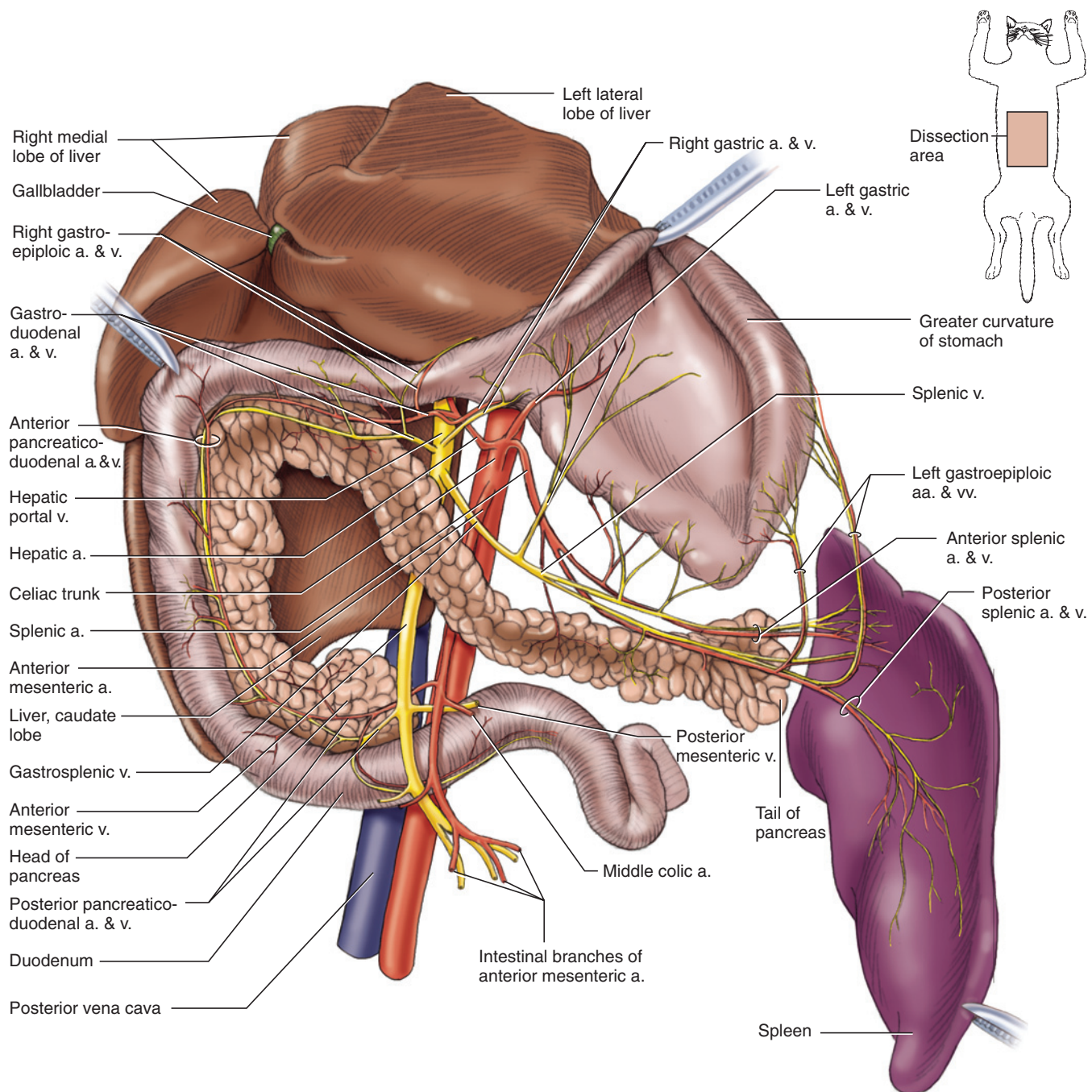
Reflect the viscera (including the duodenum and head of the pancreas) to the left, and locate the hepatic portal vein, sitting primarily on the caudate lobe of the liver, and the common bile duct as it extends toward the duo-

denum; these structures were exposed earlier (page 191). The hepatic portal is difficult to see if it is not injected. Carefully dissect along the hepatic portal vein, freeing it as much as possible from connective tissue without destroying any of its branches. (In some specimens the vein is injected with yellow latex, which greatly facilitates dissection.) In doing so, you should reveal the hepatic artery (Figures 7.61 and 7.63). Ascertain that this is indeed the hepatic artery by reflecting the viscera to the right again, gently but firmly grasping the hepatic artery with blunt forceps, and then reflecting the viscera to the left again, thus verifying that the gripped vessel is the one you saw from the other view. This method of using forceps to identify a vessel can be used to advantage in many situations.

Follow the hepatic artery anteriorly. Near the anterior margin of the caudate lobe, it usually gives off several branches, three of which can be followed into the lobes of the liver. The fourth, the **gastroduodenal artery**, follows the common bile duct as it heads toward the duodenum. Trace it until it divides into posteriorly curving and anteriorly curving branches dorsal to the pylorus. The posterior branch, the **anterior pancreaticoduodenal artery**, passes between the duodenum and pancreas. The anterior branch, the **right gastroepiploic artery**, passes to the distal part of the greater curvature of the stomach. Follow the right gastroepiploic artery with the duodenum in natural position but with the stomach reflected anteriorly (i.e., so you view its dorsal surface). The arteries are followed closely by corresponding veins. Trace the **right gastroepiploic vein** and **anterior pancreaticoduodenal vein**; their confluence forms the **gastroduodenal vein**, which enters the hepatic portal vein.

With the stomach reflected anteriorly, gently pull the tail of the pancreas posteriorly. Dissect away the connective tissue and fat between the pancreas and stomach to reveal a system of arteries and veins. Then, reflect the viscera to the right and grasp the left gastric artery with forceps, and again reflect the stomach anteriorly. Trace the left gastric artery as it passes onto the lesser curvature of the stomach. The **left gastric vein** accompanies the artery.

The splenic artery passes to the left toward the spleen (verify this by reflecting the viscera to the right and grasping the vessel with forceps). The **gastrosplenic vein**, which accompanies the splenic artery, is conspicuous even in uninjected specimens. It is formed by the confluence of the gastric vein and the **splenic vein**. Follow the splenic artery and vein. After one or two small branches to the stomach, the vein and artery divide. Follow the vein first, with both the stomach and spleen reflected anteriorly. In this view, one tributary, the **anterior splenic vein**, heads almost directly laterally and drains the left side of the spleen; the other, the **posterior splenic vein**, passes posterolaterally and drains the right

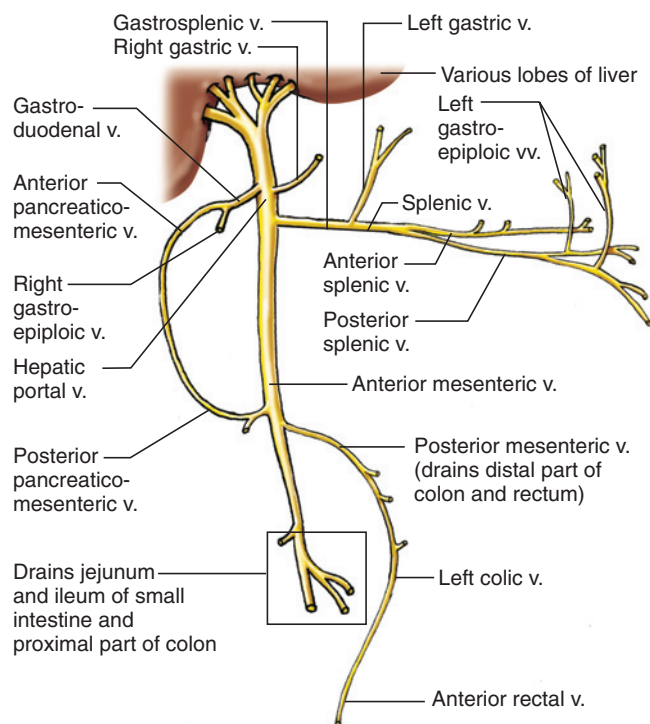


**FIGURE 7.61** Detail of vessels of the viscera, showing liver (reflected) stomach, duodenum, pancreas, and spleen (reflected) of the cat in ventral view.

side of the spleen. The **anterior** and **posterior splenic arteries** also follow this pattern, but the right splenic artery lies deep to the vein and is not apparent at first. Trace the left splenic artery and vein into the spleen. Some of their branches will be seen to stretch across to the greater curvature of the stomach. These are the **left gastroepiploic arteries and veins**.

Work your way back proximally along the gastrosplenic vein. Its confluence with the **anterior mesenteric vein**, oriented nearly anteroposteriorly, forms the hepatic

portal vein. Dissect along the anterior mesenteric vein for about 3 cm. With the viscera reflected to the right, trace the anterior mesenteric artery as it angles posteriorly to the right. Note the anterior mesenteric vein converging toward the artery. Continue to expose the anterior mesenteric artery. You will need to move through the coils of the intestines individually and tear the mesentery binding the coils together. As the artery and vein extend distally, they give off numerous branches, which mainly supply and drain the jejunum, ileum, cecum, and proximal portion of the colon (Figure 7.49).

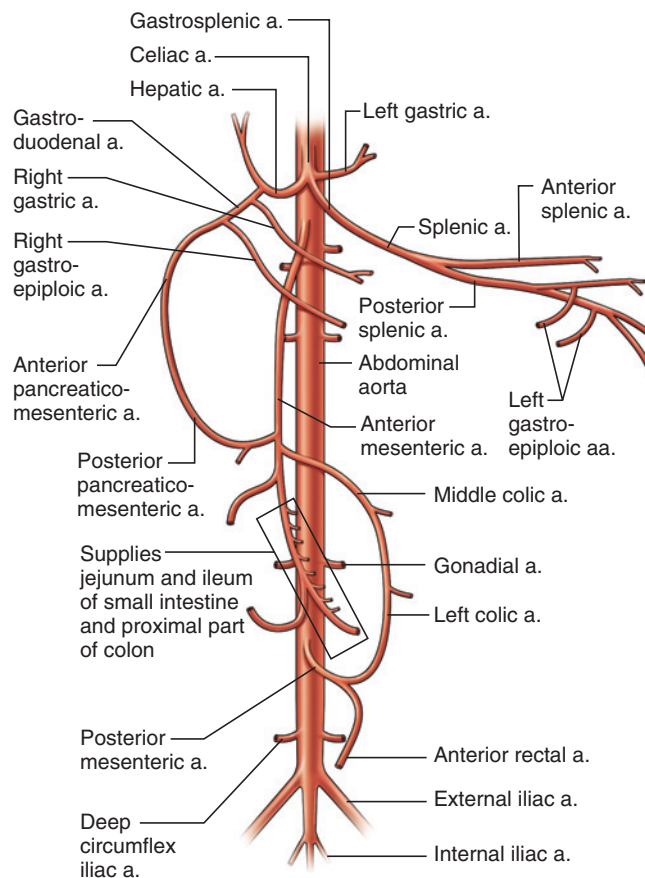


**FIGURE 7.62** Schematic illustration of the hepatic portal system of the cat in ventral view.

Two proximal branches of the anterior mesenteric artery should be traced. They often arise in close proximity, and either may have the more proximal origin. The **posterior pancreaticoduodenal artery** extends to the distal part of the duodenum and head of the pancreas. It passes anteriorly and anastomoses with the anterior pancreaticoduodenal artery. If you have trouble tracing the posterior pancreaticoduodenal artery from the anterior mesenteric, begin by tracing the anterior pancreaticoduodenal artery posteriorly, and then follow the posterior pancreaticoduodenal artery to the anterior mesenteric artery. The artery is accompanied by the **posterior pancreaticoduodenal vein**, which empties into the anterior mesenteric vein.

The other branch of the anterior mesenteric artery is the **middle colic artery**. It gives off various branches, but its main part continues posteriorly along the medial side of the descending colon. The vein that accompanies the artery proximally is the **posterior mesenteric vein**, which empties into the anterior mesenteric vein near the entrance of the posterior pancreaticoduodenal vein.

Next, trace the **posterior mesenteric artery**. It is the smallest and least complexly branched of the arteries that supply the viscera. Usually, the posterior mesenteric artery forms a short trunk that branches into the **left colic artery** and the **anterior rectal artery**. The left colic passes anteriorly on the surface of the descending colon and anastomoses with the middle colic artery. The anterior rectal artery passes posteriorly to supply



**FIGURE 7.63** Schematic illustration of the visceral arterial system of the cat in ventral view.

the distal end of the colon and the rectum. These arteries are accompanied by the posterior continuation of the posterior mesenteric vein, which sequentially becomes the **left colic vein** and the **anterior rectal vein**.

### KEY TERMS: CARDIOVASCULAR SYSTEM

abdominal aorta	anterior rectal vein
adrenal gland	anterior splenic artery
adrenolumbar artery	anterior splenic vein
adrenolumbar vein	anterior vena cava
anterior auricular artery	aorta
anterior auricular vein	aortic arch
anterior mesenteric artery	apex of heart
anterior mesenteric vein	ascending pharyngeal artery
anterior pancreaticoduodenal artery	atrium (plur., atria)
anterior pancreaticoduodenal vein	auricle
anterior rectal artery	axillary artery
	axillary vein
	azygos vein
	<i>Continues</i>



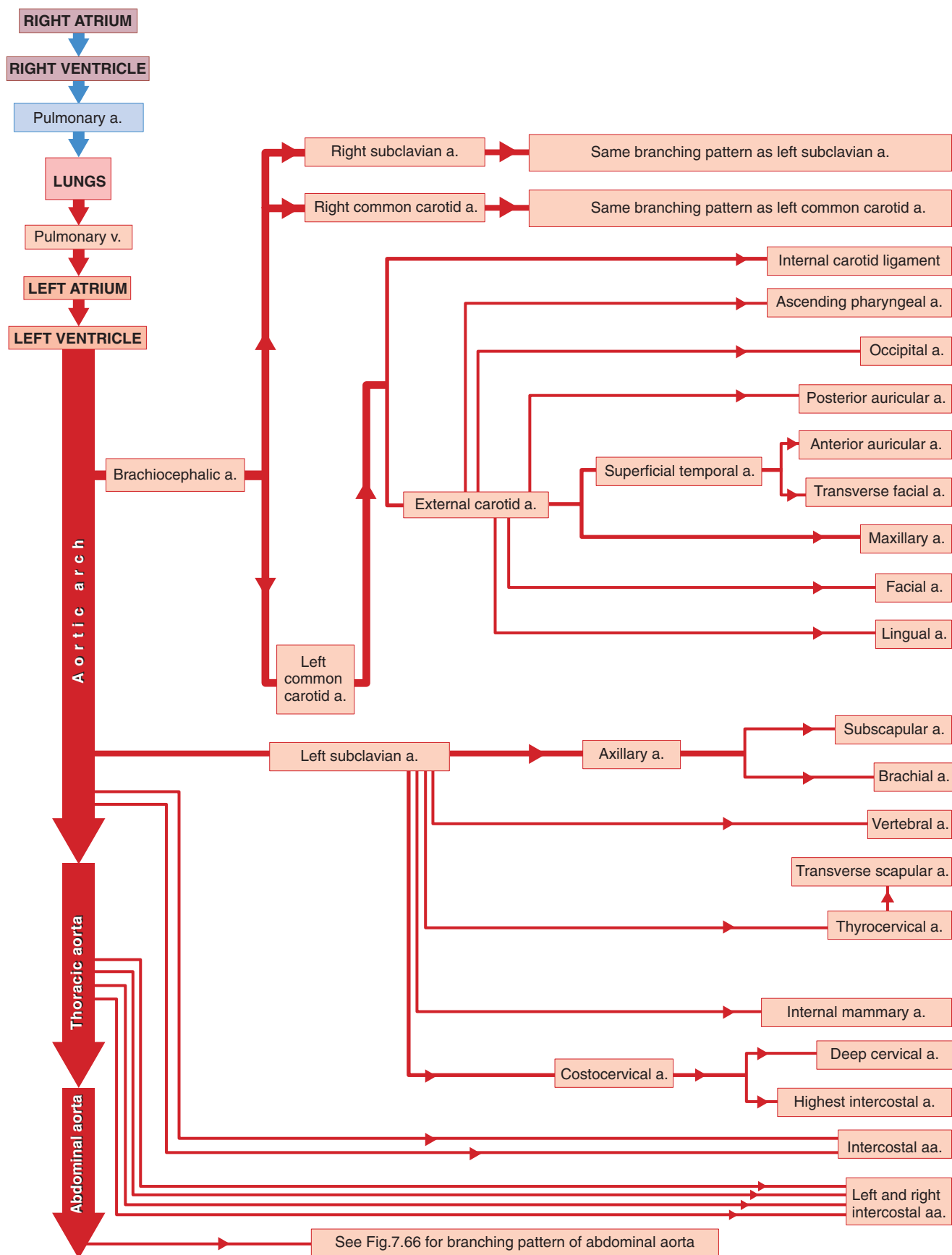
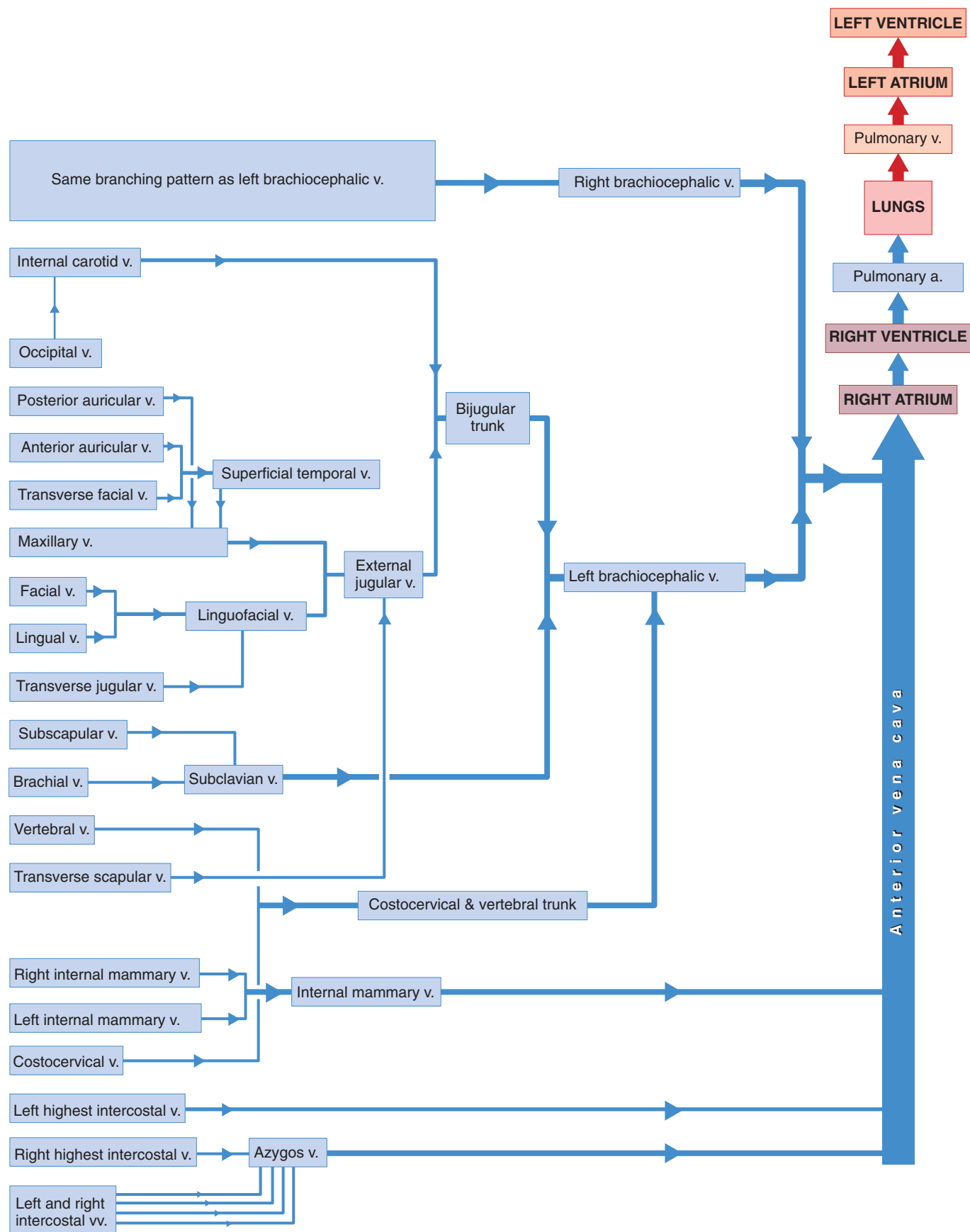
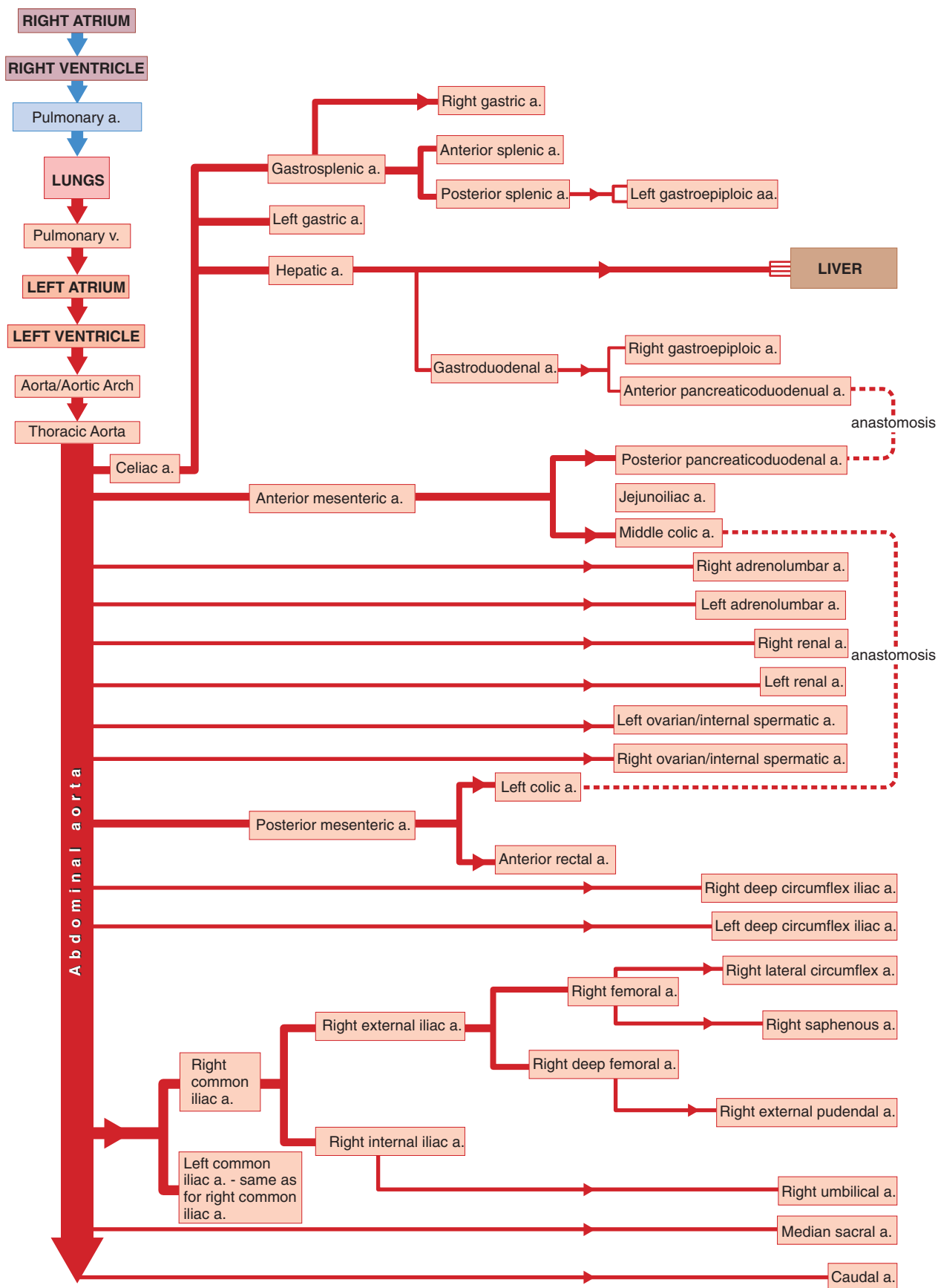


FIGURE 7.64 Flow chart diagram of the arterial system anterior to the heart of the cat.

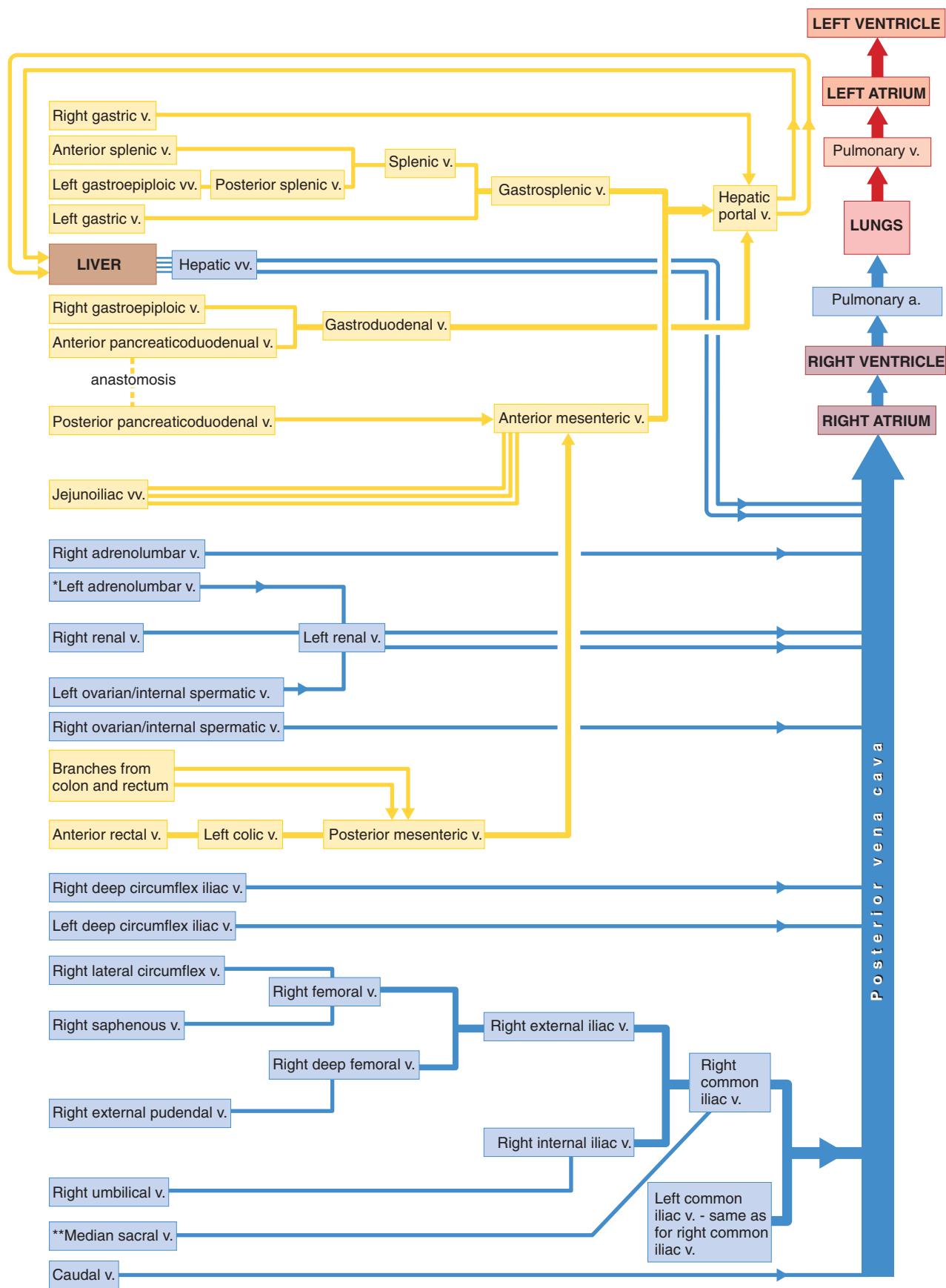


**FIGURE 7.65** Flow chart diagram of the venous system anterior to the heart of the cat.



**FIGURE 7.66** Flow chart diagram of the arterial system posterior to the heart of the cat.





**FIGURE 7.67** Flow chart diagram of the venous system posterior to the heart of the cat. \*May instead enter the posterior vena cava directly. \*\*May instead enter the left common iliac vein.

base of heart  
brachial artery  
brachial vein  
brachiocephalic artery  
brachiocephalic vein  
caudal artery  
caudal vein  
celiac artery  
cephalic vein  
common carotid artery  
common iliac vein  
coronary artery  
coronary sulcus  
coronary vein (cardiac vein)  
costocervical artery  
costocervical vein  
costocervical + vertebral trunk  
deep cervical artery  
deep circumflex iliac artery  
deep circumflex iliac vein  
deep femoral artery  
deep femoral vein  
external carotid artery  
external iliac artery  
external iliac vein  
external jugular vein  
facial artery  
facial vein  
femoral artery  
femoral vein  
gastroduodenal artery  
gastroduodenal vein  
gastroepiploic vein  
gastrosplenic vein  
heart  
hepatic artery  
hepatic portal system  
hepatic portal vein  
hepatic vein  
highest intercostal arteries

highest intercostal veins  
hypoglossal nerve  
intercostal artery  
intercostal vein  
internal carotid artery  
internal carotid ligament  
internal iliac artery  
internal iliac vein  
internal jugular vein  
internal mammary artery  
internal mammary vein  
internal spermatic artery  
internal spermatic vein  
interventricular groove  
left colic artery  
left colic vein  
left gastric artery  
left gastric vein  
left gastroepiploic artery  
left gastroepiploic vein  
ligamentum arteriosum  
lingual artery  
lingual vein  
linguofacial vein (anterior facial vein)  
maxillary artery  
maxillary vein (posterior facial vein)  
median sacral artery  
median sacral vein  
middle colic artery  
occipital artery  
ovarian artery  
ovarian vein  
pericardial cavity  
pericardium  
phrenic nerve  
posterior auricular artery  
posterior mesenteric artery  
posterior mesenteric vein

posterior pancreaticoduodenal artery  
posterior pancreaticoduodenal vein  
posterior splenic artery  
posterior splenic vein  
posterior vena cava  
pulmonary arteries  
pulmonary trunk  
pulmonary vein  
renal artery  
renal vein  
right gastroepiploic artery  
splenic artery  
splenic vein  
subclavian artery  
subclavian vein  
subscapular artery

subscapular vein  
superficial temporal artery  
superficial temporal vein  
sympathetic trunk  
thoracic aorta  
thyrocervical artery  
transverse facial artery  
transverse facial vein  
transverse jugular vein (hyoid venous arch)  
transverse scapular artery  
transverse scapular vein  
umbilical artery  
umbilical vein  
vagosympathetic trunk  
vagus nerve  
ventricle  
vertebral artery  
vertebral vein

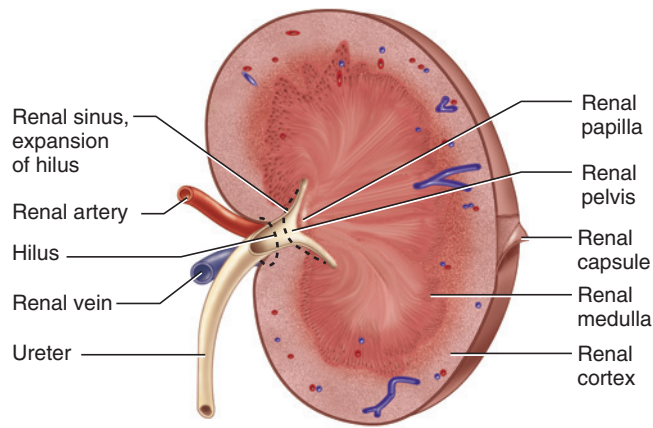
## SECTION VI—UROGENITAL SYSTEM

The urogenital system includes the excretory and reproductive systems, which perform distinct roles. The excretory system mainly functions in helping to maintain homeostasis by maintaining water balance and ridding the body of nitrogenous waste products. The reproductive system functions in producing gametes (sperm or ova), meeting all the needs of the fetuses during gestation (in the female), and maintaining gender-specific features, mainly through the production of hormones. Despite the fact that the two systems are distinct, their accessory structures, particularly in the male, become intimately associated. Thus, it is convenient to consider them together as the *urogenital system*.

### Excretory System

The **kidneys** (Figures 7.58, 7.68, 7.69, 7.71), the main organs of the excretory system, were exposed during the dissection of the circulatory system. They are retroperitoneal, lying dorsal to the parietal peritoneum in the lumbar region. The kidneys are surrounded by considerable fat that protects them from mechanical injury. Note that the left kidney lies slightly posterior to the right kidney, which abuts anteriorly against the caudate lobe of the liver.

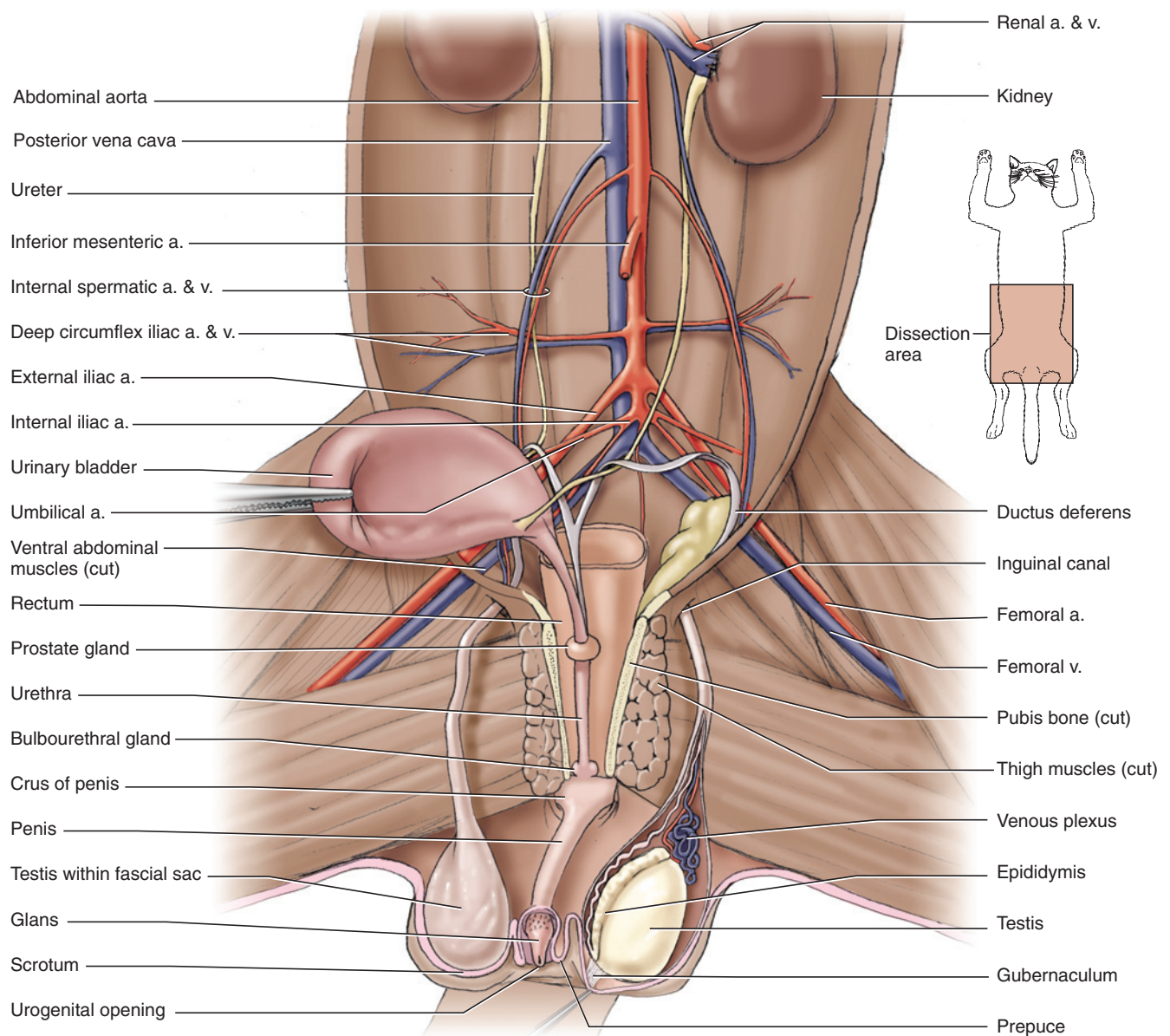
Each kidney is bean-shaped and covered by a thin, tough, fibrous **renal capsule**. The **hilus** is a medial inden-



**FIGURE 7.68** Frontal section through left kidney of the cat.

tation through which the **ureter** and blood vessels pass. Follow one of the ureters posteriorly to the urinary bladder. It passes dorsal to the **ductus deferens** in the male (Figure 7.69) and **uterine horn** in the female (Figure 7.71) (see below), and then through the fat of the lateral ligament to enter the dorsal surface of the **urinary bladder**. Dissect carefully through the fat; recall that the umbilical artery was also traced to the bladder (page 205). The urinary bladder is a sac-like reservoir for urine. Its broad anterior portion gradually narrows posteriorly into the **urethra**, a narrow tube that passes through the pelvic canal (see below).

Return to one of the kidneys, preferably the left. Remove the renal capsule, cutting carefully around



**FIGURE 7.69** Abdominopelvic cavity of the male cat with many of the viscera removed and urinary bladder reflected to the right to show vessels and urogenital structures, in ventral view.

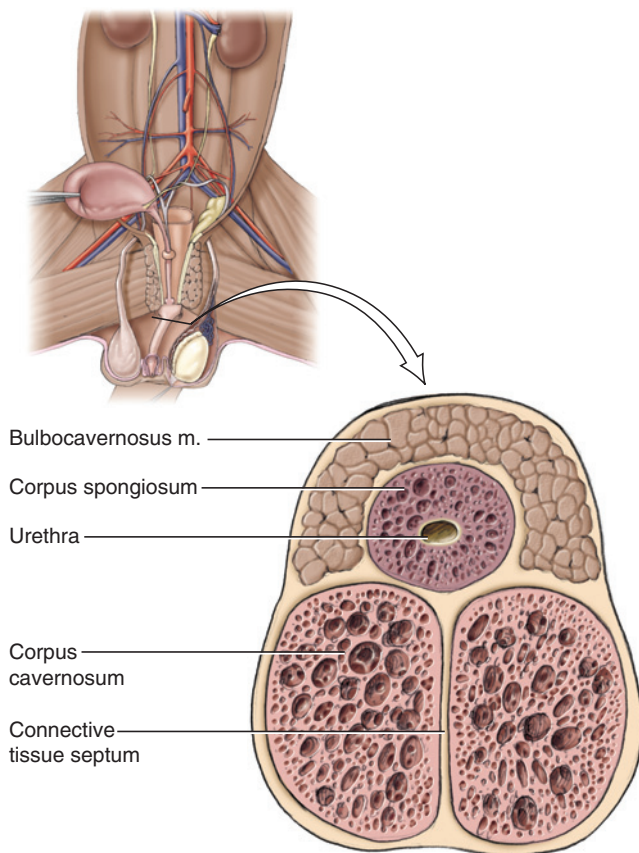


the structures passing through the hilus. Section the kidney in the frontal plane (i.e., so that you have dorsal and ventral halves) and examine one of the sectioned surfaces (Figure 7.68). The substance of the kidney is subdivided into a lighter peripheral zone, the **renal cortex**, and the darker **renal medulla**. The medullary portion constitutes a **renal pyramid**, which tapers toward the hilus into the **renal papilla**.

The ureter and renal vessels enter the hilus, which expands within the kidney into a space termed the **renal sinus**. The expanded proximal portion of the ureter within the kidney is the **renal pelvis**. If it is not evident in the section you are studying, examine the other half of the kidney.

### KEY TERMS: EXCRETORY SYSTEM

ductus deferens	renal pelvis
hilus	renal pyramid
kidneys	renal sinus
renal capsule	ureter
renal cortex	urethra
renal medulla	urinary bladder
renal papilla	uterine horn



**FIGURE 7.70** Cross-section through the penis of the cat.

## Male Reproductive System

The paired **testes** (Figure 7.69) are the male gonads and lie in the **scrotum**, which is a skin-covered sac just ventral to the anus. Externally, the **penis**, the copulatory organ, lies midventrally with respect to the scrotum. Skin the scrotum by making a small incision toward the ventrolateral side of one of the testes. Extend the incision longitudinally and peel the ventral skin of the scrotum. This exposes the left and right **cremasteric pouches**, sac-like extensions of the abdominopelvic cavity in which the testes descend from their abdominal position in the embryo.

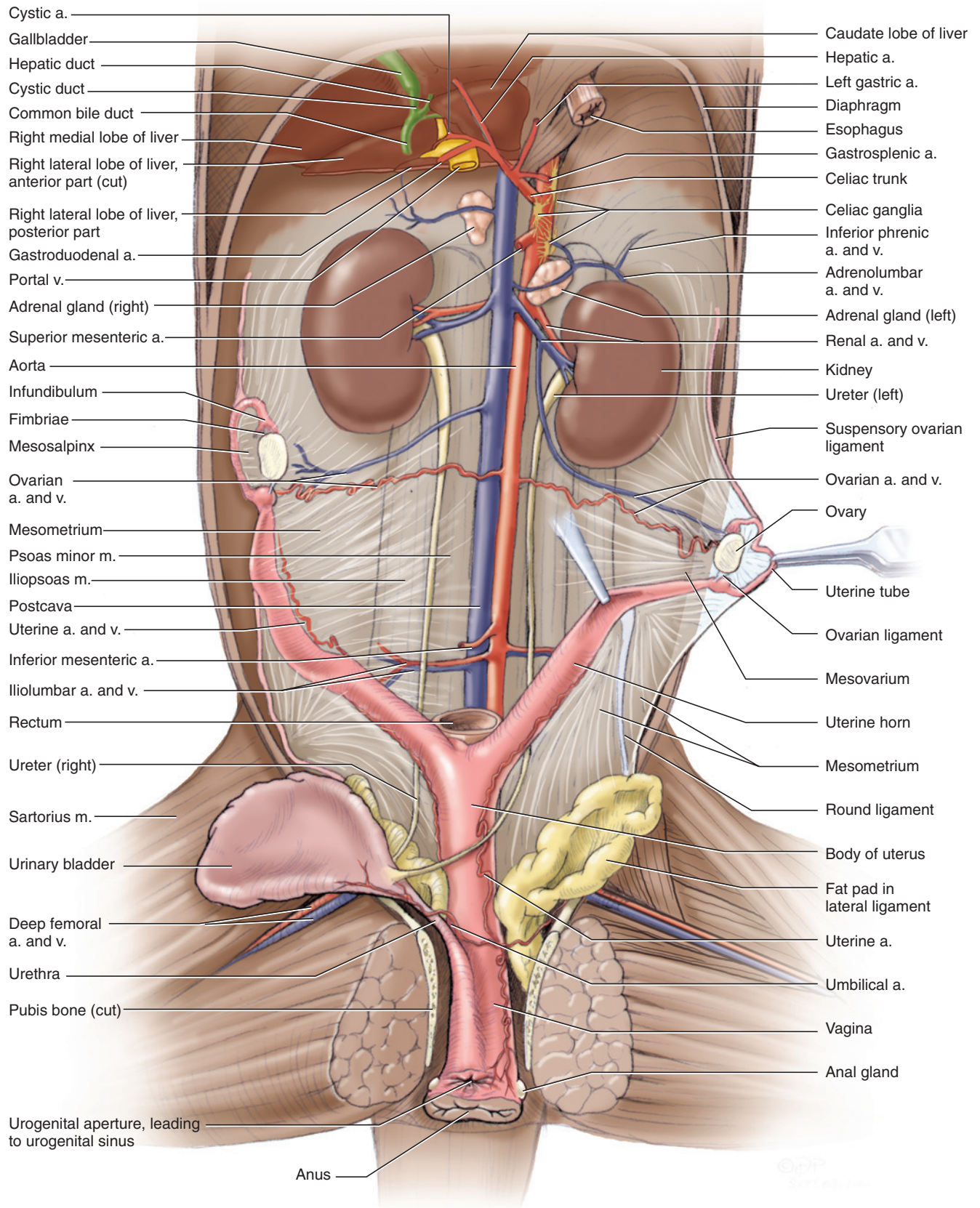
The testes, as well as other structures, are contained within the pouches. The posterior end of each pouch contains a testis and so is expanded. Follow the pouches anteriorly. Each narrows into a thin tube that passes toward the abdominal wall along the ventral surface of the pelvis, just to one side of the pubic symphysis, and passes through the wad of fat present in the groin. You were cautioned against removing this fat during skinning of the cat precisely because the cremasteric pouches pass through it. Now, follow the pouches, teasing away the fat as needed.

The penis will still have its sheath of skin attached. Remove it by making a cut through the sheath and picking through the connective tissue with needle and forceps. Work your way anteriorly until you have exposed the penis and can appreciate that it passes toward the pelvic canal.

Return to the posterior end of one of the pouches, slit its ventral surface longitudinally, and continue the cut onto its narrowed portion. The space within the pouch, the **vaginal cavity**, is analogous to the space of the abdominopelvic cavity. It is lined by **parietal tunica vaginalis**. The structures within the pouch are lined by **visceral tunica vaginalis**. The **mesorchium** is the mesentery supporting these structures. The most notable structure within the pouch is the testis. Pull the posterior end of the cremasteric pouch. The short connective tissue extending to the testis is the **gubernaculum**.

The **epididymis** is a thin, flattened band of tissue on the dorsomedial part of the testis. It consists of expanded head and tail regions and a central, narrower body. As it may be difficult to discern the epididymis in ventral view, turn the testis over by reflecting its lateral surface dorsally. The concave margin of the epididymis is easily apparent. Grasp it with a forceps and return the testis to its anatomical position.

Spermatozoa, the male gametes, from the testis pass through the head, body, and tail of the epididymis and then enter the strand-like **ductus deferens**, which passes mainly along the medial side of the testis. This portion of the ductus is highly convoluted. A thicker strand-like



**FIGURE 7.71** Abdominopelvic cavity of the female cat with many of the viscera removed and urinary bladder reflected to the right to show vessels and urogenital structures, in ventral view.



structure passes to the anterior end of the testis. This is the **pampiniform plexus**, formed by the intertwining of the convoluted distal ends of the internal spermatic artery and vein. Follow the artery, vein, and ductus deferens anteriorly by slitting the narrow part of the cremasteric pouch. These structures, bound together by the visceral tunica vaginalis, constitute the **spermatic cord**. The cord passes through the **inguinal canal**, a short passageway in the abdominal wall, into the abdominopelvic cavity. Within the abdominopelvic cavity, the vessels and ductus deferens go their separate ways. The vessels extend anteromedially. The ductus deferens loops around the ureter and then extends posteromedially, passing through the fat within the lateral ligament of the urinary bladder. Locate the ductus on the other side so that both ducti deferentes may be traced as they extend into the pelvic canal and meet the urethra (see below).

### *Opening the Pelvic Canal*

The pelvic canal must be opened in order to continue following the structures of the urogenital system. Doing so involves cutting through the pelvic symphysis, which is fairly easy, as the symphysis is not fused. Finding the symphysis, however, can be tricky. The most direct way is to continue the incision cut through the body wall posteriorly, all the way to the symphysis. In doing so, try to cut along the sagittal plane (recall that originally you cut to one side of the sagittal plane). Exposing the bladder and urethra may help, as the latter, which lies more or less sagittally, can serve as a guide. When you find the anterior end of the pelvis, attempt to push through the symphysis with a scalpel. (Scraping the pubes a little can help show the symphysis as distinct from the bones.) If you are not precisely on the symphysis, the scalpel will meet with resistance. Do not attempt to force the scalpel through. Instead, move it over slightly to one side or the other and try again; it will pass through fairly easily if it is on the symphysis. Keep trying until you cut through the symphysis. Spread the symphysis by grasping the thighs and twisting them dorsally.

### *Male Reproductive System, Continued*

Once the pelvic canal has been opened, follow the urethra posteriorly, clearing away connective tissue and fat as you do so. Just within the canal, the urethra seems to expand laterally. Careful dissection reveals that the expansion is actually the **prostate gland**. Return to the ducti deferentes and trace them through the canal. They converge and pass along the dorsal surface of the urethra. The prostate gland surrounds their entrance into the urethra. The urethra continues posteriorly and enters the penis very near the end of the pelvic canal.

The penis is formed by three columns of erectile tissue that, when filled with blood, cause its erection (Figure 7.70). The **corpus spongiosum penis** is the mid-dorsal column; the urethra is embedded within it. Posteriorly,

the corpus forms the free end of the penis, the **glans penis**, from which the urethra emerges. The other two columns, the **corpora cavernosa penis**, lie side by side on the ventral surface. The dorsal position of the urethra and corpus spongiosum is a peculiarity of the posterior-pointing penis of the cat. In most other mammals the urethra and corpus lie ventrally, and the corpora cavernosa are dorsal. Posteriorly, the corpora cavernosa diverge laterally as the **crura** (sing., **crus**) of the **penis**, which anchor the organ to the ischia. The small, paired **bulbourethral glands** lie just dorsal to the crura. Cut and reflect a crus to see them. Then section the penis near its center to view the three columns of spongy tissue. The **os penis** is a small bone (3–7 mm long) lying in the glans penis.

### **KEY TERMS: MALE REPRODUCTIVE SYSTEM**

bulbourethral glands	mesorchium
corpora cavernosa penis	os penis (baculum)
corpus spongiosum penis	pampiniform plexus
cremasteric pouches	parietal tunica vaginalis penis
crus (plur., crura) of the penis	prostate gland
ductus deferens	scrotum
epididymis	spermatic cord
glans penis	testis (plur., testes)
gubernaculum	vaginal cavity
inguinal canal	visceral tunica vaginalis

### **Female Reproductive System**

The small, oval **ovaries** are the female gonads (Figure 7.71) and lie in the abdominal cavity just posterior to the kidneys. Follow the ovarian artery and vein of one side to an ovary. As in most vertebrates, ova produced by the ovaries pass posteriorly through paired tubes that have become longitudinally differentiated into several distinct regions in mammals. The **uterine tube**, the most anterior portion, is a thin, convoluted tube lying lateral to the ovary. Its proximal end enlarges into the **infundibulum**, which forms a hood-like expansion over the anterior end of the ovary. Its margin bears **fimbriae**, frill-like projections that help ensure the ovum passes through the **ostium tubae**, which is the opening of the infundibulum, and into the uterine tube.

Each uterine tube leads posteriorly into the larger **uterine horn**. These will be narrow unless the female is gravid or has previously carried a litter. The horns of each side pass posteromedially and merge dorsal to the urinary bladder. The short, tough **ovarian ligament** anchors the ovary and the anterior end of the horn. At



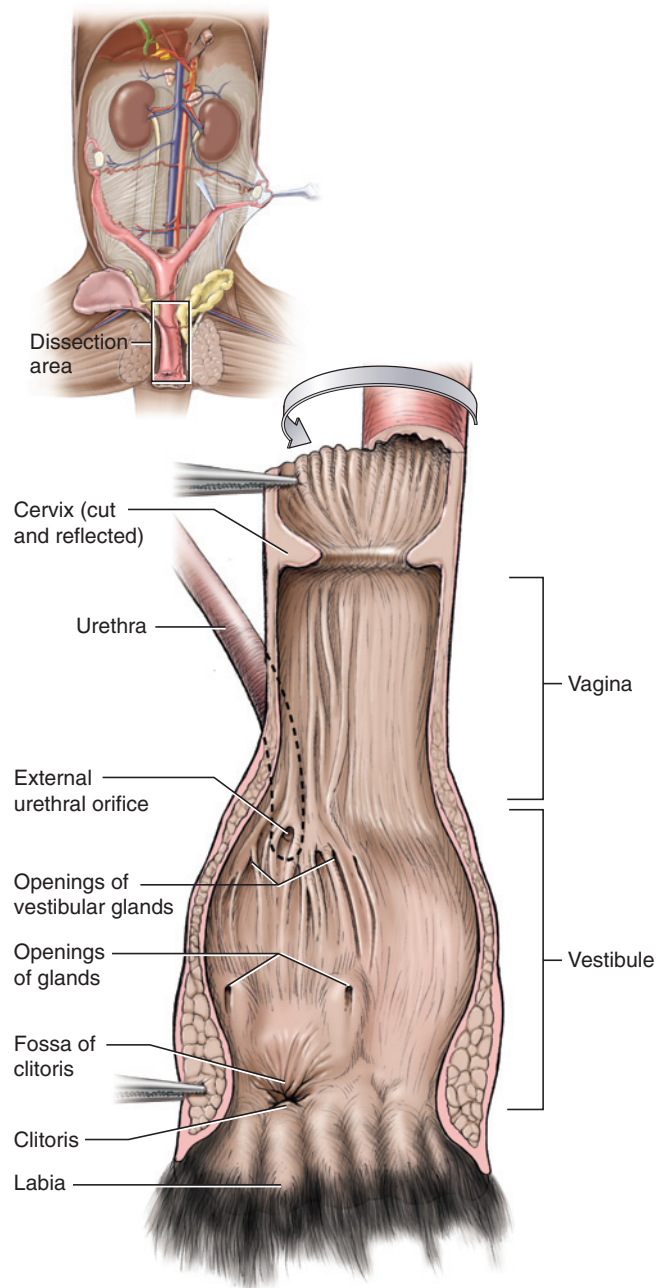
first glance, however, it appears to form a connection between the uterine horn and ovary. Thus, carefully follow the uterine horn into the uterine tube.

The union of the uterine horns posteriorly form the **body** of the uterus, a wider canal that then leads into the **vagina**. As there is no external division of these structures, their separation will be seen when they are opened. Note that the ureters pass dorsal to the uterine horns.

The reproductive tract is supported by various mesenteries. The main supporting structure is the **broad ligament**, of which several portions are recognized. Lift the reproductive structures to clearly observe the following mesenteries. The portion of the broad ligament supporting the ovary is the **mesovarium**. The **mesosalpinx** attaches to the uterine tube, and the **mesometrium** attaches to the uterus, including the uterine horn. Lift the uterine horn near its center and tug it medially, as shown in Figure 7.71. The **round ligament** is the fibrous band in the mesometrium that extends diagonally from the uterine horn posterolaterally toward the body wall. Also, note the **suspensory ovarian ligament**, which supports the ovary anteriorly, as it extends to the dorsal body wall just lateral to the kidney.

Open the pelvic canal by cutting through the pubic symphysis following the instructions given for the male on page 216. Pick away connective tissue to reveal and separate the structures passing through the canal (see Figure 7.71). The urethra and vagina unite toward the posterior end of the pelvic canal to form a common passageway, the **urogenital sinus**, which opens to the outside through the **urogenital aperture**. Dissect dorsal to the vagina and urogenital sinus to separate them from the rectum. On each side, dissect the tissue lateral to the rectum, very near the anus, to reveal the **anal glands**. Then completely separate the urogenital sinus from the rectum so that it can be turned over. Make a slit along one side of the body of the uterus, vagina, and urogenital sinus, and spread the flaps apart (Figure 7.72). Find the **urethral orifice**, the entrance of the urethra. The vagina extends anteriorly from this point to the **cervix** of the uterus, which is the distally tapered, sphincter-like portion of the uterus. Directly posterior to the urethral orifice, and just before the urogenital aperture, lies the small **clitoris**, which may be difficult to see. It is the female homologue of the penis and generally considerably smaller, but in hyenas it exceeds the penis in size.

The **mammary glands** are important reproductive structures in mammals. They were observed beneath the skin of the thorax and abdomen during skinning of the cat (see page 157).



**FIGURE 7.72** Distal portion of female urogenital tract of the cat in ventral view. The tract has been cut along its lateral margin and opened to the right to reveal the internal anatomy.

### KEY TERMS: FEMALE REPRODUCTIVE SYSTEM

anal glands  
body of the uterus  
broad ligament  
cervix of the uterus  
clitoris  
fimbriae

infundibulum  
mammary glands  
mesometrium  
mesosalpinx  
mesovarium  
ostium tubae

ovarian ligament  
ovary  
round ligament  
suspensory ovarian  
ligament  
urethral orifice  
urogenital aperture  
(vulva)

urogenital sinus (vaginal  
vestibule, urogenital  
canal)  
uterine horn  
uterine tube (fallopian  
tube)  
vagina

## SECTION VII—BRAIN AND CRANIAL NERVES

### Meninges

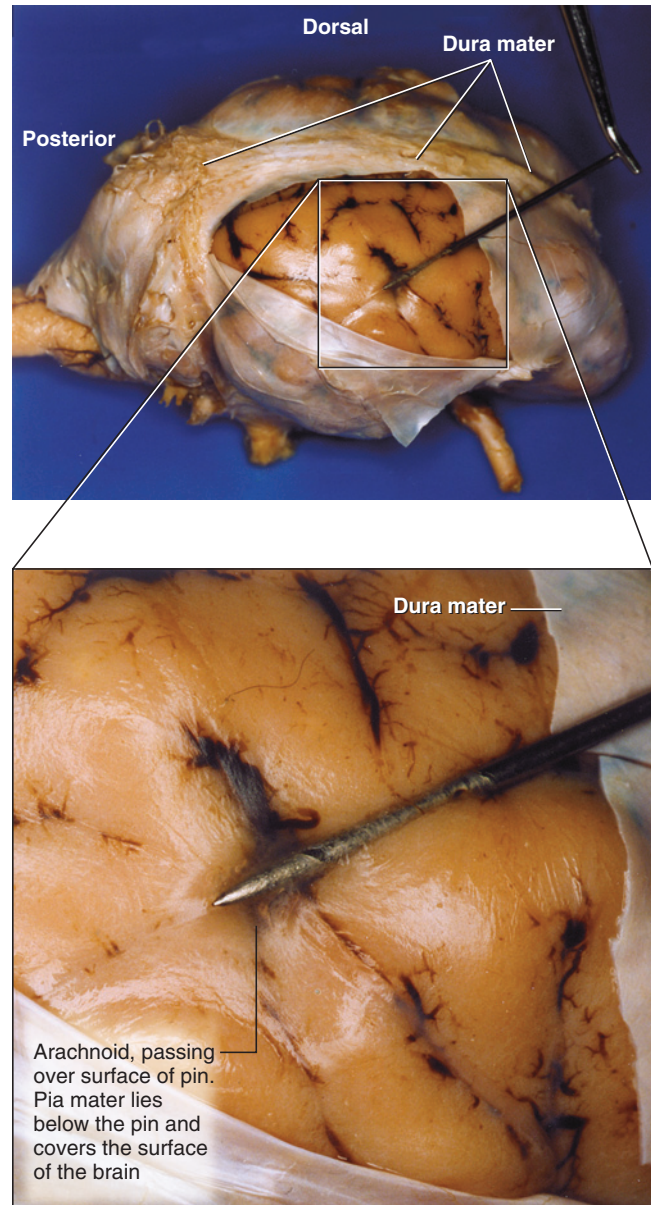
In comparative anatomy courses, the brain and cranial nerves of a sheep, rather than of a cat, are usually studied. There are two main reasons for this. First, the cat brain is small and many of its structures, particularly the nerves, are extremely difficult to find. Second, the brain of the cat would have to be carefully removed from the skull, which requires patience and the proper tools. To avoid these problems, the mammalian brain should be studied using a prepared sheep brain. Illustrations of the sheep (Figures 7.73–7.77) are provided here, as well of the cat (Figures 7.78 and 7.79). Compare the structures in the cat in these illustrations with those you observe in the sheep brain.

The brain is surrounded by three membranes, or **meninges** (sing., **meninx**), which protect and isolate it (Figure 7.73). The thickest is the **dura mater**. It fuses with the periosteum of the bones enclosing the cranial cavity and is usually left on the skull when the brain is removed, although a ventral portion of the dura mater, covering the hypophysis, is present in most specimens. If your specimen still has the dura mater adhering to it, carefully remove it, but keep its ventral and posteroventral portions. Some specimens that preserve the dura mater also preserve the branching of the trigeminal nerve (see below). In lateral view, this is a large, Y-shaped, horizontal structure lateral to the hypophysis. If present, sever the nerve just before it branches.

The other meningeal layers are the **pia mater**, a thin layer adhering to the surface of the brain, and the **arachnoid mater**, lying between the dura and pia. The arachnoid largely remains with the dura mater in the cranial cavity of the skull.

### Telencephalon

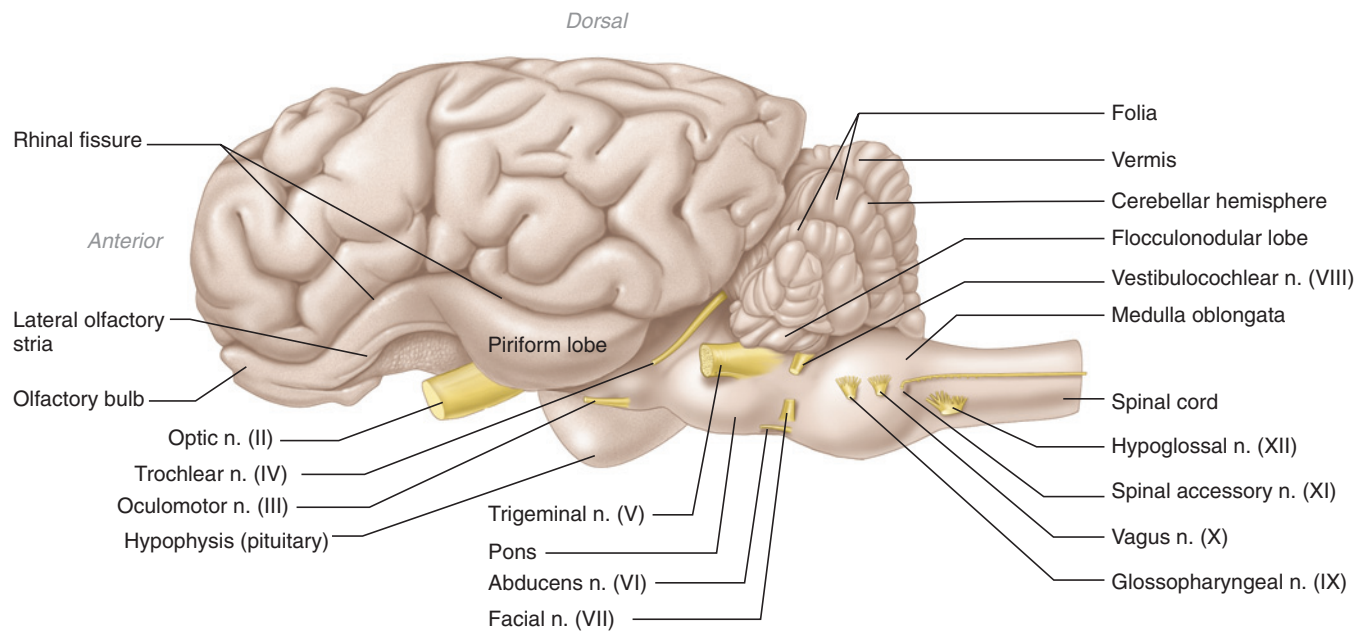
The **telencephalon** (Figure 7.77) is greatly expanded in mammals, due mainly to the enormous size of the **cerebrum**. Indeed, the largest parts of the brain are the **cerebral hemispheres**, which lie dorsally and together



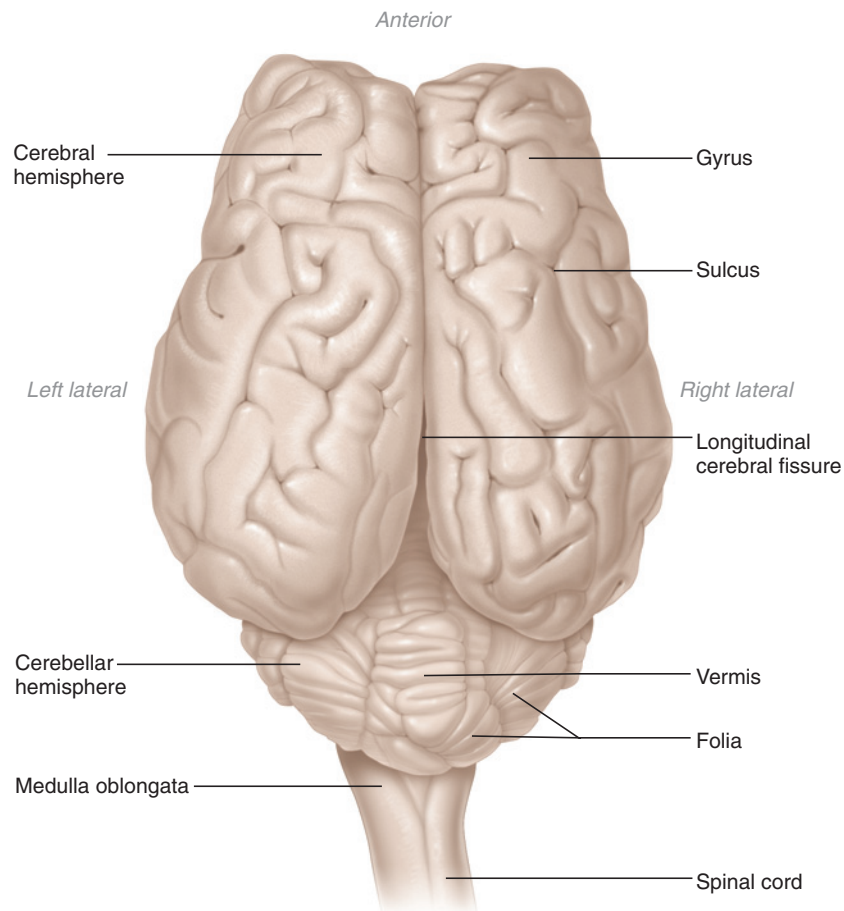
**FIGURE 7.73** Right lateral view (anterior to right of page) of the sheep brain showing meninges. The dura mater has been partially cut and reflected to reveal deeper meninges. Blowup shows the pin passing deep to the arachnoid mater.

comprise the cerebrum. The **cerebellum** (part of the **metencephalon**; see below) is another prominent part of the brain, and lies posterior to the cerebrum (Figure 7.74). The surface of the cerebrum bears numerous folds, the **gyri** (sing., **gyrus**), separated by grooves, the **sulci** (sing., **sulcus**). Right and left cerebral hemispheres are separated by the deep **longitudinal cerebral fissure** (Figure 7.75). Gently spread the hemispheres to reveal the **corpus callosum**, a white structure consisting of fibers that connect the hemispheres.

The elongated, flattened **olfactory bulbs** lie anteroventrally on the telencephalon (Figures 7.74 and 7.76). A

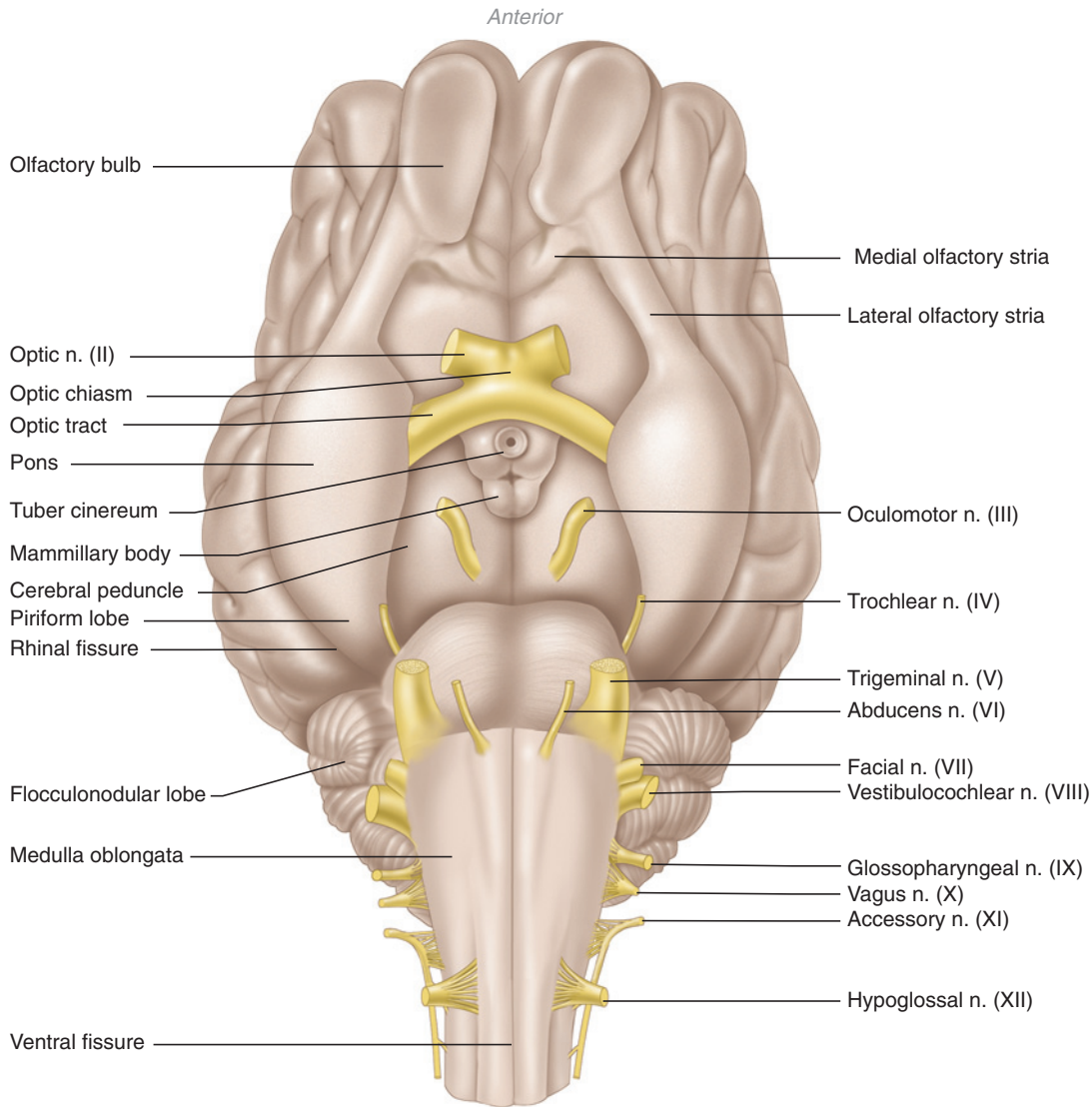


**FIGURE 7.74** Left lateral view of the sheep brain and cranial nerves, with dura mater and arachnoid mater removed.



**FIGURE 7.75** Dorsal view of the sheep brain and cranial nerves, with dura mater and arachnoid mater removed.





**FIGURE 7.76** Ventral view of the sheep brain, with dura mater and arachnoid mater removed.

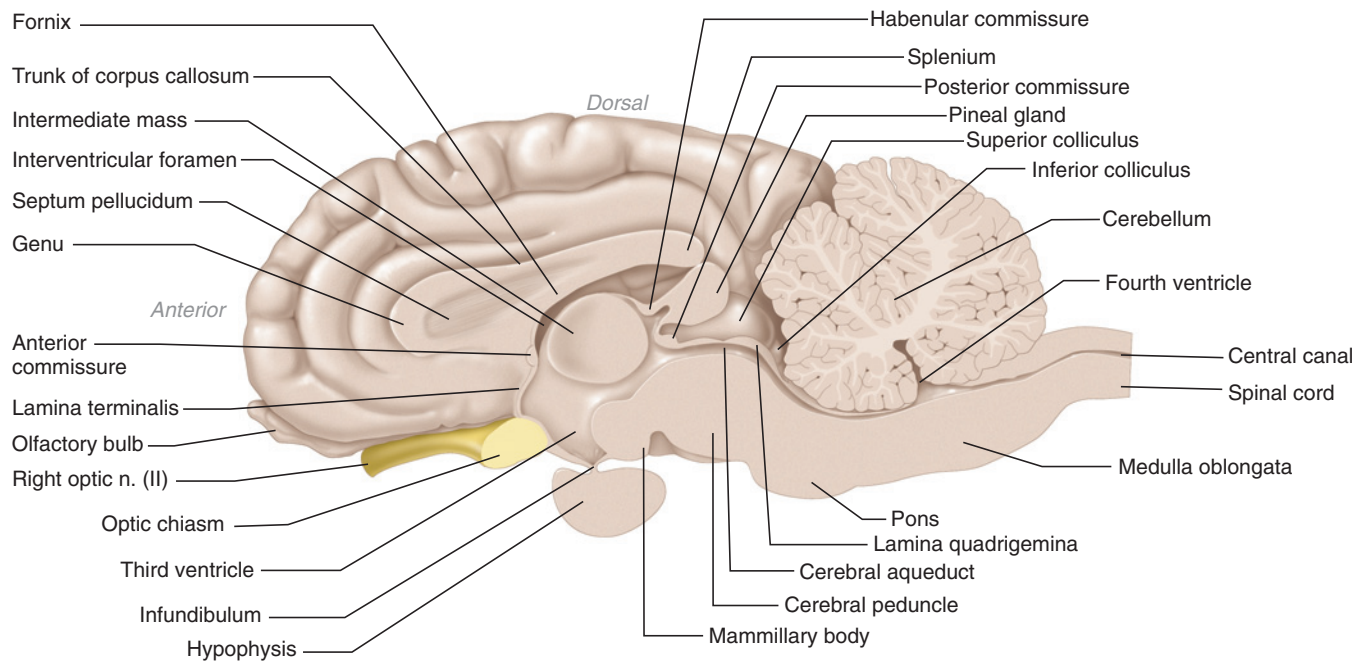
band of fibers, the **olfactory tract**, continues posteriorly from the olfactory bulb and almost immediately separates into **lateral** and **medial olfactory striae**. The medial olfactory stria extends posteromedially, whereas the lateral olfactory stria extends posterolaterally. Each stria is accompanied by a gyrus, and only the lateral olfactory stria is easily discernable. It continues posteriorly into the **piriform lobe**, which is separated from the rest of the cerebrum by the **rhinal sulcus** (Figure 7.74).

## Diencephalon

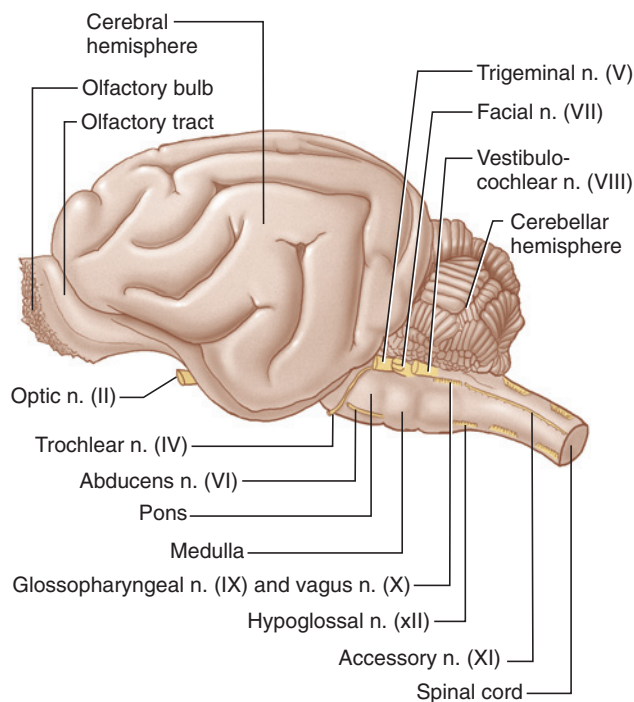
The greatly expanded cerebrum covers the roof of the **diencephalon**, so that without dissection only the **hypothalamus**, or floor of the diencephalon, may be clearly observed (Figure 7.76). The **optic chiasm**, at the anterior end of the hypothalamus, represents a partial decus-

sation of the **optic nerves**. Just posterior to the optic chiasm, a thin, delicate stalk, the **infundibulum**, suspends the **hypophysis** (Figure 7.77). In prepared specimens, the hypophysis and infundibulum may be missing. Remove them if present in your specimen. The opening for the infundibulum is a continuation of the **third ventricle** (see below). The area of the hypothalamus adjacent to the opening is the **tuber cinereum** (Figure 7.76). Immediately posterior to the tuber are the paired **mammillary bodies** (which may appear as a single rounded structure), which mark the posterior end of the hypothalamus.

The dorsal part of the diencephalon is formed by the **epithalamus**. To see it, observe the brain in dorsal view, spread apart the cerebral hemispheres, and make a longitudinal cut through the corpus callosum. The epithalamus lies mainly ventral to the latter's posterior

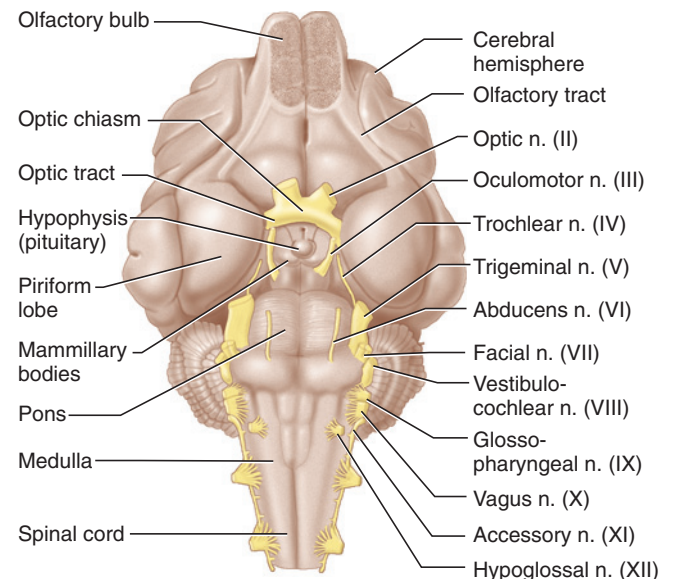


**FIGURE 7.77** Sagittal section of sheep brain.



**FIGURE 7.78** Left lateral view of the cat brain and cranial nerves, with dura mater and arachnoid mater removed.

portion. Remove its roof, the **tela choroidea**, to reveal the third ventricle, the narrow cavity of the diencephalon. The slightly thickened posterolateral margin of the ventricle forms the **habenula** on each side. These margins converge posteriorly toward the midline, and form the **habenular commissure**, which is more readily



**FIGURE 7.79** Ventral view of the cat brain and cranial nerves, with dura mater and arachnoid mater removed.

discernable in sagittal section (Figure 7.77). The rounded **pineal gland** lies posterior to the commissure.

The walls of the **thalamus**, the lateral portions of the diencephalon, are mainly lateral to the dorsal margins of the third ventricle, but their extent is difficult to appreciate. Part of the thalamus, the **intermediate mass** (see below), extends across the third ventricle to connect the left thalamus and right thalamus (Figure 7.77). You

may have cut through it during exposure of the third ventricle. The positional relationships of these structures will be examined again in sagittal view.

## Mesencephalon

The **tectum**, or roof, of the mesencephalon was partially exposed during dissection of the third ventricle. To see it more completely, spread the cerebral hemispheres from each other, as well as from the cerebellum. The tectum is characterized by two paired, prominent swellings that together form the **corpora quadrigemina**, which sit on the **lamina quadrigemina** (the latter will be seen in sagittal section). The two anterior swellings, the **superior colliculi**, are the larger, well-rounded structures that lie just posterior to the pineal gland. The **inferior colliculi** are the smaller, flattened structures that protrude from the posterior end of the superior colliculi. The **trochlear nerves** arise from the dorsal surface of the mesencephalon just posterior to the inferior colliculi.

Examine the brain in ventral view (Figure 7.76). The floor of the mesencephalon is formed by the cerebral peduncles, slightly elevated regions lateral and posterior to the mammillary bodies. The relatively wide and flattened **oculomotor nerve** arises from the surface of each cerebral peduncle.

## Metencephalon

The **metencephalon** consists mainly of two regions. Dorsally is the cerebellum (Figures 7.74 and 7.75). Its surface is highly folded into **folia**, which are separated by **sulci**. The median part of the cerebellum is the **vermis**. The **cerebellar hemispheres** lie on either side of the vermis. A **flocculonodular lobe** may be distinguished on the ventrolateral part of each hemisphere. On the ventral surface, the metencephalon consists of the **pons**, a rounded region of transverse fibers posterior to the cerebral peduncles. On each side, the **trigeminal nerve** arises laterally from the posterolateral part of the pons. Distally the trigeminal has three main branches: the ophthalmic, maxillary, and mandibular nerves, which are often respectively abbreviated as V<sub>1</sub>, V<sub>2</sub>, and V<sub>3</sub> (Table 7.4).

## Myelencephalon

The **myelencephalon** consists of the **medulla oblongata**, which forms the brain posterior to the metencephalon and connects to the spinal cord (Figures 7.76 and 7.77). The **ventral fissure** is the median ventral groove of the medulla. To either side are narrow longitudinal bands termed **pyramids**. Lateral to the anterior part of each pyramid, and just posterior to the pons, lies a **trapezoid body**.

The remaining cranial nerves are mainly associated with the medulla oblongata, but some of them may be difficult to discern if the meninges have been stripped. Thus, identify the stumps of these nerves before removing the meninges. The nerves to be identified are the **abducens**, **facial**, **vestibulocochlear**, **glossopharyngeal**, **vagus**, **accessory**, and **hypoglossal nerves** (Figures 7.74, 7.76, and 7.80).

An abducens nerve arises from the anterior part of the medulla, between the trapezoid body and pyramid. The facial nerve arises lateral to the trapezoid body just posterior to the trigeminal nerve, and the vestibulocochlear nerve arises slightly more dorsally, from beneath the flocculonodular lobe. The glossopharyngeal, vagus, and accessory nerves arise in sequence and more posteriorly from the lateral surface of the medulla. The hypoglossal nerve arises further posteriorly and ventrally. If the meninges have been stripped from the medulla, however, it will be extremely difficult to identify these nerves.

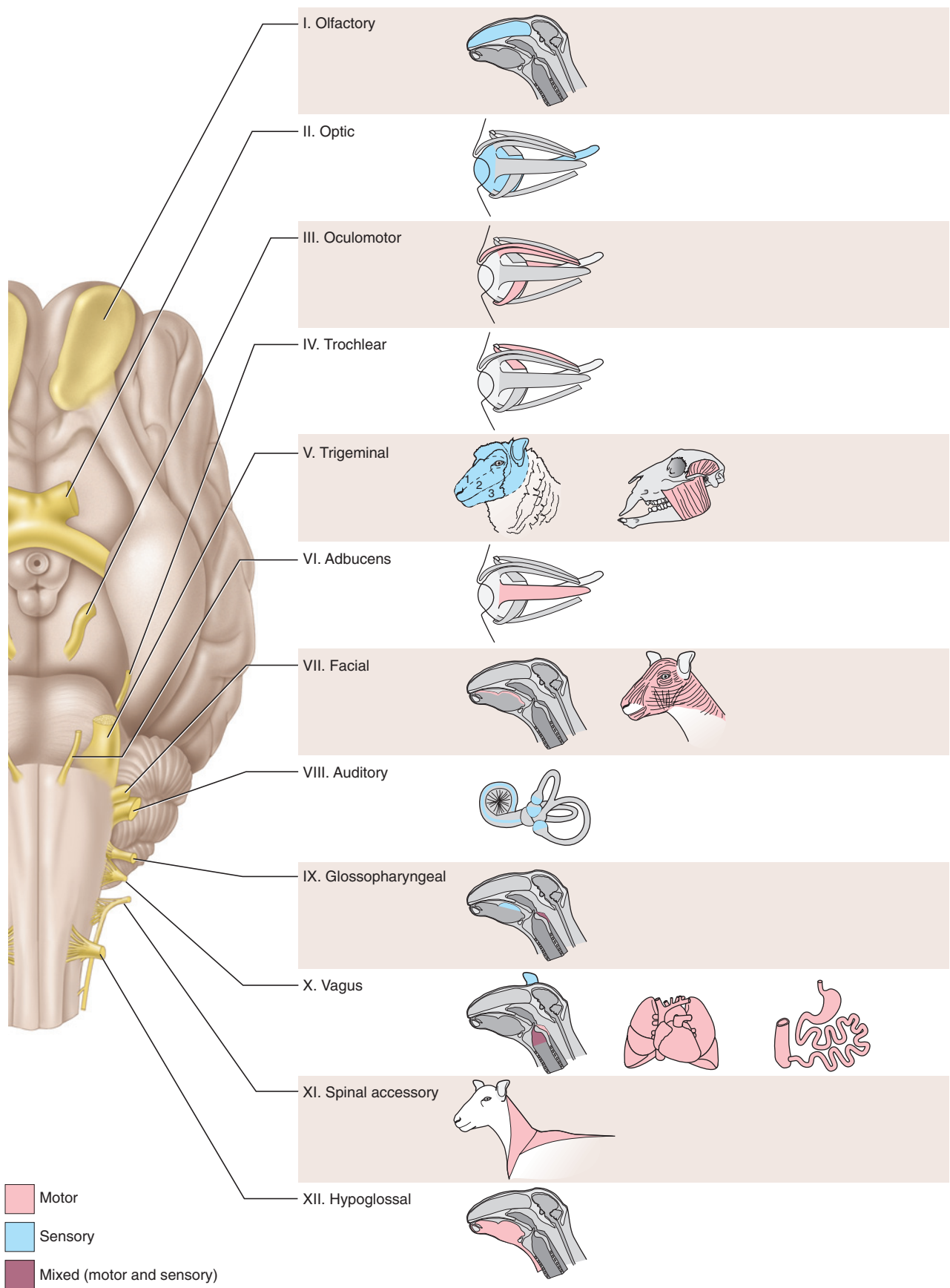
One method of exposing the nerves is to make a mid-ventral cut through the meninges using fine scissors. Begin posteriorly and work your way forward. When you reach the level of the abducens nerves, carefully reflect the meninges. As you peel the meninges back, look for a series of fine rootlets arising from the ventrolateral surface of the posterior part of the medulla. These rootlets merge to form the hypoglossal nerve. Separate it from the meninges and continue peeling the latter. Soon you will note the glossopharyngeal, vagus, and accessory nerves. The accessory will probably be the most prominent at first, because it forms a longitudinal nerve adjacent to the surface of the medulla. Follow it forward, and you will find the stumps of the three nerves arising very close to each other. The glossopharyngeal and vagus arise by a series of small rootlets, so they may not be readily discernable. The accessory nerve arises as a series of very fine rootlets along the posterior part of the medulla. Posterior to it, your specimen may preserve the 1st spinal nerve. Its origin appears similar to that of the hypoglossal nerve.

Examine the dorsal surface of the medulla. A good part of its roof is covered by a **tela choroidea**. Remove it to expose the fourth ventricle, the cavity within the medulla that continues forward under the cerebellum. This part of the roof of the fourth ventricle is covered by a separate membranous structure, the **medullary velum**.

## Sagittal Section of the Brain

With a new scalpel blade, make a sagittal section through the brain by extending the section made earlier to expose the third ventricle. Carefully continue the





**FIGURE 7.80** Cranial nerves and the structures they innervate.

section ventrally and posteriorly using the pineal body, superior colliculi, and middle of the vermis as guides to the sagittal plane of the brain.

Examine one of the halves in sagittal view (Figure 7.77) and note the great extension of the cerebrum. The **corpus callosum** (see also above), the structure allowing communication between the cerebral hemispheres, is also clearly revealed. Its anterior, curved part is the **genu**, its posterior part the **splenium**, and between them dorsally is the **trunk** of the corpus callosum. The **fornix** curves anteroventrally from near the splenium. The **septum pellucidum** is a thin, vertical, shiny partition between the corpus callosum and fornix. Most sagittal sections do not coincide precisely with the sagittal plane, and so the septum remains on one or the other half of the brain. If it is absent on the half you are examining, you will see a cavity, the **lateral ventricle** of the cerebral hemisphere; check the other half for the septum. You may break through the septum into the other lateral ventricle.

Below the ventral part of the fornix is the **anterior commissure**, a small, rounded structure representing a group of fibers. The **lamina terminalis**, forming the anterior wall of the third ventricle, extends ventrally from the anterior commissure to the **optic chiasma**, which is oval in section. The third ventricle lies mainly ventral to the fornix and splenium of the corpus callosum. Note that it is narrow but dorsoventrally high. The circular **massa intermedia** extends across the third ventricle and connects the thalami that form the right and left sides of the diencephalon. Each lateral ventricle communicates with the third ventricle through the **interventricular foramen**, located just anterior to the massa intermedia. Identify the **mammillary body** ventrally on the hypothalamus and, more posteriorly, the **cerebral peduncle** and **pons**.

Identify the **pineal body** and the **habenular commissure** in this section. Note the **posterior commissure** extending between the pineal body and the **lamina quadrigemina** (mentioned above) of the mesencephalon. Posterior to the massa intermedia, the third ventricle communicates with the **cerebral aqueduct**, a narrow passageway that extends posteriorly beneath the lamina quadrigemina and then into the fourth ventricle. The latter, in turn, extends back into the **central canal** of the spinal cord.

Examine the section through the cerebellum and observe how the white matter, the **arbor vitae**, branches into the surrounding gray matter. The roof of the fourth ventricle is formed by the **medullary velum** anteriorly and the **tela choroidea** posteriorly, but these structures were probably removed during exposure of the fourth ventricle. Note how the cerebellum attaches to the rest of the brain on each side of the fourth ventricle via a series

**TABLE 7.5** Cranial nerves and associated foramina of the sheep

Cranial Nerve		Foramen
Number	Nerve	
I	Olfactory nerve	Cribriform foramina of the cribriform plate
II	Optic nerve	Optic canal
III	Oculomotor nerve	Orbital fissure
IV	Trochlear nerve	Orbital fissure
V	Trigeminal nerve	
V <sub>1</sub>	Ophthalmic nerve	Orbital fissure
V <sub>2</sub>	Maxillary nerve	Foramen rotundum
V <sub>3</sub>	Mandibular nerve	Foramen ovale
VI	Abducens nerve	Orbital fissure
VII	Facial nerve	Internal acoustic meatus, then stylomastoid foramen*
VIII	Vestibulocochlear nerve	Internal acoustic meatus**
IX	Glossopharyngeal nerve	Jugular foramen
X	Vagus nerve	Jugular foramen
XI	Accessory nerve	Jugular foramen
XII	Hypoglossal nerve	Hypoglossal canal, then jugular foramen

\*The main part of the facial nerve passes through the inner ear and middle ear before emerging from the stylomastoid foramen.

\*\*As the vestibulocochlear supplies structures of the inner ear, it does not leave the skull.

of fiber tracts or peduncles. Make a frontal section through the peduncles to remove the cerebellum. The posterior curved part of the section consists of the **posterior cerebellar peduncle**. Anteriorly there are two peduncles. The **middle cerebellar peduncle** is slightly larger than and lateral to the **anterior cerebellar peduncle**.

## Cranial Nerves

The stumps of the 12 cranial nerves have already been identified during the dissection of the brain, but their peripheral distribution cannot easily be followed. Figure 7.80 provides a summary of the cranial nerves, their origin from the brain, and their peripheral distribution. Table 7.5 indicates the foramina through which the cranial nerves leave the skull. Review the names and numbering sequence for the nerves, as well as the foramina through which they pass.

## KEY TERMS: BRAIN AND CRANIAL NERVES

abducens nerve	central canal
accessory nerve	cerebellar hemispheres
anterior commissure	cerebellar peduncle, anterior, middle, and posterior
arachnoid mater	
arbor vitae	

cerebellum	habenular commissure	meninx (plur., meninges)	superior colliculi
cerebral aqueduct (aqueduct of Sylvius)	hypoglossal nerve	metencephalon	tectum
cerebral hemispheres	hypophysis	myelencephalon	tela choroidea of diencephalon
cerebral peduncle	hypothalamus	oculomotor nerve	tela choroidea of myelencephalon
cerebrum	inferior colliculi	olfactory bulbs	telencephalon
corpora quadrigemina	infundibulum	olfactory tract	thalamus
corpus callosum	intermediate mass	optic chiasma	third ventricle
diencephalon	interventricular foramen (foramen of Monroe)	optic nerves	trapezoid body
dura mater	lamina quadrigemina	pia mater	trigeminal nerve
epithalamus	lamina terminalis	pineal body	trochlear nerves
facial nerve	lateral olfactory stria	pineal gland	trunk, of corpus callosum
flocculonodular lobe	lateral ventricle	piriform lobe	tuber cinereum
folia	longitudinal cerebral fissure	pons	vagus nerve
fornix	mammillary body	posterior commissure	ventral fissure
genu	intermediate mass	pyramids	vermis
glossopharyngeal nerve	medial olfactory stria	rhinal sulcus	vestibulocochlear nerve (auditory nerve, octaval nerve)
gyrus (plur., gyri)	medulla oblongata	septum pellucidum	
habenula	medullary velum	splenium	
habenular commissure		sulcus (plur., sulci)	



This page intentionally left blank

# CHAPTER 8

## THE PIGEON

### INTRODUCTION

The pigeon, *Columba livia*, belongs to the Aves or birds. Although birds have long been recognized as the flying, feathered vertebrates, recent fossil discoveries—among the more exciting paleontological developments of the last few decades—have revealed that feathers first evolved in several groups of theropod dinosaurs. Feathers are therefore not unique to birds and can no longer be used to diagnose them as a group. Nonetheless, birds are the only living vertebrates with feathers. The terms Aves and birds have long been used to refer to the same group of amniotes, but they are not precisely synonymous. The Aves are considered the group that includes the ancestor of living birds and all of its descendants. However, the fossil remains of much more primitive birds have long been known to science.

Indeed, birds have a long fossil record, beginning with the earliest bird, the Late Jurassic *Archaeopteryx lithographica*. The group including *Archaeopteryx* and all other birds is termed the Avialae and is recognized by development of the forelimbs into wings. The fossil record documents several substantial radiations during the Jurassic and Cretaceous Periods, of which many became extinct. As examples, the Confuciusornithidae (a group of toothless, flying birds that still had mainly separate digits in the manus and a pair of long ornamental tail feathers in, presumably, males), Hesperornithiformes (a group of flightless, diving birds with the forelimb represented only by a splint-like humerus), and Ichthyornithiformes (a group of ancient flying birds) may be mentioned. These groups had all become extinct by the end of the Cretaceous.

Modern birds, the Aves, began their radiation during the Cretaceous. They are among the most numerous of vertebrate groups, having diversified to include at least 9,700 living species (and molecular studies suggest that there might be twice as many species as currently recognized). The Aves are characterized by complete loss of teeth and a very large sternal keel. They are subdivided into the Palaeognathae and Neognathae, which are differentiated primarily on palatal features. The paleognaths include two lineages, the flightless ratites

(e.g., ostriches, emus, rheas, cassowaries) and the tinamous.

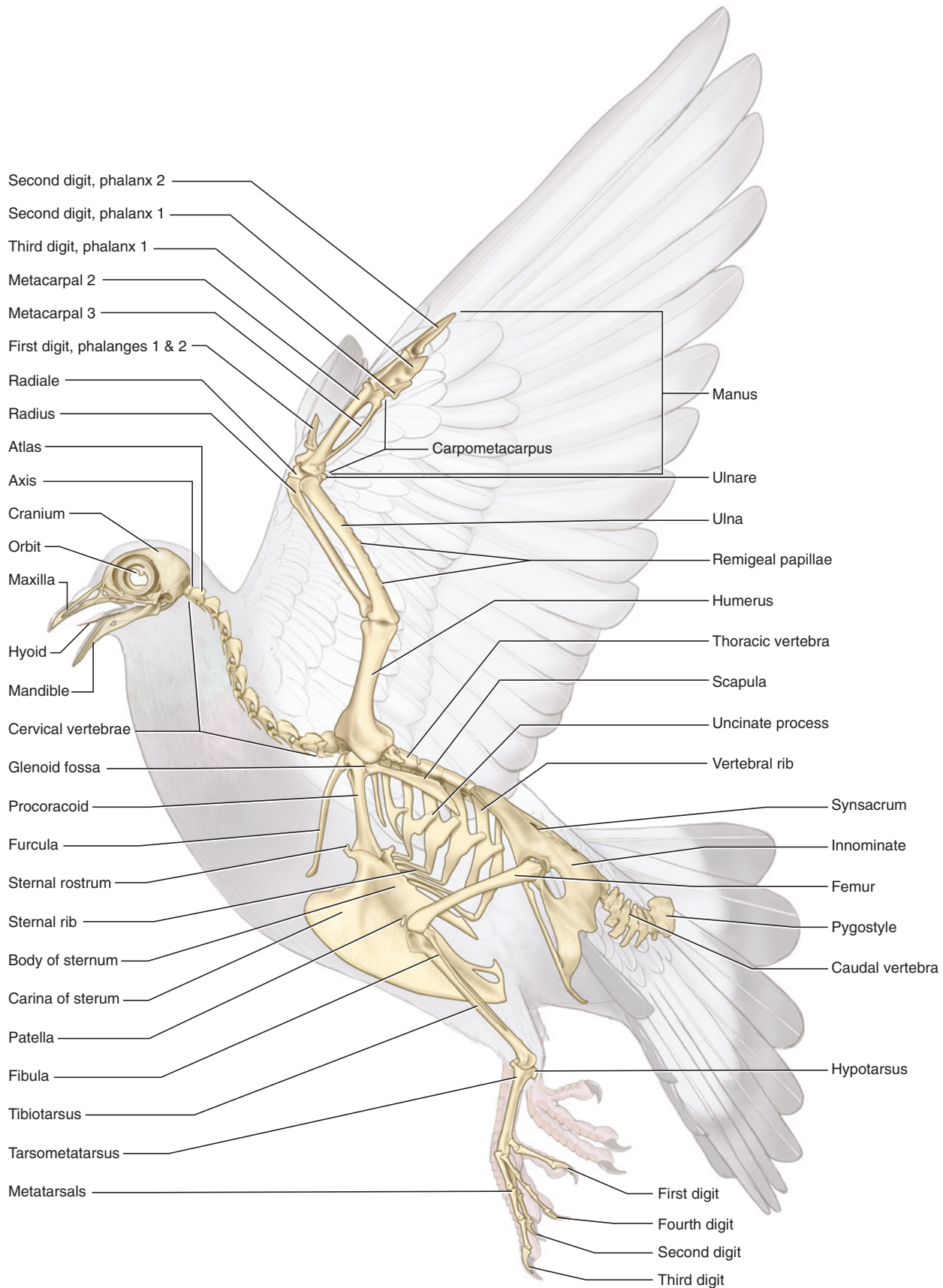
Ratites and tinamous comprise some 54 living species, so most of present-day avian diversity is represented by the neognaths. Twelve main lineages are recognized, but their interrelationships are largely unresolved. Among these may be mentioned the sister groups Anseriformes (ducks, geese, swans) and Galliformes (chickens, grouse, pheasants, turkeys), which together apparently form the outgroup to other neognaths. The Procellariiformes (albatrosses, petrels, and shearwaters), Pelicaniformes (pelicans, gannets, cormorants), Sphenisciformes (penguins), Gaviformes (loons), and Podicipediformes (grebes) are part of another lineage, as are the Falconiformes (eagles, falcons, ospreys) and Strigiformes (owls). The Passeriformes, the great group of songbirds, together with Piciformes (barbets, toucans, woodpeckers) and Coraciiformes (hoopoes, hornbills, kingfishers) represent yet another lineage. The pigeon is included with doves in the Columbiformes, which is part of the lineage including Charadriiformes (auks, curlews, snipes, terns, gulls, puffins), Ardeidae (bitterns, egrets, herons), and Gruiformes (cranes, coots, rails, bustards).

### SECTION I—SKELETON

The structure of birds, most of which can fly, has been highly modified to meet the demands of flight. The skeleton has a number of such modifications, most obviously perhaps in the forelimbs, which are adapted to form a bony frame for the wings (Figure 8.1). Also, however, the skeleton has undergone changes to reduce weight, clearly an advantage in a flying animal, and mobility, which gives the wings a rigid support. Several bones of many birds are pneumatic—hollow and containing extensions of the respiratory system's air sacs, described in more detail below (Figure 8.2).

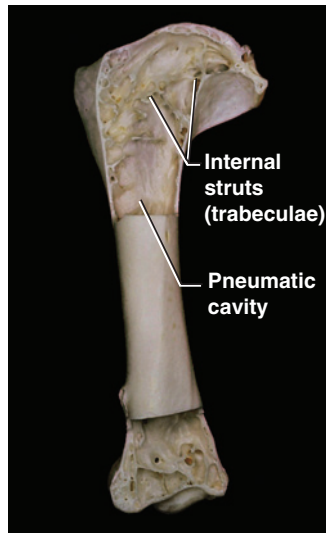
#### Skull, Mandible, and Hyoid Apparatus

The bones of the skull (Figures 8.3 and 8.4) are extensively fused to provide strength while minimizing weight. As the sutures are often obliterated, it is diffi-



**FIGURE 8.1** Skeleton of the pigeon in left lateral view, superimposed on body outline.





**FIGURE 8.2** Humerus of pigeon with proximal and distal ends sectioned to reveal internal structure.

cult to distinguish many of the bones in an adult individual. Attempting to identify each bone is, at this level of study, impractical, and it is more useful to examine various regions of the skull.

Note the large **orbits**. The often incomplete, bony septum between the orbits is formed by the **mesethmoid**. The **sclerotic ring** is a circle of small bones that support the eyeball. The **postorbital process** lies at the posteroventral margin of the orbit. The cranium, posterior to the orbits, is composed of paired **frontals** that cover most of the roof of the skull, **parietals**, smaller rectangular bones, and **squamosals** on the lateral wall of the cranium, and, posteroventrally, the **occipital**, which is formed from several bones fused into a single unit. These cranial bones can usually be distinguished, although the sutures between them are often indistinguishable.

The **quadrate** lies toward the ventral part of the orbit and is mobile in birds. It has a prominent orbital process, as well as an otic process, which contacts the cranium. Just ventral to this contact is a large, oval depression, the **auditory meatus**, which is bounded posteroventrally by the **paroccipital** process and leads into the **middle ear**. The bony region, pierced by various foramina, visible within the meatus contains the inner ear. The quadrate has a ventral process that articulates with the **mandible** to form the jaw joint.

The **foramen magnum** is the large opening in the occipital. At its anterior edge is the single **occipital condyle**. Anterior to the occipital condyle lies the **basioccipital** (Figure 8.4), one of the components of the occipital. The **basisphenoid** lies anterior to the basioccipital and has a tapered anterior end. The **parasphenoid** lies anterior to

this tapered end of the basisphenoid. The **basipterygoid processes**, one on either side, extend anterolaterally from the posterior end of the parasphenoid and contact the **pterygoid**, each of which articulates anteriorly with a **palatine**.

Anterior to the orbit, a complex of bones form the upper jaw and support the **bill** (Figures 8.1, 8.3, 8.4). This complex is the **maxilla**, and it includes the **nasals**, **premaxillae**, and **maxillae** (in this sense, as single bony elements). From its dorsal contact with the frontal, each nasal sends out two slender processes, one contacting the maxilla, the other contacting the premaxilla. The latter is a large element forming most of the dorsal and ventral anterior part of the upper jaw. Near its dorsal articulation with the nasal, the premaxillae can, in life, bend or flex slightly dorsally in many birds. The maxilla forms most of the posterior part of the upper jaw ventrally and contacts the palatine posteriorly. Finally, note the **zygomatic arch**, a slender bridge between the maxilla anteriorly and the quadrate posteriorly. It is formed almost entirely by the **jugal**; a small posterior contribution is made by the **quadratojugal**.

The mandible or lower jaw is composed of various bones, but they are difficult to distinguish. The **dentary** forms nearly the anterior half of the mandible. Its posterior end coincides roughly with the **mandibular foramen**. Most of the lateral surface posterior to the foramen is formed by the **supra-angular**. The **angular** is a smaller bone ventral to the supra-angular. The **articular** is a small element that articulates with the quadrate of the skull. Two other bones are present but are on the medial surface of the mandible.

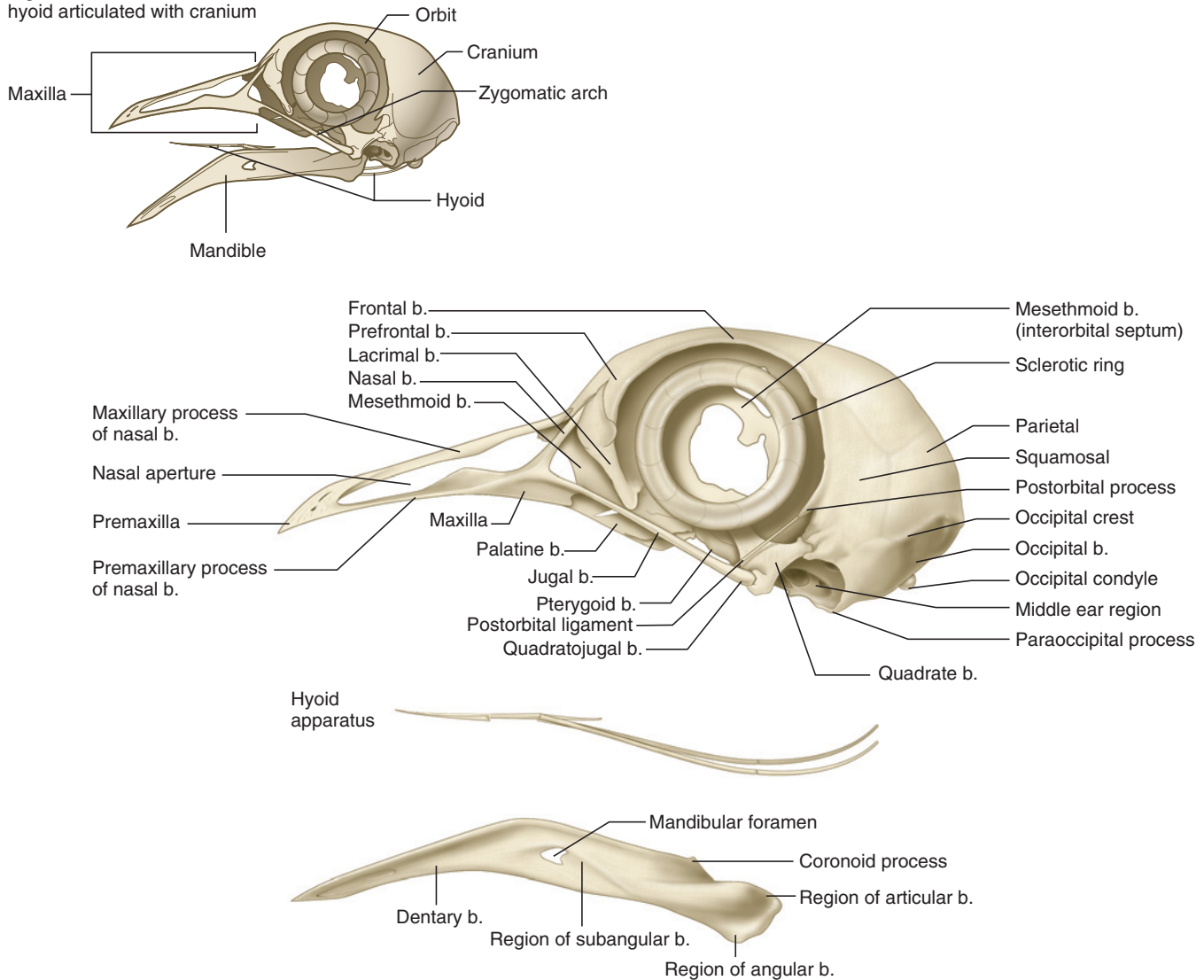
The hyoid apparatus (Figure 8.3) is a slender, elongated, Y-shaped structure that supports the tongue. It is formed by various elements, but they are difficult to distinguish and are not considered separately.

## Postcranial Skeleton

### Vertebrae

The vertebral column (Figure 8.1) normally includes 14 **cervical**, 5 **thoracic**, 6 **lumbar**, 2 **sacral**, and 15 **caudal vertebrae**. The column of the pigeon, as with most birds, is notable for its degree of fusion, with the exception of the cervical vertebrae. The atlas and axis are followed by 12 other cervical vertebrae, all fully mobile. The forelimbs of most birds are so specialized for flight that they are unavailable for other functions such as grooming or obtaining food. The long, mobile, S-shaped neck allows some of the functions usually performed by the forelimbs in other vertebrates. The last two cervicals bear small **ribs** that do not attach to the **sternum** (see below).

Pigeon skull with mandible and hyoid articulated with cranium

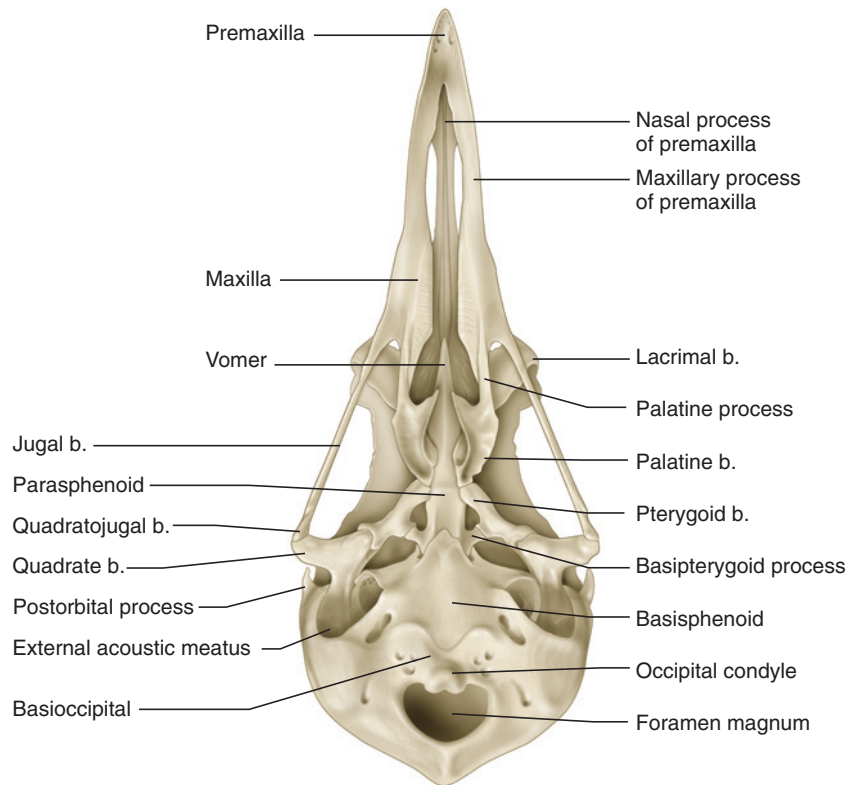


**FIGURE 8.3** Skull of the pigeon in left lateral view. Inset figure shows elements in position, and large illustration indicates detail.

There are five thoracic vertebrae, the first four of which are fused together. The thoracics each bear a pair of ribs. The fifth thoracic is fused to the first of the six lumbar vertebrae, which are all fused together and incorporated into the **syndesmus** (see below), as are the two sacral vertebrae. Of the 15 caudal vertebrae, the first five are incorporated into the syndesmus, the following six are free and mobile, and the last four are fused together to form the **pygostyle** (Figures 8.5 and 8.6). The extensive fusion of sections of the vertebral column posterior to the neck renders the trunk rather rigid. This inflexibility may be a feature that helps to reduce weight, as it decreases the need for extensive musculature to maintain a streamlined and rigid posture during flight.

## Ribs

There are several types of ribs (Figure 8.1). As noted above, ribs are associated with the last two cervical vertebrae. These ribs do not reach the sternum and are often referred to as *floating ribs* (or bicipital cervical ribs). The five ribs associated with the thoracic vertebrae are each formed from a robust, dorsal element, a **vertebral rib**, and a more slender, ventral element, a **sternal rib**. The vertebral rib, as its name implies, extends from the vertebra and articulates with the sternal rib, which in turn articulates with the sternum. In some specimens the last vertebral rib may articulate with the sternal rib of the preceding rib. Note the prominent, posteriorly projecting **uncinate processes**, which



**FIGURE 8.4** Skull of the pigeon in ventral view.

overlap the subsequent vertebral rib and help brace the ribs.

### ***Sternum***

The **body** of the **sternum** (Figures 8.1 and 8.12) is a large, curved plate of bone. Its most prominent feature is an extremely large vertical plate, the **carina** or keel. The body articulates anteriorly with the **procoracoids** (see below) and more posteriorly with the sternal ribs. The large **caudolateral process** projects posteriorly from behind the articular surfaces for the sternal ribs and helps form the **sternal notch**.

### ***Pectoral Girdle and Forelimb***

The pectoral girdle of birds is modified to produce a rigid and stable brace for the requirements of flight. These modifications are so pronounced that they usually are retained even in birds that are secondarily flightless. For example, the **scapula**, **procoracoid**, and **furcula** are tightly bound near the shoulder joint; the procoracoid is a stout, elongated element bracing the forelimbs against the sternum.

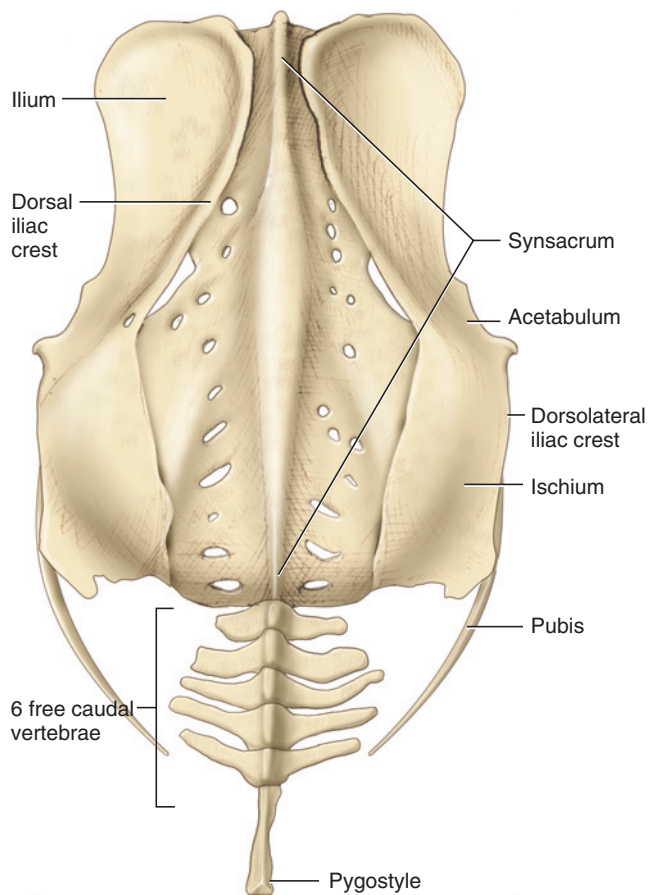
The scapula (Figures 8.1 and 8.12) is an elongated, blade-like bone that narrows anteriorly. Its anterior end forms part of the **glenoid fossa**, which articulates with the **humerus**.

The procoracoid (Figures 8.1, 8.10, and 8.12) is a stout bone. Its posterodorsal surface articulates with the scapula and completes the glenoid fossa. Dorsomedially, it articulates with the furcula (see below). The procoracoid widens ventrally and articulates with the body of the sternum, thus acting as a strut between the sternum and shoulder joint. The **triosseal canal** is a bony passage formed in many birds by three bones (hence its name), usually the scapula, procoracoid, and furcula, that serves as the passage for the tendon of the **supracoracoideus muscle** (see below). In the pigeon, however, the canal is formed only by the procoracoid. It is an oval opening located near the dorsal end of the procoracoid, just ventral to its articulation with the furcula.

The furcula (or wishbone) is a structure formed by the ventral fusion of the right and left clavicles and the median interclavicle. It is present in the pigeon, but in some species the clavicles remain unfused. In many mounted skeletons, a ligament extends between the ventral end of the furcula and the anterior end of the carina of the sternum.

The forelimb (Figure 8.1) consists of a stout proximal humerus, followed by the longer **radius** and **ulna**. The radius is the straighter, more slender bone. The ulna is bowed and has a short **olecranon process** distally. Its

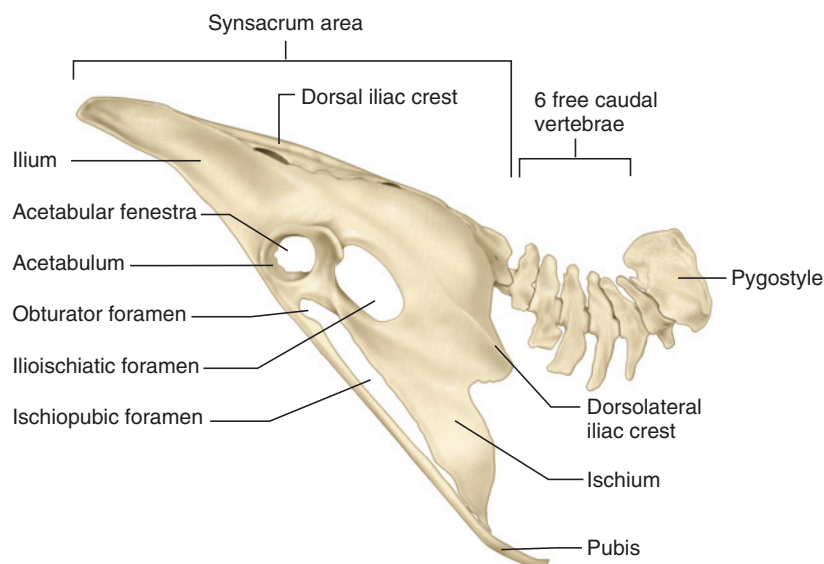




**FIGURE 8.5** Posterior part of vertebral column and pelvis of the pigeon in dorsal view.

posterior margin has several **remigeal papillae**, knob-like markings for the attachment of flight feathers. The manus consists, as usual, of carpals, metacarpals, and phalanges, but these have been highly modified in birds. Two **carpals** remain unfused: the **ulnare**, a slender bone that articulates with the ulna, and the **radiale**, which articulates with the radius. These carpals are followed by the **carpometacarpus**, an elongated element composed of several carpals, proximally, and three metacarpals fused together.

There has been considerable debate over the homology of the digits of birds, with some researchers considering them homologous with digits 1, 2, and 3 (as is typical of theropod dinosaurs) and other researchers considering them homologous with digits 2, 3, and 4. Recent morphological and developmental analyses suggest that the digits of birds represent digits 1, 2, and 3. The two elongated structures of the manus are **metacarpal II** (robust and nearly straight) and **metacarpal III** (slender and bowed). Although it is difficult to discern, **metacarpal I** (the alular metacarpal) is fused into the proximal end of the carpometacarpus, along with the carpals. The **phalanges** are also highly modified. Those of the alular digit are represented by the short, triangular fused element, including **phalanges 1** and **2**, at the proximal end of the carpometacarpus. **Phalanges 1** and **2** of digit 2 extend distally from metacarpal II. A small triangular element at the articulation between the carpometacarpus and phalanx 1 of digit 2 is **phalanx 1** of digit 3.



**FIGURE 8.6** Posterior part of vertebral column and pelvis of the pigeon in left lateral view.

## Pelvic Girdle and Hind Limb

The pelvis (Figures 8.1, 8.5, and 8.6) includes left and right **innominate** bones, each of which is formed by an **ilium**, **ischium**, and **pubis**. The ilium is the largest element, forming the dorsal half of the pelvis. It has two distinct regions: an anterior concave region and a posterior convex region (in dorsal view). The posterior part of the **dorsal iliac crest** separates these regions, just dorsal to the **acetabulum**, the depression that receives the head of the **femur** (see below). The crest continues posteriorly as the **dorsolateral iliac crest**. The ischium lies ventral to the posterior part of the ilium. The separation between these bones is marked roughly by the **ilioischadic foramen**. The acetabulum is directly anterior to it. Note that the floor of the acetabulum has an opening, the **acetabular fenestra**. The curved pubis is a very slender and elongated bone extending posteroventrally from the acetabulum, along the ventral margin of the ischium. Two other openings may be noted. The **obturator foramen** lies anteriorly between the pubis and ischium; the long and narrow **ischiopubic fenestra** lies more posteriorly.

A notable feature of birds is that the pelvis is solidly and extensively fused to the **synsacrum**, the posterior series of fused and expanded vertebrae (see above). The whole unit, pelvis and **synsacrum** together, form a rigid platform for muscles of the hind limb and tail, and is part of the system that helps a bird to maintain a stable, streamlined posture during flight.

The hind limb (Figure 8.1) includes several bones. The **femur** is the proximal bone. It is followed by the longer **tibiotarsus**, which is formed by fusion of the tibia and several **tarsals**. Articulating anteriorly between the femur and tibiotarsus is the small **patella**. A slender, splint-like **fibula** lies along the lateral surface of the tibiotarsus. Several tarsals and the 2nd, 3rd, and 4th **metatarsals** fuse together to form the **tarsometatarsus**, which bears a protuberance, the **hypotarsus**, on its posteroproximal surface. **Metatarsal I** articulates with the posterodistal surface of the tarsometatarsus. There are four digits in the **pes**, each ending in a claw. The first, or **hallux**, has two **phalanges** and is oriented posteriorly, while the three remaining digits point anteriorly. This arrangement, the most common among birds, represents the anisodactyl condition. Other arrangements include the zygodactyl (digits 1 and 4 are reversed) heterodactyl (digits 1 and 2 are reversed), syndactyl (digits 2 and 3 are fused together for much of their length), and pampodactyl (digits 1 and 4 pivot between facing anteriorly and posteriorly) conditions. Digit 2 has three phalanges, digit 3 has four phalanges, and digit 4 has five phalanges.

## KEY TERMS: SKELETON

acetabular fenestra	mesethmoid
acetabulum	metacarpal I (alular metacarpal)
angular	metacarpal II (major metacarpal)
articular	metacarpal III (minor metacarpal)
auditory meatus	metatarsal I
basioccipital	metatarsals
basipterygoid processes	middle ear
basisphenoid	nasals
body of sternum	obturator foramen
bill (beak)	occipital
carina (keel)	occipital condyle
carpals	olecranon process
carpometacarpus	orbits
caudal vertebrae	palatine
caudolateral process	parasphenoid
cervical vertebrae	parietals
dentary	paroccipital
dorsal iliac crest	patella
dorsolateral iliac crest	pes
femur	phalanges
fibula	postorbital process
foramen magnum	premaxilla
frontals	procoracoid
furcula	pterygoid
glenoid fossa	pubis
hallux	pygostyle
humerus	quadrate
hypotarsus	quadratojugal
ilioischadic foramen	radiale
ilium	radius
innominate	remigeal papillae
ischiopubic fenestra	ribs
ischium	sacral vertebrae
jugal	scapula
lumbar vertebrae	sclerotic ring
mandible	squamosals
mandibular foramen	sternal notch
maxilla (as a complex forming the upper jaw)	sternal rib
maxillae (as single bony elements)	sternum

supra-angular	triosseal canal
supracoracoideus muscle	ulna
synsacrum	ulnare
tarsals	uncinate processes
tarsometatarsus	vertebral rib
thoracic vertebrae	zygomatic arch
tibiotarsus	

## SECTION II—EXTERNAL ANATOMY

The **bill** (or beak) is the most prominent feature of the head (Figure 8.7). It includes the maxilla and mandible, which are covered by a horny sheath or **rhamphotheca**. Open the mouth and note the absence of teeth. The **nares** (sing., **naris**) pierce the maxilla. Immediately posterior to them is the **operculum**, a soft swelling of the integument. The **eyes** are large, as would be expected in a vertebrate that depends largely on vision. The **external acoustic meatus**, leading to the tympanic membrane of the ear, lies posterior and just ventral to the level of the eye, but is concealed by **feathers** (Figures 8.8, 8.9).

The most obvious feature of birds is the presence of feathers, which in most birds serve primarily for flight and temperature control and will be examined in more detail below. The **neck** appears shorter than it really is (see Section I), but this is due to the covering of feathers. The **forelimbs** are strongly modified to form wings. Spread the wings and note the prominence of the feathers. In contrast, the distal part of the hind limb, including the pes, is covered by horny **scales**.

The dorsal region is the **dorsum**, whereas the ventral region includes the expanded **breast** anteriorly and the **venter** or belly posterior to it. At the posterior end of the body, the **tail** includes the short posterior, fleshy stump of the body, the **uropygium**, as well as the feathers extending from it. Spread the feathers on the dorsal surface of the uropygium to reveal the **uropygial gland** (Figure 8.11). The gland produces an oily secretion used in preening that protects the feathers. Spread the ventral tail feathers and note the slit-like opening of the **cloaca** (Figure 8.14).

There are several types of feathers in birds, but only the larger **contour feathers** are described here. Contour feathers are those that are typically thought of as feathers, such as the flight feathers on the wings and tail, as well as smaller feathers that cover much of the body. Examine a contour feather (Figure 8.8) from the wing of the pigeon. Note the central **shaft** or quill. The **calamus** is the hollow, basal part of the quill, while the **rhachis** is the part bearing **barbs**, the tiny, parallel structures that branch from the rhachis. Numerous **barbules**

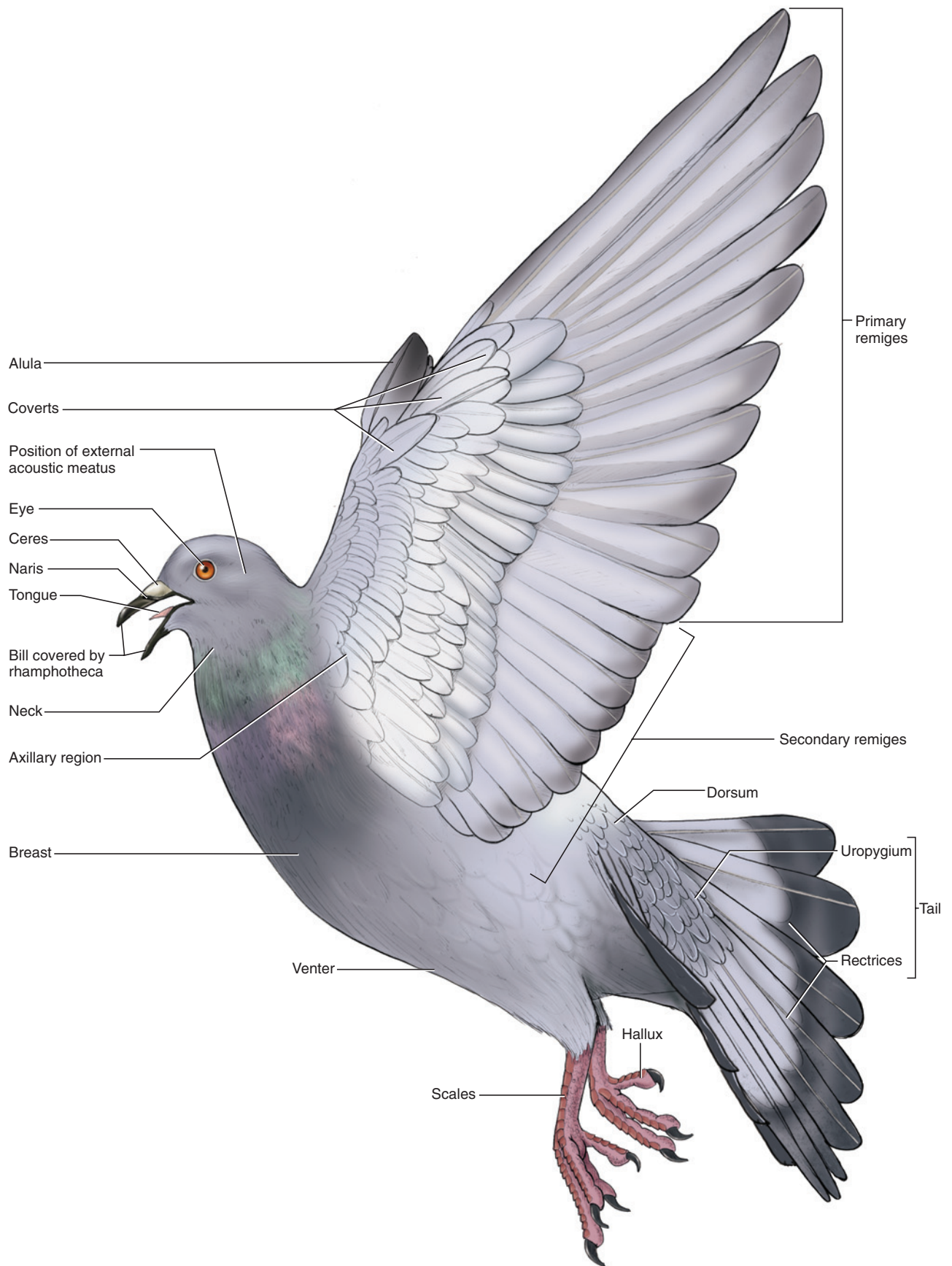
branch out from each barb and each barbule bears tiny **hooklets** that interlock with hooklets of adjacent barbules to help maintain the shape and structure of a feather. Magnification is required to observe barbules and hooklets. The barbs are arranged in two **vanes**. The vanes are usually symmetrical around the rhachis in most contour feathers covering the body, but are asymmetrical in most of the flight and, to a lesser degree, tail feathers. In flight feathers, the vane facing the leading edge of the wing is narrower than at the trailing edge.

Feathers are designated by their position on the body, and there are numerous different types. Here, only the more typical ones important in flight on the tail (Figure 8.7) and wing (Figure 8.9) are distinguished. The **remiges** (sing., **remex**) are the large feathers of the wing. On the trailing edge of the wing, the **primary remiges** (or, simply, primaries) are the feathers attaching to the distal end of the wing, the carpometacarpus and phalanges, and are numbered from 1 to 10 in proximal to distal order. Those attaching to the ulna are the **secondary remiges**, of which there are usually 15, numbered in distal to proximal order. The **tertiary remiges**, usually four in number, lie proximal to the most proximal secondaries. The **coverts**, which vary in size, cover nearly all of the remainder of the wing. The exception is a small patch of (usually four) **alular quills**, which arise from the alular phalanx and together form the **alula** or bastard wing. Though relatively small, the alula is an extremely important flight structure that helps avoid stalling during low velocity flight. The feathers of the tail are termed **rectrices** (sing., **rectix**).


### KEY TERMS: EXTERNAL ANATOMY

alula (bastard wing)	neck
alular quills	operculum
barbs	primary remiges
barbules	rectrices (sing., rectix)
bill (beak)	remiges (sing., remex)
breast	rhachis
calamus	rhamphotheca
cloaca	scales
contour feathers	secondary remiges
coverts	shaft
dorsum	tail
external acoustic meatus	tertiary remiges
eyes	uropygial gland
feathers	uropygium
forelimbs	vanes
hooklets	venter
nares (sing., naris)	





**FIGURE 8.7** External features of the pigeon, with forearm (wing) abducted, in left lateral view.



**FIGURE 8.8** Feather of the pigeon, with blowups showing successively finer detail of structures.

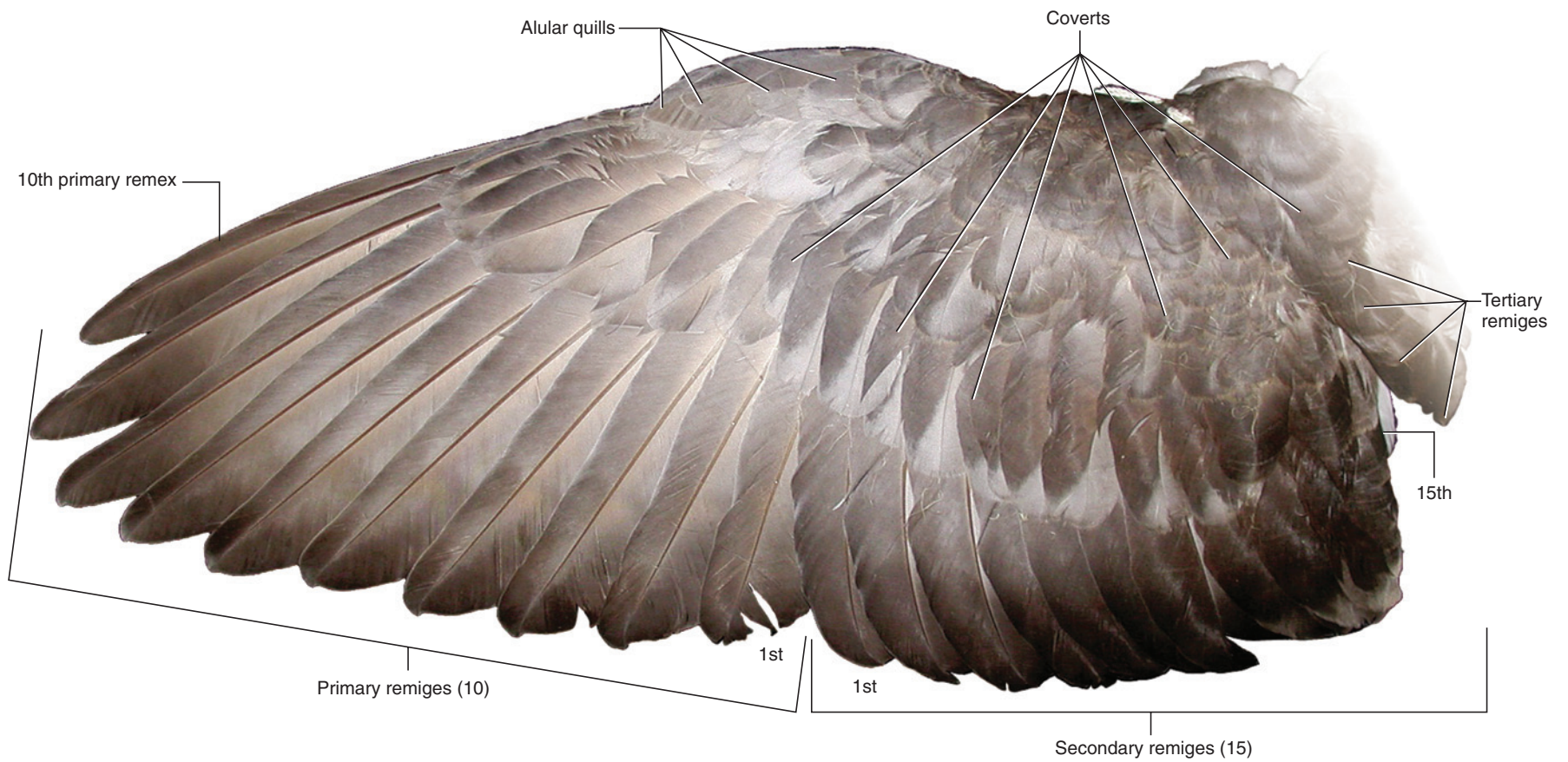
### SECTION III—MUSCULATURE

As the flight and wing musculature are among the more interesting features of the pigeon, they are the focus of this dissection. To study the musculature, the skin must be removed. Begin by brushing aside the feathers from the midventral surface of the thoracic region. Note that there are no feathers attached at the midline. Make a longitudinal incision through the skin, but work carefully, as it is quite thin. Extend the incision from the cloaca anteriorly to the anterior part of the breast, and then spread the skin, separating it from the underlying tissue using a blunt probe. In most places the skin will come off readily, but in some spots muscular slips attach to the skin, and must be cut through. You will reveal the **pectoralis** (Figure 8.10), the largest and most superficial of the flight muscles. At the anterior part of the pectoralis lies the thin-walled **crop**, a sac-like specialization of the **esophagus** (see below) that is used to store food. Carefully continue the incision anteriorly, being careful not to injure the crop, to just below the bill. Skin the neck, but do not damage vessels.

Several folds of skin form the wing surface. The large fold between the shoulder and carpus, forming the leading edge of the wing, is the **propatagium**. Several delicate muscles and tendons lie within it. A large **postpatagium** projects posteriorly from the ulna. With the wing outstretched, gently push back on the leading edge of the propatagium. The tension you feel is due to the **long tendon** (see below). Begin skinning the wing ventrally, near the central part of the brachium, and work your way anteriorly. As you approach the leading edge, be watchful of the tendon, a thin, whitish strand, and uncover it. Proceed to skin the rest of the wing up to the carpus. Then continue skinning the dorsal surface of the wing and body.

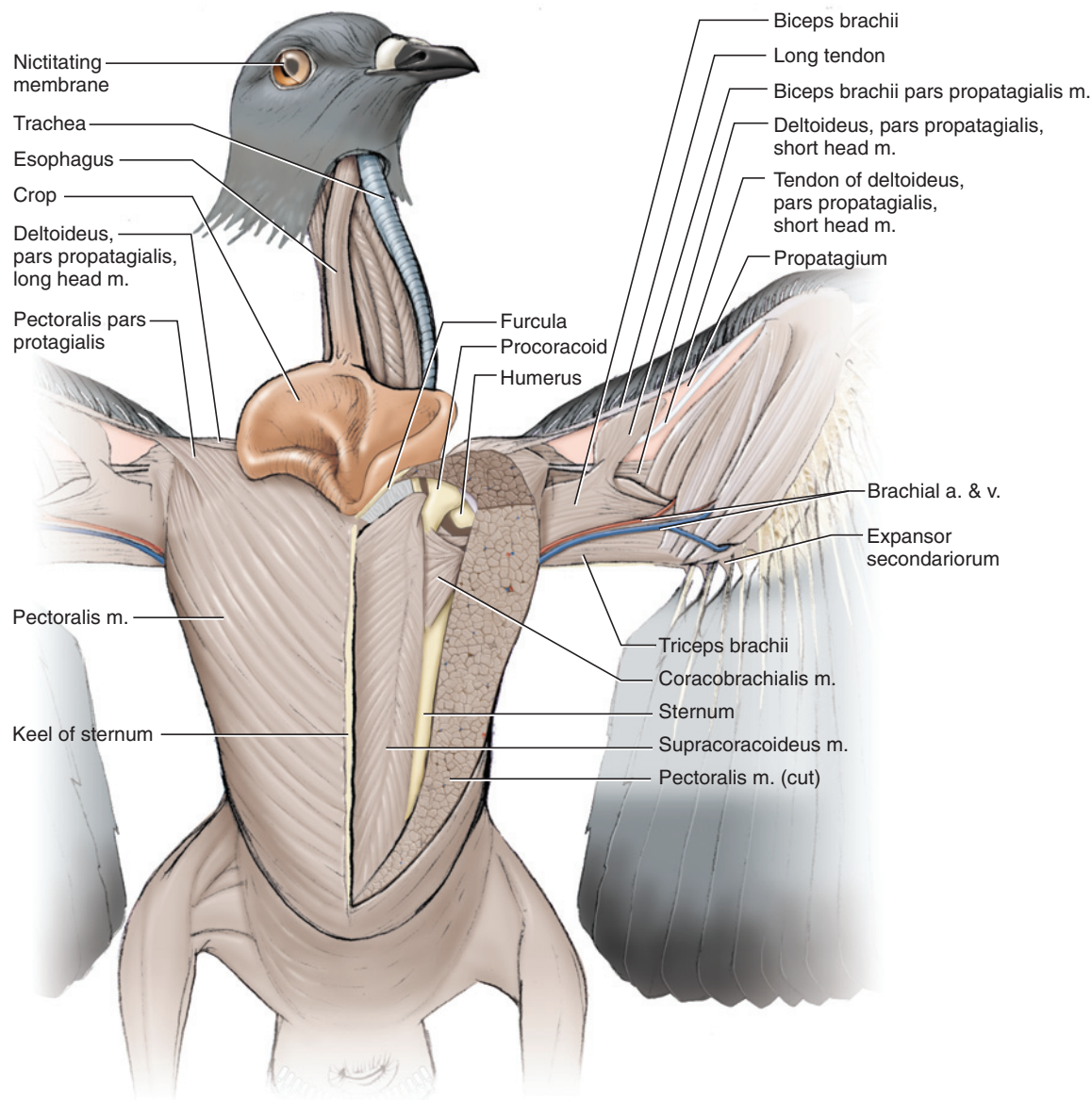
The dominance of the pectoralis can now be appreciated. It arises from the sternum and, being the main depressor of the wing, inserts mainly on the humerus. The shoulder is covered mainly by several parts of the **deltoideus** muscle (Figures 8.10 and 8.11). Anteriorly, the deltoid is represented by the **pars propatagialis**, a single hypertrophied belly consisting of long and





**FIGURE 8.9** Extended left wing of the pigeon, in dorsal view, showing arrangement of feathers.



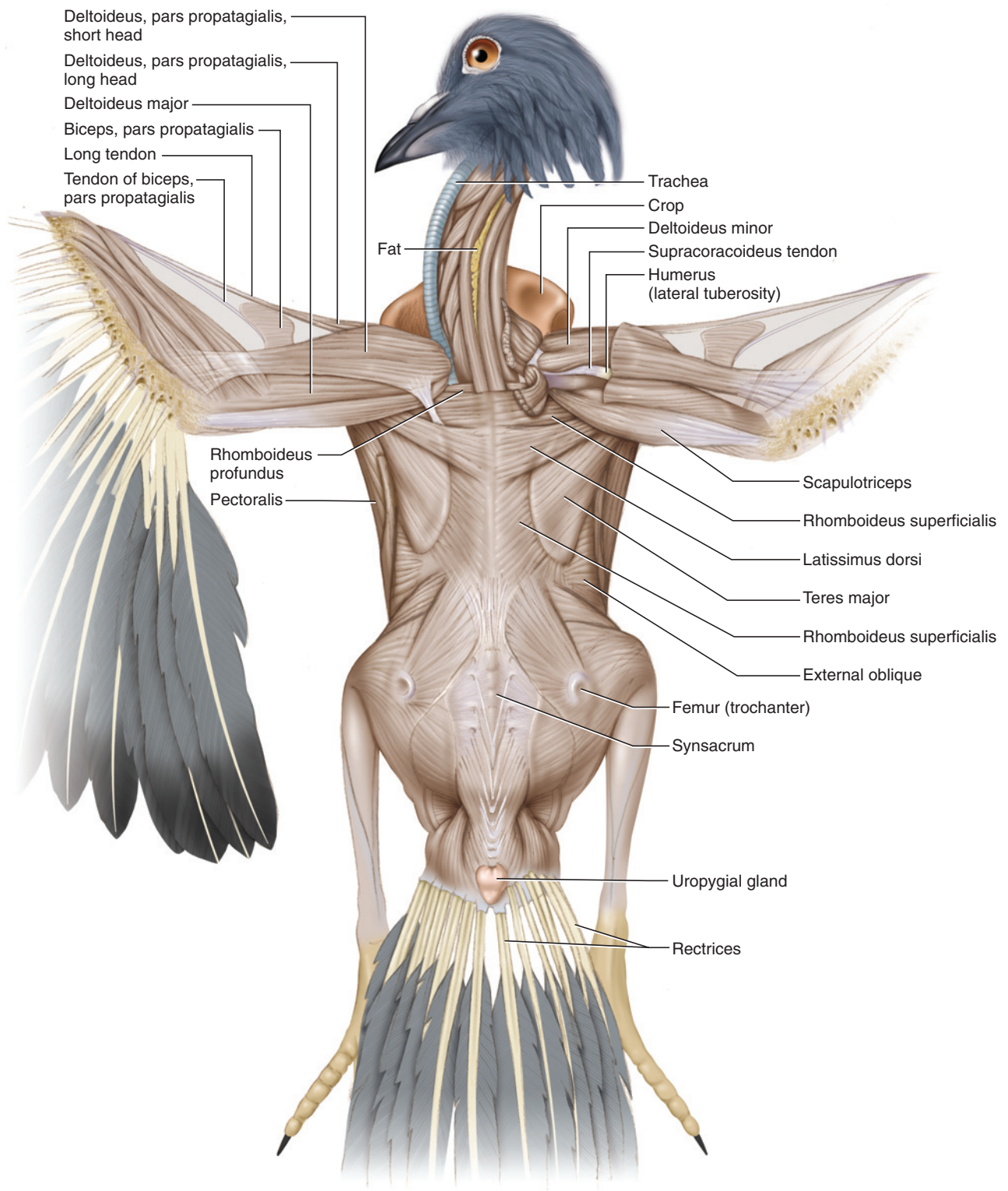


**FIGURE 8.10** Pectoral and wing musculature of the pigeon in ventral view. Left-side pectoralis muscle cut away to show underlying structures.

**short heads.** The long head is the smaller, anterior, sheet-like portion. The more posterior short head is thicker. The long head is just anterior to a small, triangular slip of the pectoralis that inserts on the common belly of the pars propatagialis. The tendon of the long head, the long tendon noted above, extends laterally toward the carpus and divides into two separate tendons, but these may be difficult to discern. Distally, the short head forms a tendinous sheet that mainly spreads to cover the muscles on the antebrachium. The **biceps brachii** muscle covers the anteromedial part of the brachium. The pars propatagialis is a slip of the biceps and arises from its anterior edge. Anteriorly, the pars propatagialis fuses with the tendon of the long tendon. Its distal end gives rise to a tendon that

angles distally to fuse with one of the divisions of the long tendon. The wing muscles described in this paragraph, except the biceps brachii, serve mainly to alter tension of the wing surface. They are commonly referred to as tensors and play a significant role in flight aerodynamics.

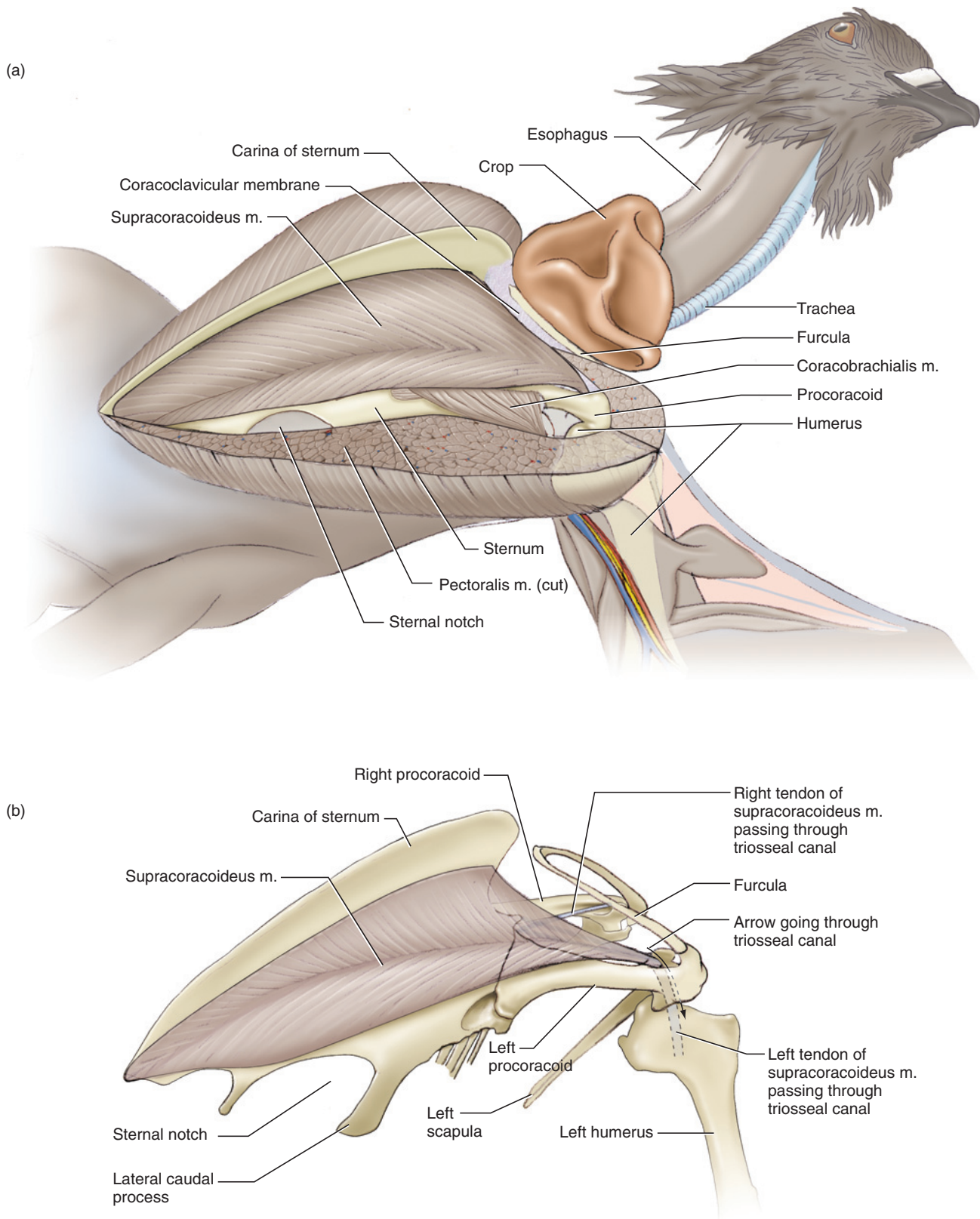
Several other wing muscles may be noted. Just posterior to the short head of the pars propatagialis of the deltoideus is the **deltoideus major**, which pulls the humerus medially and posteriorly. The triceps brachii has three portions, but only two of them, the **scapulotriceps** and **humerotriceps**, can be readily identified. The third, the coracotriceps, is a small muscle arising from the tendon of the **expansor secundariorum**. This tendon extends



**FIGURE 8.11** Musculature of the pigeon in dorsal view.

from the axilla, or armpit, along the posterior edge of the triceps brachii. Carefully dissect the margin of the postpatagium to find the small and delicate muscular portion, which fans onto the quills of the secondary remiges. The expansor secundariorum acts to spread the secondaries.

The main elevator of the wing is the **supracoracoideus**, which lies deep to and is covered entirely by the pectoralis. To expose it, make a cut through the pectoralis near its center and at right angles to the fiber direction, but do so only a few millimeters at a time. Spread the incision as you cut. This will help avoid damaging the



**FIGURE 8.12** Pectoral musculature of the pigeon in left ventrolateral view. (a) Left-side pectoralis muscle cut away. (b) Sternum and appendicular skeleton isolated to show supracoracoideus muscle and the course of its tendon through the triosseal canal.



underlying supracoracoideus. Once you have cut through the pectoralis and identified the supracoracoideus, cut out a large portion of the pectoralis to expose the supracoracoideus (Figures 8.10 and 8.12). Its fibers converge toward the middle of the muscle and extend to a stout anterolaterally directed tendon that passes through the triosseal canal onto the dorsal surface of the humerus. This acts as a pulley system, through which the wing is elevated mainly by a muscle, the supracoracoideus, that lies ventral to the wing. This arrangement enhances stability for flight by maintaining the center of gravity below the wings. To see the tendon of the supracoracoideus (Figures 8.10–8.12), cut the deltoideus major and the pars propatagialis of the deltoideus near their center and reflect them. You will uncover the **deltoideus minor**, which contributes to elevation of the wing. The tendon passes just posterior to the posterior margin of the deltoideus minor.

Other musculature that may be noted without much further effort includes the **rhomboideus superficialis** and **rhomboideus profundus**, which extend between vertebral spines and the scapula. The superficialis covers all but the anteriormost portion of the profundus. The **latissimus dorsi** is a relatively small muscle extending laterally from the middorsal line. These muscles form part of the complex of muscles that help support and stabilize the shoulder. Although there are various other back muscles, an interesting condition in birds is the relative lack or smaller size of the back musculature as compared, for example, with that of the cat. Strength and stability of the trunk is not compromised, however, as the skeletal elements are firmly fused together (see above), and this in turn allows the musculature to be reduced to minimize weight.

### KEY TERMS: MUSCULATURE

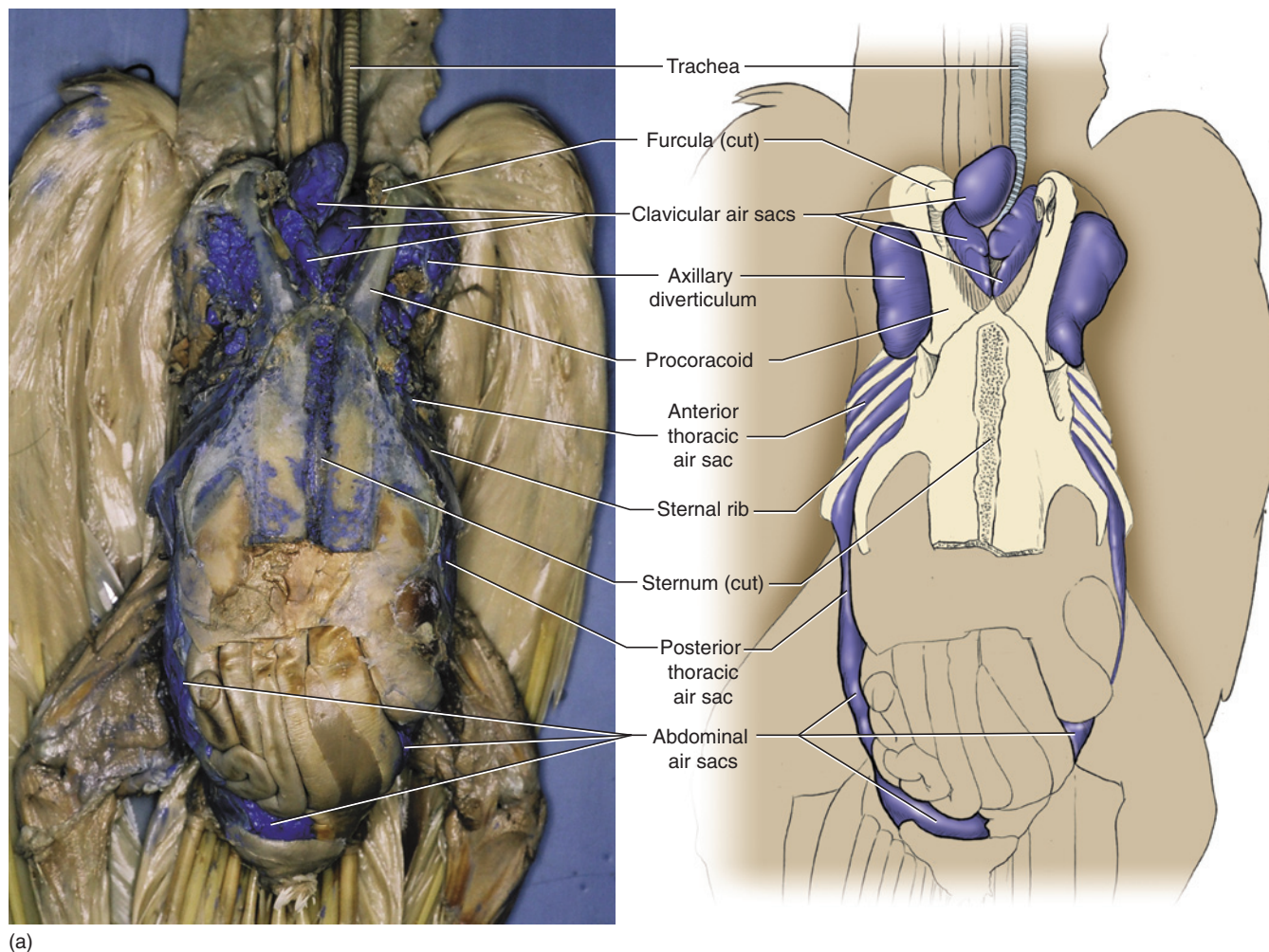
biceps brachii	slip, biceps
crop	propatagialis, patagial accessory)
deltoideus	
deltoideus major	pars propatagialis, long and short heads of
deltoideus minor	deltoideus
esophagus	pectoralis
expansor secundariorum	postpatagium
humerothriceps	propatagium
latissimus dorsi	rhomboideus profundus
long tendon of long head, pars propatagialis of deltoideus	rhomboideus superficialis
pars propatagialis of biceps brachii (biceps	scapulotriceps
	supracoracoideus

## SECTION IV—BODY CAVITY, VISCERA, AND VESSELS

The sternum and pectoral musculature must be removed to examine the structures within the body cavity, including viscera and blood vessels. Unfortunately, removal of the sternum and muscles as described below often obliterates much of the extensive respiratory system, the **air sacs** that form auxiliary air pathways in the avian respiratory system. This system was noted above in connection with the continuation of this system into several bones of the body. In birds, the respiratory system is arranged to produce a continuous stream of air through the lungs, which is made possible by the presence of the air sacs. In contrast, the system in other air-breathing vertebrates, in which air passes into and out of the lungs through the same pathway, results in a residual volume of air in the lungs. The avian system is considerably more efficient and allows the high metabolic levels required for sustained flight. The system is also involved in cooling. Although some of the air sacs can be seen when the body cavity is exposed, the system is best seen and appreciated in a prepared specimen. If a preparation is available, use Figure 8.13 to identify the major air sacs.

Return to the task of exposing the body cavity. Clear the connective tissue from the lateral part of the pectoral muscles, just posterior to the axillary regions, but do not damage any vessels. Make a longitudinal incision through the abdominal muscles, just to one side of the midventral line, and, using stout scissors, follow anteriorly along the lateral margin of one of the pectoral muscles, cutting through the ribs as you do so. Lift the sternum as much as possible and clear the connecting tissue until you see the vessels that pass to the sternum, so that you will avoid damaging them. Using a sharp scalpel, cut through the anterior part of the pectorals, as shown in Figure 8.14. You will also need to cut (with stout scissors) through the furcula and coracoid. Repeat this procedure for the pectorals on the other side. You will then be able to lift the sternum with the pectoral musculature attached to it. Remove the sternum by clearing the connective tissue between it and the deeper structures. Cut through the vessels, the **pectoral arteries** and **veins** (Figure 8.14), extending to the breast as close to the sternum as possible.

Note the **heart** (Figure 8.14) lying anteriorly on the midline. Its four main chambers include the **left** and **right atria** (sing., **atrium**) and **left** and **right ventricles** (a very small **sinus venosus** is also present but will not be identified). The **lungs**, right and left, are tucked laterally to the heart. Probe to find them, and partially remove the serosa covering them to see their spongy texture. Posterior to the heart are the lobes of the **liver**; note that



**FIGURE 8.13** Photographs and interpretive illustrations of trunk of the pigeon to show the arrangement of major air sacs of the respiratory system. (a) Ventral view. (b) Left lateral view (see page 243).

the right lobe is considerably larger than the left. Tucked deep to these lobes, on the left side, is the **gizzard**, the very muscular, distal portion of the complex, two-part **stomach** of birds. The glandular **proventriculus**, the anterior part of the stomach (though it is actually a modification of the distal part of the esophagus), continues posteriorly from the **esophagus** and lies deep to the heart, as does the posterior part of the trachea. These structures will be seen shortly (Figure 8.15). The highly coiled **small intestine** is relatively long, in contrast to the short and straight **large intestine** (Figures 8.16 and 8.17). The division between these structures is marked by the presence of a pair of small diverticula, the **colic ceca**.

Return to the heart (Figure 8.14). The **ascending aorta** arches anteriorly from the left ventricle and gives off the paired **brachiocephalic arteries** before curving to the right and posteriorly as the **aortic arch**. Each brachiocephalic soon divides into a smaller **common carotid**

**artery** and larger **subclavian artery**. The common carotid is a short artery that extends anteriorly to the base of the neck, where it divides into several arteries. The most apparent branch is the **internal carotid artery**, which extends anteriorly along the midventral surface of the neck, close beside the other side's internal carotid. These vessels converge and continue together, deep to the musculature, toward the base of the neck. Each gives off several branches, including the external carotid artery. The other branch of the common carotid gives rise to several, mainly anastomosing, vessels that ascend the neck dorsal to the internal carotid, but it is not necessary to attempt to trace these. The subclavian artery extends laterally for a short distance (after the origin of the common carotid) before subdividing into the **axillary artery** and **pectoral artery**, already noted above. The latter is a large vessel that quickly branches into several smaller arteries to supply the extensive pectoral musculature. The axillary artery gives off several branches before continuing into the arm as the **brachial artery**.



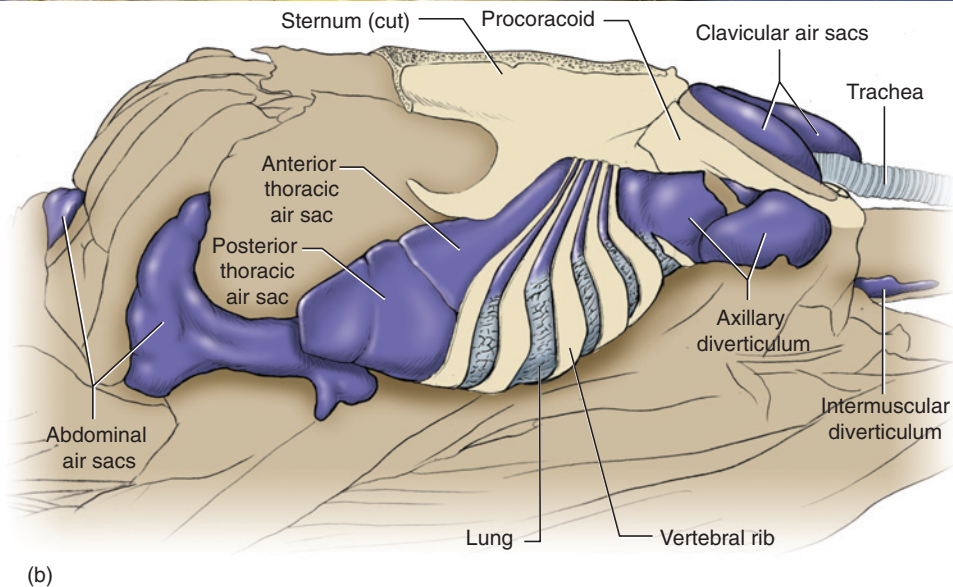
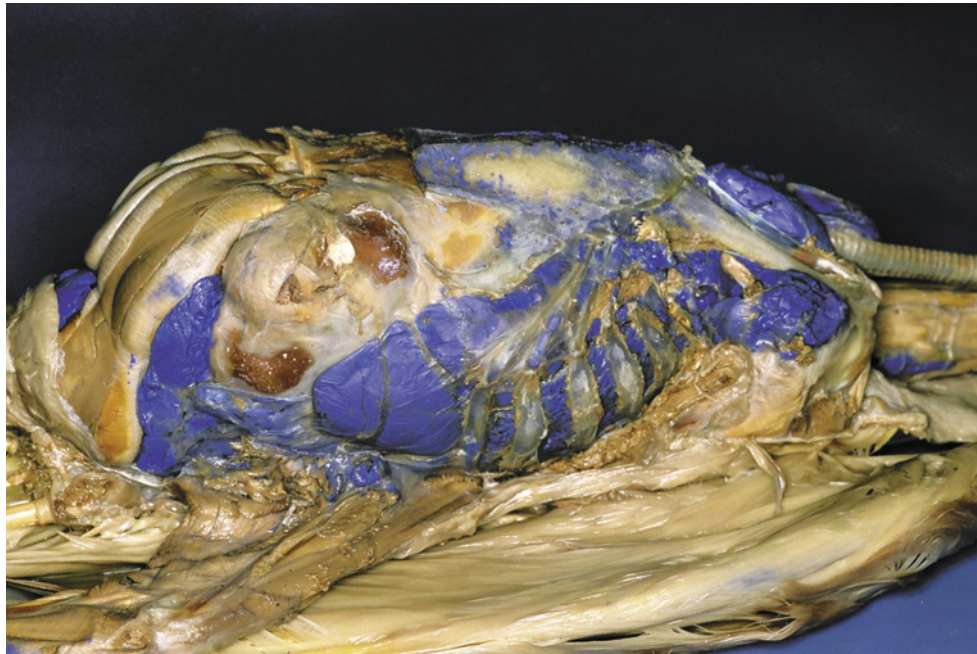


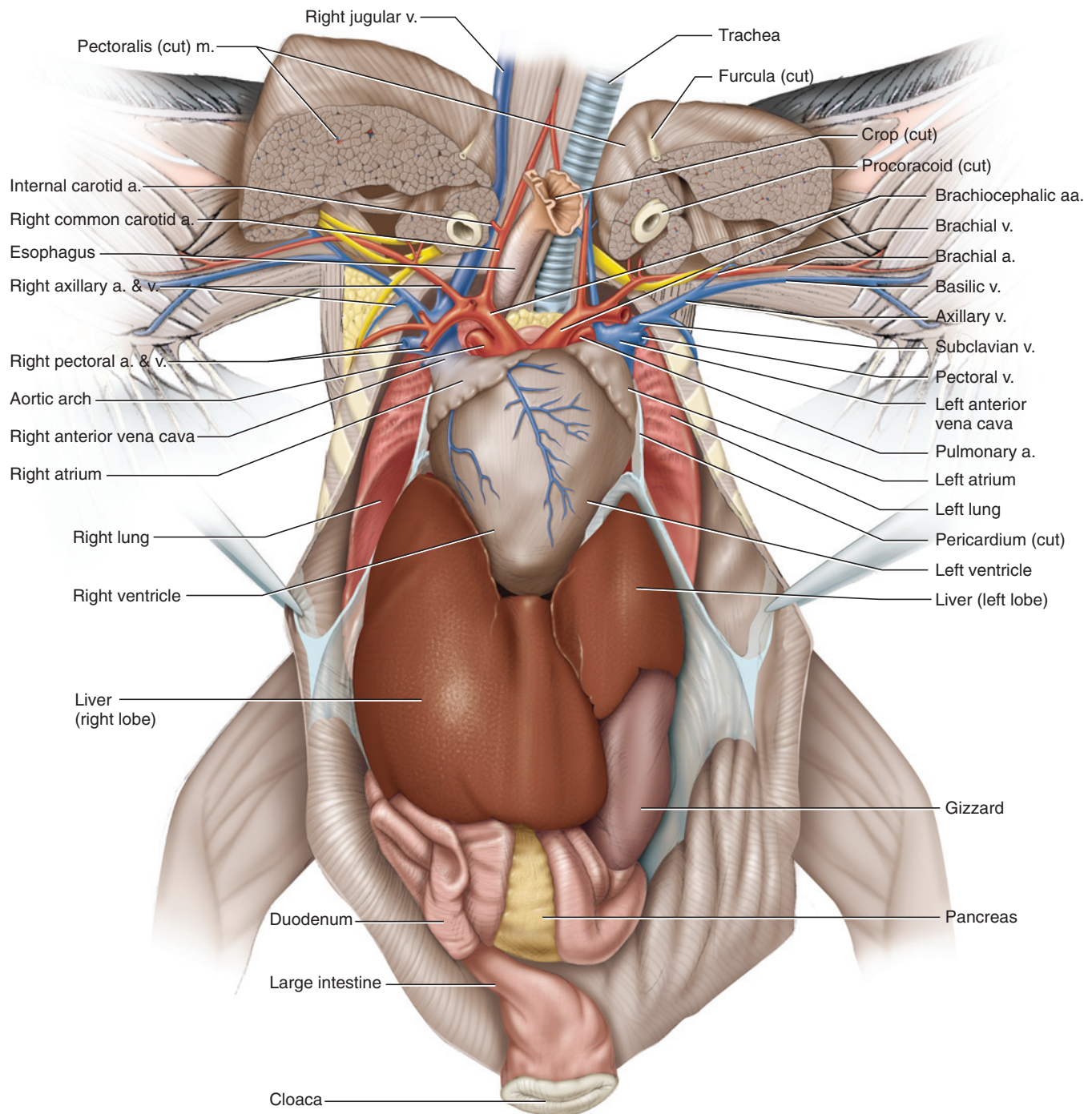
FIGURE 8.13 *Continued*

Most of the regions supplied by these arteries are drained by veins that ultimately enter the **right** or **left anterior vena cava**, each of which is formed by the confluence of three large vessels, the **jugular**, **subclavian**, and **pectoral veins**. The jugular lies along the lateral surface of the neck, draining the head and neck. The right jugular is usually larger than the left. The subclavian vein is a short segment that mainly receives the **axillary vein**, which in turn receives the **basilic vein** from the arm. It is the basilic and not the **brachial vein** that follows the brachial artery. The brachial vein is represented by an anterior branch of the axillary that divides into two narrow vessels along the anterior margin of the brachial muscle. The pectoral vein, which

divides further into branches much as those of the pectoral artery, usually enters the anterior vena cava but enters the subclavian in some specimens. The right anterior vena cava proceeds almost directly posteriorly to enter the sinus venosus, but the left anterior vena cava turns right and crosses the heart to enter the sinus venosus. The **posterior vena cava** (Figures 8.16–8.18) is a large vessel that drains the posterior part of the body. It can be found by lifting the lateral margin of the right atrium. Its branches will be followed shortly.

The **pulmonary trunk** leaves the right ventricle and almost immediately splits into **left** and **right pulmonary arteries** (Figures 8.14 and 8.15) to the lungs. The left



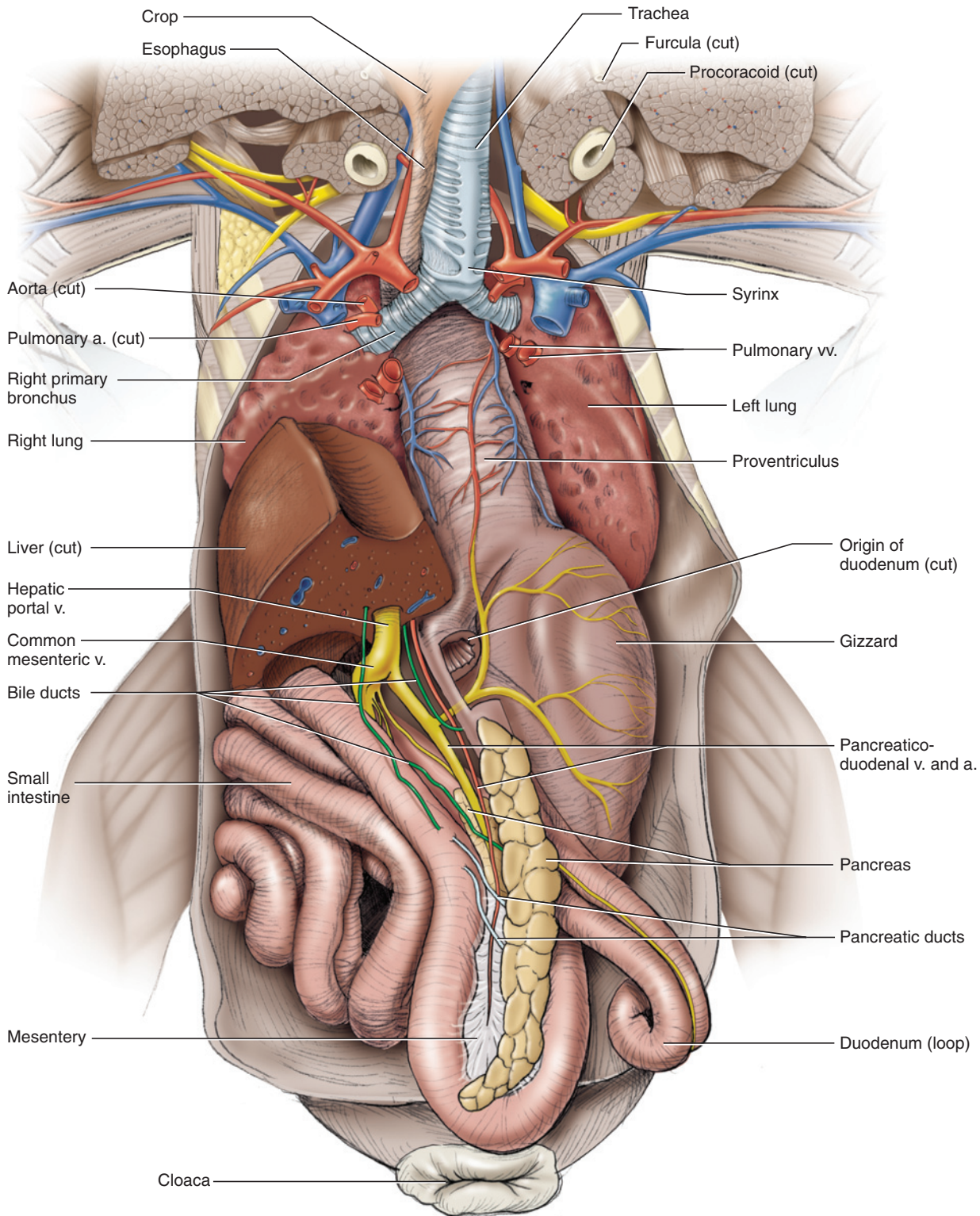


**FIGURE 8.14** Trunk of the pigeon in ventral view. Pectoral musculature and sternum removed to reveal heart, viscera, and vessels.

pulmonary artery is easily apparent and can be found passing dorsal to the left brachiocephalic artery. There are two **right** and two **left pulmonary veins** that return blood from the lungs. These vessels enter the left atrium separately. They are not easy to find, but will be seen when the heart is removed (Figure 8.15).

Lift the heart and note the great vessels, just described, associated with it. Cut each vessel, and remove the

heart. This will expose the lungs and allow you to follow the trachea and esophagus posteriorly (Figure 8.15). The trachea is held open by cartilaginous rings. More posteriorly it bifurcates into left and right **bronchi**, which extend into the lungs. The **syrix** is the sound-producing organ located at the base of the trachea. Examine the cut vessels, and identify the pulmonary arteries and pulmonary veins. The latter exit the lungs just posterior to the entrance of the bronchi. There



**FIGURE 8.15** Trunk of the pigeon in ventral view. Pectoral musculature and heart removed to reveal viscera and vessels.



are two main veins on each side but it may be difficult to discern them. The pulmonary arteries enter the lungs somewhat anterior to the bronchi.

Remove the left lobe of the liver, being careful not to injure vessels external to it. Once it has been removed, you will be able to follow the esophagus to the stomach. In birds, the stomach is a complex, two-part organ. The more proximal proventriculus secretes strong hydrochloric acid and digestive enzymes that begin the chemical digestion of food. The thicker, muscular gizzard performs most of the mechanical breakdown of food.

Next, examine the intestines. Note that they are bound by mesentery. Various vessels will be seen either supplying or draining the viscera. For the time being, identify the large **hepatic portal vein** (Figure 8.15) that extends between the viscera and the right lobe of the liver. Lift the lobe to note the entrance of the vein into the liver. Cut the portion (and only that portion) of the right lobe that is posterior to the entrance of the hepatic portal vein. You will now be able to follow the intestinal tract more easily. The **duodenum**, the first part of the **small intestine**, arises from the junction of the proventriculus and gizzard. It makes a long loop, consisting of ascending and descending portions that lie close together. Between them is the narrow, elongated **pancreas**. Follow the remaining part of the small intestine. It passes into the short and straight large intestine, which continues posteriorly into the cloaca. A pair of small **colic ceca** (sing., **cecum**) mark the division between the small and large intestines.

Return to the duodenum. Carefully dissect the connective tissue between its ascending and descending portions and the pancreas. You will reveal several structures, including the bile ducts and pancreatic ducts (Figure 8.15). There are three of the latter, but only two are readily apparent. Also, you will reveal a large vein, the **pancreaticoduodenal vein**, accompanied by the smaller **pancreaticoduodenal artery**, associated with the pancreas.

Carefully uncoil the intestines to observe that the **posterior mesenteric vein**, a branch of the hepatic portal system, extends posteriorly and eventually joins the venous system of the posterior abdominal cavity (see Figures 8.16–8.18). Once the hepatic portal system has been studied, find the point where the posterior vena cava, which returns blood from most of the body posterior to the heart, passes through the left lobe of the liver. This occurs dorsal to the entrance of the hepatic portal vein. Cut through the vena cava and remove the remainder of the liver. Cut through the distal end of the proventriculus, just dorsal to its union with the gizzard. Find the **celiac** and **anterior mesenteric** arteries

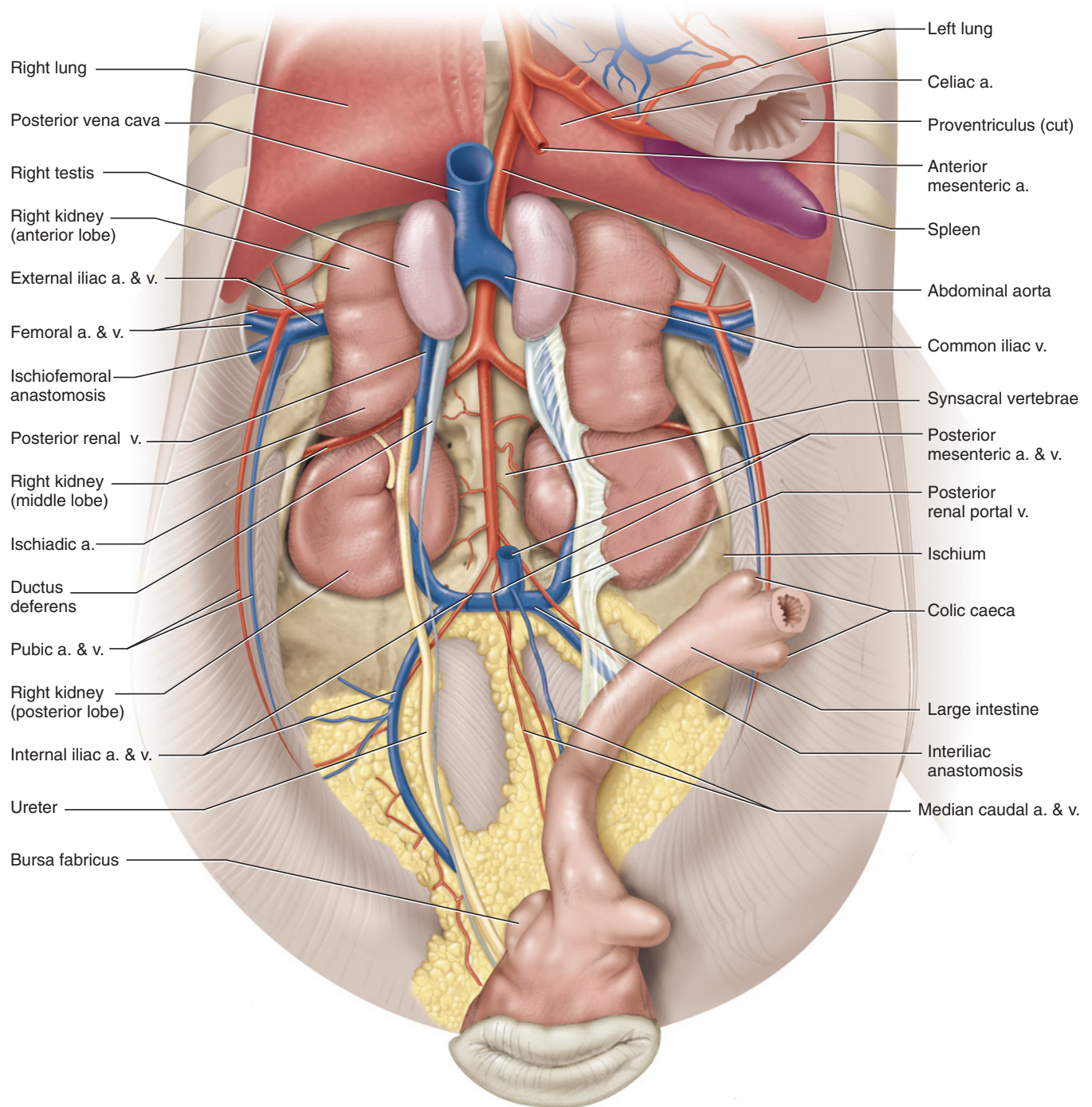
(Figure 8.16) as they emerge from the aorta, just to the right of the distal end of the proventriculus. The ovoid, dark-colored **spleen** lies in this region as well and can vary in size. Follow the celiac artery, noting its main branches. Cut through them and the anterior mesenteric artery. Also cut through the posterior end of the small intestine, just anterior to the colic ceca, and the posterior mesenteric vein. Then remove the digestive tract.

Clear away connective tissue to expose the urogenital structures and the vessels lying on the dorsal wall of the abdominal cavity. Each **kidney** is superficially subdivided into three lobes by the vessels that pass through it. Males (Figure 8.16) possess a pair of approximately bean-shaped **testes**. Each lies on the anterior lobe of a kidney. In nonbreeding males, the testes are much smaller than in breeding males and may be difficult to identify. The **vas deferens** carries semen from the testis to the cloaca. It leaves, slightly expanded, the dorsomedial side of the testis and extends posteriorly to the cloaca as a relatively straight, narrow tube. It is slightly wider and may be convoluted in breeding males. It passes for most of its length along the medial side of the **ureter**, the wider tube that carries urine from the kidneys to the cloaca. The ureter emerges from between the anterior and middle lobes of the kidneys. Near the cloaca, the vas deferens crosses the surface of the ureter and extends to the cloaca, lateral to the ureter.

In females (Figure 8.17) only the left-side reproductive organs are present, those of the right side having degenerated soon after their initial formation. The **ovary** lies on the anterior end of the left kidney. Its morphology and size varies in accordance with the breeding season. The ovary contains numerous spherical **follicles** in various stages of development. Mature ova pass from the ovary and enter the oviduct through its anterior opening, the **ostium**. The **oviduct** is a relatively straight tubular structure (Figure 8.17) that becomes large and convoluted. It conducts the ovum to the cloaca and is subdivided into glandular portions that perform specific roles (such as secreting the shell membrane or the shell itself), but these portions are not identifiable grossly. The left and right ureters of the female are in the same position as in the male. A vestigial posterior portion of the right oviduct may be present along the posteromedial end of the right ureter.

Return to the posterior vena cava and follow it posteriorly (Figures 8.16–8.18). It is formed at the level of the anterior part of the kidneys by the confluence of the **right and left common iliac veins**. An **anterior renal vein**, draining the anterior lobe of the kidney, enters each common iliac. The common iliac turns laterally between the anterior and medial lobes of the kidney. As it does



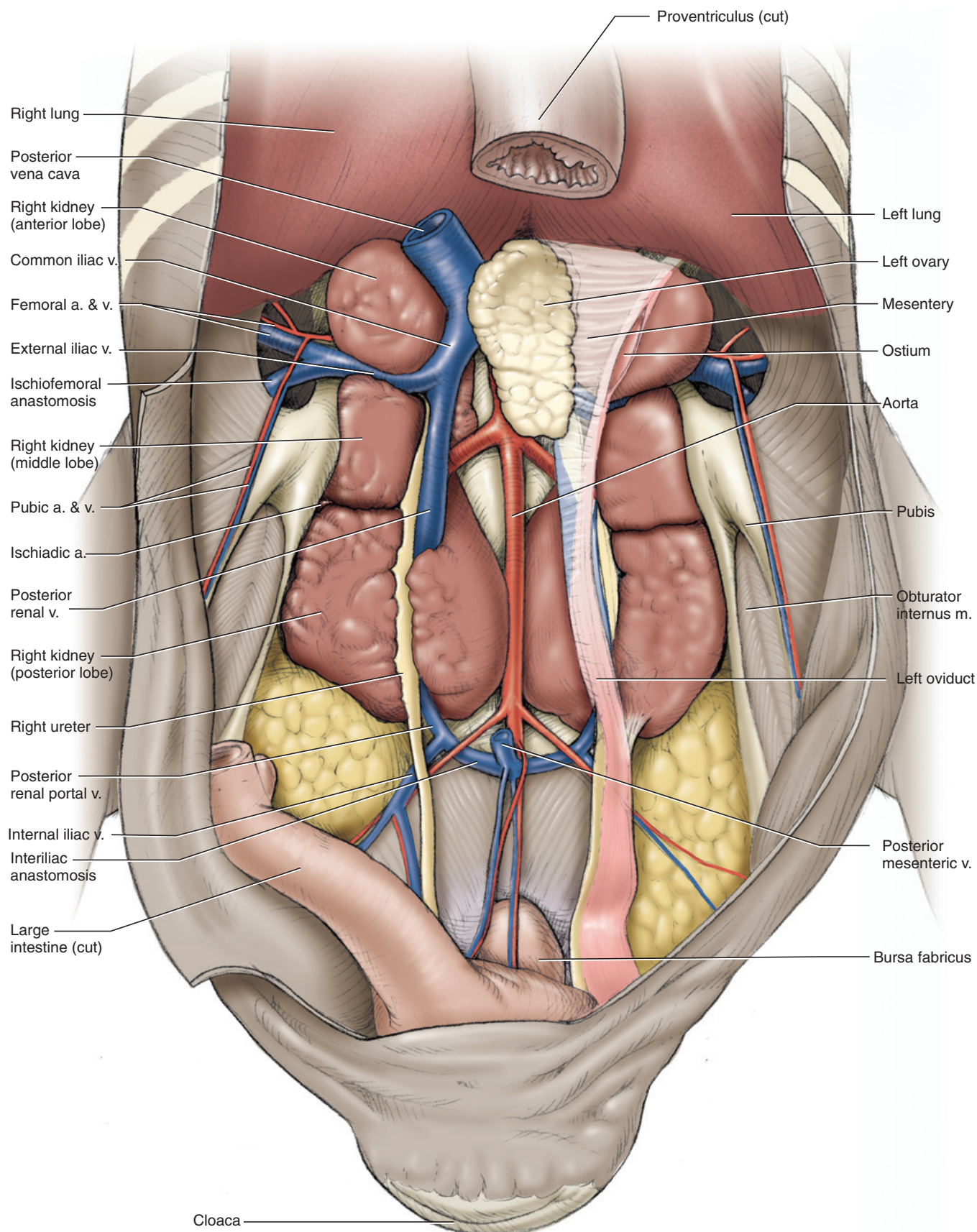


**FIGURE 8.16** Posterior end of the pleuroperitoneal cavity of the male pigeon in ventral view. Gizzard and small intestine removed to show urogenital structures, viscera, and vessels.

so, it receives the **posterior renal vein**, a large vessel that extends posteriorly on the kidney with the ureter and vas deferens in the male and the oviduct (left side only) in the female. The posterior renal vein arises from several branches in the posterior lobe of the kidney and receives a branch from the middle lobe of the kidney.

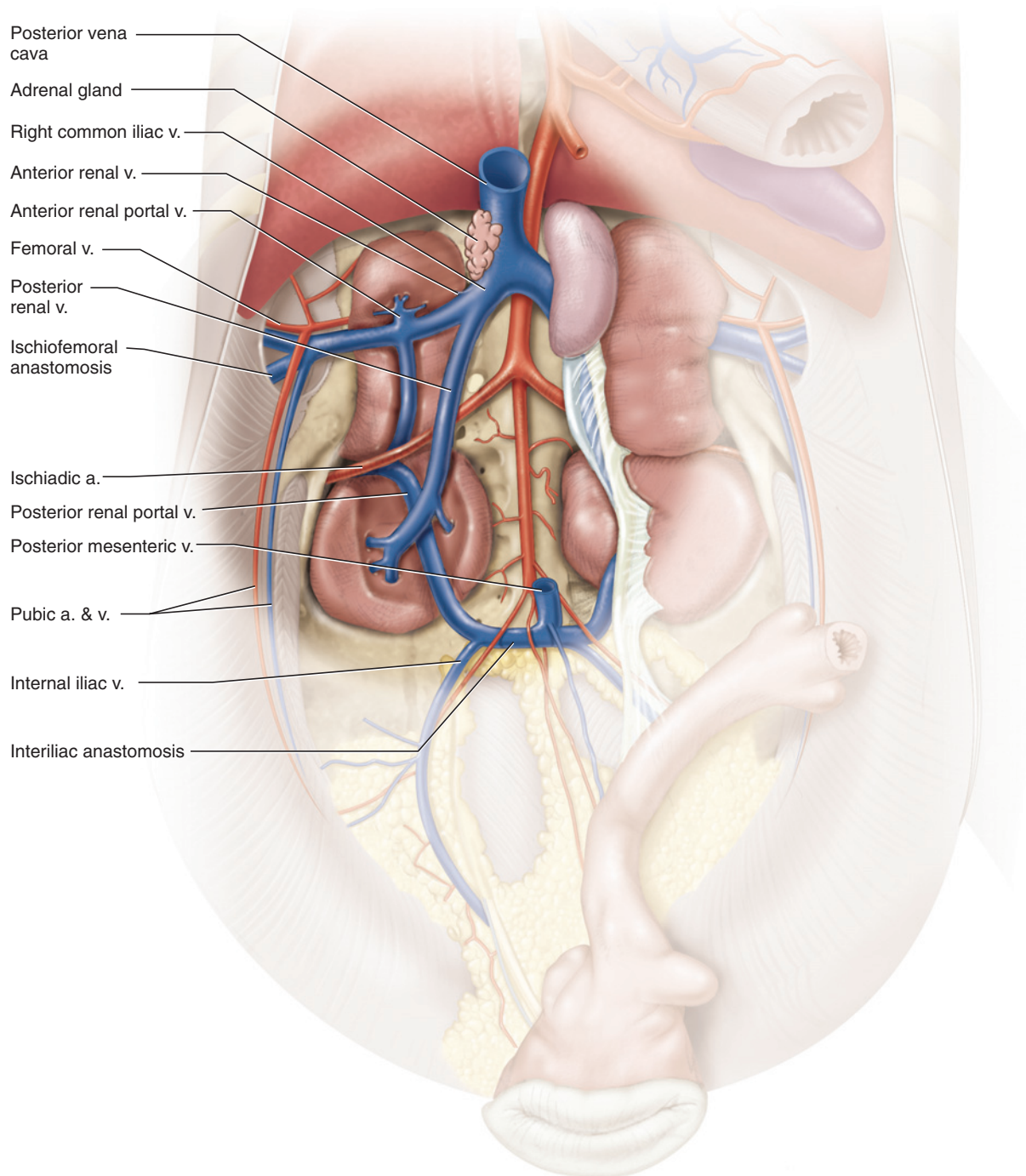
The **posterior renal portal vein** enters the posterior lobe of the kidney. To follow its path, as well as that of many

other veins in this region, kidney tissue must be removed (Figure 8.18). Begin by exposing the posterior portions of the posterior renal vein. Then follow the posterior renal portal vein as it passes anteriorly through the kidney, deep to the posterior renal vein. Between the posterior and middle lobes of the kidney, the renal portal receives the **ischiadic vein**, which is the main vein of the hind limb. The paired **ischiadic arteries** lie ventral to the ischiadic veins and are easily seen. Trace the



**FIGURE 8.17** Posterior end of the pleuroperitoneal cavity of the female pigeon in ventral view. Gizzard and small intestine removed to show urogenital structures, viscera, and vessels.





**FIGURE 8.18** Posterior end of the pleuroperitoneal cavity of the (male) pigeon in ventral view. The right-side kidney has been dissected to reveal the pattern of renal and renal portal veins.

origin of one from the descending aorta. The artery supplies the middle and posterior lobes of the kidney. Follow the ischiadic vein laterally, but do not damage the superficial and narrow **pubic vein** and **artery** lying on the musculature along the pubic bone. The ischiadic vein, accompanied by the ischiadic artery, passes through the ilioischadic foramen (Figure 8.6) as it enters the abdominal cavity from the hind limb.

Continue to follow the posterior renal portal vein. Between the anterior and middle lobes of the kidney, the renal portal vein unites with the external iliac vein to form the common iliac vein. The **anterior renal portal vein** enters almost directly opposite that of the posterior renal portal vein. Follow the external iliac vein laterally to its tributary, the **femoral vein**, which drains most of the anterior part of the thigh. The main vein of the hind



limb is the ischiadic vein, but most of the blood is diverted to the femoral vein by the **ischiofemoral anastomosis**, a large vessel between the ischiadic and femoral veins. It appears as a large branch, larger indeed than the femoral, passing posteriorly deep to musculature. You may follow it by cutting through the musculature. Lastly, note the anterior of the pubic vein, draining the lateral abdominal wall, near the origin of the external iliac. The **external iliac artery** lies deep to the external iliac vein. Carefully probe to find it. It gives rise to the **femoral artery**, supplying the hind limb, and the pubic artery, supplying the lateral abdominal wall. Trace the external iliac artery to its origin from the descending aorta. Further anteriorly, note the **anterior renal artery**, which supplies the anterior and middle lobes of the kidney.

Examine the posterior end of the abdominal cavity. The posterior renal portal vein is formed by the confluence of the narrower **interior iliac vein** and the wider, transversely oriented **interiliac anastomosis**. The posterior mesenteric vein, which was cut during removal of the intestines, arises from the middle of the interiliac anastomosis and passes anteriorly as part of the hepatic portal system. A small branch accompanies the **posterior mesenteric artery** to the posterior end of the large intestine. The narrow **median caudal vein** enters the interiliac anastomosis opposite the origin of the posterior mesenteric vein. The internal iliac vein drains the posterolateral region of the abdominal cavity. The **internal iliac artery** accompanies the internal iliac vein. Beyond the origin of the internal iliac arteries, the descending aorta continues posteriorly as the **median caudal artery**.

### KEY TERMS: BODY CAVITY, VISCERA, AND VESSELS

air sacs  
anterior mesenteric artery  
anterior renal artery  
anterior renal portal vein  
anterior renal vein  
anterior vena cava, right and left

aortic arch  
ascending aorta  
atrium (plur., atria), right and left  
axillary artery  
axillary vein  
basilic vein  
brachial artery

brachial vein  
brachiocephalic artery, right and left  
bronchi  
celiac artery  
colic ceca  
common carotid artery  
common iliac vein, right and left  
duodenum  
esophagus  
external iliac artery  
femoral artery  
femoral vein  
follicles  
gizzard  
heart  
hepatic portal vein  
interiliac anastomosis  
interior iliac vein  
internal carotid artery  
internal iliac artery  
ischiadic arteries  
ischiadic vein  
ischiofemoral anastomosis  
jugular vein  
kidney  
large intestine  
liver  
lungs  
median caudal artery  
median caudal vein  
ostium  
ovary

oviduct  
pancreas  
pancreaticoduodenal artery  
pancreaticoduodenal vein  
pectoral arteries  
pectoral vein  
posterior mesenteric artery  
posterior mesenteric vein  
posterior renal portal vein  
posterior renal vein  
posterior vena cava  
proventriculus  
pubic artery  
pubic vein  
pulmonary artery, right and left  
pulmonary trunk  
pulmonary vein, right and left  
sinus venosus  
small intestine  
spleen  
stomach  
subclavian artery  
subclavian vein  
syrinx  
testes  
ureter  
vas deferens  
ventricle, right and left

# SELECTED REFERENCES

- Ahlberg, P. E. 1999. Something fishy in the family tree. *Nature* 397: 564–565.
- Arnason, U., Gullberg, A., and Janke, A. 2001. Molecular phylogenetics of gnathostomous (jawed) fishes: old bones, new cartilage. *Zoologica Scripta* 30(4): 249–255.
- Arnason, U., Gullberg, A., Janke, A., Joss, J., and Elmerot, C. 2004. Mitogenomic analyses of deep gnathostome divergences: a fish is a fish. *Gene* 333: 61–70.
- Baumel, J. J., King, A. S., Breazile, J. E., Evans, H. E., Vanden Berge, J. C., eds. 1993. *Handbook of Avian Anatomy: Nomina Anatomica Avium*, 2<sup>nd</sup> edition. Publications of the Nuttall Ornithological Club 23, Cambridge, MA. 779 pp.
- Beaster-Jones, L., Horton, A. C., Gibson-Brown, J. J., Holland, N. D., and Holland, L. Z. 2006. The amphioxus T-box gene, *AmphiTbx 15/18/22*, illuminates the origins of chordate segmentation. *Evolution and Development* 8(2): 119–129.
- Chiasson, R. 1966. *Laboratory Anatomy of the Pigeon*. Wm. C. Brown Publishers, Dubuque. 54 pp.
- Chiasson, R. B. 1966. *Laboratory Anatomy of the Perch*. Wm. C. Brown Publishers, Dubuque. 53 pp.
- Chiasson, R. B. and Radke, W. J. 1993. *Laboratory Anatomy of the Vertebrates*. Wm. C. Brown Publishers, Dubuque. 224 pp.
- Crouch, J. E. 1969. *Text-Atlas of Cat Anatomy*. Lea & Febiger, Philadelphia. 399 pp.
- Dawkins, R. 2004. *The Ancestor's Tale: A Pilgrimage to the Dawn of Life*. Weidenfeld and Nicholson, London. 528 pp.
- Delsuc, F., Brinkmann, H., Chourrout, D., and Philippe, H. 2006. Tunicates and not cephalochordates are the closest living relatives of vertebrates. *Nature* 439: 965–968.
- Duncker, H.-R. 1971. The lung air sac system of birds. A contribution to the functional anatomy of the respiratory apparatus. *Adv. Anat. Embryol. Cell Biol.* 45(6): 1–171.
- Duncker, H.-R. 2004. Vertebrate lungs: structure, topography and mechanics. A comparative perspective of the progressive integration of respiratory system, locomotor apparatus and ontogenetic development. *Respiratory Physiology & Neurobiology* 144: 111–124.
- Ecker, A. 1971. *The Anatomy of the Frog*. Translated by Haslam. G. A. Asher & Company, Vaals. 449 pp.
- Fishbeck, D. W. and Sebastiani, A. 2001. *Comparative Anatomy: Manual of Vertebrate Dissection*. Morton Publishing Company, Englewood. 358 pp.
- Gans, C. and Parsons, T. S. 1964. *A Photographic Atlas of Shark Anatomy*. The University of Chicago Press, Chicago. 106 pp.
- Gatesy, S. M. and Dial, K. P. 1993. Tail muscle activity patterns in walking and flying pigeons (*Columba livia*). *Journal of Experimental Biology* 176: 55–76.
- George, J. C. and Berger, A. J. 1966. *Avian Myology*. Academic Press, New York. 500 pp.
- Gilbert, S. G. 1991. *Atlas of General Anatomy*, 2nd edition. Burgess Publishing, Minneapolis. 104 pp.
- Gilbert, S. G. 2000. *Outline of Cat Anatomy with Reference to the Human*. University of Washington Press, Seattle. 90 pp.
- Gilbert, S. G. 1989. *Pictorial Anatomy of the Cat*, revised edition. University of Toronto Press, Toronto. 120 pp.
- Gilbert, S. G. 1973. *Pictorial Anatomy of the Dogfish*. University of Washington Press, Seattle. 59 pp.
- Gilbert, S. G. 1974. *Pictorial Anatomy of the Frog*. University of Washington Press, Seattle. 63 pp.
- Gilbert, S. G. 1973. *Pictorial Anatomy of the Necturus*. University of Washington Press, Seattle. 47 pp.
- Homberger, D. G. and Walker, W. F., Jr. 2004. *Vertebrate Dissection*, 9<sup>th</sup> edition. Brooks Cole, Belmont, CA. 379 pp. + appendices.
- Kardong, K. V. 2002. *Vertebrates: Comparative Anatomy, Function, Evolution*, 3<sup>rd</sup> edition. McGraw-Hill Higher Education, Boston. 762 pp.
- Kardong, K. V. and Zalisko, E. J. 2002. *Comparative Vertebrate Anatomy: A Laboratory Dissection Guide*, 3<sup>rd</sup> edition. McGraw-Hill Higher Education, Boston. 214 pp. + appendix, figures.
- Kent, G. C. and Carr, R. K. 2001. *Comparative Anatomy of the Vertebrates*, 9<sup>th</sup> edition. McGraw-Hill Higher Education, Boston. 524 pp.
- King, A. S. and McLelland, J. eds. 1985. *Form and Function in Birds, Volume 3*. Academic Press, London. 522 pp.
- Laurin, M., Giron-dot, M., and de Ricqlès, A. 2000. Early tetrapod evolution. *Trends in Ecology and Evolution* 15(3): 118–123.
- Liem, K. F., Bemis, W. E., Walker, W. F., Jr., and Grande, L. 2001. *Functional Anatomy of the Vertebrates: An Evolutionary Perspective*, 3<sup>rd</sup> edition. Harcourt College Publishers, Fort Worth. 703 pp. + appendices.

- Maisey, J. G. 2001. Remarks on the inner ear of elasmobranchs and its interpretation from skeletal labyrinth morphology. *Journal of Morphology* 250: 236–264.
- Marinelli, W. and Strenger, A. 1954. *Vergleichende Anatomie und Morphologie der Wirbeltiere*. Verlag Franz Deuticke, Wien. 308 pp.
- Martin, A. 2001. The phylogenetic placement of Chondrichthyes: inferences from analysis of multiple genes and implications for comparative studies. *Genetica* 111: 349–357.
- Nickel, R., Schummer, A., Seiferle, E., Siller, W. G., and Wight, P. A. L. 1977. *Anatomy of the Domestic Birds*. Springer-Verlag, New York. 202 pp.
- Norell, M. A. and Xu, X. 2005. Feathered dinosaurs. *Annual Reviews of Earth and Planetary Science* 33: 277–299.
- O'Connor, P. M. 2004. Pulmonary pneumaticity in the postcranial skeleton of extant Aves: a case study examining Anseriformes. *Journal of Morphology* 261: 141–161.
- Pough, F. H., Janis, C. M., and Heiser, J. B. 2002. *Vertebrate Life*, 6<sup>th</sup> edition. Prentice Hall, Upper Saddle River. 699 pp. + appendices.
- Proctor, N. S. and Lynch, P. J. 1993. *Manual of Ornithology: Avian Structure & Function*. Yale University Press, New Haven. 340 pp.
- Romer, A. S. and Parson, T. S. 1986. *The Vertebrate Body*, 6th edition. Saunders College Publishing, Philadelphia. 679 pp.
- Sisson, S. and Grossman, J. D. 1953. *The Anatomy of the Domestic Animals*, 4<sup>th</sup> edition. W. B. Saunders Company, Philadelphia. 972 pp.
- Stuart, R. R. 1962. *The Anatomy of Necturus maculosus, the Mud Puppy*. Denoyer-Geppert Company, Chicago. 28 pp.
- Stuart, R. R. 1962. *The Anatomy of the Bull Frog*, 5th edition. Denoyer-Geppert Company, Chicago. 30 pp.
- Vargas, A. O. and Fallon, J. F. 2005. Birds have dinosaur wings: the molecular evidence. *Journal of Experimental Zoology (Mol Dev Evol)* 304B: 86–90.
- Wagner, P. G. and Gauthier, J. A. 1999. 1, 2, 3 = 2, 3, 4: a solution to the problem of the homology of the digits of the avian hand. *Proceedings of the National Academy of Sciences* 96: 5111–5116.
- Wake, M. H. 1979. *Hyman's Comparative Vertebrate Anatomy*, 3<sup>rd</sup> edition. The University of Chicago Press, Chicago.
- Waller, G., Dando, M., and Burchett, M. 1996. *Sealife: A Complete Guide to the Marine Environment*. Smithsonian Institution Press, Washington. 504 pp.
- Winchell, C. J., Sullivan, J., Cameron, C. B., Swalla, B. J., and Mallat, J. 2002. Evaluating hypotheses of deuterostome phylogeny and chordate evolution with new LSU and SSU ribosomal DNA data. *Molecular Biology and Evolution* 19(5): 762–776.
- Wischnitzer, S. 1993. *Atlas and Dissection Guide for Comparative Anatomy*, 5th edition. W. H. Freeman and Company, New York. 284 pp. + supplementary figures.
- Zhu, M., Xiaobo, Y., and Janvier, P. 1999. A primitive fossil fish sheds light on the origin of bony fishes. *Nature* 397: 607–610.



# INDEX

## A

- Abdomen, 152
- Abdominal aorta, 201
- Abdominal pores, 37
- Abdominal vein
  - in frog, 121, 130
  - in mudpuppy, 96, 98, 105
  - in shark, 59
- Abdominopelvic cavity, 186–194
- Abducens foramina, 28
- Abducens nerve (CN VI)
  - in cat, 222
  - in shark, 65–66, 74
- Abductor caudae internus (coccygeus muscle), 165
- Abductor cruris caudalis (tenuissimus), 166
- Abductor, defined, 40
- Accessory nerve (CN XI)
  - in cat, 222
  - in shark, 74
- Accessory process, 142
- Accessory urinary duct, 62
- Acetabular bone, 147
- Acetabular fenestra, 233
- Acetabular surface, 33
- Acetabulum
  - in cat, 147
  - in frog, 118
  - in mudpuppy, 92
  - in pigeon, 233
- Achilles tendon (calcaneal tendon), 170
- Acoustic meatus
  - in cat, 138
  - in pigeon, 234
- Acousticolateral area, 73
- Acromiodeltoid muscle, 158
- Acromion process, 145
- Acromiotrapezius, 158
- Actinista, 12, 14
- Actinopterygii, 11, 13, 14, 77
- Adductor, defined, 40
- Adductor femoris, 168
- Adductor longus (adductor femoris longus), 168
- Adductor mandibulae process, 28
- Adductor mandibulae, 41
- Adrenal gland
  - in cat, 204
  - in frog, 125
- Adrenolumbar artery/vein, 204
- Afferent branchial arteries
  - in lamprey, 24
  - in mudpuppy, 105
  - in shark, 47, 51
- Afferent renal vein, 58
- Afferent spiracular artery, 41, 51
- Agnathans, 7, 8, 9, 19
- Air sacs, 241
- Alisphenoid, 135
- Alula (bastard wing), 234
- Alular quills, 234
- Amniota, 15, 16
- Amphibia, 12, 15, 16, 89, 113
- Ampullae of Lorenzini, 37, 63
- Anal fin, 80, 81
- Anal glands, 217
- Angle of rib, 144
- Angular bone
  - in mudpuppy, 90
  - in perch, 79
  - in pigeon, 229
- Angular process, 139
- Angulare, 116
- Annular cartilage
  - in frog, 116
  - in lamprey, 19
- Antebrachium (forearm)
  - in cat, 146, 152
  - in frog, 118
- Anterior auricular artery, 199
- Anterior auricular vein, 200
- Anterior cardinal sinus, 58
- Anterior cardinal vein, 24, 26
- Anterior chamber, of eye, 67
- Anterior commissure, 224
- Anterior cornu, 116
- Anterior cranial fossa, 138
- Anterior, defined, xx
- Anterior dorsal fin
  - in lamprey, 21
  - in perch, 80, 81
  - in shark, 28, 33, 37
- Anterior facial vein. *see* Linguofacial vein
- Anterior intestinal artery, 55
- Anterior intestinal vein, 58
- Anterior lienogastric vein, 58
- Anterior mesenteric artery
  - in cat, 201
  - in pigeon, 246

Anterior mesenteric artery (*continued*)  
 in shark, 55  
 Anterior mesenteric vein, 206  
 Anterior pancreaticoduodenal artery/vein, 205  
 Anterior rectal artery/vein, 207  
 Anterior renal artery, 250  
 Anterior renal portal vein, 249  
 Anterior renal vein, 246  
 Anterior semicircular duct, 67  
 Anterior splenic artery, 206  
 Anterior splenic vein, 205  
 Anterior utriculus, 67  
 Anterior vena cava  
 in cat, 185, 195  
 in frog, 127  
 in pigeon, 243  
 Anterior ventrolateral artery, 52  
 Anterodorsal lateral line nerve, 74  
 Anteroventral lateral line nerve, 74  
 Anticlinal vertebra, 142  
 Antorbital canal (infraorbital canal), 134  
 Antorbital process  
 in mudpuppy, 89  
 in shark, 28  
 Antorbital shelf, 28  
 Anura, 113  
 Anus  
 in cat, 152, 192  
 in lamprey, 21  
 in perch, 82  
 in shark, 37  
 Aorta. *see also* Dorsal aorta; Ventral aorta  
 in cat, 195, 201  
 in pigeon, 242  
 Aortic arch  
 in cat, 195  
 in pigeon, 242  
 Apex of heart, 194  
 Apomorphic traits, 3  
 Aponeurosis, 153  
 Appendicular skeleton, 92  
 Aqueous humor, 67  
 Arachnoid mater, 218  
 Arbor vitae, 224  
 Archinephric duct (Wolffian duct)  
 in frog, 125  
 in lamprey, 22  
 in mudpuppy, 102  
 in perch, 85  
 in shark, 62  
 Arcualia, 20, 23–24  
 Arm. *see* Brachium  
 Arterial system  
 of cat, 195–207  
 of frog, 125–127  
 of lamprey, 24  
 of mudpuppy, 105–107  
 of perch, 86  
 of pigeon, 241–250  
 of shark, 51–55  
 Arteries. *see* Arterial system; *names of specific arteries*

Articular bone  
 in perch, 79  
 in pigeon, 229  
 Articular circumference, of radius, 146  
 Articularis coxae (capsularis), 168  
 Arytenoid cartilage, 183  
 Ascending aorta, 242  
 Ascending colon, 192  
 Ascending pharyngeal artery, 199  
 Ascending ramus of dentary, 139  
 Astragalus (talus; tibiale), 118, 149  
 Atlantal foramen, 141  
 Atlas  
 in cat, 141  
 in frog, 117  
 Atria, of heart  
 in cat, 194  
 in frog, 125  
 in lamprey, 24  
 in mudpuppy, 102  
 in perch, 86  
 in pigeon, 241  
 in shark, 51  
 Auditory meatus  
 in cat, 134  
 in pigeon, 229  
 Auditory nerve. *see* Vestibulocochlear nerve  
 Auditory tube (Eustachian tube)  
 in cat, 138, 183  
 in frog, 120  
 Auricle  
 of atrium, 195  
 of cerebellum, 72  
 Auricular artery, 199  
 Auricular vein, 199  
 Aves, 227  
 Avialae, 227  
 Axial skeleton, 92  
 Axillary artery  
 in cat, 201  
 in pigeon, 242  
 Axillary vein  
 in cat, 163, 201  
 in pigeon, 243  
 Axis, 141  
 Azygos vein, 195

## B

Back. *see* Dorsum  
 Barbs, of feather, 234  
 Basal plate  
 in mudpuppy, 90  
 in shark, 28  
 Basal pterygiophore, 33  
 Basapophysis, 33  
 Base of heart, 194  
 Basibranchial bones, 91  
 Basibranchial cartilages, 28  
 Basicranium, 134  
 Basihyal cartilage, 28  
 Basihyoid bone, 139

Basilic vein, 243  
 Basioccipital bone  
   in cat, 134  
   in pigeon, 229  
 Basipterygium, 80  
 Basipterygoid processes, 229  
 Basisphenoid  
   in cat, 135  
   in pigeon, 229  
 Basitrabecular processes, 28  
 Bastard wing (alula), 234  
 Beak (bill), 229, 234  
 Biceps brachii  
   in cat, 165  
   in pigeon, 238  
 Biceps femoris, 165  
 Biceps propatagialis. *see* Pars propatagialis  
 Biceps slip. *see* Pars propatagialis  
 Bicipital groove, 145  
 Bicipital tuberosity, 146  
 Bile duct  
   in cat, 189, 193–194  
   in mudpuppy, 98  
   in shark, 49  
 Bill (beak), 229, 234  
 Blood vessels. *see* Arterial system; Venous system  
 Body  
   of dentary, 138  
   of ilium, 147  
   of sternum, 231  
   of stomach, 49  
   of uterus, 217  
 Bones. *see* Skeletal system; *names of specific bones*  
 Brachial artery  
   in cat, 165, 201  
   in frog, 127  
   in mudpuppy, 107  
   in pigeon, 242  
   in shark, 47, 51  
 Brachial vein  
   in cat, 165, 201  
   in frog, 128  
   in mudpuppy, 102  
   in pigeon, 243  
   in shark, 59  
 Brachiocephalic artery  
   in cat, 195  
   in pigeon, 242  
 Brachiocephalic vein, 196  
 Brachioradialis, 160  
 Brachium (arm)  
   in cat, 152  
   in frog, 118  
 Brain  
   in cat, 218–224  
   in lamprey, 23  
   in shark, 70–73, 75–76  
 Branchial adductor muscle, 43, 47  
 Branchial arches  
   in perch, 77, 82  
   in shark, 28, 43

Branchial arteries  
   in lamprey, 24  
   in mudpuppy, 105, 107  
   in shark, 47, 51, 52  
 Branchial basket, 19  
 Branchial branches of vagus nerve, 75  
 Branchial musculature, 40–45  
 Branchiomic musculature, 40–43  
 Branchiostegal rays, 83  
 Breast, 234  
 Broad ligament, 217  
 Bronchi  
   in cat, 185  
   in pigeon, 244  
 Buccal papillae, 20  
 Bulbourethral glands, 216  
 Bulbus arteriosus  
   in mudpuppy, 102, 105  
   in perch, 86  
 Bulbus cordis, 125

## C

Calamus, 234  
 Calcaneal tendon, 170  
 Calcaneum (calcaneus), 149  
 Calcaneum (fibulare), 118  
 Canals, of cat skull, 135. *see also names of specific canals*  
 Capitulum, of humerus, 145  
 Capitulum, of rib, 141, 144  
 Capsularis, 168  
 Cardiac vein (coronary vein), 195  
 Cardinal sinus, 58  
 Cardinal veins  
   in lamprey, 24, 26  
   in mudpuppy, 102, 105  
   in shark, 59  
 Cardiovascular system  
   of cat, 194–212  
   of frog, 125–130  
   of lamprey, 24  
   of mudpuppy, 102–107  
   of perch, 86  
   of pigeon, 241, 242–244  
   of shark, 51–59  
 Carina (keel), 231  
 Carnassial tooth, 134  
 Carnivores, 132  
 Carotid arch, 127  
 Carotid artery  
   in cat, 197  
   in frog, 127  
   in mudpuppy, 105, 107  
   in pigeon, 242  
   in shark, 51  
 Carotid body, 127  
 Carpal bones  
   in cat, 147, 149  
   in frog, 118  
   in mudpuppy, 92  
   in pigeon, 232  
 Carpometacarpus, 232



- Carpus, 147
- Cat
  - brain and cranial nerves, 218–225
  - cardiovascular system, 194–212
  - cranial skeleton, 132–140
  - digestive and respiratory systems, 180–194
  - excretory system, 212–214
  - external anatomy, 151–152
  - female reproductive system, 216–218
  - forelimb muscles, 154, 158–165
  - head and trunk muscles, 174–180
  - hind limb muscles, 155–156, 165–173
  - male reproductive system, 214–216
  - postcranial skeleton, 140–151
- Caudal artery
  - in cat, 205
  - in lamprey, 24
  - in mudpuppy, 107
  - in pigeon, 250
  - in shark, 55
- Caudal, defined, xx
- Caudal fin
  - in lamprey, 21
  - in perch, 80, 81
  - in shark, 28, 33, 37
- Caudal ligament, 62
- Caudal peduncle, 81
- Caudal vein
  - in cat, 205
  - in lamprey, 26
  - in mudpuppy, 105
  - in shark, 58
- Caudal vertebrae
  - in cat, 140, 143–144
  - in mudpuppy, 92
  - in perch, 80
  - in pigeon, 229
  - in shark, 33
- Caudata, 89
- Caudate lobe, of liver, 188
- Caudofemoralis. *see* Gluteofemoralis
- Caudolateral process, 231
- Caval fold, 185
- Cecum, 192
- Celiac artery
  - in cat, 201
  - in frog, 127
  - in pigeon, 246
  - in shark, 53
- Celiacomesenteric artery
  - in frog, 127
  - in mudpuppy, 107
- Celom, 47
- Central canal of spinal cord, 76
- Central tendon, 188
- Centrum, of vertebral body
  - in cat, 140
  - in perch, 80
  - in shark, 31
- Cephalic vein, 158, 197
- Cephalochordata, 1, 5, 6
- Ceratobranchial bones, 91
- Ceratobranchial cartilages, 28
- Ceratohyal bone, 91
- Ceratohyal cartilage, 28
- Ceratohyoid bone, 139
- Ceratotrichia, 33
- Cerebellar hemispheres, 222
- Cerebellar peduncles, 224
- Cerebellar ventricle, 76
- Cerebellum
  - in cat, 218
  - in shark, 72
- Cerebral aqueduct
  - in cat, 224
  - in shark, 76
- Cerebral hemispheres
  - in cat, 218
  - in shark, 71
- Cerebral peduncle, 224
- Cerebrum
  - in cat, 218
  - in shark, 71
- Cervical artery, deep, 201
- Cervical vertebrae
  - in cat, 140
  - in mudpuppy, 92
  - in pigeon, 229
- Cervix, of uterus, 217
- Chimaeras, 27
- Choanae
  - in cat, 134, 183
  - in frog, 120
  - in mudpuppy, 95
- Choanata, 12, 14, 15
- Chondrichthyes, 10, 12, 27
- Chondrocranium
  - in lamprey, 19
  - in mudpuppy, 89, 90
  - in shark, 28
- Chordata, 2, 4–5, 6
- Choroid, 66
- Choroid plexus, 72
- Ciliary body, 66
- Circulatory system. *see* Cardiovascular system
- Circumflex artery/vein, 168
- Circumflex iliac artery/vein, 204
- Clades, 1
- Cladogram, 3
- Clasper, 27, 33, 37, 62
- Classification, 1–4
- Clavicle
  - in cat, 145
  - in frog, 118
- Clavobrachialis, 158
- Clavotrapezius, 158
- Claw, 152
- Cleidomastoid muscle, 160
- Cleithrum, 80
- Clitoris, 217
- Cloaca
  - in frog, 119, 125
  - in lamprey, 21
  - in mudpuppy, 94

- in pigeon, 234
- in shark, 37
- Cloacal arteries, 107
- Cloacal gland, 94, 102
- Cloacal papillae, 94, 102
- Cloacal vein, 59
- Coccygeofemoralis. *see* Gluteofemoralis
- Coccygeus muscle, 165
- Cochlea tibiae, 148
- Coelom, 22
- Colic artery, 207
- Colic ceca, 242, 246
- Colic vein, 207
- Collector loop of gills, 51
- Colon. *see also* Large intestine
  - in cat, 192
  - in shark, 49
- Columbia livia*, 227
- Columella
  - in frog, 116, 120
  - in mudpuppy, 90
- Commissural artery (hypobranchial artery), 51
- Common bile duct
  - in cat, 189, 193
  - in mudpuppy, 98
- Common cardinal sinus, 58
- Common cardinal vein, 102
- Common carotid artery
  - in cat, 197
  - in pigeon, 242
- Common iliac arteries, 127
- Common iliac vein
  - in cat, 205
  - in mudpuppy, 105
  - in pigeon, 246
- Condyles
  - of femur, 147
  - of humerus, 145
  - of tibia, 148
- Condylloid canal, 138
- Condylloid process, 139
- Conjunctiva, 63
- Connective tissue, types of, 153
- Constrictor muscles, 41
- Contour feathers, 234
- Conus arteriosus
  - in mudpuppy, 102
  - in shark, 51
- Coracoarcual muscles, 44
- Coracobrachial muscles, 44
- Coracobrachialis muscle, 165
- Coracohyoid muscles, 44
- Coracoid bar, 33
- Coracoid cartilage, 92
- Coracoid process, 144
- Coracomandibular muscles, 44
- Cornea, 66
- Coronary artery
  - in cat, 194–195
  - in shark, 52
- Coronary ligament, 188
- Coronary sulcus, 195

- Coronary vein (cardiac vein), 195
- Coronoid fossa, 145
- Coronoid process
  - in cat, 139, 146
  - in frog, 116
- Corpora cavernosa penis, 216
- Corpora quadrigemina, 222
- Corpus callosum, 218, 224
- Corpus spongiosum penis, 216
- Costal cartilage, 144
- Costal demifacet, 141
- Costal facet, 142
- Costocervical artery/vein, 201
- Costocervical + vertebral trunk, 196
- Coverts, 234
- Coxal bones, 233
- Cranial cavity, 138
- Cranial, defined, xx
- Cranial fossae, 138
- Cranial nerves. *see also* names of specific nerves
  - in cat, 220, 224
  - in shark, 70–71, 72–75
- Cranial skeleton
  - of cat, 132–140
  - of frog, 113–116
  - of mudpuppy, 89–92
  - of perch, 77–79
  - of pigeon, 227–229
  - of shark, 28–30
- Craniata, 1, 5, 6, 7–8
- Cremasteric pouches, 214
- Cribiform plate, 136
- Cricoid cartilage, 183
- Cricothyroid muscle, 183
- Crop, 236
- Crus of penis, 216
- Crus (shank)
  - in cat, 152
  - in frog, 118
- Ctenoid scale, 81
- Cuboid bones, 149
- Cucullaris muscle, 41
- Cuneiform bones, 147, 149
- Cutaneous artery, 127
- Cutaneous vein, 102
- Cyclostome, 19
- Cystic duct
  - in cat, 193
  - in mudpuppy, 98

## D

- Deep cervical artery, 201
- Deep circumflex iliac artery/vein, 204
- Deep femoral artery/vein, 168, 205
- Deep ophthalmic nerve, 64, 65, 74
- Deltoid ridge, 145
- Deltoideus major, 238
- Deltoideus minor, 241
- Deltoideus, 236
- Dens, 141

Dentary bone  
  in cat, 138–139  
  in frog, 116  
  in mudpuppy, 90  
  in perch, 79  
  in pigeon, 229  
Dentary teeth, 96  
Denticles (placoid scales), 35  
Dermal skull, 89  
Descending colon, 192  
Deuterostomata, phylogeny of, 2, 4–7  
Diaphragm, 184, 188  
Diaphysis  
  of femur, 147  
  of fibula, 149  
Diastema, 134  
Diencephalon  
  in cat, 220–222  
  in shark, 71  
Digastric muscle, 178, 180  
Digestive system  
  of cat, 180–184, 188–194  
  of frog, 124–125  
  of lamprey, 22, 23  
  of mudpuppy, 98  
  of perch, 85–86  
  of pigeon, 242  
  of shark, 45–50  
Digitiform gland, 49  
Digitiform gland (rectal gland), 62  
Digits  
  in cat, 147  
  in frog, 118  
Dipnoi, 12, 14  
Distal, defined, xx  
Dogfish shark. *see* Shark  
Dorsal aorta  
  in frog, 127  
  in lamprey, 24  
  in mudpuppy, 105  
  in shark, 51, 52  
Dorsal, defined, xx  
Dorsal fins  
  in lamprey, 21  
  in perch, 80, 81  
  in shark, 28, 33, 37  
Dorsal gastric artery, 55  
Dorsal hyoid constrictor muscles, 41  
Dorsal interarcual muscles, 43  
Dorsal oblique muscle, 64  
Dorsal rectus muscle, 64  
Dorsal superficial constrictor muscles, 41  
Dorsolumbar vein, 130  
Dorsum (back)  
  in cat, 152  
  in pigeon, 234  
Ductus deferens, 213, 214  
Duodenocolic ligament, 192  
Duodenum  
  in cat, 192  
  in frog, 125  
  in mudpuppy, 98

  in perch, 85  
  in pigeon, 246  
  in shark, 49  
Dura mater, 218

## E

Ear  
  in cat, 137  
  middle, 137, 229  
  in pigeon, 229  
  in shark, 67–68  
Echinodermata, 1, 2, 4  
Ectotympanic bone, 137  
Efferent branchial artery  
  in lamprey, 24  
  in mudpuppy, 107  
  in shark, 51, 52  
Efferent ductules, of testis, 62  
Efferent renal vein  
  in mudpuppy, 105  
  in shark, 59  
Efferent spiracular artery, 51  
Elasmobranchii, 10, 11  
Embryonic development, 4–5  
Endolymph, 67  
Endolymphatic duct, 67  
Endolymphatic foramina, 28  
Endolymphatic fossa, 28  
Endolymphatic pores, 37  
Endotympanic bone, 138  
Epaxial musculature, 40  
Epibranchial bones, 91  
Epibranchial cartilages, 28  
Epibranchial musculature, 41  
Epicondyles  
  of femur, 148  
  of humerus, 145  
Epididymis  
  in cat, 214  
  in shark, 62  
Epigastric arteries, 107. *see also* Ventrolateral arteries  
Epiglottal cartilage, 183  
Epiglottis, 183  
Epihyoid bone, 139  
Epimysium, 153  
Epiphyseal foramen, 28  
Epiphysis, 71  
Epiploic foramen, 191  
Episternum, 118  
Epithalamus  
  in cat, 220  
  in shark, 72  
Epitrochlearis, 160  
Epurals, 80  
Esophagus  
  in cat, 183  
  in frog, 120, 125  
  in perch, 85  
  in pigeon, 236, 242  
  in shark, 49  
“Esophagus,” in lamprey, 22, 23



Ethmoid bone, 136  
 Ethmoid foramen, 135  
 Ethmoid plate, 90  
 Eugnathostomata, 9–10  
 Eustachian tube (auditory tube), 120, 138, 183  
 Eutheria, 131–132  
 Excretory system. *see* Urogenital system  
 Exoccipital bones  
   in cat, 134  
   in mudpuppy, 90  
 Expansor secundariorum, 238  
 Extensor digitorum lateralis (peroneus tertius), 171  
 Extensor digitorum longus, 171  
 External acoustic meatus, 234  
 External anatomy  
   of cat, 151–152  
   of frog, 118–120  
   of lamprey, 20–21  
   of mudpuppy, 94–95  
   of perch, 81–82  
   of pigeon, 234–235  
   of shark, 35–38  
 External auditory meatus, 134  
 External carotid artery  
   in cat, 199  
   in frog, 127  
   in mudpuppy, 105, 107  
   in shark, 51  
 External gills, 94  
 External iliac artery  
   in cat, 168, 204  
   in pigeon, 250  
 External iliac vein, 168, 205  
 External jugular vein  
   in cat, 158, 196  
   in frog, 127  
 External nares  
   in cat, 132  
   in frog, 119  
 External oblique, 158  
 External pharyngeal slits, 20  
 External pudendal artery/vein, 168  
 External yolk sac, 63  
 Eye  
   in cat, 152  
   in frog, 119  
   in lamprey, 20  
   in mudpuppy, 94  
   in perch, 81  
   in pigeon, 234  
   in shark, 37, 63–67  
 Eye muscles, 64  
 Eyeball, 63  
 Eyelids. *see* Palpebrae

## F

Facial artery, 199  
 Facial nerve (CN VII)  
   in cat, 180, 222  
   in shark, 74  
 Facial vein, 180, 199

Falciform ligament  
   in cat, 188  
   in frog, 122  
   in mudpuppy, 96  
   in shark, 49  
 Fallopian tube (uterine tube), 216  
 False vocal cords, 184  
 Fascia, 153  
 Fascia lata, 166  
 Fat body, 122  
 Feathers, 234  
*Felis domestica*, 131  
 Female reproductive system  
   of cat, 216–218  
   of frog, 122, 124, 125  
   of mudpuppy, 102  
   of perch, 84  
   of pigeon, 216  
   of shark, 62–63  
 Femoral artery  
   in cat, 168, 205  
   in frog, 127  
   in mudpuppy, 107  
   in pigeon, 250  
   in shark, 55  
 Femoral nerve, 168  
 Femoral vein  
   in cat, 168, 205  
   in frog, 130  
   in pigeon, 249  
   in shark, 59  
 Femur  
   in cat, 147–148, 152  
   in frog, 118  
   in mudpuppy, 92  
   in pigeon, 233  
 Fenestra cochlea (round window), 137  
 Fenestra vestibuli (oval window), 137  
 Fibrous tunic, 66  
 Fibula  
   in cat, 149  
   in frog, 118  
   in mudpuppy, 92  
   in pigeon, 233  
 Fibular facet, 148–149  
 Fibulare, 118  
 Fibularis brevis (peroneus brevis), 171  
 Fibularis longus (peroneus longus), 171  
 Filiform papillae, 181  
 Fimbriae, 216  
 Fin rays  
   in lamprey, 21  
   in perch, 80  
 Fin spine, 33  
 Fins  
   in lamprey, 21  
   in mudpuppy, 94  
   in perch, 80, 81–82  
   in shark, 28, 33, 37  
 Fishes, phylogeny of, 9–12, 77  
 Flexor digitorum longus, 173  
 Flexor digitorum superficialis (plantaris), 173

Flocculonodular lobe, 222  
 Folia, of metencephalon, 222  
 Foliate papillae, 181  
 Follicles, ovarian, 102, 246  
 Foramen magnum  
   in cat, 134  
   in frog, 116  
   in mudpuppy, 90  
   in pigeon, 229  
   in shark, 28  
 Foramen of Monro, 72, 76  
 Foramen ovale  
   in cat, 136  
   in frog, 116  
 Foramen rotundum, 136  
 Foramina, of cat skull, 135. *see also names of specific foramina*  
 Forearm. *see* Antebrachium  
 Forelimb  
   in cat, 144–147, 154, 158–165  
   in frog, 118  
   in mudpuppy, 92, 94  
   in pigeon, 231–232, 234  
 Fornix of corpus callosum, 224  
 Fourth ventricle, 72, 76  
 Fovea, 146  
 Frog  
   cardiovascular system, 125–130  
   external anatomy, 118–120  
   mouth, oral cavity, and pharynx, 120  
   pleuroperitoneal cavity, viscera, and urogenital system, 120–125  
   postcranial skeleton, 117–118  
   skull, mandible, hyoid apparatus, 113–117  
 Frontal bones  
   in cat, 134  
   in mudpuppy, 89  
   in perch, 77  
   in pigeon, 229  
 Frontal, defined, xxi  
 Frontoparietal bones, 114  
 Fungiform papillae, 181  
 Furcula, 231

## G

Gall bladder  
   in cat, 188  
   in frog, 122  
   in mudpuppy, 98  
   in perch, 83  
   in shark, 49  
 Gastric artery  
   in cat, 205  
   in mudpuppy, 107  
   in shark, 53, 55  
 Gastric vein  
   in cat, 205  
   in frog, 130  
   in shark, 56  
 Gastrocnemius, 170  
 Gastroduodenal artery/vein, 205

Gastroepiploic artery/vein, 205, 206  
 Gastrohepatic artery, 53  
 Gastrohepatic ligament, 98  
 Gastrohepatoduodenal ligament (lesser omentum), 49  
 Gastrosplenic artery, 55  
 Gastrosplenic ligament  
   in cat, 191  
   in mudpuppy, 98  
   in shark, 49  
 Gastrosplenic vein  
   in cat, 205  
   in mudpuppy, 98, 105  
 Gemellus caudalis (gemellus inferior), 168  
 Gemellus cranialis (gemellus superior), 170  
 Geniculate ganglion, 74  
 Genioglossus muscle, 179  
 Geniohyoid muscle, 179  
 Genital ducts, 22  
 Genital pore, 21, 22  
 Genu of corpus callosum, 224  
 Gill filaments, 82  
 Gill lamellae, 37, 46  
 Gill rakers  
   in perch, 82  
   in shark, 46  
 Gill rays, 47  
 Gills  
   in mudpuppy, 94  
   in perch, 82  
   in shark, 46  
 Gizzard, 242, 246  
 Glans penis, 216  
 Glenoid fossa  
   in cat, 144  
   in frog, 118  
   in mudpuppy, 92  
   in pigeon, 231  
 Glenoid surface, 33  
 Glossopharyngeal foramen, 28  
 Glossopharyngeal nerve (CN IX)  
   in cat, 222  
   in shark, 75  
 Glottis  
   in cat, 183  
   in frog, 120  
   in mudpuppy, 96  
 Gluteobiceps. *see* Gluteofemoralis  
 Gluteofemoralis (caudofemoralis, coccygeofemoralis, gluteobiceps), 165  
 Gluteus medius, 165  
 Gluteus profundus (gluteus minimus), 168  
 Gluteus superficialis (gluteus maximus), 165  
 Gnathostomata, 7–8, 9–10  
 Gonads. *see* Ovary; Testis  
 Gracilis, 167  
 Grades, 4  
 Greater cornua of hyoid apparatus, 139  
 Greater curvature of stomach, 188  
 Greater omentum. *see also* Mesogaster  
   in cat, 189, 191  
   in mudpuppy, 98  
 Greater trochanter, of femur, 147

Greater tuberosity, of humerus, 145  
Gubernaculum, 214  
Gyrus, 218

## H

Habenula, 221  
Habenular commissure, 221, 224  
Hagfishes, 19  
Hagfishes, phylogeny, 7–8  
Hair, 151  
Hallux, 233  
Hamulus, 135  
Hard palate, 134  
Head  
    of cat, 151, 175–176, 178–179  
    of femur, 147  
    of fibula, 149  
    of humerus, 145  
    of lamprey, 20  
    of mudpuppy, 94  
    of perch, 77, 81  
    of radius, 146  
    of shark, 37, 40–42  
Head kidney, 83–84  
Heart  
    in cat, 194–195  
    in frog, 125  
    in lamprey, 24  
    in mudpuppy, 102  
    in perch, 83, 86  
    in pigeon, 241  
    in shark, 51  
Hemal arches  
    in cat, 143  
    in mudpuppy, 92  
    in shark, 33  
Hemal canal, 33  
Hemal plate, 33  
Hemal processes, 144  
Hemal spine, 33, 80  
Hemibranch, 46  
Hemichordata, 1, 2, 7  
Hepatic artery  
    in cat, 189, 205  
    in shark, 53  
Hepatic ducts  
    in cat, 193  
    in mudpuppy, 98  
Hepatic portal system  
    in cat, 202, 205  
    in shark, 55–58  
Hepatic portal vein  
    in cat, 205  
    in frog, 130  
    in lamprey, 24  
    in mudpuppy, 98, 105  
    in pigeon, 246  
    in shark, 56  
Hepatic sinus  
    in mudpuppy, 102  
    in shark, 58

Hepatic veins  
    in cat, 201  
    in frog, 129  
    in mudpuppy, 105  
    in shark, 58  
Hepatocavopulmonary ligament, 98  
Hepatoduodenal ligament  
    in cat, 189  
    in mudpuppy, 98  
    in shark, 49  
Hepatogastric ligament  
    in cat, 189  
    in shark, 49  
Hepatorenal ligament, 193  
Herbivores, 131–132  
Hilus of kidney, 212  
Hind limb  
    in cat, 147–150, 155–156, 165–173  
    in mudpuppy, 92, 94  
    in pigeon, 233  
Holobranch  
    in perch, 83  
    in shark, 46  
Homoplastic traits, 3–4  
Hook of clasper, 33  
Horizontal skeletogenous septum, 40  
Horny teeth, 20–21  
Humerotriceps, 238  
Humerus  
    in cat, 145  
    in frog, 118  
    in mudpuppy, 92  
    in pigeon, 231  
Hyoglossus muscle, 179  
Hyoid apparatus  
    in cat, 139  
    in frog, 116  
    in mudpuppy, 89, 91  
    in pigeon, 229  
Hyoid arch  
    in mudpuppy, 96  
    in shark, 28, 43  
Hyoid constrictor muscles, 41  
Hyoidean sinus, 58  
Hyomandibular bone, 79  
Hyomandibular branch of facial nerve, 74  
Hyomandibular cartilage, 28  
Hyomandibular foramen, 28  
Hyomandibular nerve, 41  
Hypaxial musculature, 40  
Hypobranchial artery, 51  
Hypobranchial cartilages, 28  
Hypobranchial musculature, 43–45  
Hypobranchial nerve, 75  
Hypogastric artery  
    in frog, 127  
    in mudpuppy, 107  
Hypoglossal canal, 138  
Hypoglossal nerve (CN XII)  
    in cat, 199, 222  
    in shark, 74, 75  
Hypohyal bone, 91



Hypophyseal pouch, 24  
Hypophysis  
  in cat, 220  
  in shark, 76  
Hypotarsus, 233  
Hypothalamus  
  in cat, 220  
  in shark, 72  
Hypurals, 80

## I

Ileum, 192  
Iliac arteries  
  in cat, 168, 204–205  
  in frog, 127  
  in mudpuppy, 107  
  in pigeon, 250  
  in shark, 55  
Iliac artery, deep circumflex, 204  
Iliac crest  
  in cat, 147  
  in frog, 118  
  in pigeon, 233  
Iliac process, 33  
Iliac veins  
  in cat, 168, 204–205  
  deep circumflex, 204  
  in frog, 130  
  in mudpuppy, 105  
  in pigeon, 246, 250  
Iliocostalis muscle, 178  
Ilioischadic foramen, 233  
Iliopsoas muscle, 168  
Ilium  
  in cat, 147  
  in frog, 118  
  in mudpuppy, 92  
  in pigeon, 233  
Incisor teeth, 134  
Incus, 137  
Inferior colliculi, 222  
Inferior jugular vein  
  in lamprey, 24  
  in shark, 58  
Infraorbital canal, 134  
Infraorbital nerve, 65, 74  
Infraspinatus muscle, 163  
Infraspinous fossa, 145  
Infundibulum  
  of hypothalamus, 76, 220  
  of uterine tube, 216  
Inguinal canal, 216  
Innominate bones, 147  
Innominate vein, 127  
Integument  
  in frog, 119  
  in shark, 35  
Interarcual muscles, 43  
Interbranchial muscle, 43, 47  
Interbranchial septa, 37, 43, 46  
Intercalary plates, 33

Intercondyloid fossa, 148  
Intercostal arteries, 195, 197, 201  
Intercostal muscles, 174  
Intercostal veins, 195  
Interhyoideus muscle, 42  
Interiliac anastomosis, 250  
Interior iliac vein, 250  
Intermandibularis muscle, 41  
Intermediate mass, 221  
Internal acoustic meatus, 138  
Internal carotid artery  
  in cat, 199  
  in frog, 127  
  in mudpuppy, 107  
  in pigeon, 242  
  in shark, 51  
Internal carotid ligament, 199  
Internal choanae  
  in cat, 183  
  in frog, 120  
  in mudpuppy, 95  
Internal iliac artery  
  in cat, 204  
  in pigeon, 250  
Internal iliac vein, 205  
Internal jugular vein  
  in cat, 196  
  in frog, 127  
Internal mammary artery, 196, 201  
Internal mammary vein, 195  
Internal oblique, 174  
Internal spermatic artery/vein, 204  
Internal yolk sac, 63  
Interneural arch (intercalary plates), 33  
Interoperculum, 77  
Interosseus crest, 146  
Interparietal bone, 134  
Interpterygoid vacuities, 114  
Intersegmental arteries, 55  
Intersegmental veins, 59  
Interventricular foramen (foramen of Monro), 72, 76  
Interventricular foramen, 224  
Interventricular groove, 195  
Intervertebral foramen, 140  
Intestinal artery, 55  
Intestinal vein  
  in frog, 130  
  in shark, 58  
Intestines  
  in cat, 189, 192  
  in frog, 125  
  in lamprey, 22  
  in mudpuppy, 98  
  in perch, 83  
  in pigeon, 242, 246  
Invagination, 5  
Iris, 66  
Ischiac cartilage, 92  
Ischiadic artery, 247  
Ischiadic nerve, 168  
Ischiadic vein, 247

Ischial tuberosity, 147  
 Ischiofemoral anastomosis, 250  
 Ischiopubic fenestra, 233  
 Ischium  
   in cat, 147  
   in frog, 118  
   in mudpuppy, 92  
   in pigeon, 233  
 Islets of Langerhans, 194  
 Isthmus of pancreas, 49

## J

Jejunum, 192  
 Jugal bone, 229  
 Jugular foramen, 138  
 Jugular process, 134  
 Jugular vein  
   in cat, 158, 178, 196, 197  
   in frog, 127  
   in lamprey, 24  
   in mudpuppy, 102  
   in pigeon, 243  
   in shark, 58

## K

Keel (carina), 231  
 Kidney  
   in cat, 192, 212, 214  
   in frog, 125, 127  
   in lamprey, 22  
   in mudpuppy, 102  
   in perch, 84, 86  
   in pigeon, 246  
   in shark, 49, 59, 62

## L

Labia (lips)  
   in cat, 151, 181  
   in mudpuppy, 94  
 Labial cartilage, 28  
 Labial fold, 37  
 Labial pocket, 37  
 Lacrimal bone  
   in cat, 134  
   in perch, 79  
 Lacrimal canal, 134  
 Lagenae, 68  
 Lamina quadrigemina, 222, 224  
 Lamina terminalis, 224  
 Lamina, vertebral, 140  
 Lamprey  
   external anatomy, 20–21  
   phylogeny, 7–8  
   pleuroperitoneal cavity and viscera, 21–22  
   sagittal section, 22–26  
   skeletal system, 19–20  
 Large intestine. *see also* Colon  
   in cat, 192  
   in frog, 125

  in mudpuppy, 98  
   in pigeon, 242  
 Laryngeal prominence, 120  
 Laryngopharynx, 182  
 Lateral abdominal vein, 59  
 Lateral circumflex artery/vein, 168  
 Lateral condyle  
   of femur, 147  
   of tibia, 148  
 Lateral, defined, xx  
 Lateral epicondyle, of femur, 148  
 Lateral interarcual muscles, 43  
 Lateral ligaments, 189  
 Lateral line, 81  
 Lateral line canal, 37, 63  
 Lateral line nerves, 74  
 Lateral line system  
   in lamprey, 21  
   in shark, 37, 63  
 Lateral malleolus, 149  
 Lateral olfactory stria, 220  
 Lateral rectus muscle, 64  
 Lateral semicircular duct, 67  
 Lateral vein, 105  
 Lateral ventricles  
   in cat, 224  
   in shark, 72, 76  
 Latissimus dorsi  
   in cat, 158  
   in pigeon, 241  
 Left colic artery/vein, 207  
 Left gastric artery/vein, 205  
 Lens, 66  
 Lesser cornua of hyoid apparatus, 139  
 Lesser curvature of stomach, 188  
 Lesser omentum, 189. *see also* Gastrohepatoduodenal ligament  
 Lesser peritoneal cavity, 191  
 Lesser trochanter, of femur, 147  
 Lesser tuberosity, of humerus, 145  
 Levator hyomandibulae muscle, 40  
 Levator palatoquadrati muscle, 40  
 Levator scapulae ventralis, 158  
 Leydig's gland, 62  
 Lienogastric ligament. *see* Gastrosplenic ligament  
 Lienogastric vein, 58  
 Lienomesenteric vein, 56  
 Ligamentum arteriosum, 195  
 Linea alba, 40  
 Linea aspera, 147  
 Lingual artery, 199  
 Lingual cartilage, 19, 23  
 Lingual frenulum, 181  
 Lingual nerve, 180  
 Lingual vein, 102, 199  
 Lingualis proprius, 179  
 Linguofacial vein (anterior facial vein), 180, 199  
 Lips. *see* Labia  
 Liver  
   in cat, 188  
   in frog, 122  
   in lamprey, 22

Liver (*continued*)  
 in mudpuppy, 96  
 in perch, 83  
 in pigeon, 241, 242  
 in shark, 47, 49  
 Long tendon, 236  
 Longissimus capitis, 178  
 Longissimus dorsi, 178  
 Longitudinal cerebral fissure, 218  
 Longus colli, 174  
 Loose connective tissue, 153  
 Lumbar vertebrae  
 in cat, 140, 142  
 in pigeon, 229  
 Lumbodorsal fascia, 158  
 Lung  
 in cat, 184, 185–186  
 in frog, 120, 125  
 in mudpuppy, 98  
 in pigeon, 241  
 Lymph nodes, 180

## M

Magnum, 147  
 Malar (zygomatic bone), 134, 138  
 Male reproductive system  
 of cat, 214–216  
 of frog, 122, 125  
 of mudpuppy, 102  
 of perch, 84–85  
 of pigeon, 216  
 of shark, 62  
 Malleus, 137  
 Mammalia, 15, 16, 17, 131  
 Mammary artery, 196, 201  
 Mammary glands, 217  
 Mammary vein, 195  
 Mamillary body, 220, 224  
 Mamillary processes, 142  
 Mandible  
 in cat, 138–139  
 in frog, 116  
 in mudpuppy, 89, 90  
 in perch, 81  
 in pigeon, 229  
 Mandibular arch  
 in mudpuppy, 96  
 in shark, 28, 43  
 Mandibular branch of trigeminal nerve, 74  
 Mandibular cartilage. *see* Meckel's cartilage  
 Mandibular duct, 180  
 Mandibular foramen  
 in cat, 139  
 in pigeon, 229  
 Mandibular fossa, 136  
 Mandibular gland, 158, 180  
 Mandibular nerve, 66  
 Mandibular symphysis, 138  
 Manubrium, 144  
 Manus  
 in cat, 147, 152

in frog, 118, 119  
 Massa intermedia, 224  
 Masseter muscle, 180  
 Masseteric fossa, 139  
 Mastoid bone, 136, 137  
 Mastoid process, 137  
 Maxilla  
 in cat, 134  
 in pigeon, 229  
 in frog, 114  
 in perch, 79, 81  
 Maxillae, 229  
 Maxillary artery, 199  
 Maxillary branch of trigeminal nerve, 74  
 Maxillary groove, 120  
 Maxillary teeth, 114, 120  
 Maxillary vein (posterior facial vein), 180, 199  
 Meckel's cartilage  
 in frog, 116  
 in mudpuppy, 90  
 in shark, 28  
 Medial condyle  
 of femur, 147  
 of tibia, 148  
 Medial, defined, xx  
 Medial epicondyle, of femur, 148  
 Medial malleolus, 149  
 Medial olfactory stria, 220  
 Medial rectus muscle, 64  
 Median caudal artery/vein, 250  
 Median ligament  
 in cat, 189  
 in mudpuppy, 98  
 Median sacral artery/vein, 205  
 Mediastinal septum, 185  
 Mediastinum, 185  
 Medulla oblongata  
 in cat, 222  
 in shark, 72  
 Medullary velum, 222, 224  
 Membranous labyrinth, 67  
 Meninges, 218  
 Mental foramina, 138  
 Mentomeckalian, 116  
 Mesencephalon  
 in cat, 222  
 in shark, 71  
 Mesenteric arteries  
 in cat, 201, 204, 207  
 in frog, 127  
 in mudpuppy, 107  
 in pigeon, 246, 250  
 in shark, 55  
 Mesenteric lymph nodes, 193  
 Mesenteric veins  
 in cat, 206, 207  
 in mudpuppy, 105  
 in pigeon, 246  
 Mesentery  
 in cat, 193  
 in mudpuppy, 98  
 in shark, 49



Mesethmoid bone, 136, 229  
 Mesocolon, 192  
 Mesoduodenum, 192  
 Mesogaster (greater omentum), 49  
 Mesometrium, 217  
 Mesopterygium, 33  
 Mesorchium  
   in cat, 214  
   in frog, 125  
   in mudpuppy, 102  
   in shark, 62  
 Mesorectum  
   in cat, 192  
   in mudpuppy, 98  
   in shark, 49  
 Mesosalpinx, 217  
 Mesotubarium  
   in mudpuppy, 102  
   in shark, 62  
 Mesovarium  
   in cat, 217  
   in frog, 124  
   in mudpuppy, 102  
   in shark, 62  
 Metacarpal bones  
   in cat, 147  
   in frog, 118  
   in mudpuppy, 92  
   in pigeon, 232  
 Metacarpus, 147  
 Metacromion process, 145  
 Metapterygium, 33  
 Metapterygoid bone, 79  
 Metatarsal bones  
   in cat, 149  
   in frog, 118  
   in mudpuppy, 92  
   in pigeon, 233  
 Metatheria, 131  
 Metencephalon  
   in cat, 222  
   in shark, 71  
 Middle colic artery, 207  
 Middle cranial fossa, 138  
 Middle ear  
   in cat, 137  
   in pigeon, 229  
 Middle lateral line nerve, 75  
 Monophyletic groups, 1, 3  
 Monotremata, 131  
 Mouth  
   of cat, 152, 181  
   of frog, 120  
   of lamprey, 21  
   of mudpuppy, 94, 95–96  
   of perch, 81, 82  
   of shark, 37, 46  
 Mudpuppy  
   cardiovascular system, 102–107  
   external anatomy, 94–95  
   mouth, oral cavity, and pharynx, 94, 95–96  
   pleuroperitoneal cavity and viscera, 96–98

  skeletal system, 89–94  
   urogenital system, 98–102  
 Multifidus muscle, 178  
 Musculature. *see also names of specific muscles*  
   of cat, 153–180  
   of eye, 64  
   of forelimb, in cat, 154, 158–165  
   of head and trunk, in cat, 174–180  
   of hind limb, in cat, 155–156, 165–173  
   of lamprey, 23  
   of pigeon, 236–240  
   of shark, 39–45  
 Musculocutaneous vein, 121, 128  
 Myelencephalon  
   in cat, 222  
   in shark, 71  
 Mylohyoid muscle, 178  
 Myomeres  
   in lamprey, 21  
   in shark, 40  
 Myosepta  
   in lamprey, 21  
   in shark, 40  
  
**N**  
 Nares (nostrils)  
   in cat, 132, 152  
   in frog, 119  
   in lamprey, 21  
   in mudpuppy, 94  
   in perch, 81  
   in pigeon, 234  
   in shark, 28, 37  
 Nasal aperture, 132  
 Nasal bones  
   in cat, 134  
   in frog, 114  
   in perch, 79  
   in pigeon, 229  
 Nasal capsules, 28  
 Nasopharynx, 182  
 Navicular bone, 149  
 Neck  
   in cat, 151  
   in mudpuppy, 94  
   in pigeon, 234  
*Necturus maculosus*, 89  
 Nerves. *see names of specific nerves*  
 Nervous system. *see also* Brain; Cranial nerves; Spinal  
   nerves  
   of cat, 218–225  
   of lamprey, 23–24  
   of shark, 70–76  
 Neural arch  
   in cat, 140  
   in mudpuppy, 92  
   in shark, 33  
 Neural canal  
   in cat, 140  
   in mudpuppy, 92  
   in shark, 33

Neural crest, 8  
Neural plate, 31  
Neural process, 92  
Neural spine  
  in cat, 140  
  in perch, 80  
  in shark, 31  
Neurogenic placodes, 8  
Nictitating membrane  
  in cat, 152  
  in frog, 119  
Nidamental gland, 63  
Nose, 63  
Nostrils. *see* Nares  
Notochord, 5, 20, 23

## O

Obturator foramen  
  in cat, 147  
  in mudpuppy, 92  
  in pigeon, 233  
Obturatorius externus, 170  
Obturatorius internus, 165  
Occipital artery, 199  
Occipital bone  
  in cat, 134  
  in frog, 116  
  in pigeon, 229  
Occipital condyle  
  in cat, 134  
  in frog, 116  
  in mudpuppy, 90  
  in pigeon, 229  
  in shark, 28  
Occipital nerve, 75  
Occipitovertebral artery, 127  
Octaval nerve. *see* Vestibulocochlear nerve  
Oculomotor foramina, 28  
Oculomotor nerve (CN III)  
  in cat, 222  
  in shark, 65, 74  
Olecranon, 146  
Olecranon fossa, 145  
Olecranon process, 231  
Olfactory bulbs  
  in cat, 218  
  in shark, 71  
Olfactory nerve (CN I), 74  
Olfactory sac  
  in lamprey, 24  
  in shark, 37, 63  
Olfactory stria, 220  
Olfactory tract  
  in cat, 220  
  in shark, 71  
Omental bursa, 189, 191  
Omentum, greater. *see also* Mesogaster  
  in cat, 189, 191  
  in mudpuppy, 98  
Omentum, lesser, 189. *see also* Gastrohepatoduodenal  
  ligament

Omosternum, 118  
Operculum  
  in perch, 77  
  in pigeon, 234  
Ophthalmic nerve  
  deep, 65, 74  
  superficial, 63–64, 65  
Opisthotic bones, 89  
Optic canal, 136  
Optic chiasma  
  in cat, 220, 224  
  in shark, 76  
Optic foramen, 28  
Optic lobes, 72  
Optic nerve (CN II)  
  in cat, 220  
  in shark, 64, 74  
Optic pedicle, 28, 64  
Optic ventricle, 76  
Oral cavity  
  in cat, 180–181  
  in frog, 120  
  in lamprey, 23  
  in mudpuppy, 95–96  
  in perch, 82–83  
  in shark, 46  
Oral cecum, 23  
Oral funnel, 19, 20  
Oral papillae, 181  
Orbit  
  in cat, 132  
  in frog, 114  
  in perch, 77  
  in pigeon, 229  
  in shark, 28, 63  
Orbital fissure, 136  
Orbital process, 28  
Orbital sinus, 58  
Orbitosphenoid bone, 135  
Oropharynx, 182  
Os penis, 216  
Osteichthyes, 11, 13  
Ostium  
  in cat, 216  
  in frog, 125  
  in mudpuppy, 102  
  in pigeon, 246  
Ostium tubae  
  in cat, 216  
  in shark, 62  
Otic capsules  
  in mudpuppy, 89, 90  
  in shark, 28  
Otic lateral line nerve, 74  
Oval window, 137  
Ovarian artery  
  in cat, 204  
  in mudpuppy, 107  
  in shark, 53  
Ovarian duct, 84  
Ovarian follicles, 102, 246  
Ovarian ligament, 216

Ovarian vein  
in cat, 204  
in frog, 129  
in mudpuppy, 105

Ovary  
in cat, 216  
in frog, 122  
in lamprey, 22  
in mudpuppy, 102  
in perch, 84  
in pigeon, 246  
in shark, 49, 62

Oviduct  
in frog, 124  
in mudpuppy, 102  
in pigeon, 246  
in shark, 62

Ovisac, 125

## P

Palatal rugae, 181  
Palatal teeth, 82  
Palate, 134, 182  
Palatine bones  
in cat, 134  
in frog, 114  
in pigeon, 229  
Palatine branch of facial nerve, 74  
Palatine canal, 134  
Palatine fissure, 134  
Palatine tonsils, 181  
Palatoglossal arches, 181  
Palatoquadrate cartilages, 28  
Palpebrae (eyelids), 152  
Pampiniform plexus, 216  
Pancreas  
in cat, 191, 192, 193–194  
in frog, 125  
in mudpuppy, 98  
in perch, 86  
in pigeon, 246  
in shark, 49  
Pancreatic duct, 194  
Pancreaticoduodenal artery/vein  
in cat, 205, 207  
in pigeon, 246  
Pancreaticomesenteric artery, 53  
Pancreaticomesenteric vein, 56  
Papillae  
buccal, 20  
cloacal, 94, 102  
of esophagus, 49  
of oral cavity, 181  
remigeal, 232  
renal, 214  
urinary, 37, 63  
urogenital, 21, 37, 62  
Parachordal plate, 90  
Parasagittal, defined, xxi  
Parasphenoid bone  
in frog, 116

in mudpuppy, 90  
in pigeon, 229  
Parietal bones  
in cat, 134  
in mudpuppy, 89  
in pigeon, 229  
Parietal pericardium  
in cat, 186  
in mudpuppy, 102  
in shark, 51  
Parietal peritoneum  
in cat, 187  
in perch, 83  
in shark, 47  
Parietal pleura, 185  
Parietal tunica vaginalis, 214  
Paroccipital process, 229  
Parotid duct, 180  
Parotid gland, 158, 180  
Pars propatagialis (biceps slip, biceps propatagialis, patagial accessory), 236, 238  
Patagial accessory. *see* Pars propatagialis  
Patella  
in cat, 148  
in pigeon, 233  
Patellar trochlea, 148  
Pectineus muscle, 168  
Pectoantebrachialis muscle, 160  
Pectoral abductor muscle, 40  
Pectoral adductor muscle, 40  
Pectoral arteries, 241  
Pectoral fins  
in perch, 81  
in shark, 28, 33, 37  
Pectoral girdle  
in frog, 117–118  
in mudpuppy, 92  
in perch, 80  
in pigeon, 231  
in shark, 28, 33  
Pectoral limb. *see* Forelimb  
Pectoral ridge, 145  
Pectoral vein, 241, 243  
Pectoralis major, 160  
Pectoralis minor, 160  
Pectoralis, 236  
Pedicle, vertebral, 140  
Pelvic canal, 216  
Pelvic fins  
in perch, 82  
in shark, 28, 33, 37  
Pelvic girdle  
in frog, 117, 118  
in mudpuppy, 92  
in perch, 80  
in pigeon, 233  
in shark, 28, 33  
Pelvic limb. *see* Hind limb  
Pelvic vein  
in frog, 130  
in mudpuppy, 105



- Pelvis
  - in cat, 147, 152
  - in frog, 118
- Penis, 152, 214, 216
- Perca flavens*, 77
- Perch
  - external anatomy, 81–82
  - mouth, oral cavity, and pharynx, 82–83
  - pleuroperitoneal cavity and viscera, 83–87
  - skeleton, 77–80
- Pericardial artery, 52
- Pericardial cartilage, 19
- Pericardial cavity
  - in cat, 186, 194
  - in frog, 125
  - in mudpuppy, 102
  - in shark, 47
- Pericardioperitoneal canal, 51
- Pericardium
  - in cat, 186, 194
  - in frog, 122, 125
  - in mudpuppy, 102
  - in shark, 51
- Perilymphatic foramina, 28
- Peritoneal cavity, 191
- Peritoneum
  - in cat, 187
  - in perch, 83
  - in shark, 47
- Peroneus brevis, 171
- Peroneus longus, 171
- Peroneus tertius, 171
- Pes
  - in cat, 149–150, 152
  - in frog, 118, 119
  - in pigeon, 233
- Petromyzon marinus*, 19
- Petromyzontoidea, 8, 10
- Petrosal bone, 136
- Petrosal ganglion, 75
- Phalanges
  - in cat, 147, 149
  - in frog, 118
  - in mudpuppy, 92
  - in pigeon, 232, 233
- Pharyngeal artery, 199
- Pharyngeal slits, 5, 8
  - in lamprey, 20
  - in mudpuppy, 94
  - in shark, 37
- Pharyngeal teeth, 82
- Pharyngobranchial cartilages, 28
- Pharyngoesophageal artery, 52
- Pharynx
  - in cat, 182
  - in frog, 120
  - in mudpuppy, 95–96
  - in perch, 82, 83
  - in shark, 37, 46
- Phrenic nerve, 185, 198
- Phylogeny
  - classification and, 1–4
  - of Deuterostomata, 4–7
  - of vertebrates, 8–17
- Pia mater, 218
- Pigeon
  - body cavity, viscera, and vessels, 241–250
  - external anatomy, 234–235
  - musculature, 236–240
  - skeleton, 227–234
- Pineal body, 224
- Pineal complex, 21
- Pineal eye complex, 24
- Pineal gland, 221
- Pinnae, 152
- Piriform lobe, 220
- Piriformis, 170
- Pisiform bone, 147
- Piston cartilage (lingual cartilage), 19, 23
- Piston (tongue), 23
- Placodermi, 9, 10, 12
- Placoid scales (denticles), 35
- Plantaris, 173
- Plesiomorphic traits, 3
- Pleura, 185
- Pleurapophyses, 142
- Pleuroperitoneal cavity
  - of frog, 120–125
  - of lamprey, 21–22
  - of mudpuppy, 96–98
  - of perch, 83–87
  - of shark, 47–50
- Polypteriformes, 11, 13
- Pons, 222, 224
- Popliteal notch, 148
- Popliteus muscle, 173
- Portal veins. *see* Hepatic portal vein; Renal portal vein
- Postcleithrum, 80
- Postcranial skeleton
  - of cat, 140–151
  - of frog, 117–118
  - of mudpuppy, 92–94
  - of perch, 80–81
  - of pigeon, 229–233
  - of shark, 31–33
- Posterior auricular artery, 199
- Posterior cardinal vein
  - in lamprey, 24, 26
  - in mudpuppy, 105
  - in shark, 59
- Posterior (caudal), defined, xx
- Posterior chamber, of eye, 67
- Posterior commissure, 224
- Posterior cornua, 116
- Posterior cranial fossa, 138
- Posterior dorsal fin
  - in lamprey, 21
  - in perch, 80, 81
  - in shark, 28, 33, 37
- Posterior facial vein. *see* Maxillary vein

Posterior intestinal artery, 55  
 Posterior intestinal vein, 58  
 Posterior lateral line nerve, 75  
 Posterior lienogastric vein, 58  
 Posterior mesenteric artery  
   in cat, 204, 207  
   in pigeon, 250  
   in shark, 55  
 Posterior mesenteric vein  
   in cat, 207  
   in pigeon, 246  
 Posterior pancreaticoduodenal artery/vein, 207  
 Posterior renal portal vein, 247  
 Posterior renal vein, 247  
 Posterior semicircular duct, 67  
 Posterior splenic artery/vein, 206  
 Posterior utriculus, 67  
 Posterior vena cava  
   in cat, 185, 195, 201  
   in frog, 125, 129  
   in mudpuppy, 98  
   in pigeon, 243  
 Posterior ventrolateral artery, 55  
 Postorbital process  
   in cat, 134  
   in pigeon, 229  
   in shark, 28  
 Postotic lateral line nerves, 74  
 Postpatagium, 236  
 Posttemporal bone, 80  
 Posttrematic artery, 47  
 Posttrematic gill filaments, 83  
 Postzygapophysis  
   in cat, 140  
   in mudpuppy, 92  
 Precerebral cavity, 28  
 Precerebral fenestra, 28  
 Prehallux, 118  
 Premaxilla  
   in cat, 134  
   in pigeon, 229  
   in frog, 114  
   in mudpuppy, 89  
   in perch, 79, 81  
 Premaxillary teeth  
   in frog, 114, 120  
   in mudpuppy, 95  
 Premolar teeth, 134  
 Preoperculum, 77  
 Preorbitalis muscle, 65  
 Preotic lateral line nerves, 74  
 Prepollex, 118  
 Presphenoid bone, 135  
 Pretrematic artery, 47  
 Pretrematic gill filaments, 83  
 Prezygapophysis  
   in cat, 140  
   in mudpuppy, 92  
 Primary gill lamellae, 46  
 Primary tongue, 46  
 Procoracoid bone  
   in frog, 118  
   in perch, 80  
   in pigeon, 231  
 Procoracoid cartilage, 92  
 Prootic bone  
   in frog, 116  
   in mudpuppy, 89  
 Propatagium, 236  
 Propterygium, 33  
 Prostate gland, 216  
 Protostomata, 2, 4  
 Proventriculus, 242, 246  
 Proximal, defined, xx  
 Pseudobranch, 37  
 Pterygiophore  
   in perch, 80  
   in shark, 33  
 Pterygoid blades, 134  
 Pterygoid bone  
   in frog, 116  
   in mudpuppy, 89  
   in pigeon, 229  
 Pterygoid muscle, 180  
 Pterygoid processes, 135  
 Pterygoid ridge, 120  
 Pterygoid teeth, 95  
 Pubic artery, 249  
 Pubic cartilage, 92  
 Pubic symphysis, 147  
 Pubic vein, 249  
 Pubis  
   in cat, 147  
   in frog, 118  
   in pigeon, 233  
 Puboischiadic bar, 33  
 Puboischiadic plate, 92  
 Pudental artery/vein, 168  
 Pulmocutaneous arch, 127  
 Pulmonary arteries  
   in cat, 195  
   in frog, 127  
   in mudpuppy, 107  
   in pigeon, 243  
 Pulmonary ligament  
   in cat, 185  
   in mudpuppy, 98  
 Pulmonary trunk  
   in cat, 195  
   in pigeon, 243  
 Pulmonary veins  
   in cat, 195  
   in frog, 128  
   in pigeon, 244  
 Pupil, 66  
 Pygostyle, 230  
 Pyloric cecum, 85  
 Pyloric region of stomach, 49  
 Pyloric sphincter  
   in cat, 188  
   in mudpuppy, 98

Pylorus, 49  
Pyramids, 222  
Pyriformis (piriformis), 170

## Q

Quadrates bone  
  in mudpuppy, 89  
  in perch, 79  
  in pigeon, 229  
Quadrates cartilage, 90  
Quadratojugal bone  
  in frog, 114  
  in pigeon, 229  
Quadratus femoris, 168  
R  
Radial bones, 80  
Radial fossa, 145  
Radial notch, 146  
Radial pterygiophores, 33  
Radiale, 232  
Radices, 105  
Radio-ulna, 118  
Radius  
  in cat, 146–147  
  in frog, 118  
  in mudpuppy, 92  
  in pigeon, 231  
Ramus of dentary, 139  
*Rana catesbeiana*, 113  
Raphes, 41  
Ratfish, 27  
Rays, 27  
Rectal artery/vein, 207  
Rectal gland (digitiform gland), 49  
Rectrices, 234  
Rectum  
  in cat, 192  
  in perch, 85  
  in shark, 49  
Rectus abdominis, 174  
Rectus femoris, 168  
Rectus muscles of eye, 64  
Remigeal papillae, 232  
Remiges, 234  
Renal artery  
  in cat, 202  
  in mudpuppy, 107  
  in pigeon, 250  
Renal capsule, 212  
Renal cortex, 214  
Renal medulla, 214  
Renal papilla, 214  
Renal pelvis, 214  
Renal portal system, 58  
Renal portal vein  
  in frog, 130  
  in mudpuppy, 105  
  in pigeon, 247, 249  
  in shark, 58  
Renal pyramid, 214  
Renal sinus, 214

Renal veins  
  in cat, 202  
  in frog, 129  
  in mudpuppy, 105  
  in pigeon, 246, 247  
  in shark, 58, 59  
Reproductive system. *see* Urogenital system  
Reptilia, 4, 15, 16, 17  
Respiratory system  
  of cat, 182–185  
  of pigeon, 241  
  of shark, 45–50  
Respiratory tube (“pharynx”), 23  
Retina, 66  
Rhachis, 234  
Rhamphotheca, 234  
Rhinal sulcus, 220  
Rhinarium, 152  
Rhpidistia, 12, 14  
Rhomboideus capitis, 163  
Rhomboideus profundus, 241  
Rhomboideus superficialis, 241  
Rhomboideus, 163  
Ribs  
  in cat, 144  
  in mudpuppy, 92  
  in perch, 80  
  in pigeon, 230–231  
  in shark, 33  
Rostral carina, 28  
Rostral, defined, xx  
Rostral fenestra, 28  
Rostrum  
  in cat, 134  
  in shark, 28  
Round ligament, 188, 217  
Round window, 137  
Rugae of stomach  
  in cat, 188  
  in shark, 49

## S

Sacculus, 67  
Sacral artery, 205  
Sacral foramina, 143  
Sacral vein, 205  
Sacral vertebrae  
  in cat, 140, 142–143  
  in frog, 117  
  in mudpuppy, 92  
  in pigeon, 229  
Sagittal crest, 134  
Sagittal, defined, xx  
Salamanders, 89  
Salivary glands, 180  
Saphenous artery, 168  
Saphenous nerve, 168  
Saphenous vein, 168  
Sarcopterygii, 12, 13, 14  
Sartorius, 165  
Scalenus, 174



- Scales  
   in perch, 81  
   in pigeon, 234  
   in shark, 35
- Scapholunar bone, 147
- Scapula  
   in cat, 144  
   in mudpuppy, 92  
   in frog, 117  
   in perch, 80  
   in pigeon, 231
- Scapular artery, 201
- Scapular process, 33
- Scapular spine, 144
- Scapular vein, 163, 197
- Scapulotriceps, 238
- Sciatic artery, 127
- Sciatic vein, 130
- Sclera, 66
- Sclerotic ring, 229
- Scrotum, 152, 214
- Sella turcica, 138
- Semicircular ducts, 67
- Semimembranosus muscle, 165
- Seminal vesicle, 62
- Semispinalis capitis, 178
- Semispinalis cervicis, 178
- Semitendinosus, 165
- Sensory organs, 63–69
- Septum pellucidum, 224
- Serratus dorsalis caudalis, 174
- Serratus dorsalis cranialis, 174
- Serratus ventralis, 163
- Shaft  
   of feather, 234  
   of femur, 147  
   of fibula, 149  
   of humerus, 145  
   of rib, 144
- Shank. *see* Crus
- Shark  
   brain and cranial nerves, 70–76  
   cardiovascular system, 51–59  
   digestive and respiratory systems, 45–50  
   external anatomy, 35–38  
   muscular system, 39–45  
   sensory organs, 63–69  
   skeletal system, 27–35  
   urogenital system, 59–63
- Shell gland (nidamental gland), 63
- Sinus venosus  
   in frog, 125  
   in lamprey, 24  
   in mudpuppy, 102  
   in perch, 86  
   in pigeon, 241  
   in shark, 51
- Siphon, 40, 62
- Skates, 27
- Skeletal system  
   of cat, 132–151  
   of frog, 113–118  
   of lamprey, 19–20  
   of mudpuppy, 89–94  
   of perch, 77–80  
   of pigeon, 227–234  
   of shark, 27–35
- Skeletogenous septum, horizontal, 40
- Skin. *see* Integument
- Skull  
   in cat, 132–138  
   in frog, 113–116  
   in mudpuppy, 89–90  
   in perch, 77–79  
   in pigeon, 227–229
- Small intestine  
   in cat, 192  
   in frog, 125  
   in mudpuppy, 98  
   in perch, 83  
   in pigeon, 242, 246
- Snout, of shark, 37
- Soft palate, 182
- Soleus muscle, 170
- Somatic motor columns, 72
- Somatic sensory column, 73
- Somitichordata, 2, 5, 6
- Sperm sac, 62
- Spermatic artery, 204
- Spermatic cord, 216
- Spermatic vein  
   in cat, 204  
   in frog, 129
- Sphenethmoid bone, 114
- Sphenoid bone, 135
- Sphenopalatine foramen, 135
- Spinal cord, in lamprey, 23
- Spinal nerves, 75
- Spinalis dorsii, 178
- Spine of clasper, 33
- Spinodeltoid, 158
- Spinotrapezius, 158
- Spiracle, 37, 46
- Spiracular artery, 41, 51
- Spiracular valve, 37
- Spiracularis muscle, 40
- Spiral valve, 49
- Splanchnocranium, 28
- Spleen  
   in cat, 188  
   in frog, 125  
   in mudpuppy, 98  
   in perch, 83  
   in pigeon, 246  
   in shark, 49
- Splenic bone, 90
- Splenic teeth, 96
- Splenic artery, 206
- Splenic vein, 205–206
- Splenium of corpus callosum, 224
- Splenius, 163
- Squalus acanthias*, 27

Squamosal bones  
   in cat, 136  
   in frog, 116  
   in mudpuppy, 89  
   in pigeon, 229  
 Stapedial artery, 51  
 Stapes, 137  
 Statoacoustic nerve (CN VIII), 74  
 Stegocephali, 12, 14, 15  
 Sternal notch, 231  
 Sternal rib, 230  
 Sternebrae, 144  
 Sternohyoid muscle, 174, 178  
 Sternomastoid muscle, 158  
 Sternum  
   in cat, 144  
   in frog, 118  
   in pigeon, 229, 231  
 Stomach  
   in cat, 188  
   in frog, 124  
   in mudpuppy, 98  
   in perch, 83  
   in pigeon, 242, 246  
   in shark, 49  
 Styloform process, 138  
 Styloglossus muscle, 179  
 Stylohyoid bone, 139  
 Stylohyoid muscle, 179  
 Styloid process, 146, 147  
 Stylomastoid foramen, 137  
 Stylus of columella, 90  
 Subclavian artery  
   in cat, 195, 197, 200–201  
   in frog, 127  
   in mudpuppy, 107  
   in pigeon, 242  
   in shark, 52  
 Subclavian vein  
   in cat, 196, 200–201  
   in frog, 127  
   in mudpuppy, 102  
   in pigeon, 243  
   in shark, 58  
 Sublingual gland, 180  
 Suboperculum, 77  
 Subscapular artery, 201  
 Subscapular fossa, 144  
 Subscapular vein  
   in cat, 201  
   in frog, 127  
   in shark, 59  
 Subscapularis, 165  
 Sulcus, 218, 222  
 Superficial constrictor muscles, 41  
 Superficial ophthalmic branch of ADLLN, 74  
 Superficial ophthalmic branch of trigeminal nerve, 74  
 Superficial ophthalmic foramina, 28  
 Superficial ophthalmic nerve, 63–64, 65  
 Superficial temporal artery, 199  
 Superficial temporal vein, 200  
 Superior colliculi, 222

Supra-angular bone, 229  
 Suprachoroidea, 66  
 Supracleithrum, 80  
 Supracondyloid foramen, of humerus, 146  
 Supracoracoideus muscle, 231, 239  
 Supraoccipital bone, 134  
 Supraorbital crest, 28  
 Suprascapula, 118  
 Suprascapular cartilage  
   in mudpuppy, 92  
   in shark, 33  
 Supraspinatus muscle, 163  
 Supraspinous fossa, 145  
 Supratemporal lateral line nerve, 75  
 Suspensory ovarian ligament, 217  
 Swim bladder, 83, 86  
 Sympathetic trunk, 198–199  
 Sympleiomorphic traits, 3  
 Synapomorphic traits, 3  
 Synapsida, 15, 16  
 Synotic tectum, 90  
 Synsacrum, 230  
 Syrinx, 244  
 Systemic arch, 127

## T

Tail  
   of cat, 152  
   of lamprey, 21  
   of mudpuppy, 94  
   of perch, 77, 81  
   of pigeon, 234  
   postanal, 5  
   of shark, 37  
 Tail fin, 94  
 Talus (astragalus), 149  
 Tarsal bones  
   in cat, 149  
   in mudpuppy, 92  
   in pigeon, 233  
 Tarsometatarsus, 233  
 Taxonomy, 1–4  
 Tectum, 222  
 Teeth  
   in cat, 134  
   in frog, 114, 120  
   horny, in lamprey, 20–21  
   in mudpuppy, 90, 95, 96  
   in perch, 82  
   in shark, 46  
 Tela choroidea  
   in cat, 221, 222, 224  
   in shark, 72  
 Telencephalon  
   in cat, 218–220  
   in shark, 71  
 Teleost fishes, 77  
 Teleostomi, 10, 11, 13  
 Temporal artery, 199  
 Temporal bone, 134, 136, 137  
 Temporal fossa, 133

Temporal lines, 134  
 Temporal vein, 200  
 Temporalis muscle, 180  
 Tendons, defined, 153  
 Tensor fasciae latae, 166  
 Tentorium, 138  
 Tenuissimus, 166  
 Teres major, 163  
 Teres minor, 163  
 Terminal nerve, 72, 74  
 Testicular artery  
   in mudpuppy, 107  
   in shark, 53  
 Testicular duct, 84  
 Testicular vein, 105  
 Testis  
   in cat, 214  
   in frog, 125  
   in lamprey, 22  
   in mudpuppy, 102  
   in pigeon, 84, 246  
   in shark, 49, 62  
 Tetrapoda, 12, 15, 16  
 Thalamus  
   in cat, 221  
   in shark, 72  
 Theria, 131  
 Third ventricle  
   in cat, 220  
   in shark, 72, 76  
 Thoracic aorta, 195  
 Thoracic vertebrae  
   in cat, 140, 141–142  
   in pigeon, 229  
 Thorax, 152, 184–185  
 Thyrocervical artery, 201  
 Thyrohyoid bone, 139  
 Thyrohyoid muscle, 178  
 Thyroid cartilage, 183  
 Tibia  
   in cat, 148–149  
   in frog, 118  
   in mudpuppy, 92  
 Tibial crest, 148  
 Tibial tuberosity, 148  
 Tibiale (astragalus), 118  
 Tibialis anterior (tibialis cranialis), 173  
 Tibialis posterior (tibialis caudalis), 173  
 Tibio-fibula, 118  
 Tibiotarsus, 233  
 Tongue  
   in frog, 120  
   in lamprey, 23  
   in mudpuppy, 96  
   in shark, 46  
 Tonsillar pits, 181  
 Tori, 152  
 Trabeculae, 90  
 Trabecular horns, 90  
 Tracheal cartilages, 184  
 Transverse colon, 192  
 Transverse, defined, xxi  
 Transverse facial artery, 199  
 Transverse facial vein, 200  
 Transverse foramina, 141  
 Transverse jugular vein, 178, 197, 199  
 Transverse process, vertebral  
   in cat, 140  
   in frog, 117  
   in mudpuppy, 92  
 Transverse scapular artery, 201  
 Transverse scapular vein, 163, 197  
 Transverse septum  
   in lamprey, 24  
   in mudpuppy, 102  
   in perch, 83  
   in shark, 47, 51  
 Transversus abdominis, 174  
 Transversus costarum, 174  
 Transversus thoracis, 174  
 Trapezium, 147  
 Trapezoid body, 222  
 Trapezoid bone, 147  
 Triceps brachii, 158, 165  
 Triceps surae, 171  
 Trigeminal foramen, 116  
 Trigeminal nerve (CN V)  
   in cat, 222  
   in shark, 74  
 Trigemino-facial foramen, 28  
 Triosseal canal, 231  
 Trochanteric fossa, 147  
 Trochlea, of humerus, 145  
 Trochlea tali, 149  
 Trochlear foramen, 28  
 Trochlear nerve (CN IV)  
   in cat, 222  
   in shark, 66, 74  
 Trochlear notch, 146  
 Truncus arteriosus, 125  
 Trunk  
   in cat, 151, 174–178  
   in mudpuppy, 94  
   of perch, 77, 81  
   in shark, 37, 39–40  
 Trunk vertebrae  
   in mudpuppy, 92  
   in perch, 80  
 Tuber cinereum, 220  
 Tuberculum, of rib, 142, 144  
 Tunica vaginalis, 214  
 Turbinate bones, 136  
 Tympanic bullae, 134, 137–138  
 Tympanic membrane, 116, 119  
 Tympanohyoid bone, 139  
 Typhlosole, 22

**U**  
 Ulna  
   in cat, 146  
   in frog, 118  
   in mudpuppy, 92  
   in pigeon, 231



- Ulnare, 232
- Umbilical artery/vein, 205
- Unciform, 147
- Uncinate processes, 230
- Ureter, 246
- Urethra, 213
- Urethral orifice, 217
- Urinary bladder
  - in cat, 189, 213
  - in frog, 125
  - in mudpuppy, 97
  - in perch, 84
- Urinary duct, accessory, 62
- Urinary papilla, 37, 63
- Urochordata, 1, 2, 5–6, 7
- Urogenital aperture
  - in cat, 152, 217
  - in perch, 82
- Urogenital arteries, 127
- Urogenital papilla
  - in lamprey, 21
  - in shark, 37, 62
- Urogenital sinus
  - in cat, 217
  - in shark, 62
- Urogenital system
  - of cat, 212–218
  - of frog, 120–125
  - of lamprey, 21–22
  - of mudpuppy, 98–102
  - of perch, 84–85
  - of pigeon, 246
  - of shark, 59–63
- Uroneurals, 80
- Uropygial gland, 234
- Uropygium, 234
- Urostyle, 117
- Uterine body, 217
- Uterine horn, 213, 216
- Uterine tube (fallopian tube), 216
- Uterus, 63
- Utriculus, 67

## V

- Vagina, 217
- Vaginal cavity, 214
- Vagosympathetic trunk, 198
- Vagus foramen, 28
- Vagus nerve (CN X)
  - in cat, 185, 198, 222
  - in shark, 75
- Vallate papillae, 181
- Valvular intestine, 49
- Vanes, of feather, 234
- Vas deferens, 246
- Vascular sac, 76
- Vascular tunic, 66
- Vastus intermedius, 168
- Vastus lateralis, 168
- Vastus medialis, 168
- Veins. *see names of specific veins*; Venous system

- Velum, 19, 23
- Vena cava
  - in cat, 185, 195, 201
  - in frog, 125, 127, 129
  - in mudpuppy, 98
  - in pigeon, 243
- Venous system
  - of cat, 195–207
  - of frog, 127–130
  - of lamprey, 24, 26
  - of mudpuppy, 102–105
  - of perch, 86
  - of pigeon, 241–250
  - of shark, 55–59
- Venter, 234
- Ventral abdominal vein
  - in frog, 121, 130
  - in mudpuppy, 96, 98, 105
- Ventral aorta
  - in lamprey, 24
  - in shark, 51
- Ventral, defined, xx
- Ventral fissure, 222
- Ventral gastric artery, 55
- Ventral hyoid constrictor muscles, 41
- Ventral oblique muscle, 64
- Ventral rectus muscle, 64
- Ventral superficial constrictor muscles, 41
- Ventricles, of brain
  - in cat, 220, 224
  - in shark, 72, 76
- Ventricles, of heart
  - in cat, 194
  - in frog, 125
  - in lamprey, 24
  - in mudpuppy, 102
  - in perch, 86
  - in pigeon, 241
  - in shark, 51
- Ventrolateral arteries, 52, 55
- Vermis, 222
- Vertebrae
  - in cat, 140–141
  - in mudpuppy, 92
  - in perch, 80
  - in shark, 31–33
  - in frog, 117
  - in pigeon, 229–230
- Vertebral arch
  - in mudpuppy, 92
  - in shark, 33
- Vertebral artery
  - in cat, 201
  - in mudpuppy, 105
- Vertebral canal. *see* Neural canal
- Vertebral column
  - in cat, 140–144
  - in frog, 117
  - in shark, 28
- Vertebral rib
  - in cat, 144
  - in pigeon, 230

Vertebral vein, 196  
 Vertebrata  
   early evolution of, 8  
   phylogeny, 1, 6, 7–8  
   subgroups, 8–17  
 Vertebrochondral ribs, 144  
 Vertebrosteral ribs, 144  
 Vesicular vein, 98, 105  
 Vessels. *see* Arterial system; Venous system  
 Vestibular window (oval window), 137  
 Vestibule, 181  
 Vestibulocochlear nerve, 222. *see also* Statoacoustic nerve  
 Vibrissae (whiskers), 152  
 Viscera  
   of frog, 120–125  
   of lamprey, 21–22  
   of mudpuppy, 96–98  
   of perch, 83–86  
   of pigeon, 241–250  
   vessels of, in cat, 205  
 Visceral arches, 28, 42–43  
 Visceral branch of vagus nerve, 75  
 Visceral motor column, 73  
 Visceral pericardium  
   in cat, 186  
   in mudpuppy, 102  
   in shark, 51  
 Visceral peritoneum  
   in cat, 187  
   in perch, 83  
   in shark, 47  
 Visceral pleura, 185  
 Visceral sensory columns, 73  
 Visceral tunica vaginalis, 214  
 Vitreous chamber, of eye, 67  
 Vitreous humor, 67  
 Vocal cords, 184

Vomer  
   in cat, 136  
   in frog, 114  
   in mudpuppy, 89  
 Vomerine teeth  
   in frog, 120  
   in mudpuppy, 95  
 Vulva (urogenital aperture), 152, 217

## W

Whiskers. *see* Vibrissae  
 Wing of ilium, 147  
 Wolffian duct (archinephric duct)  
   in frog, 125  
   in lamprey, 22  
   in mudpuppy, 102  
   in perch, 85  
   in shark, 62

## X

Xiphihumeralis, 160  
 Xiphisternum  
   in cat, 144  
   in frog, 118  
 Xiphoid cartilage, 144

## Y

Yolk sac, 63

## Z

Zygomatic arch  
   in cat, 133  
   in pigeon, 229  
 Zygomatic bone, 134, 138